

The authors would like to acknowledge the help of all the people involved in this project and especially to Eugene Myers, Milan Profant and Ricard Simo who took part in the review process. Without their support, this book would not have become a reality.



Miroslav Tedla  
Gabriela Pavlovčinová  
Sabyasachi Chakrabarti

Basic  
Otorhino  
laryngology

2017

Univerzita Komenského v Bratislave

© Dr. Miroslav TEDLA, MD, PhD (Consultant ENT Surgeon, Medical Faculty of Comenius University and University Hospital Bratislava, Slovakia; Honorary Senior Research Fellow, Institute of Cancer and Genomic Sciences, University of Birmingham, UK; previously Consultant ENT/Head and Neck/Thyroid Surgeon, University Hospitals Coventry and Warwickshire, UK)

Dr. Gabriela PAVLOVČINOVÁ, MD, PhD (ENT Specialist, Medical Faculty of Comenius University and University Hospital Bratislava, Slovakia)

Dr. Sabyasachi CHAKRABARTI, MS, MRCS (ENT), DOHNS FRCS (ORL-HNS) (Consultant ENT, AMRI hospitals, Kolkata and Consultant (ENT) at Calcutta Medical Research Institute, Kolkata, previously Specialist Registrar, University Hospitals Coventry and Warwickshire, UK), 2017

Recenzent: Mr. Ricard Simo LMS, FRCS, FRCS (ORL-HNS)  
prof. MUDr. Milan Profant, CSc.

Ilustrácie: © Daniel Denes, Martina Patočková

Obálka: © Miroslav Čipár

**ISBN 978-80-223-3963-6**



# CONTENTS

Foreword .....	9
<b>1 THE EAR .....</b>	<b>11</b>
1.1 Applied Anatomy and Physiology .....	11
1.1.1 The external ear .....	11
1.1.2 The middle ear.....	11
1.1.3 The inner ear.....	13
1.1.4 The mechanism of hearing .....	16
1.1.5 Physiology of the balance system.....	17
1.2 Evaluation.....	18
1.3 Diseases of the External Ear .....	25
1.3.1 Congenital anomalies of the external ear .....	25
1.3.2 Inflammation of the external ear .....	27
1.3.3 Trauma to the external ear.....	29
1.3.4 Cerumen .....	30
1.3.5 Foreign bodies in the external auditory canal.....	31
1.3.6 Tumors of the external ear.....	31
1.4 Diseases of the Middle Ear .....	33
1.4.1 Congenital anomalies of the middle ear .....	33
1.4.2 Inflammation of the middle ear .....	33
1.4.3 Trauma to the middle ear – temporal bone fractures .....	39
1.4.4 Tumours of the middle ear .....	41
1.5 Diseases of the Inner Ear .....	43
1.5.1 Congenital anomalies of the inner ear .....	43
1.5.2 Otosclerosis .....	43
1.5.3 Ménière's disease.....	45
1.5.4 Tumours of the inner ear .....	48
1.5.5 Sensorineural hearing loss.....	49
1.5.6 Vertigo.....	53
1.5.7 Tinnitus .....	55
1.6 Facial Nerve.....	57
1.6.1 Anatomy .....	57
1.6.2 Facial nerve paralysis .....	60
1.6.3 Bell's palsy.....	61
1.6.4 Herpes zoster oticus (Ramsay-Hunt syndrome) .....	62
<b>2 NOSE AND PARANASAL SINUSES.....</b>	<b>64</b>
2.1 Applied Anatomy.....	64
2.2 Physiology .....	67
2.3 Evaluation.....	68
2.4 Diseases of the Nose and Paranasal Sinuses.....	71
2.4.1 Inflammatory diseases.....	71
2.4.2 Complications of sinus infections .....	76

2.4.3	Tumours .....	80
2.4.4	Trauma .....	87
2.4.5	Nasal septum .....	91
2.4.6	Epistaxis .....	93
2.4.7	Disturbances of olfaction.....	95
2.4.8	Congenital defects of the nose.....	95
2.4.9	Foreign bodies in the nose .....	97
2.4.10	Other diseases.....	97
<b>3</b>	<b>ORAL CAVITY AND PHARYNX .....</b>	<b>99</b>
3.1	Applied Anatomy.....	99
3.2	Physiology .....	103
3.2.1	Swallowing.....	104
3.2.2	Taste .....	105
3.2.3	Immune-specific function of Waldeyer's ring.....	105
3.2.4	Speech .....	105
3.3	Evaluation.....	106
3.4	Diseases of the Oral Cavity and Pharynx .....	107
3.4.1	Congenital anomalies .....	107
3.4.2	Hypertrophy of lymphoepithelial organs.....	109
3.4.3	Inflammatory diseases.....	110
3.4.4	Complications of infectious diseases.....	119
3.4.5	Other non- neoplastic conditions.....	122
3.4.6	Swallowing disorders .....	124
3.4.7	Tumours of the oral cavity and pharynx.....	124
<b>4</b>	<b>OESOPHAGUS .....</b>	<b>131</b>
4.1	Applied Anatomy.....	131
4.2	Physiology .....	132
4.3	Evaluation.....	132
4.4	Diseases of the Oesophagus.....	133
4.4.1	Congenital disorders.....	133
4.4.2	Inflammatory diseases .....	133
4.4.3	Trauma .....	134
4.4.4	Diverticulum.....	137
4.4.5	Tumours of the oesophagus.....	137
4.4.6	Motility disorders .....	138
<b>5</b>	<b>LARYNX AND TRACHEA .....</b>	<b>140</b>
5.1	Applied Anatomy.....	140
5.2	Physiology .....	144
5.3	Evaluation.....	146
5.4	Disease of the larynx and trachea .....	147
5.4.1	Congenital anomalies .....	147
5.4.2	Laryngeal and tracheal trauma .....	150
5.4.3	Inflammatory diseases .....	151
5.4.4	Benign and malignant tumours.....	155
5.4.5	Functional disorders of the larynx .....	162
5.4.6	Foreign bodies in the upper airway.....	163
<b>6</b>	<b>NECK.....</b>	<b>165</b>
6.1	Applied Anatomy and Physiology .....	165
6.2	Evaluation.....	170

6.3	Diseases of the Neck.....	174
6.3.1	Congenital abnormalities.....	174
6.3.2	Inflammatory diseases.....	176
6.3.3	Trauma.....	180
6.3.4	Vascular malformations.....	180
6.3.5	Musculoskeletal defects.....	182
6.3.6	Benign tumours.....	183
6.3.7	Malignant tumours.....	184
<b>7</b>	<b>THYROID AND PARATHYROID GLANDS.....</b>	<b>188</b>
7.1	Applied Anatomy.....	188
7.2	Thyroid and Parathyroid Physiology.....	190
7.3	Evaluation.....	191
7.4	Thyroid and Parathyroid Diseases.....	194
7.4.1	Thyroid dysfunction.....	194
7.4.2	Parathyroid adenoma.....	195
7.4.3	Congenital abnormalities.....	195
7.4.4	Thyroiditis.....	196
7.4.5	Benign thyroid nodules and thyroid cancer.....	197
7.5	Thyroid and Parathyroid Surgery.....	200
<b>8</b>	<b>SALIVARY GLANDS.....</b>	<b>202</b>
8.1	Applied Anatomy.....	202
8.2	Physiology.....	203
8.3	Evaluation.....	203
8.4	Diseases of the Salivary Glands.....	204
8.4.1	Inflammatory diseases of the salivary glands.....	204
8.4.2	Sialosis.....	205
8.4.3	Sialolithiasis.....	206
8.4.4	Tumours of the salivary glands.....	207
<b>9</b>	<b>BASICS OF PHONiatrics.....</b>	<b>211</b>
9.1	Speech and Language Development.....	211
9.2	Speech and Language Disorders.....	211
9.3	Hearing Loss.....	212
9.3.1	Types of hearing loss.....	213
9.3.2	Degrees of hearing loss.....	213
9.4	Treatment and Rehabilitation of Hearing Loss.....	214
9.5	Voice Disorders.....	216
9.6	Voice and Speech after Laryngectomy.....	218
<b>10</b>	<b>PRINCIPLES OF SELECTED SURGICAL PROCEDURES IN OTORHINOLARYNGOLOGY.....</b>	<b>221</b>
10.1	Tonsillectomy.....	221
10.2	Paratonsillar Abscess Drainage.....	222
10.3	Adenoidectomy.....	222
10.4	Rigid Pharyngoscopy, Laryngoscopy and Oesophagoscopy.....	223
10.5	Nasal Septoplasty.....	224
10.6	Basic Principles of Functional Endoscopic Sinus Surgery (FESS).....	224
10.7	Myringotomy, Grommet Insertion.....	225
10.8	Myringoplasty.....	226
10.9	Basic Mastoidectomy.....	227
10.10	Excision of the thyroglossal cyst (sistrunk procedure).....	227
10.11	Thyroidectomy.....	228

10.12 Parathyroidectomy .....	229
10.13 Parotidectomy .....	229
10.14 Main Principles of the Neck Dissection.....	230
10.15 Securing airway – tracheostomy, coniotomy, endotracheal intubation .....	231
References .....	233
List of Figures .....	234
List of Tables.....	240
List of Abbreviations.....	241
Index.....	242
Appendix .....	247

# FOREWORD

This book is designed to be used by medical students and junior doctors. It includes the entirety of our vibrant specialty and is written in English so that it may be read by medical students in the many countries comprising Central Europe. In each section a brief summary of the basic anatomy and physiology is presented and then the key elements for making a diagnosis such as a pertinent history, physical examination, and specialized testing, including imaging, are presented in a clear manner making it very understandable for the intended reader. The usual treatment options are also very clearly presented. Reading this excellent contribution to the literature after a day in the ENT Clinic will supply the reader with enough information about the patient/s seen in the clinic that day to more fully understand and appreciate the clinical experience.

Miro Tedla M.D. Ph.D., the Senior author, is a member of the Faculty in the Department of Otolaryngology at the Comenius University in Bratislava, Slovakia. He was ably assisted by Gabriela Pavlovčinová M.D. Ph.D. also from Comenius University and Dr Sabyasachi Chakrabarti, MS (ENT), DOHNS, MRCS (ENT), FRCS (ORL-HNS), from the Calcutta Medical Research Institute, Kolkata, India, previously working as a specialist registrar in Coventry U.K. Professor Milan Profant, the Chairman of the Department, who is a very good friend of mine, was anxious to expose Dr. Tedla to a basic science research experience which was not available in their Department at that time. As Chairman of the Department of Otolaryngology at the University of Pittsburgh I arranged for Dr. Tedla to be a Visiting Research Fellow in our laboratory from 2002 – 2004. This experience was funded through a Ruth Crawford Mitchell Fellowship from the University of Pittsburgh. These funds are used to support Visiting Scholars from Slovakia who are studying in the U.S or U.S. Scholars studying in Slovakia.

As his mentor I came to know Dr. Tedla very well during those years and then again when he returned in 2005 – 2006 as a Visiting Fellow in Swallowing Disorders with Professor Ricardo Carrau. Dr Tedla has devoted much of his research to this subspecialty which ultimately led to his writing a textbook – Swallowing Disorders-published in Slovak language in 2009.

He spent three years as a Consultant in the University Hospitals of Coventry and Warwickshire U.K. and now having returned home to his native Slovakia he will, I'm certain, be one of the leaders in Otolaryngology in Slovakia.

**Eugene N. Myers M. D. F.A.C.S. F.R.C.S Edin. (Hon)**

Distinguished Professor and Emeritus Chair

Department of Otolaryngology

University of Pittsburgh School of Medicine

Author of: Cancer of the Head and Neck-4<sup>th</sup> Ed. Elsevier

Operative Otolaryngology-Head and Neck Surgery 3<sup>rd</sup> Ed. (in preparation) Elsevier

Decision Making in Otolaryngology-Head and Neck Surgery 2<sup>nd</sup> Ed. (in preparation) Jaypee Press

This book was kindly supported by following companies:

Centrum Kramáre  
Dently  
ENT studio o.z.  
InHANSE  
Medel  
Medicentrum Piešťany  
Mediklinik Levice  
Medtronic  
Nutricia  
ORL Humenné  
Radix

# 1 THE EAR

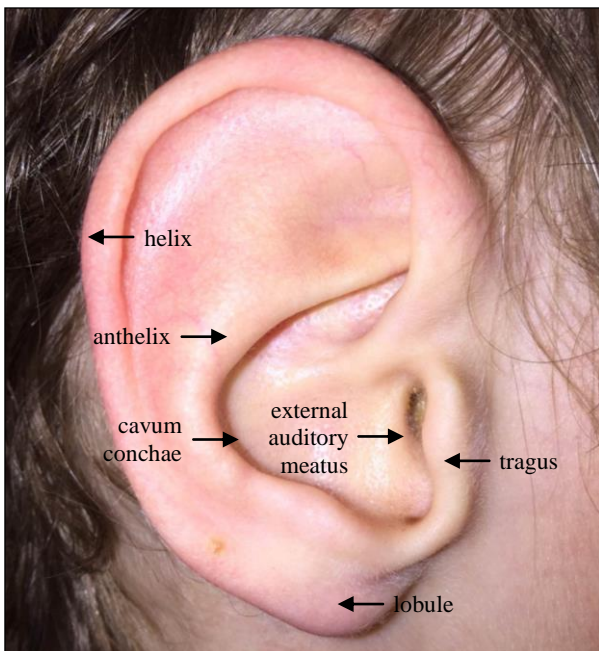
## 1.1 APPLIED ANATOMY AND PHYSIOLOGY

The ear is composed of the external, middle and inner ear segments, which function as one organ to support its physiological functions of hearing, balance and body position.

### 1.1.1 The external ear

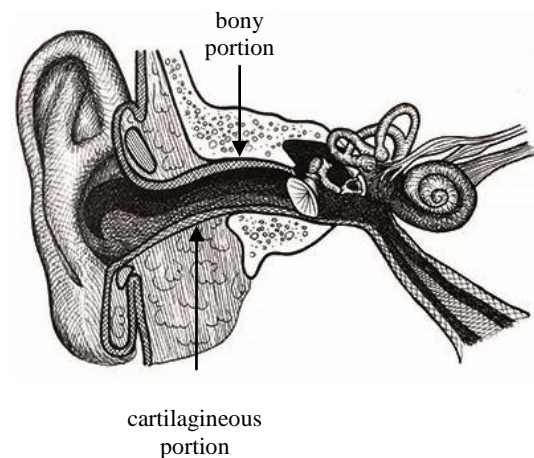
The external ear consists of the auricle, external auditory canal and the epithelial surface of the tympanic membrane.

**The auricle (pinna)** is composed of fibroelastic cartilage covered by skin (Figure 1.1).



**Figure 1.1**  
Auricle-lateral surface

**The external auditory meatus**, also known as the external acoustic canal, is about 2.5 cm long in adults and is divided into an outer cartilaginous portion (one third) and an inner bony portion (two thirds) (Figure 1.2). The external auditory canal protects the middle and the inner ear and serves as a channel for sound transmission. The skin lining the auditory canal is very thin; it adheres closely to the cartilaginous and osseous portions of the tube, and covers the outer surface of the tympanic membrane. In the subcutaneous tissue of the cartilaginous portion of the meatus are numerous cerumen glands, which secrete the cerumen. There are no glands or hair follicles in the subcutaneous layer of the bony portion. This very thin skin can be easily traumatised.

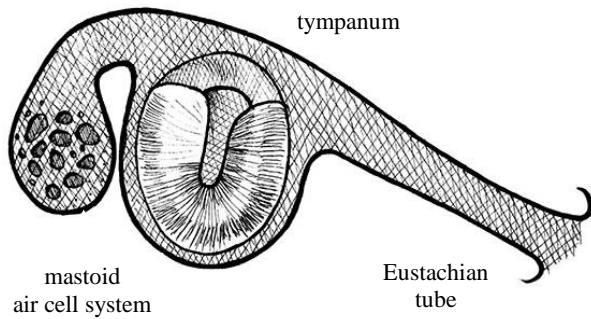


**Figure 1.2**  
External auditory meatus

### 1.1.2 The middle ear

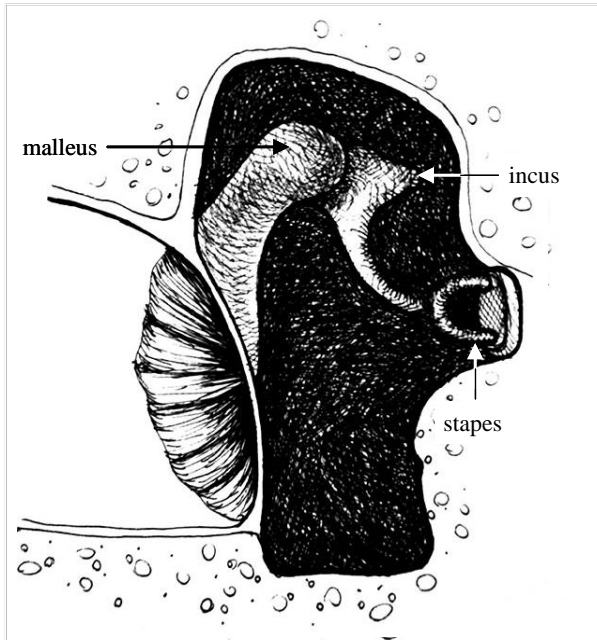
The middle ear cleft is a continuous space that begins from the nasopharyngeal orifice of the Eustachian tube and extends to the furthest mastoid air cell. It includes the tympanum (middle ear

cavity proper), the Eustachian tube, and the mastoid air cell system (Figure 1.3).



**Figure 1.3a**

Scheme of the middle ear – parts of the middle ear



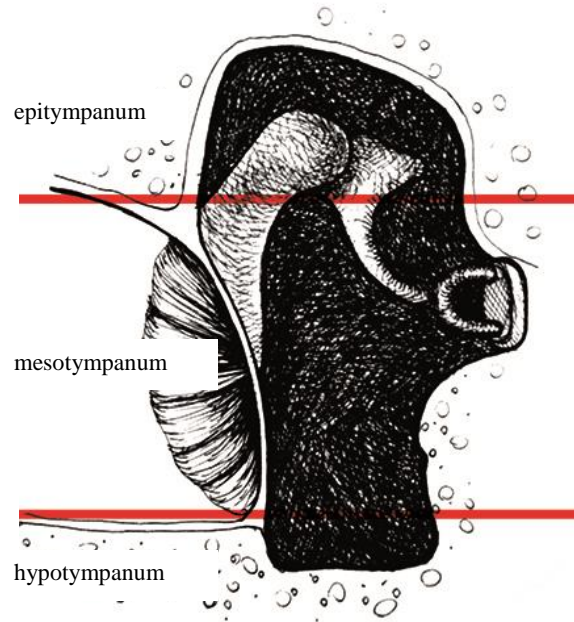
**Figure 1.3b**

Scheme of the middle ear – ossicles

**The tympanic cavity** is lined with mucosa consisting of cuboidal or ciliated cylindrical epithelium. The mucociliary transport is oriented towards the ostium of the Eustachian tube. This air-containing cavity is separated from the external ear by the tympanic membrane (TM), and from the inner ear by the round and oval windows.

The middle ear cavity proper is divided into three parts (Figure 1.4):

1. epitympanum or attic (above TM);
2. mesotympanum (opposite TM);
3. hypotympanum (below TM).



**Figure 1.4**

Levels of the tympanic cavity

**The tympanic membrane** separates the external ear from the middle ear. It is oval in shape, 9–10 mm tall, 8–9 mm wide, and 0.1 mm thick.

The primary function of the middle ear is to efficiently transfer sound energy from compression waves in the air to fluid–membrane waves within the cochlea. The sound energy is transmitted and amplified by a chain of three bones known as ossicles (malleus, incus and stapes) from the tympanic membrane to the oval window of the cochlea.

**The ossicles** are connected by synovial joints. The smallest ossicle is the stapes; its footplate is set in the oval window.

The middle ear is filled with air which flows from the nasopharynx into the middle ear through the Eustachian tube. The normally closed Eustachian tube opens briefly with swallowing as a result of

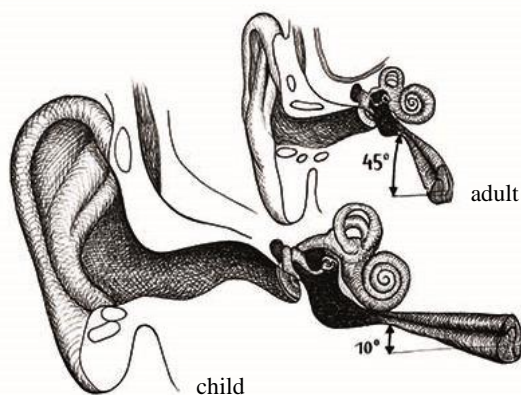


contraction of the tensor veli palatini muscle to transmit air into the middle ear.

**The Eustachian tube** has three important functions:

- ventilation (pressure regulation of the middle ear)
- protection of the middle ear from ascending nasopharyngeal secretions and pathogens
- clearance of middle ear secretions towards the nasopharynx (mucociliary transport, pumping action during closing)

This tube is 3.5–4.0 cm long and is directed downwards, forwards and medially from the middle ear to the nasopharynx. It is lined by respiratory epithelium and is subject to all of the allergies, irritants and infections of this system. It consists of a cartilaginous portion and a bony portion; the junction between these parts (called the isthmus) is very narrow. The Eustachian tube is shorter, wider and more horizontal in children. Greater patency of the Eustachian tube allows easier access for secretions from the nasopharynx- the reason why infections are more common in infants and small children. (Figure 1.5).



**Figure 1.5**

Difference between the Eustachian tube in children and adults

The middle ear cleft includes the tympanum (middle ear cavity), Eustachian tube, and the mastoid air cell system. The middle ear cavity is divided into the mesotympanum, epitympanum (attic) and the hypotympanum. The tympanic membrane is the lateral wall of the middle ear and separates the middle ear from the external ear canal.

The fenestra vestibuli (fenestra ovalis, oval window) is an opening leading from the tympanic cavity into the vestibule of the internal ear. The fenestra cochleae (fenestra rotunda, round window) is situated inferior to and a little posterior to the fenestra vestibuli, from which it is separated by a rounded elevation, the promontory. It is placed at the bottom of a funnel-shaped depression and, in the cadaveric bone, leads into the cochlea of the internal ear. In the fresh state it is closed by a membrane, the secondary tympanic membrane, which is concave towards the tympanic cavity, and convex towards the cochlea. The promontory (promontorium) is a rounded prominence, formed by the projection outwards of the first turn of the cochlea.

The junction between the attic and mastoid antrum, called aditus ad antrum, is narrow and may be closed by granulation tissue in the case of chronic otitis leading to deficient aeration of the mastoid air cell system. The air cells of the temporal bone are in continuity with the air in the middle ear. There is a marked variability of pneumatization of the temporal bone.

### 1.1.3 The inner ear

#### Embryology

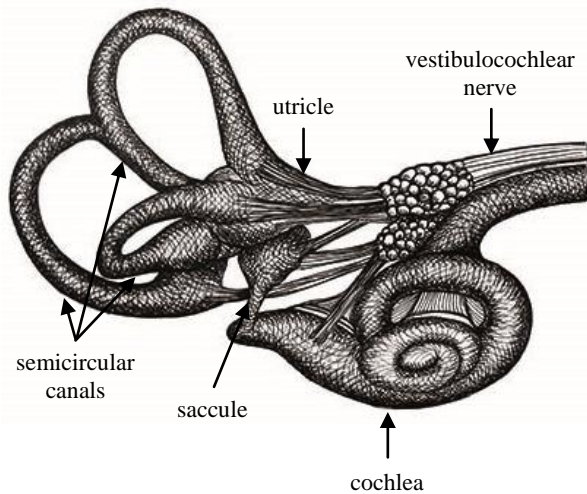
During week 4 of embryonic development, the human inner ear develops from the auditory placode, a thickening of the ectoderm that gives rise to the bipolar neurons of the cochlear and vestibular ganglions. As the auditory placode invaginates towards the embryonic mesoderm, it forms the auditory vesicle or otocysts. The auditory vesicle gives rise to the utricular and saccular components of the membranous labyrinth. They contain the sensory hair cells and otoliths of the macula of the utricle and of the saccule. At the beginning of the fifth week of development, the auditory vesicle also gives rise to the cochlear duct, which contains the spiral organ of Corti and the endolymph that accumulates in the membranous labyrinth.

#### Clinical anatomy

The inner ear is composed of two parts: the bony labyrinth, a system of cavities within the petrous portion of the temporal bone; and the membranous labyrinth, a system of ducts and sacs within the bony labyrinth.

**The bony labyrinth** protects delicate structures of the membranous labyrinth and is filled with a fluid called perilymph. The walls of the bony labyrinth consist of dense bone everywhere except in two small areas near the base of the cochlear spiral. The oval and round windows are openings in the bone of the labyrinth and they are closed by the stapes footplate and a membrane, respectively.

The bony labyrinth can be divided into five parts: the vestibule (housing the utricle and saccule), the cochlea, the semicircular canals, the vestibular aqueduct, and the cochlear aqueduct. The vestibule is an ovoid cavity located just medial to the tympanic cavity. The cochlea is anterior to the vestibule, and the apex of the cochlea is directed anteriorly and laterally. The three semicircular canals lie posterosuperior to the vestibule. Each canal forms about two thirds of a circle and communicates at each end with the vestibule. Each canal lies at right angles to each other (Figure 1.6).

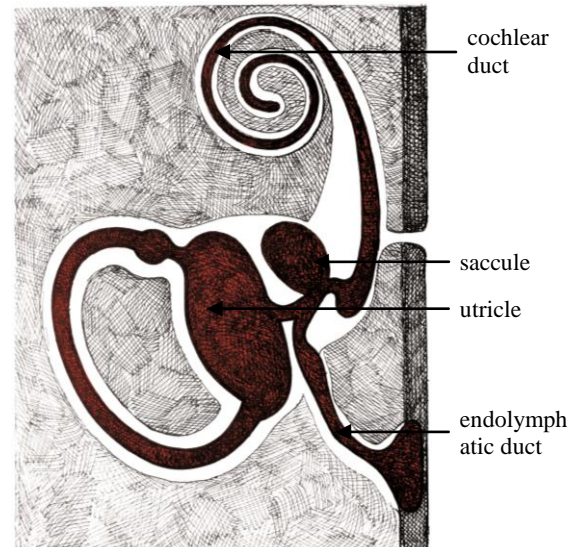


**Figure 1.6**

Inner ear anatomy

**The membranous labyrinth** consists of a system of ducts and sacs within the bony labyrinth. The fluid inside the membranous labyrinth is called endolymph. There are no ducts or open connections between perilymph and endolymph. The membranous labyrinth consists of the endolymphatic duct and sac, the saccule, the utricle, the semicircular ducts, which are jointly termed the vestibular system and are a key element in the balance mechanism, and the, and the cochlear duct, which is responsible for hearing (Figure 1.7). The perilymph is formed partly by filtration from the blood and partly by diffusion of cerebrospinal fluid. The endolymph is a filtrate of

perilymph, but its concentration of sodium and potassium is different. The major cation in the perilymph is sodium (as in extracellular fluid), but the major cation in endolymph is potassium, which is vital for the functioning of the inner ear.



**Figure 1.7**

Membranous labyrinth

The inner ear consists of two functionally separate systems: the cochlea and the vestibular system.

#### The blood supply

The internal auditory artery, or labyrinthine artery, supplies the entire inner ear. It originates as a branch of either the anterior inferior cerebellar artery or the basilar artery. It divides into the vestibular artery, the vestibulocochlear artery, and the cochlear artery. The vestibular artery supplies the vestibular nerve and parts of the saccule, the utricle, and the semicircular ducts. The vestibulocochlear artery supplies the basal turn of the cochlea, as well as the saccule, the utricle, and the semicircular canals. The cochlear artery enters the modiolus and gives rise to the spiral arteries which supply the majority of the cochlea.

#### The vestibular system

The vestibular system provides information about head motion and orientation with respect to gravity. The balance mechanism of the vestibule consists of the otolith organs **the utricle and**

**sacculle.** Sensory hair cells are embedded within the membrane (macula) of each organ. Calcium carbonate crystals called otoconia are attached to both the medial wall of the sacculle and the floor of the utricle. The otoconia enable the vestibular system to detect tilts and movements of the head, because they respond primarily to linear acceleration forces such as gravity.

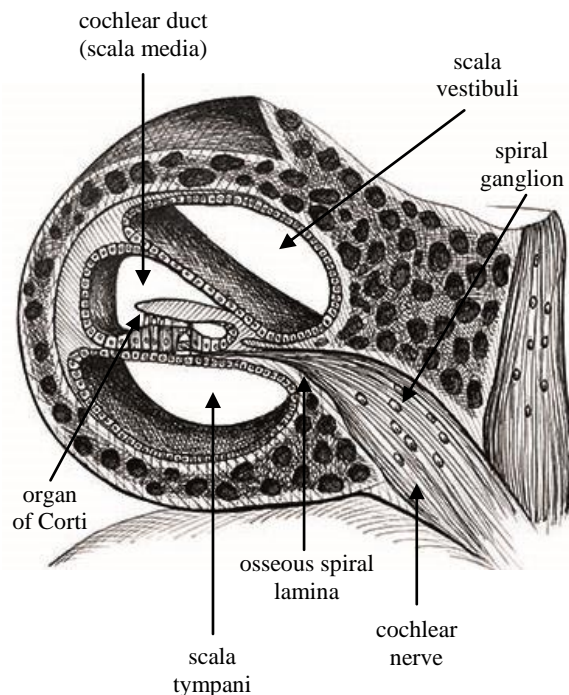
The angular accelerations are detected by three **semicircular canals**: the lateral, superior (anterior) and posterior. The canals are positioned at a 90° angle from one another, with the horizontal canal tipped backwards 20–30 degrees. Each canal includes the ampulla at one end, which contains the cupula: a gel-like bud. The cupula has sensory hair cells which detect the flow of endolymph within the semicircular canals. The semicircular canals detect angular accelerations by detecting the change in flow of endolymph while the head moves or rotates. The sensory signals are transmitted by the vestibular division of the VIIIth nerve, which unites in the internal auditory meatus with the cochlear division to form the vestibulocochlear nerve.

Connections between the vestibular centres, the centres of the ocular muscles, and the cervical musculature (together with the cerebellum) form the morphologic basis for the extremely precise coordination of the three functional systems. This allows the visual fixation of an object even during movement of the head. Control of the synchronised coordination of the ocular and cervical muscles is achieved through the vestibular apparatus via the gamma neurons.

### The cochlea

The bony cochlea is a hollow tube, in the form of a spiral, wound with two-and-a-half turns around a central axis named the modiolus through which pass the cochlear vessels and nerves. It is likened to a snail's shell. A bony shelf, called the osseous spiral lamina, projects from the central hub into the tube. The cochlear duct lies within and follows the spiral shape of the bony cochlear canal. It begins at the vestibule and ends at the apex of the cochlea. The cochlear duct is triangular in a cross-section. The floor of the duct is formed by the basilar membrane, attached to the spiral lamina medially and the spiral ligament laterally. The

lateral wall of the duct is lined by a stria vascularis and the third wall is made up of Reissner's membrane. Reissner's membrane and the basilar membrane divide the cochlea into three spaces: the scala media, the scala tympani and the scala vestibuli (Figure 1.8). The scala media contains endolymph and is linked to the sacculle. The scala tympani and vestibuli contain perilymph and communicate with one another at the apex of the cochlea through an opening called the helicotrema. The scala tympani is connected to the cerebrospinal fluid (CSF) of the subarachnoid space by the cochlear aqueduct. The endolymphatic system of the cochlea (scala media) is connected to the sacculle by the ductus reuniens and, from there, connects to the endolymphatic sac, which lies in a bony niche within the cranium. The endolymph of the utricle and semicircular canals also connects to the endolymphatic sac.

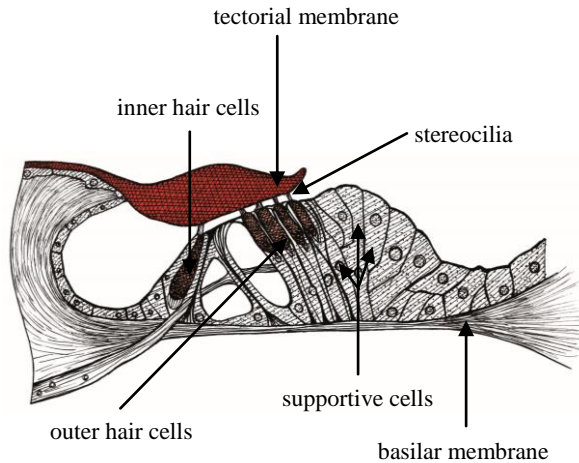


**Figure 1.8**

Cross-section through the cochlea

The sense organ responsive to acoustic energy is located on the basilar membrane and is called **the organ of Corti** (Figure 1.9).





**Figure 1.9**  
Organ of Corti

#### Anatomy of the organ of Corti

The organ of Corti consists of the sensory cells and supporting cells. The sensory cells are called hair cells. The inner hair cells (IHCs) are aligned in a single row, while the outer hair cells (OHCs) are aligned in three rows. There are approximately 3500 inner hair cells and 12,000 outer hair cells. Hair cells are separated by supporting cells called Deiters cells. The IHCs and OHCs differ from one another in a number of important respects. IHCs are pear-shaped and contain a centrally located nucleus, whereas OHCs are cylindrically shaped with a nucleus near the base. The apical pole of the hair cell has several rows of stereocilia. These are arranged in a graduated fashion with the shortest stereocilia on the outer rows and the longest in the center. This gradation is thought to be an important anatomic feature of the organ of Corti as it allows superior tuning capability. The organ of Corti is covered by a gelatinous structure called the tectorial membrane.

The arrangement of the basilar membrane, the organ of Corti, and the tectorial membrane is such that a deflection of the basilar membrane (by transmitted sound waves) will result in a shearing movement between the hair cells and the tectorial membrane, resulting in lateral or medial deflection of the stereocilia. This bending movement of the stereocilia initiates the transduction of acoustic energy into neural signals. Each region of the cochlea is associated with a specific frequency range. The low frequencies are represented towards the apex of the cochlea and the high frequencies towards the base.

#### Ascending auditory nervous system

The cell bodies of the bipolar, spiral ganglion neurons are located within the osseous spiral lamina. The peripheral axon projects to the hair cells of the organ of Corti, while the central process passes through the internal auditory meatus, forming the acoustic division of the eighth cranial nerve. It runs through the same internal auditory meatus and unites with the vestibular division. The nerve enters the lateral aspect of the brainstem at the pontomedullary junction, where it bifurcates into ascending and descending divisions and terminates in the cochlear nuclei in the caudal pons. From the cochlear nuclei, projections are made to the superior olivary complex in the pons, bilaterally, and to the contralateral inferior colliculus via the lateral lemniscus. From the inferior colliculus, ascending fibres pass to the medial geniculate body, from which the fibres pass to the primary auditory cortex, located in the superior temporal gyrus (Heschel's gyrus) of the temporal lobe.

#### 1.1.4 The mechanism of hearing

The sound is produced by the vibration of molecules within the air in the form of pressure waves. Ultimately, the ear converts these pressure waves into neural action potentials, which are perceived by the brain as hearing.

Sound is collected and transmitted to the tympanic membrane by the external ear. The folds and ridges of the pinna help to direct the sound towards the ear canal. The shape of the pinna also helps to determine the direction of the sound to some extent. Sound waves then enter the external auditory canal and are directed towards the tympanic membrane. The pinna and the ear canal not only direct the sound to the tympanic membrane, but also amplify the sound to some extent. The amplification by the pinna and ear canal is maximum at 3000 Hz (around 20 dB).

The sound waves cause the tympanic membrane to vibrate and this, in turn, causes the ossicles, namely the malleus, incus and stapes to vibrate. The middle ear thus conducts the sound vibrations from the tympanic membrane to the footplate of the stapes, and finally into the fluids of the inner ear. The middle ear also amplifies the sound, which is due to two main factors:

- Area ratio between the tympanic membrane and the stapes footplate. The surface area of

the tympanic membrane is 17 times larger than the surface area of the stapes footplate; thus, the vibrations of the eardrum are amplified by 17 times when it gets concentrated on the footplate.

- Lever action of the ossicles – amplifies the sound by 1.2 times.

The total amplification by the middle ear is thus 21 times. This amplification of sound energy is required since much of the sound energy is lost while it is transferred from the air-containing middle ear to the fluid-containing inner ear. The amount of sound energy lost is almost identical to the amplification achieved by the middle ear, which is called **impedance matching**.

The stapes footplate overlies the oval window, and its movement sets up a pressure wave in the perilymph of the scala vestibuli. The scala vestibuli communicates with the scala tympani in the apical part called helicotrema and, therefore, the wave travels along the length of these channels and ends at the round window. Movement in the perilymph causes vibration of the basilar and tectorial membranes of the organ of Corti. The organ of Corti rests on the basilar membrane in the whole length of the cochlea, and contains the hair cells. The vibration causes deflection of the stereocilia of hair cells opening potassium channels, which enter the hair cells from the surrounding endolymph, producing neural impulses. When these impulses reach the auditory centre of the cortex, through the auditory pathway, sound is perceived.

A different frequency of sound vibrates different areas of the cochlea, and this makes the cochlea frequency-specific. The low frequencies are represented towards the apex of the cochlea and the high frequencies are represented towards the base.

The entire frequency spectrum of 18 to 20,000 Hz is represented in the hair cells of the organ of Corti over the entire basilar membrane. High frequencies stimulate the basal turn, while low frequencies are detected at the cochlear apex.

### 1.1.5 Physiology of the balance system

The vestibular system is the sensory apparatus of the inner ear that helps the body to maintain its postural equilibrium. The information furnished by the vestibular system is also essential for coordinating the position of the head and the movement of the eyes. The balance is maintained by the interactions between the labyrinth and other systems in the body, such as the visual and skeletal systems. The main inputs into the balance system are the vestibular labyrinths, visual system (eyes), and somatosensory system, especially proprioception. The main outputs from the vestibular nuclei are vestibulo-ocular (permitting reflex eye movements related to posture) and vestibulo-spinal (anti-gravity muscles in the lower limb, reflex arcs which control gait).

The three semicircular canals of the labyrinth are associated with sensing rotatory motion (angular acceleration), and the utricle and saccule respond to changes in the position of the head with respect to gravity (linear acceleration).

Because the three semicircular canals – superior, posterior, and horizontal – are positioned at right angles to one another, they are able to detect movements in three dimensions. When the head begins to rotate in any direction, the inertia of the endolymph causes it to lag behind, exerting pressure that deflects the cupula in the opposite direction. This deflection stimulates the hair cells by bending their stereocilia in the opposite direction. The gravity receptors that respond to linear acceleration of the head are the maculae of the utricle and saccule. The left and right utricular maculae are in the same, approximately horizontal, plane; because of this position, they are more useful in providing information about the position of the head and its side-to-side tilts when a person is in an upright position. The saccular maculae are in parallel vertical planes and probably respond more to forward and backward tilts of the head. Shearing forces occur during linear acceleration. These shift the otoliths from their base, causing shearing of the hair cells and producing a neural impulse.

The relation between the vestibular apparatus of the two ears is reciprocal. When the head is turned to the left, the discharge from the left horizontal canal is decreased, and vice versa. Normal posture is the result of their acting in cooperation and in opposition. When the vestibular system of one ear is damaged, the unrestrained activity of the other causes a continuous false sense of turning (vertigo) and rhythmical, jerky movements of the eyes (nystagmus), both towards the uninjured side.

## 1.2 EVALUATION

### History

Patients should be questioned about symptoms of pain, hearing loss, ear discharge, tinnitus, aural fullness or pressure and disequilibrium. Further questions are directed towards formulation of a differential diagnosis based on the patient's response. Especially with the symptom of hearing loss, family history can provide insight into the diagnosis.

### Inspection

When examining the external ear, one should look at the size, shape, and position of the auricle, as well as for redness, swelling, ulceration, the presence of surgical scars, and congenital abnormalities such as accessory auricles, skin tags or pre-auricular sinuses. In the external auditory canal we should look for cerumen, foreign bodies, and any exudates.

### Palpation

The mastoid process, auricle and regional lymph nodes should be palpated while looking for swelling or sensitivity to pressure.

### Otoscopy (otomicroscopy)

Otoscopy is the visual examination of the auditory canal and the eardrum. The external auditory canal should be straightened by gently pulling the pinna upwards, outwards and backwards. A light source,

otoscope or microscope can be used. The largest speculum that will fit into the ear canal should be used and must be introduced gently. If cerumen is present it needs to be removed. During otoscopy, we focus on the auditory canal and the entire tympanic membrane (Figure 1.10). The pars tensa of the tympanic membrane is normally greyish-yellow; we can see three basic structures: the handle of malleus (stria mallearis), the lateral process of the malleus (prominentia mallearis), and the light reflex in the anterior inferior part of the membrane. It is important to pay particular attention to the strip at the top of the eardrum (called pars flaccida), since it is in this area that cholesteatomas are first seen. Some pathological findings of the tympanic membrane are injection of the vessels, haemorrhage, retraction as a result of decreased pressure in the middle ear, bulging, thickening, scars or perforation of the tympanic membrane.



**Figure 1.10**

Otoscopy

### Imaging

The imaging of the middle ear is based upon computed tomography (CT) and magnetic resonance imaging (MRI). In trauma, CT demonstrates the fracture, lesions of the ossicles, and lesions of the windows. For all of the potential tumours of the middle ear, CT and MRI have to be performed. A study in an axial plane should always be accompanied by coronal sections. MRI is becoming more and more useful for evaluating the middle ear. It can give information in

postoperative patients considering a possible recurrent cholesteatoma. MRI is also used in pathologies involving both middle and inner ears, such as some cholesteatomas and traumatic lesions, particularly with fistulas and malformation and in all kinds of tumours in the tympanic cavity.

### Tests of hearing

Auditory symptoms include hearing loss, tinnitus, and aural fullness, while balance disturbances can range from light headedness and gait disorder to true, rotational vertigo. Auditory problems can arise in the external, middle or inner ear, the auditory brainstem or the central auditory pathways. Vestibular dysfunction can develop from pathology in the peripheral or central vestibular system, the visual system, or the somatosensory system.

*Simple test of hearing.* Hearing can be examined without special equipment; these tests are known as free field tests. The patient is asked to repeat words given by an examiner. It must be done without giving the patient any visual clues, and the non-tested ear should be prevented from hearing. Most people with normal hearing should be able to hear a whisper at a distance of a few metres. At 60 cm, a whisper is about 12 dB, a softly spoken voice about 48 dB, and shouting about 76 dB.

*Tuning forks.* These tests are used to assess the patient's hearing. Usually a tuning fork with a frequency of 512 Hz is used. The test demands a good technique and a basic understanding of air and bone conduction. The value of these tests lies in determining whether hearing loss is a conductive or sensorineural type. The tests most commonly employed are the Rinne and Weber tests (Figure 1.11).



**Figure 1.11**  
Tuning fork

Rinne's test compares hearing in each ear through air and bone conduction. Normally we hear with air conduction, which is more efficient than hearing through the bone. The tuning fork is activated and held next to the ear for a few seconds and then placed behind the ear on the mastoid process. The patient is asked which sounds louder. In a healthy individual or in a patient with sensorineural hearing loss, Rinne's test is positive; the air conduction (front of the ear) is better than bone conduction. The Rinne test is said to be negative when the fork sounds louder behind the ear, and bone conduction is better than air conduction; this is typical in conductive hearing loss.

In Weber's test the tuning fork is struck and placed in the midline, usually the vertex, forehead or bridge of the nose. The principle is the binaural comparison of bone conduction. The patient is asked where he or she can hear the sound better. In a normal hearing patient or bilateral or symmetrical hearing loss of either type, the sound is perceived in the midline. The patient with unilateral conductive hearing loss localises the tone in the affected (worse hearing) ear. On the other hand, the patient with unilateral sensorineural hearing loss localises the tone in the healthy (better hearing) ear.

Schwabach's test compares the bone conduction of the patient with the examiner.

Gelle's test. A vibrating tuning fork is applied to the mastoid process, and the air in the external auditory canal is compressed by a Politzer balloon. The excess pressure is fixing the stapes in the oval window and the sound is reduced, but is again perceived if the air pressure is removed (positive). It is a test of the mobility of the ossicles. In fixation of the footplate due to otosclerosis the loudness does not change (negative).

### Impedance audiometry

Impedance audiometry is an investigation of the sound conduction apparatus. It includes the following methods: tympanometry, measurement of the stapedius reflex, acoustic decay reflex, and Eustachian tube function. Impedance audiometry

is a measurement of energy or air pressure which involves the external auditory canal, eardrum, ossicular chain, stapedius muscle, cochlea, facial nerve, vestibulocochlear nerve, and the brain stem.

**Tympanometry**

Tympanometry is used to test the conditions in the middle ear, the mobility of the tympanic membrane, and the ossicles (Figure 1.12).

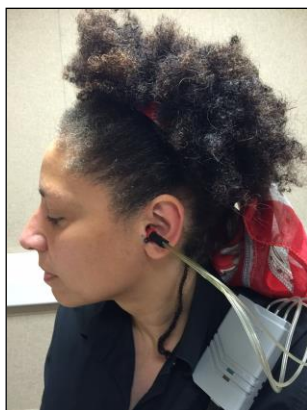
The test is performed using a probe tube which creates a varying pressure in the ear canal while emitting a sound and measuring the amount of sound reflected back to the probe. The probe is inserted into the external auditory canal until an airtight seal is obtained. Positive and negative pressures are introduced into the external ear canal and the compliance is measured. The changes of compliance as a function of variations of air pressure are plotted on a graph, called a tympanogram.



**Figure 1.12a**  
Tympanometer



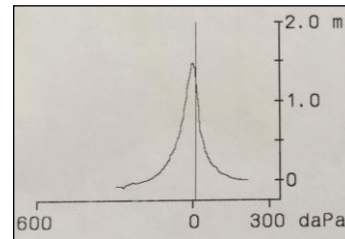
**Figure 1.12b**  
Patient interface



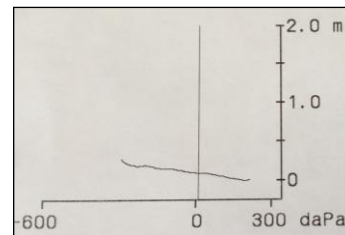
**Figure 1.12c**  
Placement in the ear canal

Tympanometry measures the mobility of the tympanic membrane as air pressure is varied in the ear canal.

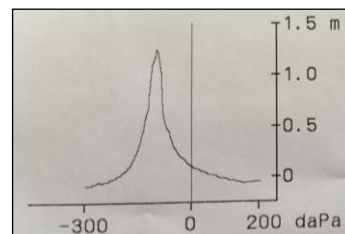
**Tympanogram.** A type A tympanogram suggests normal middle ear function in which the peak is centred around 0 daPa of air pressure. Type As (low peak) suggests ossicular fixation (e.g. otosclerosis), while type Ad suggests ossicular discontinuity (Figure 1.13).



**Figure 1.13a**  
Tympanogram curves – Type A



**Figure 1.13b**  
Tympanogram curves – Type B



**Figure 1.13c**  
Tympanogram curves – Type C

A type B tympanogram is a flat trace with no observed peak regardless of the air pressure



introduced into the external air canal. Decreased mobility indicates fluid in the middle ear as in otitis media with effusion.

A type C tympanogram peaks when air pressure reaches -200 daPa or lower. It suggests significant negative pressure in the middle ear system and may suggest developing or resolving otitis media. Additionally, this type indicates a malfunctioning Eustachian tube.

The stapedius reflex occurs when the stapedius muscle contracts in response to a sound stimulus greater than 70 dB above the hearing threshold. The contraction occurs bilaterally, even if only one ear is stimulated. In the case of conductive hearing loss, reflexes are abnormally elevated or absent. A stapedial muscle contraction in response to an intense signal occurs bilaterally in normal ears with either unilateral or bilateral stimulation. If reflexes are present, sensorineural hearing loss is probably no worse than moderate in degree, and the ipsilateral acoustic reflex pathway is largely intact. Stapedius reflexes are generally absent or cannot be recorded in the presence of type B tympanograms.

### Pure tone audiometry

Pure tone audiometry is a hearing test used to determine the presence or absence of hearing loss. The primary purpose of pure tone tests is to determine the type, degree, and configuration of hearing loss. An **audiometer** is an electric tone generator used to determine the hearing threshold for pure tones. **The tone** is a pure sinusoidal vibration in the audible range characterised by **frequency**, which is a vibration per second in Hertz. The pure tone audiogram provides an estimate of hearing sensitivity. This measure involves the peripheral and central auditory systems. Hearing sensitivity is plotted on an audiogram, which is a graph displaying intensity as a function of frequency.

### Pure tone audiometry

A pure tone **air conduction** hearing test determines the faintest tones that a person can hear at selected frequencies, from low to high. During this test, headphones are placed over the outer ear, so that information can be obtained for each ear. The signal is transmitted through the outer, middle, and inner ear and then through the brain to the cortex.

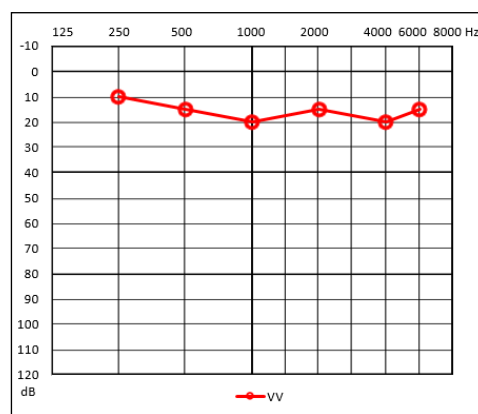
**Bone conduction** is performed by sending a tone through a small vibrator placed behind the ear. The signal is transmitted through the bones of the skull to the cochlea and then through the auditory pathways of the brain. It stimulates the bones of the skull, which, in turn, stimulates both cochleae. This type of testing bypasses the outer and middle ear. In these cases, this test helps the audiologist to determine the type of hearing loss being measured.

**Masking** presents a constant noise to the ear which is currently not being tested to prevent crossover from the ear being tested.

**The degree of hearing loss** refers to the severity of the loss (Table 1.1). Hearing loss is measured in decibels (dB). The softest sounds are made at zero dB, and the loudest are around 120 dB. The amount of hearing loss someone has is ranked as mild, moderate, severe or profound.

**Table 1.1** Degree of hearing loss

Hearing loss	Range of hearing loss
Normal hearing	Up to 20 dB
Mild	In the better ear between 25 and 39 dB
Moderate	40 to 69 dB
Severe	70 to 89 dB
Profound	More than 90 dB



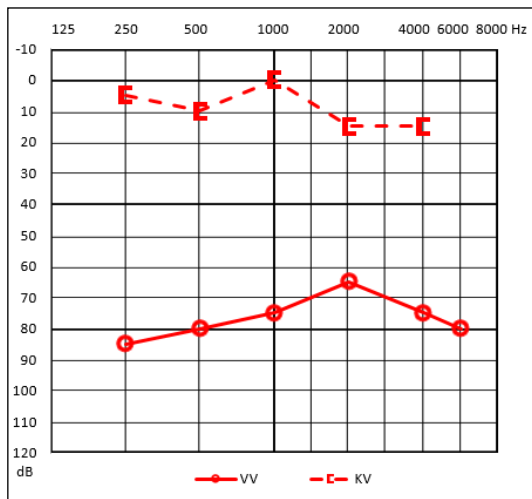
**Figure 1.14**

Pure tone audiogram – normal hearing

To determine **the type of hearing loss**, thresholds for air and bone conduction are compared. If air and bone conduction thresholds agree within 10

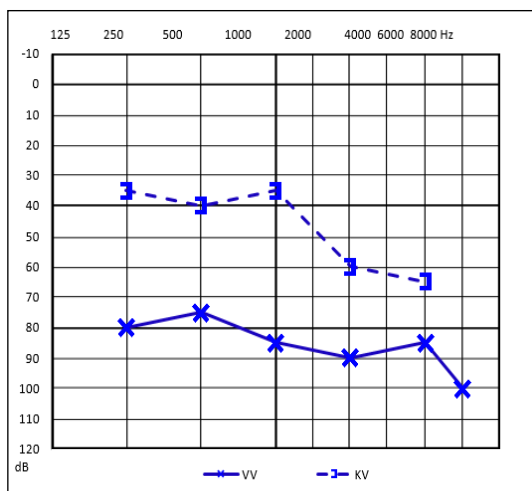
dB and are within the normal hearing range, the individual has **normal hearing** (Figure 1.14). There are three basic types of hearing loss: conductive, sensorineural, and mixed.

If air and bone conduction thresholds agree within 10 dB but are poorer than 20 dB HL, the hearing loss is **sensorineural**. Sensorineural hearing loss happens when there is damage or deterioration of the inner ear (cochlea) or to the nerve pathways from the inner ear to the brain.



**Figure 1.15**

Pure tone audiogram – conductive hearing loss



**Figure 1.16**

Pure tone audiogram – mixed hearing loss

If air conduction thresholds are poorer than the bone conduction thresholds by 15 dB or more and bone conduction thresholds are within normal limits, the hearing loss is **conductive** (Figure 1.15). Conductive hearing loss occurs when there is a defect in the outer ear, tympanic membrane or the ossicles, and the sound is not conducted well to the inner ear.

If air conduction thresholds are poorer than bone conduction thresholds by 15 dB or more and bone conduction thresholds are poorer than 20 dB, the hearing loss is **mixed** (Figure 1.16).

**Bilateral** hearing loss means hearing loss in both ears. **Unilateral** hearing loss means that hearing is normal in one ear but there is hearing loss in the other ear. The hearing loss can range from mild to very severe.

**Symmetrical** means that the degree and configuration of hearing loss are the same in each ear. **Asymmetrical** means that the degree and configuration are different in each ear.

**Progressive hearing loss** means that hearing loss becomes worse over time. **Sudden hearing loss** means that the loss happens quickly. Such a hearing loss requires immediate medical attention to determine its cause and treatment.

**Fluctuating hearing loss** means hearing loss that changes over time — sometimes getting better, sometimes getting worse. **Stable hearing loss** does not change over time and remains the same.

**Free field testing**

Sound field (free field) testing signals are presented via speakers. This form of testing is used with infants, toddlers, and other individuals with special needs for whom earphone use may be problematic. During sound field testing, an individual sits in the centre of the room, facing forward, halfway between each speaker. Typically, visual reinforcement audiometry (toys light and animate when the child responds to sound), conditioned orientation response audiometry (toys on both sides test localisation) or play audiometry (various games, e.g. dropping a block in response to sound) is used.

**Visual reinforcement audiometry (VRA)**

This is a screening method used in children between 6 months and 2 years of age. The child is trained to look towards a sound source. When the child gives a correct response (the child looks to a

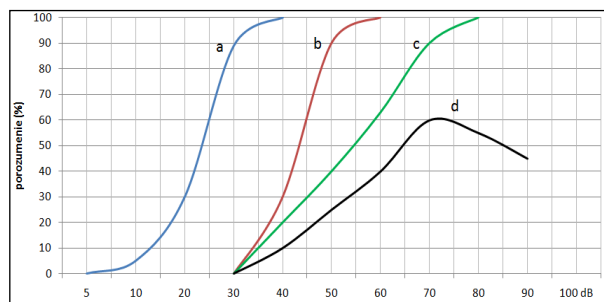
source of sound when it is presented), the child is "rewarded" through a visual reinforcement. Example rewards include getting to watch a toy that moves or a flashing light.

### Conditioned play audiometry

This can be used as the child matures and is commonly used with toddlers and preschoolers (ages 2–5). The child is trained to perform an activity each time a sound is heard. The activity may involve putting a block in a box, placing pegs in a hole, or putting a ring on a cone.

### Speech audiometry

Speech audiometry measures the individual's ability to communicate. In Slovakia, speech audiometry is carried out using uniform test material consisting of monosyllabic and multisyllabic words. Determination of the percentage of hearing loss for speech comprehension is achieved by ascertaining the total word comprehension, and determination of the hearing loss for speech is assessed from the speech audiogram (Figure 1.17).



**Figure 1.17**

Speech audiogram – normal (a),  
conductive loss (b), sensorineural loss (c),  
retrocochlear pathology (d)

The ability to hear and understand speech is more important in human communication than the ability to hear pure tones. Speech audiometry in conjunction with pure tone audiometry can aid in determining the degree and type of hearing loss.

### Auditory brainstem response

The electrical activity evoked in the auditory nerve and brainstem pathways is known collectively as the auditory brainstem response (ABR), or brainstem auditory evoked potential (BAEP), or brainstem auditory evoked response (BAER), or brainstem evoked response audiometry (BERA). The patient is exposed to an acoustic stimulus repeatedly and an electroencephalogram (EEG) is used to assess whether there is any change in brain activity. The elicited waveform response is measured by surface electrodes typically placed at the vertex of the scalp and on each mastoid or earlobe. The test can be performed with the patient under natural sleep, sedation or general anaesthesia.

#### ABR waveform

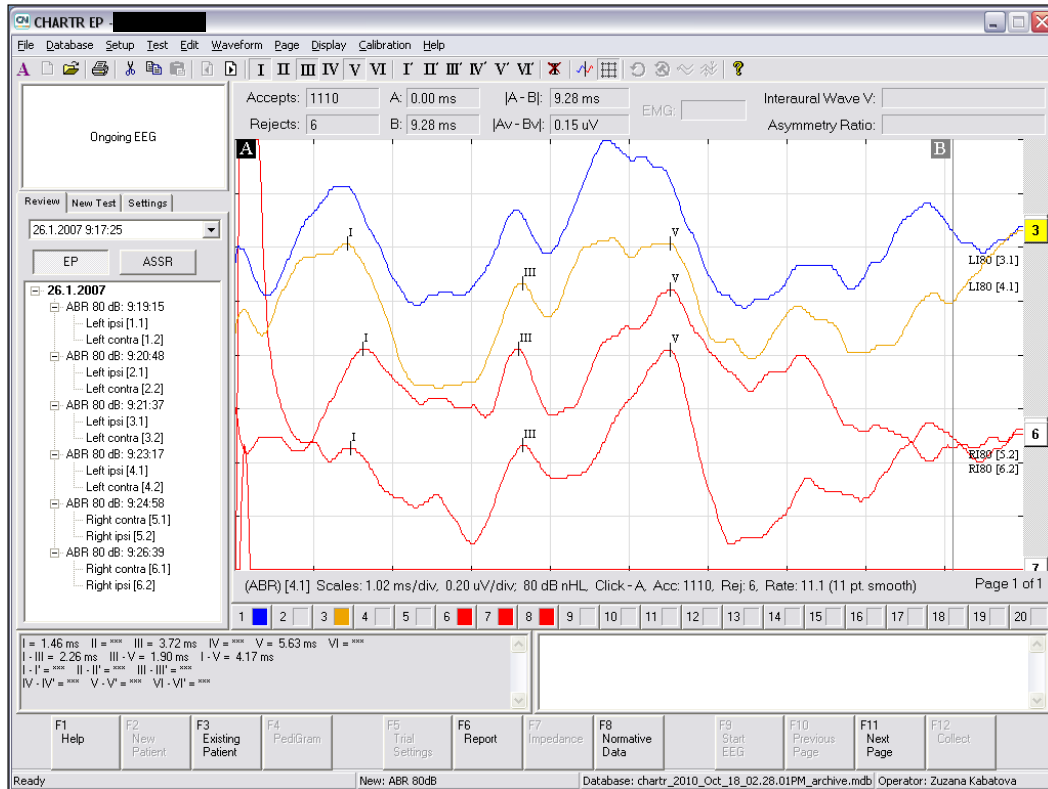
The ABR comprises seven waves, of which waves I, III and V are the most visible and of more significant clinical value. The currently used classification for the generating site of these waves is:

- I – distal portion of the auditory nerve relative to the brainstem (action potential of the auditory nerve);
  - II – proximal portion of the auditory nerve relative to the brainstem;
  - III – cochlear nucleus;
  - IV – superior olivary complex;
  - V – lateral lemniscus;
  - VI – inferior colliculus;
  - VII – medial geniculate body
- (Figure 1.18)

ABR is useful in the differential diagnosis of many auditory disease processes. It is used to assess hearing sensitivity in infants, and it can predict a degree of hearing loss. Although the ABR provides information regarding auditory function and hearing sensitivity, it is not a substitute for a formal hearing evaluation, and results should be used in conjunction with behavioural audiometry whenever possible.

#### Auditory steady state response

Auditory steady state response (ASSR) is an objective test of hearing sensitivity used for children too young for traditional audiometric testing. The test is similar to ABR; however, the hearing threshold obtained here is frequency-specific. Different frequencies can be measured, which is not possible in ABR.



**Figure 1.18**  
The ABR waveform

### Otoacoustic emissions

Otoacoustic emissions (OAEs) are a simple, highly sensitive, relatively inexpensive, non-invasive and reliable audiological diagnostic method. OAEs can be recorded in the ear canals in normal hearing individuals but are absent in the ear canal of individuals with significant hearing loss. OAEs are sounds generated in the cochlea that are transmitted through the middle ear into the external ear canal. By placing a small probe with a sensitive microphone into the external ear canal, this low-intensity energy can be elicited and recorded.

OAEs are generated within the cochlear, with outer hair cells (OHCs) playing an integral role. A cut-off level for hearing loss exists, above which an OAE will not be detectable. OAEs are absent in cases of sensorineural hearing loss >30 dB HL. The most common use of OAEs is in screening

programmes in the testing of neonates with possible hearing loss. OAE results should always be interpreted in the light of other results from the chosen test battery. It is advantageous to obtain tympanometric data prior to OAE testing. When middle ear function is compromised the value of even attempting OAE testing is debatable.

The biggest advantage of using otoacoustic emissions in clinical practice is that they can be easily detected, noninvasive and quickly measured in the external ear canal. Such measurement provides noninvasive insight into the function of outer hair cells, which are the most sensitive part of the cochlea. Absent OAEs raises the suspicion of hearing loss. Other audiological tests are required to determine the nature and extent of any possible loss.

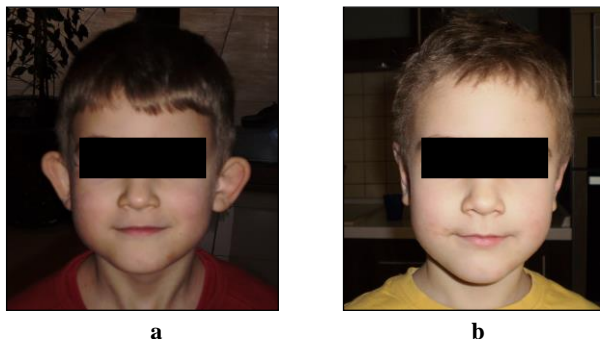### Neonatal hearing screening

Universal neonatal hearing screening has the potential to reduce the age at confirmation of congenital impairments. The sense of hearing is a vitally important factor in the acquisition of speech. It is therefore essential that hearing loss in a child be recognised and treated. The earlier the treatment is instituted, the more successful it is. Nowadays, universal newborn hearing screening programmes are adopted on a nationwide basis in most countries of the developed world. It is common practice to perform the neonatal hearing screening test before the neonate is discharged home. OAEs are used to screen neonates, and those who fail the test need further evaluation with ABR or ASSR.

## 1.3 DISEASES OF THE EXTERNAL EAR

### 1.3.1 Congenital anomalies of the external ear

*Definition.* Congenital anomalies are the product of errors in embryogenesis or the result of intrauterine events that affect embryonic and foetal growth. The formation of the ear involves fusion of ectoderm, endoderm, and mesoderm. Defects in formation may lead to a wide variety of dysfunctional or malformed structures.



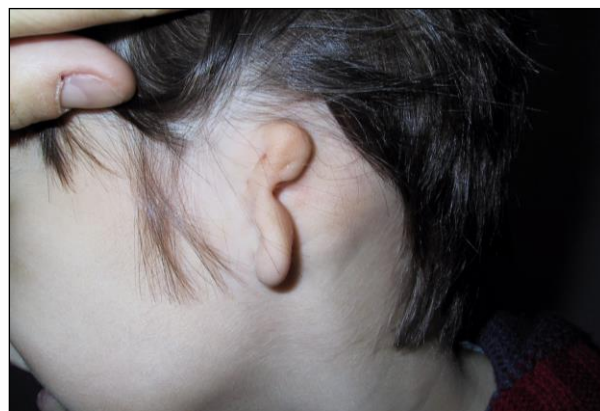**Figure 1.19**

Apostasis auriculae before surgery (a), after surgery (b)

**Bat ear or prominent ear (apostasies, auriculae, otopostosis)** is one of the most common anomalies. It is caused by failure of the normal formation of the folds of the auricle. The treatment is surgical correction (Figure 1.19).

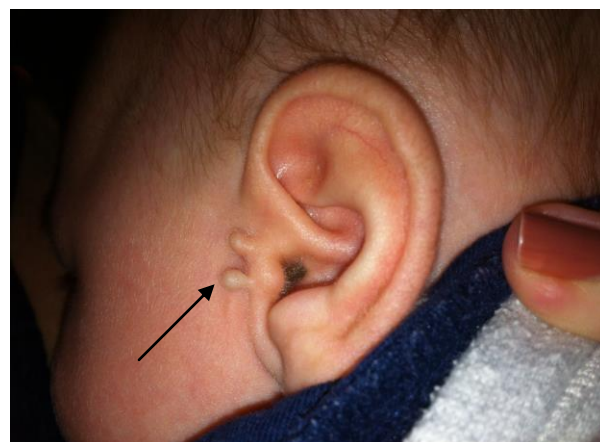**Macrotia** is a large but normally formed auricle not usually associated with functional abnormality. It is defined as an ear which is two or more standard deviations from the mean.

**Microtia** is a small and deformed auricle. Over 90% of the time, microtia is unilateral. Boys are affected more than girls, and in unilateral microtia, the right side is affected more than the left (Figure 1.20).



**Figure 1.20**

Microtia and atresia of the external auditory canal



**Figure 1.21**

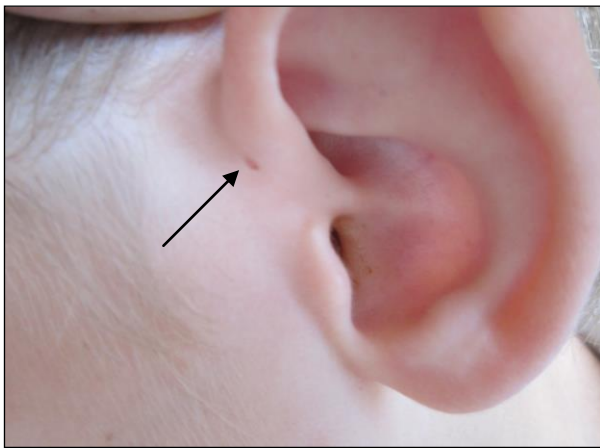
Preauricular appendix



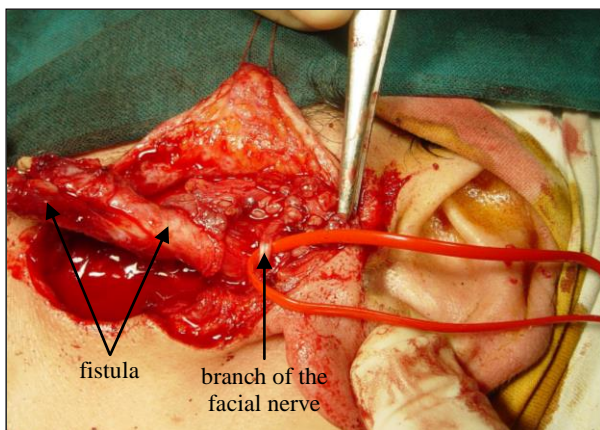
Based on severity of the deformity, there are three grades of *microtia*:

- Grade I: a pinna with all anatomic subunits present but abnormally shaped
- Grade II: a pinna with some recognisable subunits but are rudimentary and malformed
- Grade III: a severely deformed ear, with an inferior fibro-adipose lobule and a nubbin of cartilage in the superior remnant

**Anotia** is the total absence of the auricle, most often with narrowing or the absence of the external auditory meatus.



**Figure 1.22a**  
Preauricular fistula ostium



**Figure 1.22b**  
Perioperative picture – fistula leading under the branch of facial nerve

**Congenital auricular appendages** and **aural fistulae** are usually found anterior to the auricle. They are due to incomplete closure of the first branchial groove or an incomplete fusion of auricular hillocks. The appendages range from simple skin tags to complex structures containing cartilage (Figure 1.21, Figure 1.22). In case aural fistulae cause symptoms due to infection, they can be surgically excised, remembering the danger of damage to the facial nerve or parotid gland.

### **Congenital atresia of the external auditory canal**

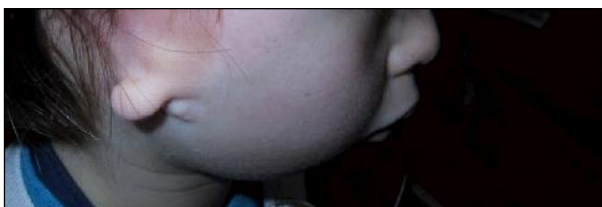**Definition.** This is complete closure of the external auditory canal, which is caused by a failure of canalisation of the epithelial plug portion of the first branchial cleft. The atresia is bony in most cases, and less often membranous. It can be unilateral or bilateral. The atresia of the external auditory canal is often associated with malformation of the auricle.

**Clinical features.** Anomalies of the external ear are often associated with malformation of the middle and/or inner ear. Ossicular malformations may be seen as they arise from the first branchial cartilage. On the other hand, atresia or aplasia of the external auditory canal may occur as an isolated malformation. Failure of the EAC to canalise means that sound cannot reach the tympanic membrane, resulting in conductive hearing loss. The combination of atresia and ossicular malformations may result in more severe conductive hearing loss. In addition, 11–47% of patients also have sensorineural hearing loss in the affected ear.

**Diagnosis** is usually made at birth, when a malformed auricle or atretic canal is noticed in a newborn. An audiological assessment is carried out to rule out hearing impairment in the infant. Imaging of the temporal bone is necessary for accurate diagnosis and in decision making in therapy. CT scanning of the temporal bones in axial and coronal direct sections obtained in thin 1mm cuts is required. Usually patients with unilateral atresia do not require surgery.

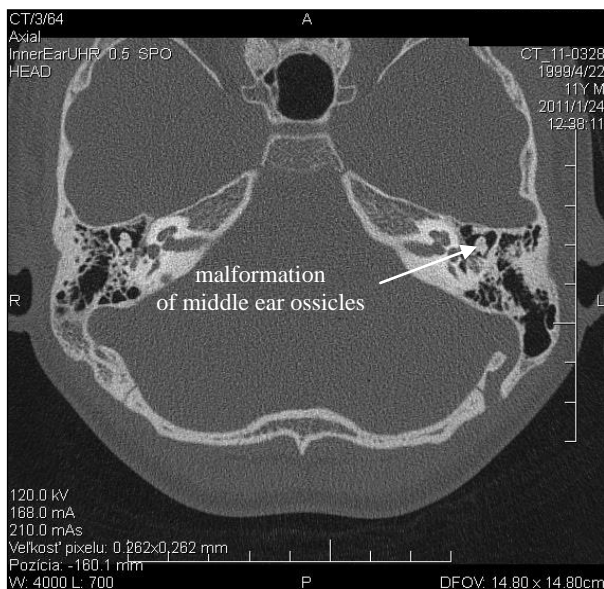
**Treatment.** Bilateral atresia usually requires surgery to restore hearing. Surgical intervention on the first ear generally occurs around age 4–5

years. Hearing tests and early placement of hearing aids are very important, and the evoked potential testing should be performed as soon as feasible, attempting to place hearing aids by age 6 months at the latest. In patients with bilateral abnormalities, a bone anchored hearing aid (BAHA) is the first line of treatment. In very young children there is a possibility of the BAHA soft-band. Another possibility is the use of a fully implantable hearing aid, which potentially aids patients who have a malformation of the middle ear. The floating mass transducer is a surgically implantable device on the round window and has been shown to augment the air-bone gap (see Chapter 9.4).



**Figure 1.23a**

Child with congenital anomaly of the external and middle ear



**Figure 1.23b**

Child with congenital anomaly of the external and middle ear;  
CT scan, axial plane

**Congenital stenosis of the external auditory canal** is characterised by narrowing of the ear canal. This can also be associated with external and middle ear malformations. Patients with auditory canal stenosis are at high risk for ear canal cholesteatoma formation.

Malformations of the auricle and meatal stenosis or atresia are often combined and may be associated with anomalies of the middle and internal ear. They may form part of many chromosomal anomalies and syndromes (Treacher Collins, Goldenhar, Klippel–Feil, Branchio-Oto-Renal (Figure 1.23)). All children with microtia or congenital atresia must be referred for audiological assessment.

### 1.3.2 Inflammation of the external ear

Inflammation of the external ear can be acute or chronic; it can affect the auricle, external auditory canal or epithelial layer of the tympanic membrane. The skin and cartilage are subject to the same insults as elsewhere in the body, so many diseases (e.g. atopic dermatitis, psoriasis, herpes zoster, perichondritis) are discussed in greater detail in other books. The most common in clinical practice is the inflammation of the external auditory canal.

#### Acute otitis externa – localised

**Definition.** It is an infection of the hair follicles, most often caused by *Staphylococcus aureus*, which may progress to form an abscess or *furuncle*.

**Clinical features.** Severe pain in the ear elicited by moving or putting pressure on the auricle is characteristic. Physical examination is often difficult because of swelling and pain on pressure or traction on the auricle.

**Treatment.** Topical antibiotics or local anti-inflammatory drugs can be used. A localised abscess should be treated by incision and drainage and oral or local antibiotics.

#### Acute otitis externa – diffuse

**Definition.** Otitis externa or “Swimmer’s ear” is a bacterial infection of the external ear canal, with an incidence of 4/1000 children and adults per year; 80% of cases occur in summer.

**Aetiology.** It is caused by an abrogation of the protective lipid film of the external canal, which exposes the epithelium to water and other

contaminants. The predisposing factors include heat, humidity, frequent swimming, anatomic obstruction of the ear canal (stenosis, exostosis, impacted cerumen), hearing aids, ear plugs, foreign bodies, and middle ear discharge. The infection usually begins with local trauma as a result of itching and skin maceration from scratching the canal with a cotton swab or fingernail. These violations of the epithelium allow bacteria to enter. The most commonly isolated organisms are *Pseudomonas aeruginosa*, *Proteus mirabilis* and *S. aureus*. The resulting inflammatory process leads to progressive erythema and oedema.

*Clinical features* include pain, itching, aural fullness, decreased hearing, and otorrhoea. A typical sign is pain elicited by tragal pressure or by pulling on the auricle. The lumen of the external auditory canal is narrowed by oedema and debris from the thickened and irritated skin. The examination of the ear canal can reveal different findings according to the stage of acute bacterial otitis externa; the erythematous canal in the case of an early stage of otitis externa; the oedematous canal filled with purulent debris; and a completely obstructed external ear canal because of increasing hyperaemia, oedema, and otorrhoea in the severe inflammatory stage.

*Diagnosis* is made by symptoms and local findings. A culture may be helpful for infections that are refractory to treatment.

*Treatment* involves the careful atraumatic cleaning of the external ear canal using a microscope, drying of the ear canal, frequent inspection, and control of pain. Ear canal cleaning is of paramount importance. Local medication such as acidification of the canal and antiseptics or antibiotics with steroid drops or creams, antifungal agents and ichthammol can be used. Oral or intravenous antibiotics should be reserved for complications of otitis externa (cellulitis, perichondritis, chondritis).

---

Chronic otitis externa is a diffuse infection and inflammation of the skin of the external ear canal that persists for months or years. It results in thickening the skin and narrowing of the lumen of the EAC.

---

### **Necrotising (malignant) otitis externa**

*Definition.* Malignant otitis externa is a very aggressive form of otitis externa, typically seen in elderly people and people with diabetes. It is a potentially lethal infection of the auditory canal, surrounding tissue and skull base.

*Aetiology.* The most common pathogen is *Pseudomonas aeruginosa*.

*Clinical features.* The infection spreads from EAC to bone, causing an osteitis or osteomyelitis of the skull base, followed by progressive replacement of compact bone with granulation tissue. Facial nerve paralysis and Cranial Nerves IX, X, XI palsies occur as the infection spreads across the skull base. Typical symptoms are severe otalgia, granulation tissue in the meatus, and facial nerve paralysis.

*Treatment.* There is a high mortality rate and the treatment must be prompt: hospitalisation, treatment of diabetes, use of high-dose intravenous antibiotics specific for *Pseudomonas*, and sometimes surgery (mastoidectomy, facial nerve decompression, subtotal petrosectomy, partial temporal bone resection).

### **Otomycosis**

*Definition and aetiology.* Fungal otitis externa is an inflammatory disease usually caused by *Candida sp.* in the case of a superficial infection in patients who use hearing aids or by *Aspergillus sp.*, which is a more aggressive infection and involves the epithelial and subcutaneous tissues.

*Clinical features.* The most common symptom is pruritus. In otomicroscopy, erythematous skin, hyphae and spores may be seen.

*Treatment* consists of frequent cleaning, drying, acidification, and antifungal cream or powder.

### **Inflammatory diseases of the auricle**

**Cellulitis.** *Definition.* Cellulitis of the auricle is a bacterial infection; it often follows an ear piercing or laceration.

*Clinical features.* Symptoms are pain with a red and swollen auricle.

*Treatment* consists of oral or intravenous antibiotic and wound care.



**Perichondritis.** *Definition.* Perichondritis or chondritis is an infection of the perichondrium or cartilage of the auricle.

*Aetiology.* It usually arises from improper treatment of cellulitis or otitis externa. The most common pathogen is *Pseudomonas sp.* Other causes are trauma, insect bites, ear piercing or systemic inflammatory conditions.

*Clinical features.* The affected ear is oedematous, and painful, with serous or purulent exudates and with possible involvement of surrounding tissue.

*Treatment* of choice is aural cleaning, local and oral antibiotics (fluoroquinolones) and, in severe cases, hospitalisation and intravenous antibiotics.

### **Bullous myringitis**

*Definition.* Bullous myringitis is a painful inflammation of the tympanic membrane. Although it is considered in the external ear section here, it can be also considered as a part of the middle ear as well, as the tympanic membrane is the borderline between the external and middle ears.

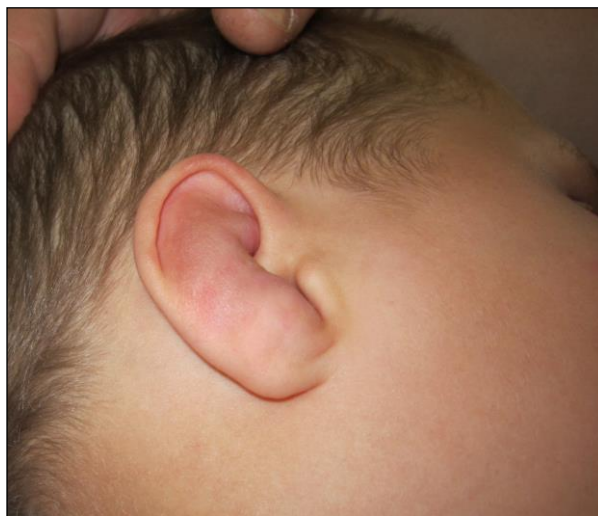*Clinical features.* It is characterised by a rapid onset, and examination shows different-sized, serum or blood-filled vesicles or bullae on the tympanic membrane. It was thought that viruses or mycoplasma were the most common pathogens, but recent studies have demonstrated that the pathogens are similar to otitis media.

*Treatment* requires strong analgesics because of the associated pain. Rupturing the bullae for relief of pain is controversial. Topical antibiotic eardrops may be useful in the prevention of development of a secondary bacterial otitis externa.

### 1.3.3 Trauma to the external ear

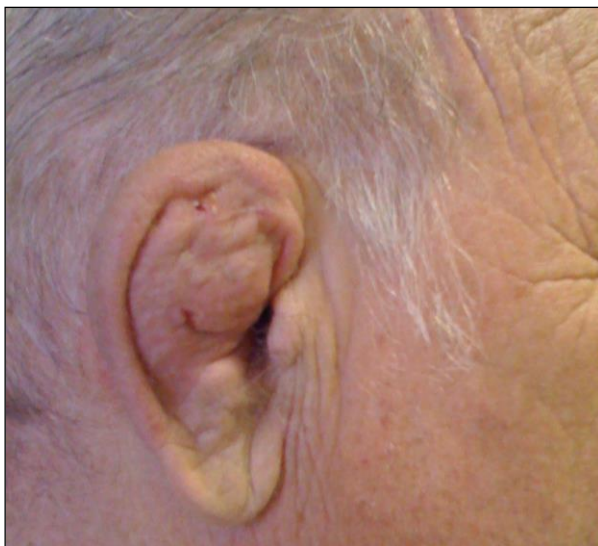The position of the auricle and its soft structure make it vulnerable to all kinds of trauma in all age groups. We can recognise different kinds of trauma, including a blunt or sharp injury, resulting in a haematoma or laceration, and a cold or hot thermal injury.

Every injury to the auricle and cartilaginous part of the external auditory canal may damage the perichondrium, causing necrosis of the cartilage. A patient with sharp and blunt auricular trauma requires stabilisation, extensive debridement, primary suture, and antibiotic treatment.



**Figure 1.24**

Auricular haematoma in child



**Figure 1.25**

Cauliflower ear

**Haematoma of the auricle** arises from direct blunt trauma to the external ear, leading to disruption of a perichondrial blood vessel, accumulation of blood in the subperichondrial space, and separation of the perichondrium from the cartilage (Figure 1.24). It happens commonly in sports injuries. Treatment is based on evacuation of the haematoma; the method of choice is adequate incision and drainage, followed by compression dressing and antibiotics. Delayed treatment of the haematoma may lead to fibrosis and necrosis of the cartilage and can cause a permanent deformity of the auricle: *cauliflower ear* (Figure 1.25). Bacterial infection can cause perichondritis with destruction of cartilage, also leading to a cauliflower ear or atresia of the EAC.

**Sharp trauma** can vary from a small laceration to partial or complete amputation of the auricle. Because of the very good blood supply of the external ear, even large parts of the auricle can be saved using appropriate surgical techniques.

The auricle is quite susceptible to **frostbite** because of its location. Exposure to very low temperatures causes a severe and prolonged vasoconstriction of the capillary walls, resulting in damage to these walls. The anaesthesia that takes place in those areas of the skin exposed to the cold allows a significant amount of damage to occur without the individual's knowledge. The ear becomes red, swollen and tender. It should be warmed with sterile dressings, and treated gently to avoid further damage to the devitalised tissue — antibiotics and analgesics should be used. Rewarming is usually successful; debridement of gangrenous tissue may be required.

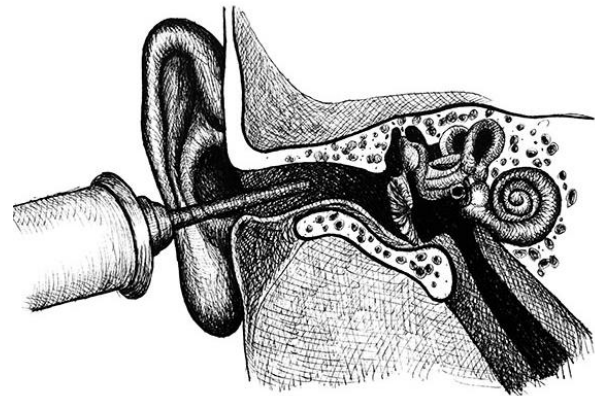
**Burns** are classified in three degrees according to severity: 1. erythema, 2. blistering, 3. full-thickness destruction. They require the same treatment as burns of the skin, and may lead to perichondritis if untreated.

### 1.3.4 Cerumen

Cerumen (earwax) is a mixture of viscous secretions from sebaceous glands and less viscous ones from modified apocrine sweat glands and is

produced in the outer third of the cartilaginous portion of the ear canal. The primary components of cerumen are desquamated layers of skin, with 60% of the cerumen consisting of keratin, 12–20% saturated and unsaturated long-chain fatty acids, alcohols, and squalene, and 6–9% cholesterol.

Accumulation of cerumen is the most common ear problem in the general population, which makes removal of cerumen from the ear a significant part of the workload of an otolaryngologist.



**Figure 1.26**

Ear canal syringing

#### Cleaning of the ear canal

Cerumen naturally moves outwards and clears itself. This process is helped by movement of the jaw during chewing and talking. Use of ear buds is counter-productive, removes only a small portion of cerumen, and may push most of the cerumen further into the ear canal.

The most common method of cerumen and foreign body removal is syringing with warm water (at body temperature). To straighten the external ear canal we have to pull the auricle superiorly and posteriorly. The stream of water is directed along the superior canal wall (Figure 1.26). Perforation of the tympanic membrane should be excluded by a careful history before syringing. If there is a perforation, the wax should be removed manually with a cerumen hook, probe or by microsuction.

Cerumen protects the skin, assists in lubrication, and also provides some protection from bacteria, fungi, insects and water. On the other hand,

excessive cerumen may cause hearing loss, discomfort, problems with viewing the tympanic membrane, and may become a source of infection. Movement of the jaw helps the ears' natural cleaning process.

### 1.3.5 Foreign bodies in the external auditory canal

Foreign bodies in the external auditory canal (EAC) are a relatively frequent reason for visiting an ENT specialist, especially in children. Food (nuts, beans), stones, little toys and other small objects, and cotton from cotton swabs in adults are common. They may cause pain, irritation, hearing loss or even otorrhea. They are diagnosed by otoscopy. A careful history should be taken to establish the nature of the foreign body. Removal of a foreign body from EAC should be done by a specialist under direct visualisation, and preferably using a microscope. The method of removal depends on the nature of the foreign body. The best chance to remove the foreign body is the first attempt. After this, the ear may become painful. Foreign bodies in small children that cannot be removed in the office should be removed in the operating room under general anaesthesia.

### 1.3.6 Tumors of the external ear

#### **Exostoses and osteoma of the ear canal**

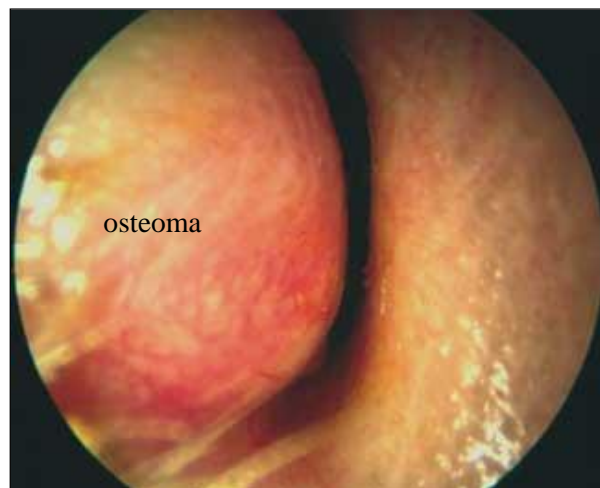*Definition.* Exostoses are multiple, while osteoma is usually solitary. They involve the bony (deep) part of the ear canal.

*Aetiology.* Exostosis is commonly seen in people with prolonged exposure to cold water, e.g. swimmers, surfers and divers. Thus, it is also called *surfer's ear*.

The *pathogenesis* of exostoses is thought to be due to chronic periostitis due to prolonged exposure to cold water and reactionary bony overgrowth. Osteomas are, however, true benign neoplasms.

*Clinical symptoms.* Early in the disease, they do not produce any symptoms and may be detected

incidentally. Later on, as they grow larger and narrow the ear canal, patients are prone to repeated infections of the ear canal (otitis externa), which is quite difficult to treat as the debris cannot be cleared effectively due to the presence of bony obstructions (Figure 1.27).



**Figure 1.27**

Osteoma of the ear canal

*Treatment.* Prevention of exostoses involves avoiding prolonged exposure to cold water, preventing ear infections through the use of topical antibiotics, and regular inspection and cleaning of the ear canal. In severe cases, surgical treatment in the form of canaloplasty is offered. This aims at drilling away the bony exostoses in order to widen the external auditory meatus.

---

#### **Chondrodermatitis nodularis chronica helicis**

This is an uncommon condition of the pinna which presents as a painful erythematous nodule, usually at the superior aspect of the helix. A lesion appears spontaneously and can last for several years. It is thought to be a result of minor trauma or exposure to cold, which induces perichondritis and inflammation. It is more commonly seen in males. Treatment involves intralesional steroid injections or surgical excision.

---

**Squamous papilloma.** It is a warty lesion of the external ear. It may be related to human papilloma virus (HPV). The lesion is usually excised and histology confirms the diagnosis.

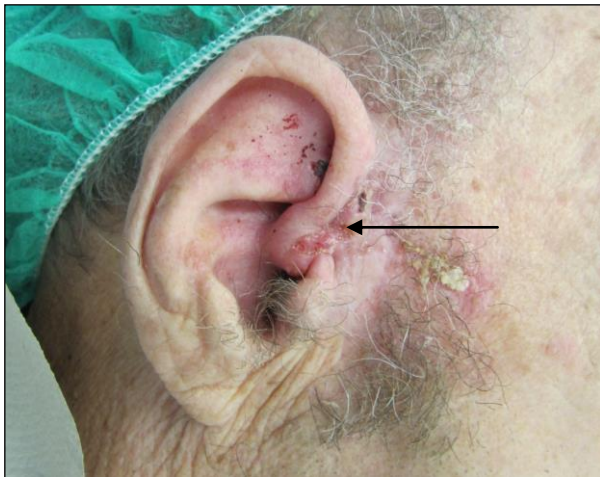

**Ceruminous tumours.** These lesions arise from the ceruminous glands and involve the lateral (outer) part of the ear canal. They are rare and can be benign (adenoma) or malignant (adenocarcinoma, adenoid cystic carcinoma). They appear as skin-covered growths in the ear canal, and are often complicated by otitis externa due to occlusion of the ear canal. Surgical excision and histological examination are recommended. For malignant lesions, radical surgery to get a clear margin is essential.

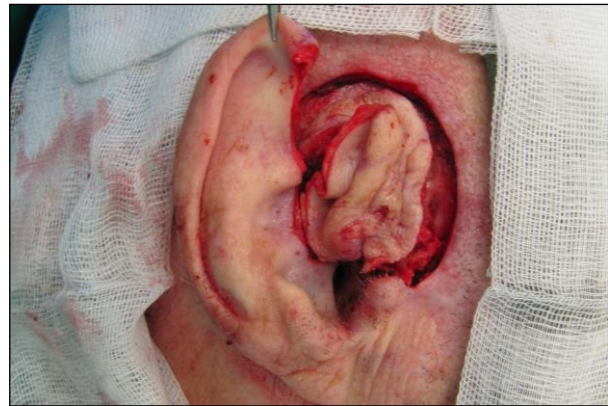**Malignant skin tumours**

Malignancies of the ear canal can be misdiagnosed as otitis externa; thus, any otitis externa in an elderly patient, which is not responding well to treatment and has suspicious features (growth, ulceration, bleeding on touch), should be biopsied.

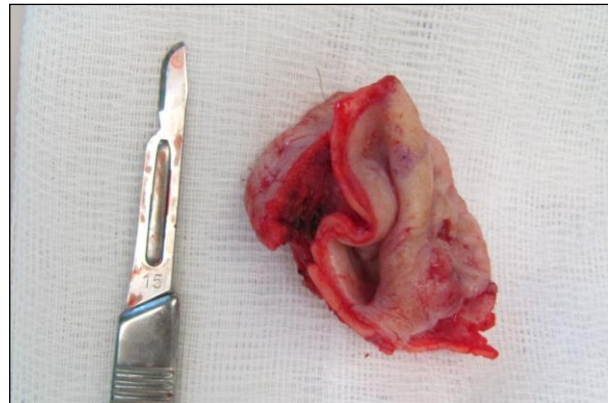
Malignant neoplasms involving the skin can involve the external ear. These include squamous cell carcinoma (Figure 1.28), basal cell carcinoma (Figure 1.29), and malignant melanoma. Squamous cell carcinoma is described in the section on tumours of the middle ear and mastoid.



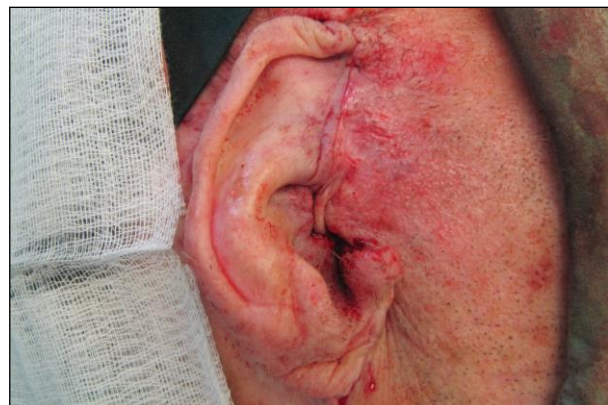**Figure 1.28a**  
Squamous cell carcinoma of the external ear  
Clinical picture



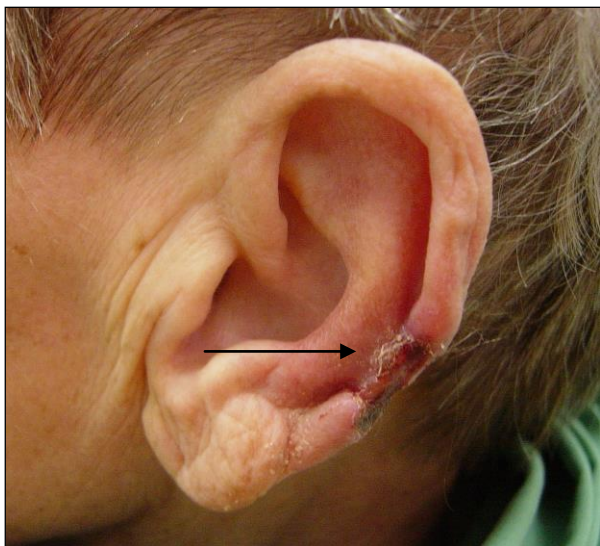**Figure 1.28b**  
Primary closure



**Figure 1.28c**  
Specimen



**Figure 1.28d**  
Primary suture



**Figure 1.29**  
Basal cell carcinoma of the auricle

## 1.4 DISEASES OF THE MIDDLE EAR

### 1.4.1 Congenital anomalies of the middle ear

There is a great diversity of anomalies of the middle ear. They may be isolated (minor) or associated with anomalies of the external auditory canal and auricle (major). Some of them are listed in Table 1.2.

#### **Congenital anomalies of the middle ear**

Many of these anomalies are part of paediatric syndromes, e.g. Brachio-Oto-Renal syndrome, Treacher Collins syndrome, Pierre Robin syndrome, craniofacial dysostosis, and Down's syndrome. The main symptom of middle ear anomalies is conductive hearing loss. A congenital disorder of the middle ear may be suspected due to failure of the child to react to noise or external ear or other abnormalities. The diagnosis is based on clinical findings, radiology of the temporal bone, and audiological assessment. The mild anomalies may remain unknown or may present in later life with mild hearing loss. Reconstruction of the conducting system or a bone-conducting hearing aid can achieve a good hearing result.

**Table 1.2** Congenital anomalies of middle ear

Anomalies of the tympanic cavity	Anomalies of the ossicles and facial nerve
<ul style="list-style-type: none"> <li>• aplasia of tympanic cavity often associated with atresia of external auditory canal or inner ear anomalies</li> <li>• rudimentary tympanic cavity</li> <li>• small tympanic cavity filled with foetal connective tissue</li> <li>• congenital hamartoma teratoma</li> <li>• congenital cholesteatoma</li> </ul>	<ul style="list-style-type: none"> <li>• congenital ankylosis of stapes</li> <li>• ankylosis of stapes and anomalies of other ossicles</li> <li>• congenital anomalies of ossicular chain with mobile stapes</li> <li>• congenital aplasia or dysplasia of oval or round window</li> <li>• window is overlapped with stapedial artery</li> <li>• window is overlapped with facial nerve</li> <li>• dehiscent Fallopian canal ~ congenital paresis of facial nerve</li> </ul>
Anomalies of the Eustachian tube	Anomalies of mastoid process
<ul style="list-style-type: none"> <li>• undeveloped Eustachian tube</li> <li>• narrowing of bony part of Eustachian tube</li> <li>• collapsed lumen of Eustachian tube</li> </ul>	<ul style="list-style-type: none"> <li>• hypoplasia of mastoid process</li> <li>• undeveloped antrum</li> <li>• hypoplastic antrum</li> <li>• underdeveloped mastoid cells</li> </ul>

### 1.4.2 Inflammation of the middle ear

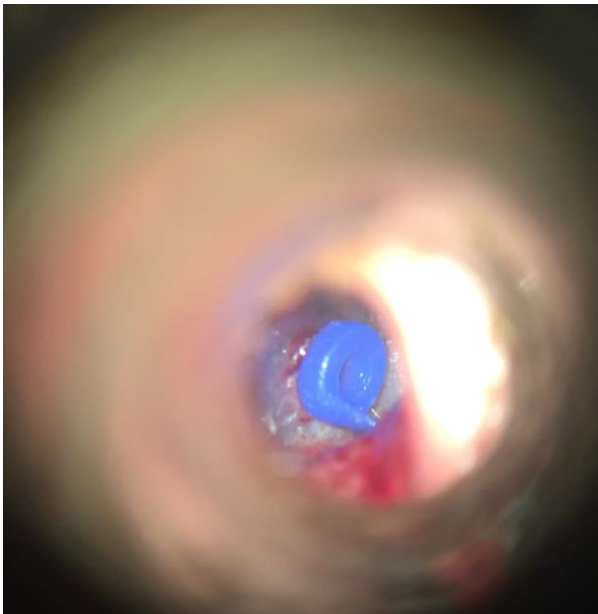
Otitis media (OM) represents an inflammatory condition of the middle ear cleft, without reference to aetiology or pathogenesis. Many terms have been used to describe the various inflammatory conditions of the middle ear space. Otitis media may occur with or without effusion. Middle ear effusion is the liquid resulting from OM. An effusion may be serous (thin, watery), mucoid (viscid, thick) or purulent (pus). The process may be acute (0–3 weeks), subacute (3–12 weeks) or chronic (more than 12 weeks). The inflammatory diseases of the middle ear are important because of their frequency and their life-threatening complications due to the close relationship between the middle ear and the cranial cavity.

Otitis media is an inflammation of the middle ear cleft. It can be acute (0–3 weeks), subacute (3–12 weeks) or chronic (more than 12 weeks). Chronic otitis media has two types: mucosal and squamosal. The squamosal type involves the presence of cholesteatoma, and is more dangerous as it is more prone to serious complications.

#### 1.4.2.1 Tubotympanic inflammation (Otitis media with effusion)

*Definition.* Disorder of ventilation and drainage of the middle ear are characteristic of tubotympanic inflammation. This condition is mainly seen in children, with a dual peak age of 2 years and 5 years.

*Pathogenesis.* The Eustachian tube does not open regularly on swallowing, resulting in poor ventilation of the middle ear cavity. This leads to resorption of the air in the middle ear, creating a vacuum with production of sterile and thick or sticky effusion.



**Figure 1.30**

Tympanic membrane with ventilation tube

*Aetiology.* Problems with tensor veli palata muscle, swelling of tubal mucosa (allergy, reflux of gastric juice, chronic sinusitis, tonsillitis) or obstruction of the ostium of tubae (hypertrophic adenoids, tumour of the nasopharynx).

*Diagnosis.* Presence of fluid or air bubbles may be seen in the middle ear through the tympanic membrane. Presence of effusion leads to conductive hearing loss and a feeling of blocked ears. The tympanic membrane appears dull on otoscopy.

*Treatment* includes observation and waiting for the condition to resolve on its own. If persistent for more than 3 months, hearing aids or myringotomy and grommet insertion can be offered (Figure 1.30).

#### 1.4.2.2 Acute otitis media

*Definition.* Acute otitis media (AOM) is one of the most common paediatric infectious diseases. Its clinical spectrum may extend from a benign, self-limiting condition to a prolonged, complicated disease. AOM is mainly a disease of young children, occurring most commonly between the ages of 3 months and 3 years. By 3 years of age, 50–85% of children have had AOM — the incidence decreases with age.

*Aetiology.* It is usually associated with an upper respiratory tract infection that spreads to the middle ear via the Eustachian tube. The causative agents may be viral or bacterial. AOM is an infectious disease, resulting from the interaction between microbial load, Eustachian tube dysfunction, and an immature immune response.

---

#### Epidemiologic factors of higher incidence of OM in children

- attending nursery
  - seasonal variation, increased incidence in colder months
  - genetic predisposition
  - immunologic deficiencies
  - adenoid hypertrophy
  - anatomical variants (cleft palate, craniofacial abnormalities)
  - passive smoking
  - lower incidence in breast-fed children
-



In 5–20% of AOM cases, the cause is a viral infection alone and respiratory syncytial virus is the most common pathogen. Co-infection with bacteria is much more common, occurring in 65% of cases. The main bacterial pathogens are *Streptococcus pneumoniae* (30–50%) and *Haemophilus influenzae* (20–30%), followed by *Moraxella catarrhalis*, *Streptococcus pyogenes*, and *Staphylococcus aureus*.

*Clinical features.* Acute otitis media represents the rapid onset of an inflammatory process of the middle ear space associated with one or more symptoms and signs. These include:

- otalgia (pain, worst at night)
- fever
- hearing loss
- otorrhea (discharge from ear)
- irritability
- anorexia
- vomiting or diarrhoea

Most children recover well from AOM, even without antibacterial therapy. The choice of treatment is empirical. Ten to 20 percent of children develop recurrent otitis media, with at least three episodes of AOM in 6 months or more than four episodes of AOM in 12 months. Some cases of AOM result in OME, which is the leading cause of childhood hearing loss.

*Complications.* If the infection spreads beyond the middle ear cleft, serious complications can occur. The infectious (acute, chronic mastoiditis, petrositis, intracranial infection) and noninfectious complications (chronic perforation of TM, ossicular erosion, labyrinthine erosion, tympanosclerosis – major causes of hearing loss) of otitis media in childhood may result in serious morbidity.

*Treatment* includes analgesics, antipyretics and antibacterial therapy. If severe, then myringotomy and drainage of purulent exudate may be required.

#### 1.4.2.3 Chronic otitis media

- It concerns long-standing inflammation of the middle ear cleft (more than 12 weeks' duration), usually characterised by ear

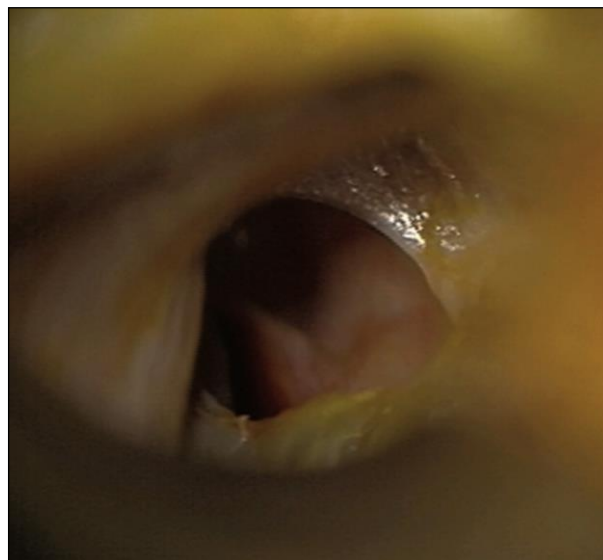
discharge tympanic membrane perforation and decreased hearing. There are two types of chronic otitis media:

- **Chronic mesotympanic otitis media** is associated with central perforation of the eardrum.
- **Chronic epitympanic otitis media with otitis and cholesteatoma** is often associated with cholesteatoma, granulations and bone erosion.

#### Chronic mesotympanic otitis media

*Definition.* This is commonly a consequence of acute otitis media, when the perforation of the eardrum does not heal and becomes permanent. Recurrent infection of the middle ear occurs through the perforation.

*Aetiology.* Common organisms causing infection include *Pseudomonas aeruginosa*, *Proteus* sp, *E. coli*, *Staph. aureus*, and anaerobes.



**Figure 1.31**

Central tympanic membrane perforation

*Clinical features.* Patients complain of recurrent ear discharge, which may be mucoid or mucopurulent. The discharge is usually intermittent, copious in amount, non-foul-smelling, and not blood-tinged. Patients also complain of decreased hearing in the affected ear.

**Diagnosis.** The tympanic membrane shows central perforation, which might be small (<25%), medium (25–50%) or large (>50%), situated anteriorly, inferiorly, posteriorly or involving more than one region (Figure 1.31). Perforation is called subtotal if it involves the entire tympanic membrane, sparing only the annulus. Middle ear structures may be seen through the perforation.

**Treatment** involves the control of infection during the active stage of the disease, by aural cleaning, and the use of antibiotics with steroid ear drops. Once the ear is dry, definitive surgical treatment may be undertaken in the form of tympanoplasty, in which the eardrum perforation is repaired with/without reconstruction of the ossicular chain.

### Chronic epitympanic otitis media with otitis and cholesteatoma

**Definition.** This is the more dangerous of the two and is associated with a retraction pocket, cholesteatoma and bone erosion. Due to the bone-eroding property of the cholesteatoma, the risk of serious complications is greater. Cholesteatoma is the main pathology in this type of chronic otitis media.

Cholesteatoma is the presence of keratinising squamous epithelium in the middle ear cleft. Normally the middle ear cleft is lined by non-keratinising epithelium.

Once cholesteatoma is in the middle ear, it expands by bone erosion, eroding the ossicles, labyrinth, facial canal, sinus plate and dural plate, giving rise to several complications.

Theories to explain how this type of epithelium reaches the middle ear:

**Congenital.** Congenital epidermal cell rests in the middle ear and temporal bone. This is a rare cause of cholesteatoma.

**Invagination.** The epithelium on the outer surface of the tympanic membrane is normally keratinising squamous epithelium. If the tympanic membrane invaginates towards the middle ear, which happens in negative middle ear pressure and retraction pockets, the keratinising squamous epithelium and keratin debris may expand into the middle ear cleft.

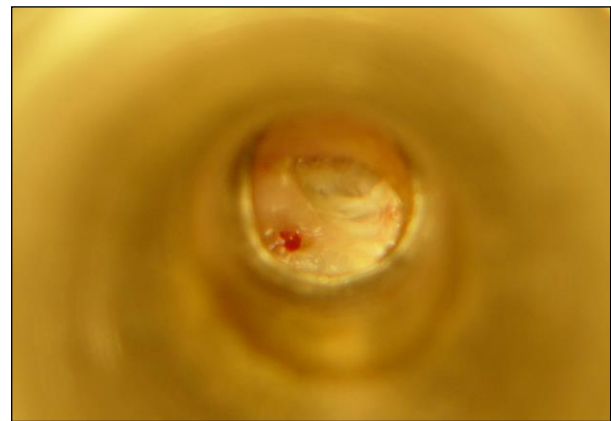
**Epithelial invasion.** The squamous epithelium of the ear canal and outer layer of the tympanic membrane may migrate into the middle ear through an existing marginal perforation in the tympanic membrane.

**Basal cell hyperplasia** causing papillary ingrowth of epithelium into the middle ear.

**Metaplasia** of normal middle ear mucosa from a nonkeratinising to keratinising type.

**Clinical features.** Patients complain of ear discharge, which is scanty, foul-smelling and may be blood-stained (compared with mucosal type). Hearing loss is due to erosion of the ossicles, and a tympanic membrane defect. Presence of vertigo, facial weakness, otalgia, and intracranial symptoms suggest complications. Perforation is either a postero-superior marginal type or attic type. Retraction pockets may be seen with pearly white flakes of keratin debris (Figure 1.32).

**Diagnosis.** Non-contrast MR imaging with diffusion-weighted imaging together with HRCT is recommended.



**Figure 1.32**

Retraction pocket in the epitympanum

**Treatment** is always surgical, and the main aim is to render the ear safe by removing the disease. The secondary aim is to restore as much hearing as possible. This is achieved by various types of mastoidectomies with tympanoplasty. Long term follow-up is necessary; patient might need open mastoid cavity cleaning, second look operation or follow-up with imaging.



#### 1.4.2.4 Complications of otitis media

Complications of otitis media have declined in the recent past; however, they are not infrequent, and can be dangerous and potentially life-threatening. Otitis media is complicated when the infection and/or inflammation spreads beyond the confines of the middle ear cleft. This is a result of two pathological processes: production of pus under tension and hyperaemic decalcification of the bony walls of the middle ear cleft.

##### Predisposing factors

Several factors predispose a patient to developing complications. Complications are more common at extremes of age, in low socio-economic groups, and in immune-compromised hosts. More complications occur in association with cholesteatoma. Infection may also spread along certain preformed pathways out of the middle ear, e.g. dehiscence of the bony facial canal, dehiscence of the jugular bulb, perilymph fistula or stapedial surgeries.

##### Classification

Classification of the complications is simple. It is based on whether extracranial or intracranial structures are involved. Intratemporal (extracranial) complications involve structures within the temporal bone, adjacent to the middle ear, but which have not spread into the cranial cavity (Table 1.3).

**Table 1.3** Complications of otitis media

Intratemporal (extracranial)	Extratemporal (extracranial)	Intracranial
Mastoiditis	Post-aural abscess	Lateral sinus thrombosis
Labyrinthitis	Bezold's abscess	Extradural abscess
Facial paralysis	Luc's abscess	Subdural abscess
Petrositis	Citelli's abscess	Meningitis
	Zygomatic abscess	Brain abscess
	Deep neck space abscess	Otitic hydrocephalus

##### General principles of management

Most of these patients will require hospitalisation, with proper maintenance of fluid and electrolyte balance. Appropriate consultations with other specialists, e.g. physicians, paediatricians, and neurosurgeons, are to be sought early when required. Intravenous antibiotics will be required to eliminate the infectious process. Antibiotics are to be chosen according to the local policy; however, amoxicillin with clavulanic acid is a good initial choice, as are third-generation cephalosporins. Third-generation cephalosporins are preferred in intracranial complications as their permeability to the blood–brain barrier is higher. Surgical intervention is often required. It may be in the form of myringotomy to release the purulent exudate, if the tympanic membrane is erythematous and bulging, or may even require cortical mastoidectomy in order to drain mucopurulent exudate from the mastoid air cell system or other forms of mastoid surgeries in cholesteatoma. Along with this, neurosurgical intervention may be essential for patients with intracranial complications.

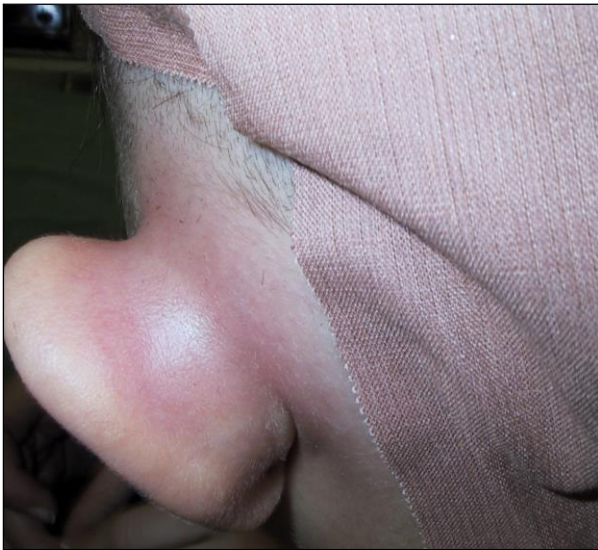#### CLINICALLY IMPORTANT COMPLICATIONS

##### Mastoiditis

*Definition.* The term “mastoiditis” is used when the inflammation spreads to involve the bony walls of the mastoid air cell system. As the mastoid air cell system is part of the middle cleft, mucosal involvement of the air cell system is almost inevitable in otitis media and is not mastoiditis. This particular complication is more common in young children, especially infants, immunocompromised hosts and malnourished children. Mastoiditis can occur in relation to acute otitis media, chronic otitis media or tuberculous otitis media as well.

*Clinical features.* The symptoms of mastoiditis are usually super-added to the symptoms of an already ongoing otitis media. The patient may develop pain in the ear, which is new or increasing in severity. The pain may be felt at the back of the ear. Fever is a common accompaniment. The ear

may start discharging or existing ear discharge may increase in quantity and purulence. Clinical signs include swelling and a smooth, ‘ironed out’ feel of the mastoid region with obliteration of the retroauricular groove and tenderness on pressure over the mastoid region. The tympanic membrane might have a perforation, and mucopurulent secretions may be seen pulsating out of the perforation, often called “the lighthouse effect” (Figure 1.33).



**Figure 1.33**

Acute mastoiditis in child

*Diagnosis* is often clinical, and cross-sectional imaging in the form of a CT scan of the mastoids and head will help to confirm the diagnosis and rule out other associated complications.

*Treatment* is in accordance with the general principles as mentioned above. Cortical mastoidectomy is often required to drain the mucopurulent exudate from the mastoid air cell system.

### **Labyrinthitis**

*Definition.* This complication occurs when the inflammation extends to the membranous labyrinth from the middle ear cleft. Labyrinthine function can be reversible initially, when actual bacterial invasion and suppuration have not

occurred (diffuse serous labyrinthitis), or permanent damage to the labyrinth can be done in later stages (diffuse suppurative labyrinthitis). Sometimes a part of the membranous labyrinth is exposed due to bony erosion without any inflammation of the labyrinth itself. This is known as labyrinthine fistula and is most common over the lateral semicircular canal.

*Clinical features and diagnosis.* The main complaint is vertigo. This may be aggravated on head movement. Usually in diffuse labyrinthitis the patient is incapacitated, lying in a bed, with severe vertigo associated with nausea and vomiting. Nystagmus is detected, with a quick component towards the affected ear initially. If carefully tested, usually some degree of sensori-neural hearing loss is associated.

*Treatment* involves following the general principles. The patient is usually placed at bed rest. Labyrinthine sedatives (prochlorperazine, cinnarizine) help to control the symptom of vertigo and give symptomatic relief. Surgical drainage of the infection in the form of myringotomy or cortical mastoidectomy is often required.

### **Petrositis**

*Definition.* Spread of infection to the petrous part of the temporal bone is called petrositis.

*Clinical features.* This infection gives rise to a classical presentation called Gradenigo’s syndrome, which includes: a) external rectus palsy (VI Cranial Nerve involvement), b) deep-seated retro-orbital pain (V Cranial Nerve involvement), and c) persistent ear discharge. It is uncommon to see the full triad of symptoms these days, especially in partially treated patients. Imaging with CT and MRI scans are essential to see the extent of the disease and for surgical planning, as well as to rule out intracranial involvement.

*Treatment* involves following the general principles. Cortical mastoidectomy while following the cellular tract to the petrous apex might be required.

### **Sigmoid sinus thrombosis**

*Definition.* This involves inflammation of the wall of the lateral venous sinus (sigmoid sinus) with

formation of thrombus inside as a result of the spread of infection from the middle ear and mastoid to the sigmoid sinus through eroded bone or emissary veins. It is a potentially fatal complication, and although the incidence has been greatly reduced due to the use of antibiotics, a high index of suspicion is required to correctly diagnose this condition.

*Clinical features* can be masked due to the use of antibiotics, and just the persistence of fever, headache and otorrhea might be the only presentation. Several classical features are described, which include picket fence fever with rigors, tenderness and oedema over the mastoid region (Griesinger's sign) due to thrombosis of the mastoid emissary vein, thrombosis of the internal jugular vein, paralysis of IXth, Xth, and XIth Cranial Nerves (jugular foramen syndrome), and papilloedema.

Confirmation of *diagnosis* requires CT imaging. A CT scan also helps to exclude other intracranial complications which may co-exist. Contrast CT produces rim-enhancing dura surrounding an empty triangle which resembles the clot in the sinus. This is known as the delta sign.

*Treatment* is a combination of surgery and antibiotics. Surgery, in the form of mastoidectomy, (depending on the primary middle ear disease), confirms the presence of lateral sinus thrombosis intraoperatively, opening the sinus, and draining the infected clot.

## **Meningitis**

*Definition.* Meningitis is a common complication of acute otitis media, chronic otitis media or mastoiditis. Meningitis is inflammation of the meninges, commonly with microbial invasion of cerebrospinal fluid in subarachnoid space. The spread of infection is usually hematogenous; however, it can also spread by retrograde thrombophlebitis or direct bone erosion.

*Clinical features.* Fever with headache and neck rigidity. Patients develop nausea and vomiting (which is often projectile). Irritability and photophobia are characteristic. As infection progresses, seizures, drowsiness and other neurological deficits develop. If left untreated,

patients would become comatose and might become fatal.

*Diagnosis.* CT scans of the temporal bone and CT or MRI of the brain are essential, along with a lumbar puncture to prove the diagnosis.

*Treatment* involves antibiotics, supportive measures and surgical treatment (myringotomy +/- mastoidectomy) to remove the source of infection.

---

### **Abscess in relation to otitis media**

*Post-aural abscess:* This develops from mastoiditis, when the purulent exudate erodes through the cortex of the mastoid bone and forms a subperiosteal collection in the post-aural region. This results in fluctuant swelling with oedema and erythema, and displacement of the pinna forwards and downwards. If untreated it eventually breaks through the periosteum, subcutaneous tissues and the skin to form a discharging fistula. Treatment involves draining the abscess and performing a cortical mastoidectomy, along with systemic antibiotics.

*Bezold's abscess:* The purulent exudate from the mastoid cavity breaks through the medial side of the tip of the mastoid to form an abscess along the digastric or the sternocleidomastoid muscles, in the superior aspect part of the neck. If left untreated, this can progress to involve the deep neck spaces. Treatment includes draining the abscess and treating the mastoiditis with cortical mastoidectomy and systemic antibiotics.

*Luc's abscess:* Purulent exudate breaks through the bony wall between the mastoid and the deep external auditory canal, producing a bulge in the deep part of the ear canal.

*Citelli's abscess:* The abscess here is formed more posteriorly, towards the occipital bone.

---

## **1.4.3 Trauma to the middle ear – temporal bone fractures**

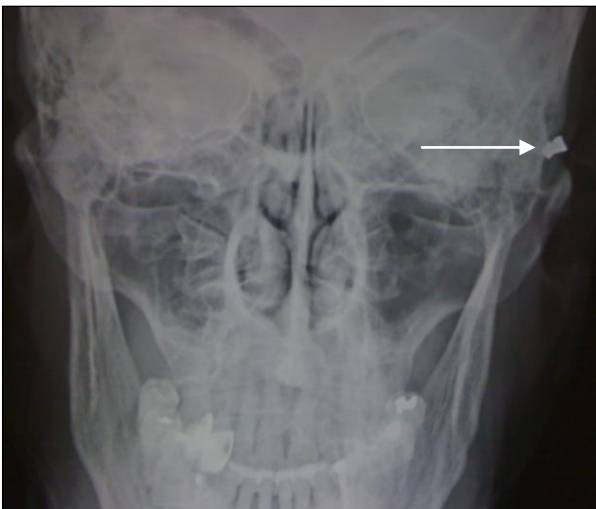A temporal bone fracture involves the external ear, middle ear and inner ear structures; however, for simplicity, the topic will be discussed in this chapter.

The temporal bone contains many vital structures; thus, fractures of the temporal bone may cause significant morbidity. It is almost always seen in patients with a head injury, with other intracranial injuries being as high as 90%. Management of other intracranial injuries and stabilisation of the patient are more important than the management of the temporal bone fracture, which is always done

when the patient is stable. Temporal bone fractures can be divided into longitudinal, transverse and mixed types based on the course of the fracture line through the temporal bone (Table 1.4).

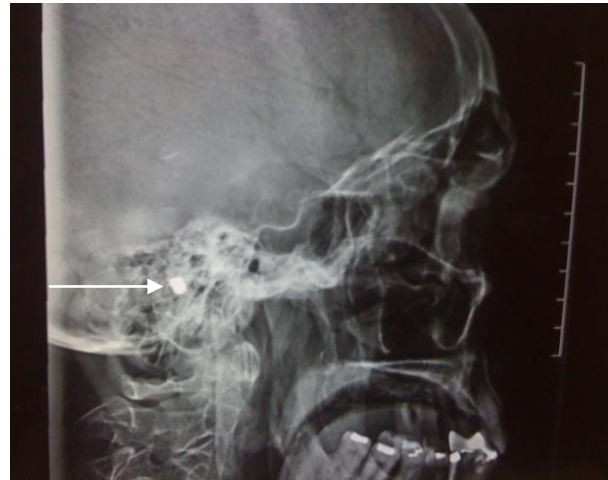**Table 1.4** Differences between longitudinal and transverse temporal bone fractures

Longitudinal fracture	Transverse fracture
Seen 80% of the time	Seen 20% of the time
Fracture line is along the long axis of the petrous temporal bone	Fracture line is perpendicular to long axis of petrous temporal bone
Result of a lateral blow to the head	Result of frontal or occipital blow
Tympanic membrane is commonly ruptured	Uncommon
CSF leak and bleeding from the ear are common	Uncommon
Hearing loss is commonly conductive	Hearing loss is commonly sensori-neural
Vertigo is mild, due to concussion	Vertigo is severe, due to the fracture destroying the otic capsule
Facial nerve paralysis is uncommon (20%) Usually a delayed onset and temporary	Facial nerve paralysis is more common (50%) Usually an immediate onset and permanent



**Figure 1.34a**

Gun shot with a bullet in the middle ear; plain radiograph, postero-anterior view



**Figure 1.34b**

Gun shot with a bullet in the middle ear; plain radiograph, lateral view

*Aetiology.* Two major causes are road traffic accidents and assault. Other causes include falls, accidental injuries, penetrating injuries (including gunshot wounds), and sports injuries (Figure 1.34). Men are affected more, due to increased involvement in high-risk activities. The highest incidence is seen in men aged 21–30 years.

#### 1.4.3.1 Longitudinal fractures (lateral from lateral inner ear wall)

*Definition and aetiology.* These are seen 80% of the time. They occur due to a lateral blow to the temporo-parietal region. The fracture line runs parallel to the long axis of the petrous portion of the temporal bone. It extends from the squamous temporal bone up to foramen lacerum. Commonly, it fractures the external auditory canal, ruptures the tympanic membrane, runs through the roof of the middle ear, and may disrupt the ossicles. The otic capsule and the facial nerve commonly escape injury.

*Clinical features.* The symptoms include bleeding from the ear (and possible CSF otorrhoea), conductive or mixed deafness, and facial paralysis in 20% of patients. Vertigo is possible but usually it is not severe.



Remember the mnemonic ‘L’ for longitudinal fractures

- Largely seen (80%)
- Lateral blow
- Along the Long axis of the petrous temporal bone
- Lots of bleeding
- Leak of CSF
- Laceration of TM, with ossicular disruption
- Loss is conductive

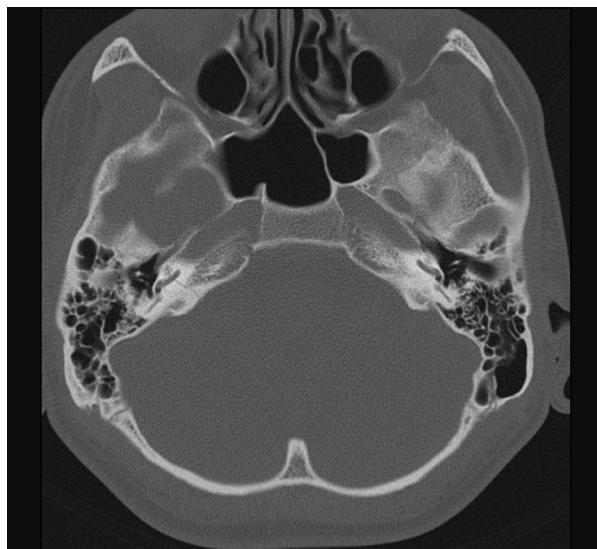
#### 1.4.3.2 Transverse fractures (medial to lateral inner ear wall)

*Definition and aetiology.* This type is seen 20% of the time. It occurs due to a frontal or occipital blow and is usually the result of a more serious injury. The fracture line runs at a right angle to the long axis of the petrous temporal bone and commonly involves the otic capsule (cochlea and vestibule) (Figure 1.35). It also usually involves the facial nerve (50%).

*Clinical features.* Symptoms include hearing loss (sensorineural or mixed) with severe vertigo and facial nerve paralysis. The differences between longitudinal and transverse fractures are shown in table 1.

*Diagnosis and treatment.* As mentioned before, these patients have a head injury patients. Initially, survey and management are according to Advanced Trauma Life Support protocols in order to stabilise the patient. An ENT specialist gets called in much later to evaluate the bleeding ear or the patient with vertigo or facial nerve palsy. Examination of the ear should look for bruising in the postauricular region (Battle sign), lacerations and haematoma of the pinna, lacerations and step deformity of the ear canal, and rupture of the eardrum. Hearing can be tested using tuning forks. Nystagmus should be looked for if the patient is conscious and obeys commands. The facial nerve is examined by asking the patient to raise his eyebrows, tightly close his eyes, frown, puff his cheeks, show his teeth, and put his lips. A complete ENT examination should be done to look for trauma to other regions of the

midface. Aseptic precautions are necessary as there is a potential CSF leak and brain herniation in these patients. In a suspected temporal bone fracture, the ear should not be lavaged nor should ear drops be introduced as this can be a source of infection in CSF leaks.



**Figure 1.35**

Transverse fracture of the temporal bone; CT scan, axial plane

HRCT of the temporal bone is essential in these patients and it shows the fracture line with the structures involved and ossicular status. The ear is usually managed conservatively, with hearing tests done after 6 weeks to look for hearing loss. Conductive hearing loss can be corrected by repairing the ossicular chain (ossiculoplasty) and/or the tympanic membrane (myringoplasty). Sensori-neural hearing loss may require hearing aids. Facial nerve paralysis can be treated with systemic steroids.

### 1.4.4 Tumours of the middle ear

#### 1.4.4.1 Glomus tumours

*Definition.* These are the most common benign tumours (only 3% can have distant metastasis and, hence, are malignant) involving the middle ear

and the temporal bone. They are extremely vascular, encapsulated tumours.

---

Glomus tumours are derived from the paraganglionic cells and, thus, are also called paragangliomas. Paraganglia occur in several regions in the body (commonly the abdomen, thorax, head and neck) and function as chemoreceptors. The carotid body is an example of paraganglia. They are derived from embryonic neuroepithelial cells which are in close association with the autonomic nervous system. In the head and neck, paragangliomas include glomus jugulare (paraganglia in relation to the jugular bulb), glomus tympanicum (in relation to the tympanic branch of the glossopharyngeal nerve), glomus vagale (in relation to the vagus nerve), and carotid body tumours (in relation to the carotid body).

---

*Clinical features.* Symptoms are caused by compression of important structures, such as cranial nerves, or middle ear structures with local invasion and/or local extension of the tumour. In relation to the temporal bone, glomus jugulare and glomus tympanicum will be described.

**Glomus jugulare** develops in relation to the jugular bulb and involves the hypotympanic area of the middle ear (inferior part). It can then involve the mastoid air cells, petrous apex, carotid canal, and can go intracranial. The tumours can erode the tympanic membrane and prolapse as a polyp into the ear canal. Tumours can be classified based on the extent, and Fisch classification is extensively used. Classification helps in choosing the surgical approach for its removal and allows comparison of outcomes.

---

#### **Fisch classification of glomus tumours**

Type A tumour	Tumour limited to the middle ear cleft (glomus tympanicum)
Type B tumour	Tumour limited to the tympanomastoid area with no infralabyrinthine compartment involvement
Type C tumour	Tumour involving the infralabyrinthine compartment of the temporal bone and extending into the petrous apex
Type C1 tumour	Tumour with limited involvement of the vertical portion of the carotid canal
Type C2 tumour	Tumour invading the vertical portion of the carotid canal
Type C3 tumour	Tumour invasion of the horizontal portion of the carotid canal
Type D1 tumour	Tumour with an intracranial extension less than 2 cm in diameter
Type D2 tumour	Tumour with an intracranial extension greater than 2 cm in diameter

---

**Glomus tympanicum** develops in relation to the tympanic branch of the glossopharyngeal nerve (Jacobson's nerve) which is located on the promontory. Initially, the tumour is limited within the middle and can be removed relatively easily. Glomus jugulare originates in the region of the jugular bulb and extends into various important structures surrounding it.

*Diagnosis.* Pulsatile tinnitus and hearing loss are the most common symptoms. Tinnitus is of the swishing type and synchronous with the pulse; it may be temporarily stopped by compressing the carotid artery. Hearing loss is usually of a conductive type; however, mixed or sensori-neural loss can occur as the tumour grows larger. With growth, Cranial Nerves at the jugular foramen (IX–XI) become involved, causing dysphagia, nasal regurgitation, dysphonia, and shoulder weakness. Facial nerve weakness may be seen in 30% of patients. Bloody ear discharge can also occur when the eardrum has been eroded by the tumour. As the tumour extends intracranial, headache, hydrocephalus, ataxia, and other symptoms of brainstem compression may ensue.

---

Examination may typically reveal a vascular mass in the inferior aspect of the middle ear, as seen through an intact tympanic membrane. This is called a 'rising sun' appearance. On positive pressure with Siegel's auricular speculum the mass behind the eardrum may blanch and this is called Brown's sign. Occasionally, unilateral carotid compression may cause cessation of pulsations of the mass (Aquino sign). Facial nerves and the lower cranial nerves need to be examined.

A pure tone audiogram usually reveals conductive or mixed hearing loss. A CT scan with contrast shows a hypervascular tumour with bony erosion. MRI with gadolinium contrast shows a 'salt and pepper pattern' of the tumour and its extensions into surrounding structures.

---

*Treatment* options include the watch-and-wait approach and serial observations. These are suitable for small tumours with slow growth. Gamma knife radiosurgery can be applied to relatively smaller tumours, where radiation is used to shrink the tumour and reduce or stop the rate of growth. Surgical excision is challenging due to their location in the skull base and hypervascularity. Small tumours can be excised

through the ear canal, while larger tumours require transmastoid approaches or various infratemporal approaches.

#### 1.4.4.2 Squamous cell carcinoma

*Definition and epidemiology.* Squamous cell carcinoma of the middle ear is a very rare tumour; however, this is still the most common primary malignancy of the middle ear. It can originate in the middle ear and spread to the external ear canal (or vice versa). Most cases are seen in middle-aged to elderly patients with a history of chronic otitis media and long-standing otorrhea.

*Clinical features.* Diagnosis is difficult, as the complaints are similar to that of chronic otitis media initially. Persistent otorrhea, blood-stained ear discharge and persistent pain increasing at night are early symptoms. Granulation and polyps may be found in the ear canal. Later on, hearing loss increases and tinnitus, vertigo, facial palsy and masses in the region of the parotid and neck may appear.

*Diagnosis.* When suspected, a biopsy of the granulations and polyp is taken through the ear canal and this may confirm the diagnosis. A CT scan of the temporal bone and neck with contrast is extremely important for treatment planning.

*Treatment.* Surgical treatment (often with post-operative radiotherapy) is offered if the patient is fit. En-bloc resection is the best chance of a cure. Several types of temporal bone resections can be done based on the extent of the tumours. Patients who are not amenable to surgical treatment can be offered palliative radiotherapy.

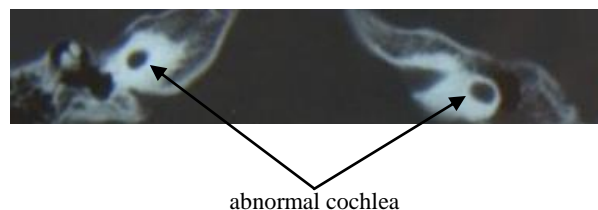
## 1.5 DISEASES OF THE INNER EAR

### 1.5.1 Congenital anomalies of the inner ear

The inner ear is the collection of structures within the bony labyrinth: the semicircular canals, the vestibule and the cochlea. Congenital abnormalities

here are rare and will result in deafness (in addition to possible dizziness) and account for up to 20% of children with sensorineural hearing loss. They may be associated with external or middle ear abnormalities or may exist on their own. The diagnosis is based on clinical, audiological and radiological evaluation. A positive family history can suggest a genetic origin, whilst a detailed history of pregnancy may reveal a teratogenic cause. Intrauterine infection can cause inner ear damage; the best known is rubella (labyrinthine anomalies with dysplasia of the middle ear). Developmental malformations that affect the otic capsule result in anomalies of both the membranous and bony labyrinth. The most common anomaly is dysplasia of the membranous labyrinth. The specific timing of the insult during otic capsule development determines the resultant type along a spectrum of congenital inner ear malformations. In a descending order of severity and later developmental time course, they are Michel's aplasia, cochlear aplasia, common cavity, incomplete partition-I (cystic cochleovestibular malformation), cochleovestibular hypoplasia, and incomplete partition-II (classic Mondini's malformation) (Figure 1.36).

High-resolution CT scanning will determine the nature and extent of the problem, and the multidisciplinary approach (including rehabilitation) is necessary.



**Figure 1.36**

Abnormalities of the cochlea – Mondini's malformation, CT scan

### 1.5.2 Otosclerosis

*Definition.* Otosclerosis is a slowly progressive primary disorder of the bony labyrinth causing

replacement of normal bone with spongiotic or sclerotic new bone. It is a common cause of progressive hearing loss.

**Epidemiology.** Otosclerosis is much more common in the white population, and at least 2 times more common in females than in males.

**Aetiology.** The exact cause of otosclerosis is unknown; however, there are various features of the disease that are unique.

---

**Heredity:** Otosclerosis runs in the family; often, more than one member of the family is affected. Since the disease is more common in females, we should always enquire about the presence of similar complaints among other female members in the family. It is an inherited disease, showing an autosomal dominant pattern with incomplete penetrance.

**Measles:** The association of otosclerosis with measles is interesting. Measles viral RNA was detected in surgical specimens of a footplate removed from patients with otosclerosis, thus giving rise to the idea that measles can cause otosclerosis. However, all cases of otosclerosis do not show an association with measles. It is possible that the measles virus may play a role in activating the gene that is responsible for causing the disease.

**Pregnancy:** There is a well-known association between pregnancy and progression of the disease. Though pregnancy does not cause otosclerosis, the disease is seen to progress faster during pregnancy.

---

**Pathophysiology.** The predominant pathological process in otosclerosis is the replacement of normal bone with spongiotic and/or sclerotic bone. The replacement is pleomorphic, with early stages showing spongy vascular new bone, which later matures into dense sclerotic bone. Sclerotic bone may cause fixation of stapes, causing symptoms of decreased hearing.

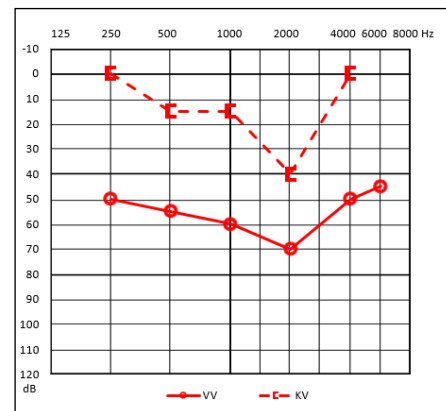
---

Otosclerosis can be classified into histologic and clinical types. The histologic type has the presence of otosclerotic foci without the presence of clinical symptoms. This is 10 times more common than the clinical type. Clinical otosclerosis can be stapedial (causing stapes fixation and predominantly conductive hearing loss) or cochlear (predominantly sensorineural hearing loss).

---

**Clinical features.** Hearing loss is the presenting symptom, which usually starts in the patients twenties and is progressive. It is usually bilateral (70%); however, the degree of hearing loss may differ in both ears. A positive family history,

especially among the female members, is an important history to elicit. Otosclerosis is associated with accelerated progression during pregnancy, around menopause and during hormonal therapy. Due to conductive hearing loss, patients have a soft speech, as they hear their own voice louder due to enhanced bone conduction. *Paracusis Willisii* is an interesting phenomenon in patients with otosclerosis. Patients hear better in noisy surroundings than in quiet places. This is because in a noisy surrounding, a normal person would raise his voice during conversation, which helps patient with otosclerosis to hear better. Hearing loss may be associated with tinnitus, which is due to increased vascularity in otosclerotic foci and/or associated cochlear damage with sensorineural hearing loss. Vestibular symptoms are rare in otosclerosis; however, they may be present in advanced disease. The tympanic membrane is quite normal on examination and is said to be in a ‘mint condition’. However, rarely (10%), a reddish hue is detected through the tympanic membrane in the middle ear over the promontory. This is known as the *Schwartz sign*, and represents active otosclerotic foci with increased vascularity. Tuning fork tests reveal conductive loss (Rinne negative with Weber lateralised to the worse ear) and varying degrees of sensorineural loss based on the extent of the disease.



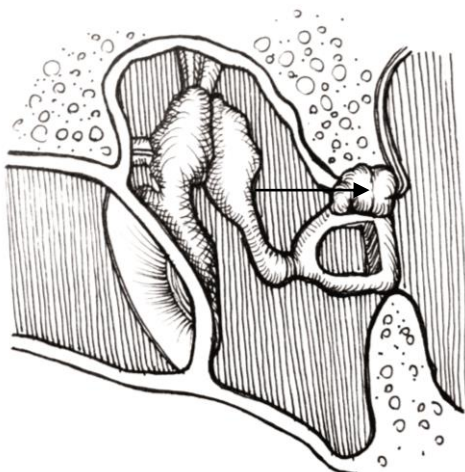
**Figure 1.37**

Otosclerosis – pure tone hearing test- Carhart’s notch

Pure tone audiometry shows nearly normal bone conduction with a large air-bone gap. A character-

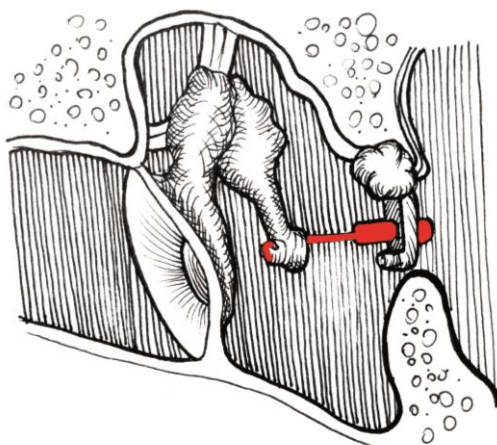


istic feature is the presence of *Carhart's notch*, which is an artifactual dip of 10–15 dB in bone conduction at 2000 Hz (Figure 1.37). Carhart's notch disappears after successful stapedotomy. Tympanometry is extremely helpful, and shows an A type of curve with the absence of stapedial reflex, which signifies ossicular stiffness or fixation.



**Figure 1.38a**

Principle of surgical treatment of otosclerosis.  
Sclerotic bone fixing footplate of stapes



**Figure 1.38b**

Principle of surgical treatment of otosclerosis.  
Piston as a part of ossicular chain

*Differential diagnosis.* Congenital stapes fixation, fixed malleus-incus syndrome, tympanosclerosis, ossicular discontinuity, secretory otitis media, osteogenesis imperfecta, and Paget's disease are some other diseases that can present with conductive hearing loss with a similar history. However, careful history taking, good clinical examination and attention to pure tone audiometry and tympanometry will help in differentiating otosclerosis from all of these diseases.

*Treatment.* Medical treatment of otosclerosis is limited. Sodium fluoride has been tried. It slows the progression of the disease, and helps to mature active spongiotic foci of otosclerosis. Besides sodium fluoride, there are two main options in treating otosclerosis: hearing aids and surgery (stapedotomy). Hearing aids aim to amplify the sound reaching the ear, thus improving hearing. It has no effect on improving or halting the disease process.

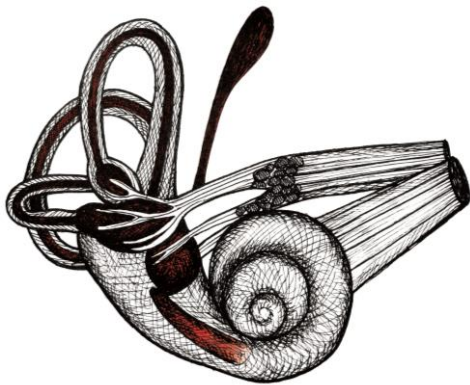
*Surgery* is in the form of stapedotomy, which aims at removal of the stapes suprastructure, making a fenestration in the stapes footplate and insertion of prosthesis between the long process of the incus and the oval window (Figure 1.38). This prosthesis performs the function of the stapes, transmitting vibrations from the ossicular chain into the inner ear, thus bypassing the fixed footplate. The surgery requires considerable technical skill and training, and is not devoid of complications. A very small percentage of patients (1 in 200) may even have a total hearing loss following the surgery.

### 1.5.3 Ménière's disease

*Definition.* Ménière's disease (MD) is an idiopathic condition first described by Prosper Ménière in the *Gazette Médicale de Paris* in 1861. It consists of a triad of **episodic vertigo**, **fluctuating hearing loss** and **tinnitus**, and is often associated with **aural fullness**. Ménière's syndrome refers to other pathological entities (e.g. otosyphilis, autoimmune inner ear disease) which produce clinical features similar to Ménière's disease.

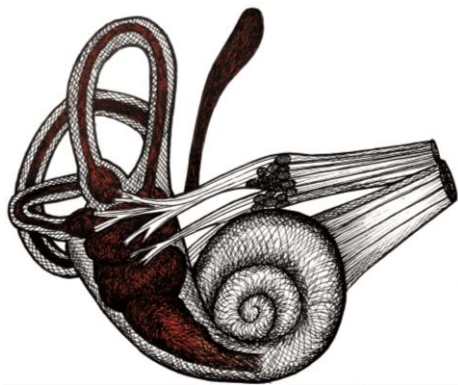
The *aetiology* and *pathogenesis* of MD are an enigma. The most acceptable theories are described. Detailed pathophysiology of MD is beyond the scope of this book.

Endolymphatic hydrops is thought to be the pathologic basis for Ménière's disease. Endolymph, the potassium-rich fluid, is present inside the membranous labyrinth of the inner ear, and perilymph is contained in the bony labyrinth, which surrounds the membranous labyrinth. Endolymphatic hydrops, which means excessive fluid accumulation in the endolymphatic space, may be due to either excessive synthesis or inadequate resorption, resulting in expansion of the endolymphatic space (Figure 1.39). Several mechanisms have been suggested to explain how endolymphatic hydrops may produce clinical symptoms of spontaneous attacks of vertigo. The most accepted theory suggests that endolymphatic hydrops causes rupture of the distended membranes of the inner ear, allowing the potassium-rich endolymph to leak into the perilymphatic space. The electrochemical imbalance, due to mixing of endolymph with perilymph, causes excitation and then subsequent inhibition of the inner ear hair cells, giving rise to episodic vertigo, tinnitus and gradual hearing loss over a period of time.



**Figure 1.39a**

Ménière's disease – Normal labyrinth



**Figure 1.39b**

Ménière's disease – Endolymphatic hydrops

The classical triad of symptoms includes: vertigo, sensori-neural hearing loss, and tinnitus (along with other symptoms such as aural fullness and anxiety).

*Clinical features.* Vertigo (false sense of rotatory motion when there is none) is the main feature and is episodic, sudden at the onset, and occasionally preceded by an aura of increased aural fullness, increased tinnitus or a change in character of tinnitus. It is accompanied by nausea and vomiting, sweating and sometimes other vagal disturbances, e.g. diarrhea, abdominal cramps, pallor and bradycardia. Attacks may occur in clusters with long and variable periods of remission in between. Usually, vertigo in MD lasts from 20 minutes to 24 hours, and is usually 1–2 hours in duration. The patient is incapacitated during the attack and usually lies still in bed, often vomiting. Hearing loss may initially be fluctuating, with increased hearing loss during the attacks of vertigo. Later in the disease, after several years, as more inner ear hair cells are damaged, hearing loss becomes more obvious. This is permanent, slowly progressive sensori-neural hearing loss. Tinnitus is usually low-pitched, roaring type and is aggravated during attacks. Some amount of tinnitus is usually present all of the time, however, a change in intensity and pitch of the tinnitus may act as a warning symptom of an impending attack. Other features include aural fullness, emotional stress and anxiety due to vertigo. The impact of MD on quality of life is huge, as it affects the patient's occupation, social life, mood, sleep and several other aspects of daily life.

*Evaluation.* Clinical examination of the ear reveals no abnormalities. Tuning fork tests will show the presence of sensori-neural hearing loss of a varying degree (positive Rinne's test, Weber lateralising to the better ear). Nystagmus can be appreciated during an acute attack.

*Diagnosis.* Pure tone audiometry reveals sensori-neural hearing loss. Early in the disease the hearing loss is more at lower frequencies with an up-sloping audiometric curve; however, as the disease progresses, hearing decreases further,

whereby affecting all frequencies with the curve flattening out.

*Glycerol test:* Administration of oral glycerol (dehydrating agent, thus decreasing endolymphatic hydrops) improves hearing in MD patients. An audiometry may be done 3 hours after oral glycerol administration and improvement of 10 dB or more of the hearing threshold is very suggestive of MD.

*The caloric test* shows a reduced response on the affected side. Canal paresis on the affected side is the most common finding with or without direction preponderance to the opposite side.

*Electrocochleography (ECoChG)* has an important role in MD and shows some diagnostic features. Detailed explanation is beyond the scope of this book. The diagnostic features include a summing potential/action potential ratio of greater than 30% and distorted cochlear microphonics.

*Vestibular Evoked Myogenic Potential (VEMP):* VEMP is a neuroelectrophysiological test that evaluates the otolithic organs of the utricle and saccule. An increased VEMP threshold or absent VEMP may help the diagnosis of MD.

*MR Imaging* of the inner ear is always done to rule out tumours such as vestibular schwannoma and endolymphatic sac tumours, as MD is a diagnosis of exclusion.

For a diagnostic summary see Table 1.5.

**Table 1.5** Criteria for diagnosis of MD (American Academy of Otolaryngology and Head & Neck Surgery)

Definition	Symptoms
Certain Ménière's disease	Definite Ménière's disease plus histopathologic confirmation
Definite Ménière's disease	≥2 definitive spontaneous episodes of vertigo for 20 min or longer Audiometrically documented hearing loss on at least one occasion Tinnitus or aural fullness in the treated ear Other causes excluded
Probable Ménière's disease	One definitive episode of vertigo Audiometrically documented hearing loss on at least one occasion Tinnitus or aural fullness in the treated ear Other causes excluded
Possible Ménière's disease	Episodic vertigo without documented hearing loss, or sensorineural hearing loss fluctuating or fixed, with dysequilibrium but nonepisodic Other causes excluded

*Treatment.* There is no proven cure for MD and current therapy focuses on reducing symptoms.

*General measures.* Dietary restriction of sodium, caffeine and alcohol is extremely important. *Low salt diet* has been proven to reduce the number of attacks and induce remission. Daily sodium intake should not be more than 2 grams. Caffeine and alcohol reduction has benefits, however, supporting evidence is low. Vestibular rehabilitation exercises during the remission period help to improve vestibular function and achieve symptom control. Other measures that have been proven to be helpful include relaxation, challenging negative beliefs, and lifestyle modification, all of which reduce amplification of dizziness by anxiety. It is very important to reassure patients, which helps them to cope better with their symptoms.

*Medications.* Vestibular sedatives (prochlorperazine, cinnarizine) help to achieve control of vertigo during acute attacks. They may be effective in controlling associated nausea, vomiting and other vagal symptoms. Prolonged use of vestibular sedatives is not recommended. Diuretics (triamterene 50 mg/hydrochlorothiazide 25 mg) may reduce the severity and frequency of attacks. They may be used 5 days a week to avoid the complication of electrolyte imbalance. Betahistine (8–16 mg, three times daily) is widely used, although its exact mechanism of action is unclear. It helps in reducing vertigo and also has some beneficial effect with tinnitus. Intratympanic gentamicin injection may be used in patients not responding well to other medications. Gentamicin is predominantly vestibulotoxic, and when injected into the middle ear, it is absorbed through the round window membrane into the inner ear and destroys the vestibular labyrinth, abolishing episodic vertigo. It has the potential to damage hearing as well, but the effect on the vestibular labyrinth is far greater than the effect on the cochlea.

A *Meniett device* is a treatment used in the USA. It is a low-pressure pulse generator device. The prerequisite is myringotomy and placement of a grommet so that this device can deliver intermittent positive pressure waves to the round window membrane. It must be used three times daily for several weeks to get significant results.

*Surgical treatment* is reserved for a small percentage of MD patients with frequent attacks and no control of symptoms with general measures and medication. Several surgical procedures have been described; some procedures are nondestructive, hearing-sparing procedures, while others are destructive. Non-destructive procedures are endolymphatic sac surgeries (endolymphatic sac decompression and endolymphatic shunt), which are probably the first-choice procedures and are done more commonly. Destructive procedures include vestibular nerve section and labyrinthectomy, and are reserved for patients who do not respond to symptomatic treatment.

#### 1.5.4 Tumours of the inner ear

The cerebellopontine angle (CPA) is a CSF-filled space bounded medially by the brainstem, laterally by the posterior part of the temporal bone, and posteriorly by the anterior surface of the cerebellum. The most common tumour affecting this space is the acoustic neuroma (80%). Other tumours affecting CPA include meningioma, facial nerve neuroma, arachnoid cyst, ependymoma, other cranial nerve schwannomas, vascular tumours, and metastasis. Besides CPA tumours, other tumours affecting the middle ear, mastoid and external ear can extend to involve inner ear structures. These have been described earlier in Chapters 1.3.6. and 1.4.4.

##### **Acoustic neuroma**

*Definition and epidemiology.* It is a benign tumour, arising from the Schwann cells of the vestibular nerve. Thus, it is also called the vestibular schwannoma. It affects individuals in the 4<sup>th</sup> to 6<sup>th</sup> decades. The only predisposing factor, which increases its incidence, is exposure to radiation. Bilateral acoustic neuromas are seen in patients with neurofibromatosis II.

*Clinical features.* The tumours can be very slow-growing, slow-growing or rapidly growing. Symptoms are produced by compression of adjacent structures. Unilateral hearing loss and tinnitus are very common presenting features, and are present in almost 90% of patients. Tumours are

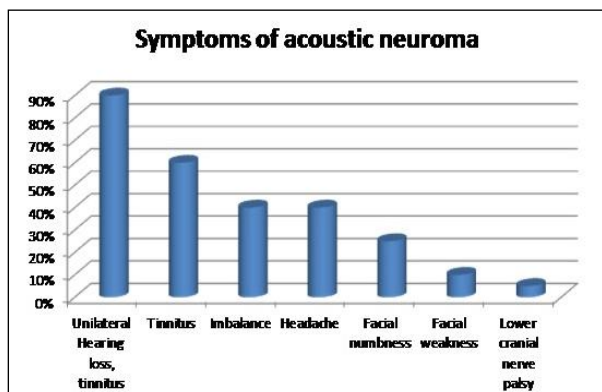
often small and compress the VIIIth cranial nerve, producing hearing loss. Occasionally, the hearing loss can be sudden or fluctuating. It is mandatory to evaluate patients who have unilateral hearing loss and sudden hearing loss with contrast MRI to rule out acoustic neuroma. Vertigo is not common as the tumour grows quite slowly, and this gives the vestibular system time to compensate for the unilateral vestibular loss. As tumours grow larger, the trigeminal nerve can be affected, causing facial numbness. Facial weakness is rare, as the facial nerve is quite robust, and it functions well even when the nerve is stretched by the tumour. However, sensory fibres of the facial nerve can be affected early and it may result in paraesthesia and hypoesthesia of the posterior meatal wall, which is called the Hitselberger sign. As the tumour grows larger, several cerebellar signs and instability may be noted. It finally distorts the CSF-containing spaces causing hydrocephalus and may compress the brainstem. This may give rise to headaches, drowsiness, coma and, finally, death. Graphic representation of the frequency of various symptoms is given in Figure 1.40a.

*Diagnosis.* Pure tone audiometry will reveal unilateral/asymmetric sensorineural hearing loss. Speech audiometry shows poor speech discrimination disproportionate to the hearing loss. Vestibular tests may show a diminished vestibular response on the affected side. The most important investigation, however, is MRI with gadolinium contrast to image the internal auditory meatus, which can reveal a tumour of even a few millimetres. MRI can determinate the intracanalicular part and the part which extends into the CP angle, in relation to various other important structures (Figure 1.40).

*Treatment.* There are three options to treat acoustic neuroma: serial MRI as part of the observation approach, gamma knife radio-surgery (for relatively small tumours), and surgical removal. Serial MRI and observation can be offered to elderly patients with small, slow-growing tumours. On many occasions the tumour grows extremely slowly and symptoms may not progress much for 20–30 years. Gamma knife radiosurgery uses radiation, which is focused on the tumour. Radiation damages the tumour cells and shrinks the

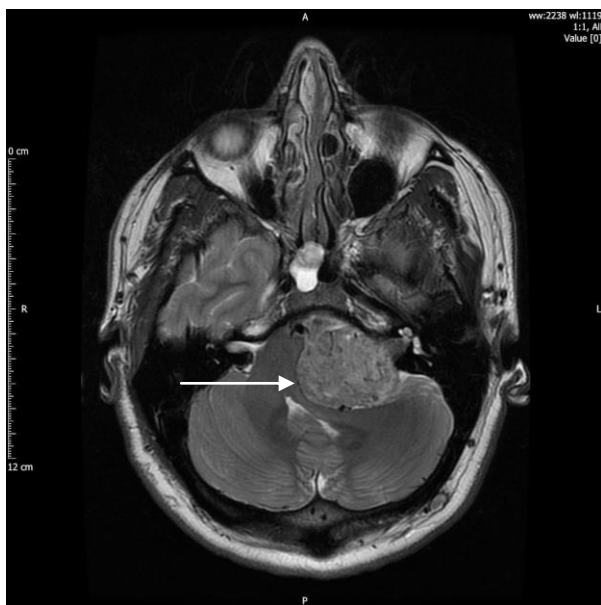


tumour. It also stops growing or grows extremely slowly. Long-term follow-up with MRI is required. Surgery involves removal of the tumour. There are three approaches to the CP angle: *translabyrinthine* approach, *middle cranial fossa* approach and *retrosigmoid* approach. The decision to use a particular approach depends on the size of the tumour, extension of the tumour, the status of the hearing, and the function of the facial nerve.



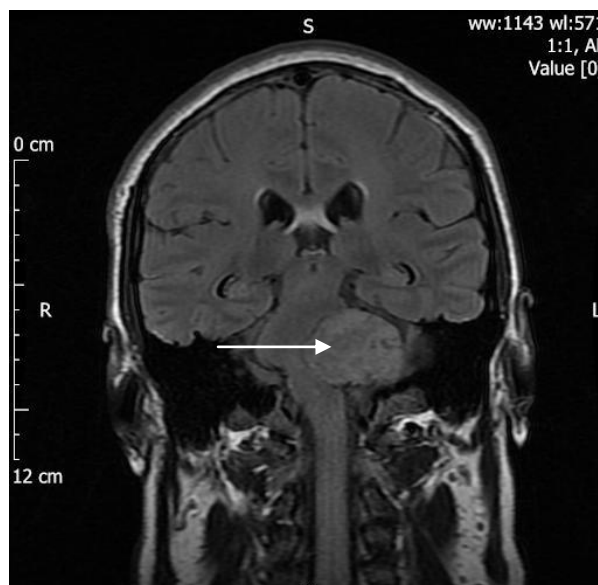
**Figure 1.40a**

Symptoms of acoustic neuroma



**Figure 1.40b**

Acoustic neuroma; MRI scan, T2-weighted image, axial plane



**Figure 1.40c**

Acoustic neuroma; MRI scan, T2-weighted image, coronal plane

### 1.5.5 Sensorineural hearing loss

A brief overview of sensorineural hearing loss (SNHL), along with a short discussion of the common causes, is presented in this section.

*Definition.* The mechanical acoustic energy is conducted through the external and middle ear to the sensory organ for hearing, the cochlea. The cochlea converts acoustic vibrations into frequency-specific action potentials. This electric current is transmitted through the VIII<sup>th</sup> nerve and the central auditory pathway to the hearing centre in the brain. Thus, any lesions of the cochlea, VIII<sup>th</sup> nerve or the central auditory pathway will result in SNHL.

*Aetiology.* SNHL can be congenital or acquired. It can also be classified as unilateral (affecting one ear) or bilateral. The common causes are listed in Table 1.6.

*Clinical features.* Hearing loss may be present since birth (congenital) or develop later in life. The onset of hearing loss may be sudden or it might have progressed gradually. Patients with SNHL find it extremely difficult to hear in noisy surroundings

(unlike in otosclerosis) and in places where many people are talking from different directions (e.g. round-table conferences). Discrimination of words and speech may be poor (out of proportion to the degree of hearing loss). History pertaining to the various suspected causes should be sought.

**Table 1.6** Common causes of SNHL

Unilateral SNHL	Bilateral SNHL
Sudden sensorineural hearing loss	Presbycusis
Infections (viral/bacterial labyrinthitis, meningitis)	Ototoxicity
Vestibular schwannoma	Noise-induced hearing loss (occupational)
Trauma (temporal bone fracture, head injury)	Autoimmune inner ear diseases
Acoustic trauma	Familial progressive hearing loss
Ménière disease	Systemic diseases (DM, hypothyroidism, multiple sclerosis)
Iatrogenic (post-operative deafness)	All causes of unilateral SNHL affecting both ears

**Diagnosis.** As in any condition, it is of paramount importance to take a good history and do a complete ENT examination in a patient with SNHL. Examination of the ear usually reveals a normal ear canal and tympanic membrane. The tympanic membrane must be visualised in all cases after clearing the ear canal of any cerumen or debris (if present). Tuning fork tests give a clue to the type of hearing loss. In SNHL, Rinne’s test is positive, while Weber lateralises to the better hearing ear.  
**Treatment.** A hearing aid is the mainstay of rehabilitation for SNHL (see also Chapter 9.4).

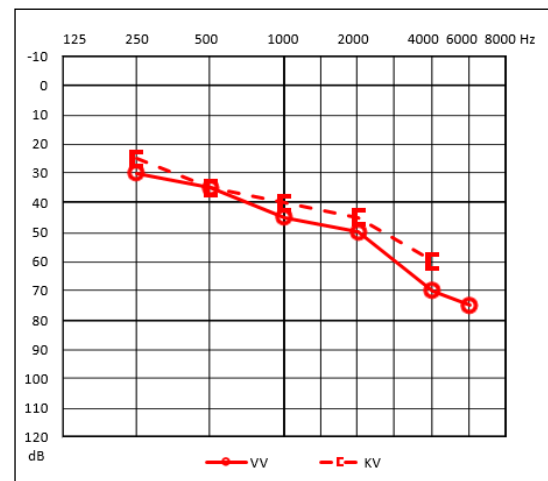
### 1.5.5.1 Presbycusis

**Definition.** It is a very common condition of hearing loss associated with the aging process.

**Epidemiology.** The prevalence of bilateral hearing loss is 28.7% in men and 17% in women aged 60–69 years, which increases to 79.1% at an age of

above 80 years. It usually manifests by the 5<sup>th</sup> to 6<sup>th</sup> decades and slowly progresses. The hearing loss is usually bilaterally symmetrical.

**Clinical features and diagnosis.** The most important investigation that clinches the diagnosis is a pure tone audiometry. Audiometry shows bilateral hearing loss, with a reduction of both air conduction and bone conduction with no air-bone gap. The audiogram demonstrates the type of hearing loss and degree of hearing impairment. Initially, the hearing loss is more marked in higher frequencies (giving a down-sloping audiogram) and later it might affect all frequencies (Figure 1.41).



**Figure 1.41**

Pure tone hearing test – presbycusis

It is important to ascertain whether the hearing loss is symmetrical or not. Asymmetrical hearing loss will require an MRI scan of the internal auditory meati to rule out the occasionally detected vestibular schwannoma and other cerebello-pontine angle tumours.

**Treatment.** Hearing loss is irreversible and managing these patients involves hearing rehabilitation, using whatever serviceable hearing remains.

General measures such as facing the person while speaking, reducing the volume of the television while talking, and speaking slowly and clearly



instead of shouting would help a person with presbycusis to hear better. If hearing loss is significant in affecting daily activities, hearing aids are a good option and should be used bilaterally to give better results (see also Chapter 9.4).

### 1.5.5.2 Ototoxicity

*Definition.* Ototoxicity is the tendency of certain therapeutic agents to damage the tissues of the inner ear, especially the end organs and neurons of the cochlea and vestibular system. These drugs and chemicals can give rise to tinnitus, hearing loss and dysequilibrium.

*Clinical features.* The ototoxic effect of a drug is enhanced by some patient-related factors. These include advanced age, renal impairment, concomitant use of more than one ototoxic drug, and genetic susceptibility. Ototoxicity presents with one of the following: tinnitus, hearing loss or dysequilibrium.

Tinnitus is the most common initial symptom. It is usually high-pitched initially, often continuous, and becomes low-pitched if the damage continues. This is an early warning sign of inner ear damage. Hearing loss is often gradually noticeable after a few days or weeks by the patient. However, loop diuretics may cause immediate hearing loss, some of which fortunately recovers. Hearing loss is initially in the high frequencies and most often permanent. Dysequilibrium may be seen with predominantly vestibulotoxic drugs. True vertigo is rare, as both ears are affected symmetrically. Patients may have trouble moving around and getting up from a bed, especially if vision is poor or in the dark.

*Diagnostics and treatment.* Diagnosis of ototoxicity typically results from ruling out all other possible sources of hearing loss. Treatment options vary, and some patients experience only temporary symptoms that do not require treatment. No specific treatment may be available, but withdrawal of the ototoxic drug may be warranted when the consequences of doing so are less severe than those of the ototoxicity. Physical therapy may prove useful for regaining balance and walking abilities.

Cochlear implants are sometimes an option to restore hearing.

---

#### Common ototoxic drugs

*Aminoglycoside antibiotics* (streptomycin, gentamicin, neomycin, amikacin). Streptomycin and gentamicin are primarily vestibulotoxic, while amikacin and neomycin are mainly cochleotoxic. They damage the outer hair cells of the cochlea and cause hearing loss in high frequencies initially. Most of the hearing loss is permanent; recovery (if any) is extremely minor.

*Loop diuretics* (furosemide) cause oedema and cystic changes in the striae vascularis of the cochlear duct and result in flat hearing loss, whereby affecting all frequencies. The hearing loss may be immediate and has a potential to recover.

*Salicylates* (aspirin) tend to cause hearing loss by constriction of blood vessels going to striae vascularis, which damages inner hair cells, which are extremely sensitive to anoxia. They may also act on an enzymatic level to produce an ototoxic effect. Hearing loss generally affects all frequencies and is reversible. Hearing is expected to return to base line 72 hours after discontinuating the use of Aspirin.

*Quinine* has been used in treatment of malaria, and it produces hearing loss similar to that of salicylates. Hearing loss is a flat type and is reversible following cessation of the drug.

*Cisplatin* and *carboplatin* are chemotherapeutic agents used in the treatment of cancer of the bladder, testes, ovaries, breast, and some cancers of the head and neck. The mechanism of damage is similar to aminoglycosides with loss of hair cells. Cisplatin is predominantly cochleotoxic. Tinnitus is the initial symptom, followed by hearing loss (which may be permanent). The degree of hearing loss depends on the cumulative dose of the drug.

*Other drugs* with an ototoxic effect include erythromycin, chloramphenicol, indomethacin, ibuprofen, propranolol and propylthiouracil.

---

### 1.5.5.3 Noise-induced hearing loss (NIHL)

*Definition.* This term refers to a reduction in auditory acuity associated with noise exposure. The reduction may be temporary or permanent. It may be the result of long-term repeated exposure to loud noise (factory workers) or a single episode of exposure to intense, loud sound (firecrackers, firearms, blasts). The latter is called acoustic trauma.

Certain predisposing factors also play a role in determining why some individuals are more sensitive to effects of noise than others. There is a potential genetic susceptibility to NIHL. Age is an

important factor, and aged people are usually more susceptible to effects of noise. Some other factors include smoking, use of recreational drugs, diseases such as diabetes, and cardiovascular diseases, all of which increase the damage to the cochlea in the presence of loud noise.

---

The mechanisms as to why there is decreased hearing associated with noise exposure are not entirely clear. There is apoptosis and necrosis of the outer hair cells of the cochlea, leading to hearing loss. Increased release of neurotransmitters, decreased blood flow, increased metabolic demand, and micromechanical structural changes in the cochlea during noise exposure are all implicated in causing hearing loss.

---

*Clinical features and diagnosis.* NIHL is extremely important medico-legally and claims are often made based on the diagnosis. Daily noise exposure above 85 dB may cause NIHL, and as the noise level increases, the number of hours of exposure allowed daily decreases. In elderly people it is extremely important to determine whether the hearing loss is age-related or noise-induced. Invariably, the two components are mixed and it requires considerable experience to dissect the two. Certain standardised tables are available which mention the average amount of hearing loss expected in a particular age in otherwise healthy individuals. Decreased hearing is often the main complaint. In early stages, difficulty arises in the presence of a background noise or while watching television, which later progresses to difficulty in having a normal conversation. The hearing loss is usually slowly progressive. Tinnitus is often associated and it may affect sleep, mood and concentration. It is important to take the history of the noise exposure: the level of noise, continuous or intermittent, number of hours of exposure and the use of hearing protective devices. It is also important to rule out a family history of early hearing loss, head injury, meningitis and ototoxic medication as causes of the hearing loss. Clinical examination of the ear is usually normal. Audiometry is necessary in all cases, and it typically shows SNHL with a notched pattern. There is maximum hearing loss at 4 kHz

(3–6 kHz) with some recovery at 8 kHz. This is very typical of NIHL; however, the absence of a notched audiogram cannot be used to exclude NIHL.

*Management and prevention.* NIHL should be prevented as the hearing loss is permanent and cannot be regained. An employer should conduct a noise survey and embark on education of the workers about NIHL. Appropriate *personal hearing protective devices* (ear plugs and muffs) should be provided and it is mandatory if noise levels are 90 dB or more. Regular hearing tests should be offered to the workers. In patients with NIHL, further noise exposure should be avoided. Hearing rehabilitation with counselling, general measures to improve communication (face-to-face talking, decreasing background noise while in conversation), and hearing aids are the mainstay of management of these patients.

#### 1.5.5.4 Sudden sensorineural hearing loss

*Definition.* Sensorineural hearing loss of 30 dB or more in three or more contiguous frequencies occurring in less than 3 days is termed sudden sensorineural hearing loss (SSNHL).

*Aetiology.* There may be several causes of SSNHL (Table 1.7); however, most often the cause is not detected (95%) and is termed as idiopathic sudden sensorineural hearing loss (ISSNHL).

**Table 1.7** Causes of sudden sensorineural hearing loss

#### Causes of SSNHL

- Viral infection
- Syphilis
- Encephalitis
- Vascular occlusion/thrombosis
- Autoimmune
- Labyrinthine membrane rupture
- Ototoxic drugs
- Multiple sclerosis
- Cogan's disease
- Vestibular schwannoma

---

In idiopathic SSNHL, as the name suggests, the cause is unknown; however, there are several theories proposed. Viral infection, vascular occlusion and autoimmune phenomenon are thought to be the most important factors damaging the inner ear.

*Clinical features and diagnosis.* Patients present with sudden loss of hearing in one ear and often the presentation is after a few days or sometimes a few weeks. The loss of hearing may have been attributed to the common cold or impacted cerumen, and only when the condition does not improve with simple remedies may patients present to an ENT specialist. Examination of the ear will be normal and tuning fork tests suggest unilateral SNHL. It is important to establish that the patient did not have any previous hearing disabilities and the onset is really acute. A previous audiogram (if available) is very helpful to establish a diagnosis. Patients are often worried regarding the other ear; however, it is extremely rare (<1%) to get ISSNHL in both ears. Patients can be safely reassured that this is most likely unilateral and they will have hearing in the unaffected ear.

Pure tone audiometry is obviously essential for diagnosis. If possible, it is compared with previous audiograms (if available), which proves that the hearing loss is new. Other investigations include screening blood tests and MRI of the internal auditory meatus to rule out vestibular schwannoma.

*Treatment.* It is extremely important to discuss the diagnosis with the patient and the treatment options with their complications. Most treatments have only a little effect on the disease process; thus, it is essential to select drugs with the fewest side effects for a particular patient.

Many agents have been used for management with variable results. Steroids (oral/injectable/intratympanic), antivirals, vasodilators and plasma expanders have all been used. An oral steroid in the form of prednisolone (1 mg/kg) is most commonly used in reducing dosage (along with acyclovir). Many centres use injections of steroids through the tympanic membrane and claim to have better results with fewer side effects. Treatment remains controversial, with marginal benefit (if any).

## 1.5.6 Vertigo

*Diagnosis.* Vertigo is a false sense of motion, either of the environment or of the individual when there is none.

ENT diseases causing vertigo usually give rise to a sense of rotatory motion. Terms such as dizziness, unsteadiness, light-headedness and others are vague terms and may not be true to vertigo.

*Diagnosis.* History is of paramount importance in vertigo patients. Most patients are diagnosed on the basis of the history itself. It is important to determine what the patient actually means when the complaint is vertigo. Sometimes, other symptoms (like temporary loss of consciousness or light-headedness) may be confused by the patient as vertigo. If it is truly vertigo, it is important to ask how long it lasts, how often it happens, any precipitating factors, e.g. head movement, and associated symptoms such as nausea and vomiting. Other otologic symptoms such as hearing loss, tinnitus, ear discharge, otalgia, and facial weakness will give a clue to the underlying cause. It is important to rule out neurological symptoms, as central causes for vertigo should be kept in mind.

*Clinical examination* should focus on complete ear and hearing assessment, with assessment of the balance system. This includes eliciting nystagmus, a smooth pursuit, saccades, head thrust test, head shake test, Romberg test, Unterberger test, Dix–Hallpike manoeuvre, and a number of cerebellar tests. All cranial nerves should be examined along with neurological assessment for central causes.

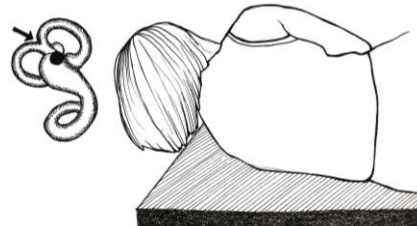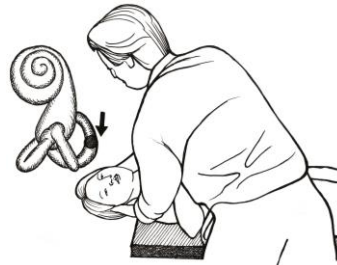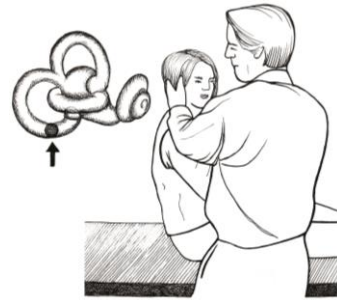
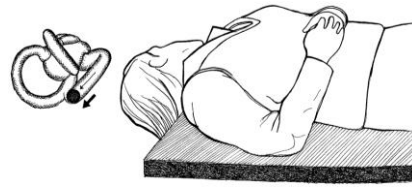Further assessment can be done by *certain tests*. Traditionally, the caloric test has been used to evaluate the peripheral vestibular system. It uses irrigation of the ear canal with cold (30°C) and warm (44°C) water to induce nystagmus and vertigo by stimulating the lateral semicircular canal. The response to cold and warm water is noted on both sides and conclusions can be made

regarding canal paresis and directional preponderance. Other tests available include electronystagmography, video nystagmography, rotation tests, vestibular evoked myogenic potentials, electrocochleography, and computerised dynamic posturography. Details of these tests and their interpretations are beyond the scope of this book.

Common ENT causes of vertigo are being discussed in the following chapters.

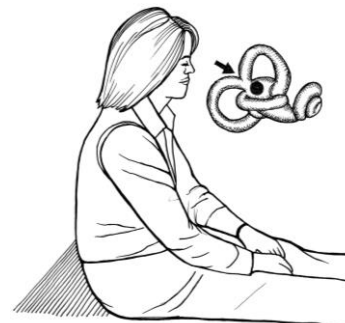### Nystagmus

Nystagmus is an involuntary, rhythmic, to-and-fro motion of the eyeball. It has a fast component and a slow component. Direction of nystagmus is the direction of the fast component. Nystagmus can be horizontal (sideways to-and-fro motion), vertical (up-and-down motion), rotatory or a combination of these. Nystagmus can be classified as spontaneous when present while looking straight ahead and gaze-induced, which is only present when staring at the examiner's finger placed in different positions. Nystagmus can be graded to various degrees. It is 1<sup>st</sup> degree if nystagmus is weak and only present while looking in the direction of the fast component, 2<sup>nd</sup> degree when present while looking straight ahead, and 3<sup>rd</sup> degree (strongest) when present even while looking in the direction of the slow component. Nystagmus caused by peripheral vestibular problems (ENT causes) usually has a latency, of a fixed direction to one side only, is fatiguable and, thus, reduces on repeated examination and is associated with symptoms of vertigo and other systemic upsets. Nystagmus caused by central lesions (neurological) will not have a latency, will not be fatiguable, is usually direction-changing/bi-directional, and may not be associated with subjective symptoms. This is an important differentiating point between central and peripheral causes of vertigo.



### 1.5.6.1 Benign paroxysmal positional vertigo (BPPV)

**Definition.** This is a common clinical problem and it is characterised by episodes of a spinning sensation when the head is placed in certain positions, such as looking on a shelf or looking underneath a chair. The vertigo is short-lived, for a few seconds, and the patient is normal afterwards. There are no other otological or neurological symptoms. *The Dix-Hallpike test is positive*, which confirms the diagnosis.



**Figure 1.42**  
Epley manoeuvre

*Aetiology.* It is thought to be caused by free-floating otoconial debris that has been dislodged from the utricle/sacculle and settled in the posterior semicircular canal. With head movement, the otoconial debris moves itself or causes movement of the endolymph inside the semicircular canal, causing vertigo. Rarely is the lateral semicircular canal affected.

*Treatment.* The condition can be treated by Epley manoeuvre (Figure 1.42). The treatment can be repeated more than once if it is ineffective on the first attempt and the success rate is generally fairly high. It essentially aims to reposition the otoconial debris out of the posterior semicircular canal into the utricle, where it is normally found. Patients with this condition are often terrified and should be reassured, as BPPV is a self-limiting and otherwise harmless condition.

#### 1.5.6.2 Ménière's disease

Ménière's disease is characterised by a triad of vertigo, sensorineural hearing loss, and tinnitus with aural fullness. This is described in detail in Chapter 1.5.3.

#### 1.5.6.3 Vestibular neuronitis

*Definition.* This condition is characterised by the sudden onset of severe vertigo which lasts for several days to a few weeks.

*Aetiology.* It may sometimes be preceded by a viral flu-like illness of an upper respiratory tract infection. Thus, the cause of this is thought to be a viral infection involving the vestibular ganglion. This is, however, not entirely proven, and other factors such as local ischaemia may play a role as well.

*Clinical features.* The patient is usually acutely unwell. Vertigo increases on head movement and patients may prefer to lie still on the bed. Associated nausea, vomiting and other vagal symptoms are often seen. Hearing is normal and this differentiates vestibular neuronitis from

labyrinthitis. It may take more than a week for the symptoms to completely resolve. There is usually some residual vestibular weakness.

*Diagnosis* is often made on the basis of history. It is important to note that hearing is normal here, unlike in labyrinthitis, where both hearing and balance are affected. *Treatment* includes vestibular sedatives and anxiolytics in the acute period. Later on, patients require vestibular rehabilitation therapy (VRT) in order to improve balance. VRT involves a combination of vestibular exercises, physical therapy and other adjuvant therapies such as relaxation techniques.

#### 1.5.6.4 Labyrinthitis

*Aetiology.* Labyrinthitis may be infective (caused by virus or bacteria), traumatic or a complication of chronic otitis media.

*Clinical features.* The symptoms are similar to vestibular neuronitis, with additional sensorineural hearing loss, as this condition affects the entire labyrinth (both the vestibular and hearing organ). Serous labyrinthitis occurs when bacterial toxins and enzymes cause inflammation of the inner ear and is potentially reversible; however, suppurative labyrinthitis is irreversible and is due to the actual invasion of inner ear structure by bacteria.

---

Other peripheral causes of vertigo include migrainous vertigo, vestibulotoxic drugs, head trauma, and vestibular Schwannoma.

Central causes of vertigo should always be kept in mind and evaluation should try to rule out central causes. Common central causes include basilar migraine, vertebrobasilar insufficiency, posterior inferior cerebellar artery syndrome, multiple sclerosis, cerebellar diseases, tumours of the brainstem and posterior fossa, and several others.

---

*Treatment.* The management of the patient is similar to that of vestibular neuronitis.

#### 1.5.7 Tinnitus

*Definition.* Tinnitus is the perception of sound in the absence of any external source. It is usually



perceived in the form of noise, and it is different from auditory hallucinations, where there is false perception of voices (including words and sentences). The word *tinnitus* in Latin means ‘to ring’.

**Classification and clinical features.** Tinnitus can be generally classified into two types: *subjective tinnitus*, which is heard only by the patient, and *objective tinnitus*, which may be heard by the examiner as well. Objective tinnitus is extremely rare and is due to vascular or neuromuscular causes producing audible pulsations or clicks respectively. Subjective tinnitus may be in the form of ringing, buzzing, hissing, roaring or any combination. It is important to note that tinnitus is not a disease. It is a symptom; as such, it does not cause any harm to the patient. It is the patient’s reaction to tinnitus, which causes symptoms such as annoyance, a lack of concentration and poor sleep.

**Table 1.8** Causes of tinnitus

<b>Subjective tinnitus</b>	Otologic
	<ul style="list-style-type: none"> <li>• Impacted cerumen, otitis externa</li> <li>• OME, acute and chronic otitis media</li> <li>• Otosclerosis</li> <li>• Ménière's disease</li> <li>• Noise trauma</li> <li>• Ototoxic drugs</li> <li>• Tumours of Cranial Nerve VIII</li> <li>• Presbycusis</li> </ul>
<b>Objective tinnitus</b>	Non-otologic
	<ul style="list-style-type: none"> <li>• Central nervous system diseases: stroke, multiple sclerosis, epilepsy, migraine, tumours</li> <li>• Anaemia, hypertension</li> <li>• Hypoglycaemia, metabolic disturbances</li> </ul>
<b>Objective tinnitus</b>	Vascular
	<ul style="list-style-type: none"> <li>• Aberrant internal carotid artery</li> <li>• High and dehiscent jugular bulb</li> <li>• Glomus tumours</li> <li>• Arteriosclerosis</li> <li>• AV malformations</li> </ul>
<b>Objective tinnitus</b>	Neuromuscular
	<ul style="list-style-type: none"> <li>• Palatal myoclonus</li> <li>• Tensor tympani and stapedial myoclonus</li> <li>• Temporomandibular joint clicks</li> </ul>

**Aetiology.** Anything which reduces hearing may give rise to tinnitus (Table 1.8). Temporary tinnitus may be experienced by all of us when exposed to loud noise. Tinnitus can be caused by lesions in the external ear, middle ear, inner ear, auditory nerve, auditory pathway or in the central nervous system. On many occasions the ear may be entirely normal (except for some age-related sensorineural hearing loss), but patients may experience troublesome tinnitus. Although it is important to thoroughly examine the ear, hearing and balance systems, tinnitus can happen with no apparent pathologies.

**Diagnosis.** It is important to rule out any ear pathologies by complete otological examination. Pure tone audiometry should determine the hearing thresholds. Additional investigations may include imaging, MRI to rule out acoustic neuroma in unilateral tinnitus, a CT scan with contrast in pulsatile tinnitus to rule out vascular anomalies or tumours, and neurological evaluation if central lesions are suspected.

In the majority of cases, tinnitus is caused by damage to the hearing organ. Only a very few cases of tinnitus are caused by identifiable, repairable medical conditions. MRI of posterior cranial fossa in case of unilateral tinnitus excludes possibility of acoustic neuroma.

**Treatment.** In most cases, there is no need for treatment, other than reassurance that the tinnitus is not being caused by another treatable illness. In the very rare instance where the tinnitus is extremely bothersome, anti-anxiety or anti-depressant medication and sometimes small masker devices such as hearing aids help to block out the sound of the tinnitus with "white noise". Most people with tinnitus find that their symptoms are worse when under stress, so relaxation techniques can be helpful. Tinnitus retraining therapy helps to accept the sounds from tinnitus as normal, helping the patient to be less aware of it. Hearing loss worsens the effect of tinnitus, so protection of hearing and avoiding loud noises are very important in preventing worsening of the symptoms.



## 1.6 FACIAL NERVE

### 1.6.1 Anatomy

The facial nerve is the VII<sup>th</sup> cranial nerve and it is intimately related to the temporal bone and the parotid gland, hence being encountered at several points during various otologic surgeries and head and neck surgeries, particularly the parotid surgery. Therefore, it is extremely important for an ENT surgeon to know a detailed anatomy of the facial nerve (Table 1.9).

**Table 1.9** Course of facial nerve

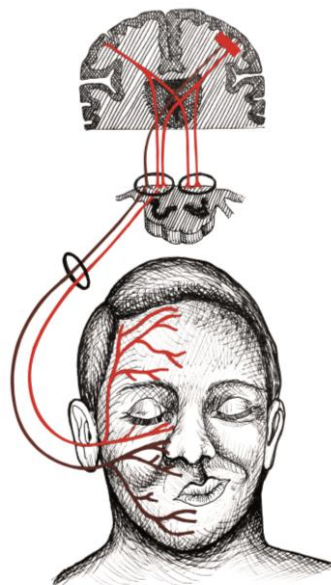
Segment	Location	Length in mm
Supranuclear	Motor cortex	-
Nucleus (Brainstem)	Motor nucleus of facial nerve, superior salivatory nucleus, nucleus of tractus solitarius	-
Intracranial	Brainstem to internal auditory canal (IAC)	14–17
Meatal segment	In the internal auditory canal	8–10
Labyrinthine segment	Fundus of IAC to geniculate ganglion (1 <sup>st</sup> genu)	3–4
Tympanic segment	Geniculate ganglion to pyramidal eminence (2 <sup>nd</sup> genu)	8–11
Mastoid segment	Pyramidal process to stylomastoid foramen	10–14
Extratemporal segment	Stylomastoid foramen to pes anserinus	15–20

The facial nerve is a *mixed cranial nerve*, having 70% of its fibres supplying muscles of facial expression. All muscles derived from the 2<sup>nd</sup> branchial arch are innervated by the facial nerve. The rest of the fibres are secretomotor and somatosensory. Secretomotor fibres innervate the lacrimal gland, submandibular and sublingual salivary glands, and nasal and palatal glands. Somatosensory fibres carry taste sensation to the anterior two thirds of the tongue and palate and

general sensation from the concha and retroauricular skin. The course of the facial nerve, from its origin to termination, can be divided into various segments:

#### Nucleus of facial nerve and supranuclear connections

The motor nucleus of the facial nerve is located in the pons. It has superior and inferior halves for fibres going to the superior part of the face and lower part of the face respectively. Voluntary motor impulses originate in the motor cortex, and get transmitted through the corticobulbar tract to the motor nucleus. The fibres synapse at the motor nucleus of the facial nerve. Interestingly, the superior part of the facial nucleus receives supranuclear fibres from both of the cerebral hemispheres, while the inferior half of the nucleus receives only crossed fibres from the opposite cerebral hemisphere (Figure 1.43). Thus, upper motor neuron lesions of the facial nerve will relatively spare the upper half of the face as the upper half has bilateral representation. The secretomotor fibres originate from the superior salivatory nucleus and the taste fibres relay in the nucleus of tractus solitarius.



**Figure 1.43**

Facial nerve and the supranuclear connections

### 1.6.1.1 Course of facial nerve

#### Intracranial part

Motor fibres take origin from the motor nucleus, loop around the VI<sup>th</sup> nerve nucleus, and leave at the pontomedullary junction. The sensory root of the facial nerve is called the nervus intermedius or nerve of Wrisberg and leaves separately, to be joined with the facial nerve later. At this point the facial nerve is located at the cerebello-pontine angle and travels towards the internal auditory meatus. The length of this segment in adults is around 15 mm.

#### Intratemporal part

The facial nerve enters the temporal bone through the internal auditory meatus (IAM) and exits through the stylomastoid foramen. Thus, it has a long course through the temporal bone, and is enclosed in a bony canal called the Fallopius canal (after Gabriele Fallopius, one of the most important anatomists and physicians of the XVI<sup>th</sup> century). This part of the facial nerve is vital for otologic surgeries and to prevent facial nerve damage while operating on the temporal bone. The course is divided into four parts (Figure 1.44).

*Meatal segment:* within the internal auditory canal (IAC), from the meatus (medially) to the fundus of the canal (laterally).

*Labyrinthine segment:* from the fundus of the IAC to the geniculate ganglion. It is a 3–4mm segment; however, the diameter of the nerve is *narrowest* here (0.61–0.68 mm) and so is the bony canal. Thus, this is the segment that is affected easily if the nerve is inflamed and oedematous. This segment also lacks arterial anastomosis, thus making the nerve vulnerable to ischaemia.

*Tympanic/horizontal segment:* from the geniculate ganglion to the pyramidal eminence. This segment is related to the medial wall of the middle ear. It lies above the oval window and below the lateral semicircular canal.

*Vertical/mastoid segment:* from the pyramidal eminence to the stylomastoid foramen, where it exits. This segment is related to the posterior wall of the middle ear and mastoid and, therefore, the nerve is at risk during mastoid surgery.

Along this course, the nerve has two bends or genu. The *first genu* (site for the geniculate ganglion) is between the labyrinthine and the tympanic segment. This is a sharp bend posteriorly and has an angulation of 60–75 degrees. The *second genu* is between the tympanic and mastoid segments, where the nerve gradually bends inferiorly over a 120-degree angle.

---

#### Branches of facial nerve and topodiagnostic tests

*Greater superficial petrosal nerve:* arises from the geniculate ganglion and supplies the lacrimal gland and nasal glands.

*Nerve to stapedius:* arises at the level of the 2<sup>nd</sup> genu and supplies the stapedius muscle.

*Chorda tympani:* arises from the vertical segment, approximately 6 mm proximal to the stylomastoid foramen. It carries taste from the anterior two thirds of the tongue and secretomotor to submandibular and sublingual salivary glands.

*Communication to auricular branch of vagus nerve*

*Cutaneous branch:* arises as it exits from the stylomastoid foramen and supplies the posterior wall of the external auditory canal.

*Posterior auricular nerve:* supplies the muscles of the pinna and occipital belly of occipitofrontalis.

*Muscular branches:* supplies the stylohyoid and posterior belly of digastric.

*Terminal branches:* are within the parotid gland. The nerve usually divides into upper temporofacial and lower cervicofacial divisions, which further branch into temporal, zygomatic, buccal, marginal mandibular and cervical branches. This terminal part is called pes anserinus (goose foot) due to its appearance.

The clinical significance of knowing the branches of the facial nerve is to be able to locate the level of injury or damage in facial nerve paralysis. As the branches arise from different levels, if some are spared while others are paralysed, we can easily determine the level of injury. These are called topodiagnostic tests, which are:

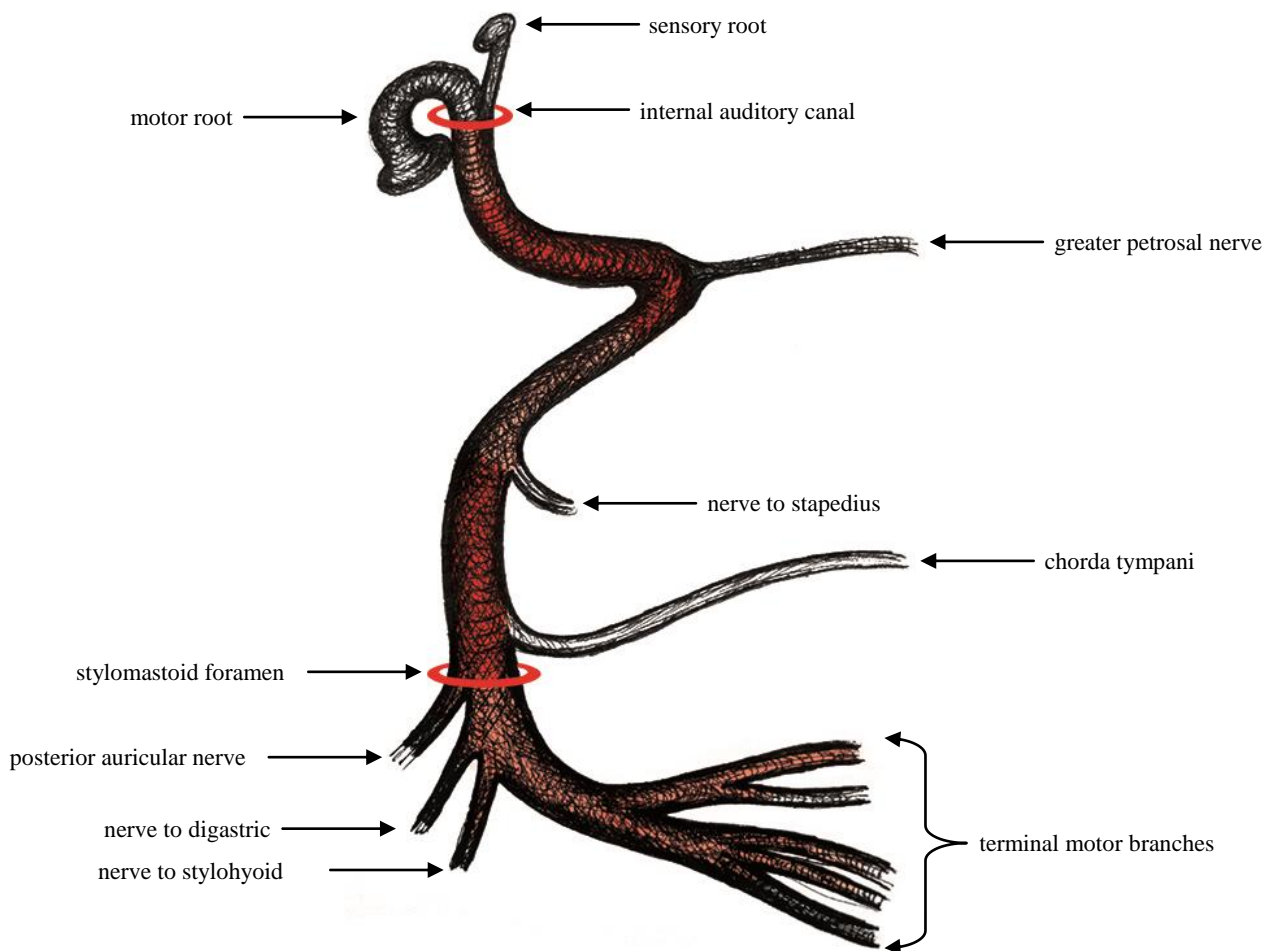
*Schirmer eye test:* This compares the lacrimation in both eyes. A strip of filter paper is put in the inferior fornix and the lacrimation is measured. Reduced lacrimation implies involvement of the greater superficial petrosal nerve, thus placing the lesion proximal to geniculate ganglion.

*Stapedial reflex* can be tested by tympanometry. It requires a functioning stapedius muscle; thus, the loss of stapedial reflex implies involvement of the nerve to the stapedius muscle. Normal lacrimation but a loss of stapedial reflex place the lesion between the geniculate ganglion and second genu.

*Taste sensation* is carried by the chorda tympani. Impaired taste on one side implies involvement of chorda tympani, again helping to note the level of the lesion. It can be tested by applying sweet, salty, sour and bitter substances in increasing concentrations to a protruded tongue or by electrogustometry.

*Submandibular salivary flow test:* This also measures the function of the chorda tympani nerve.

---



**Figure 1.44**

Facial nerve

### 1.6.1.2 Surgical landmarks to identify facial nerve

#### *During middle ear and mastoid operations*

**Processus cochleariformis:** this is a very robust landmark and is not easily destroyed by cholesteatoma or other destructive processes. This is a pointer to the beginning of the tympanic segment of the facial nerve.

**Oval window and lateral semicircular canal:** mark the posterior part of the tympanic segment, near its termination. The nerve is located above the oval window and below the lateral semicircular canal.

**Fossa incudis and short process of incus:** the second genu of the nerve is medial to the short process of incus at the region of aditus.

**Pyramidal eminence:** marks the beginning of the mastoid segment of the facial nerve. The nerve is postero-medial to the pyramid.

**Digastric ridge:** encountered during mastoidectomy and points to the inferior aspect of the mastoid segment of the facial nerve.

#### *During parotid surgery*

**Tragal pointer (of Conley):** this is a triangular extension of tragal cartilage and the nerve usually lies 1 cm deep and anterior to it.

The tympanomastoid suture can be followed towards the stylomastoid foramen leading to the nerve.

The styloid process can be exposed and the nerve will be lateral to it.

The posterior belly of the digastric muscle can be identified and traced backwards, towards the mastoid tip. The muscle crosses the sternocleidomastoid muscle 1 cm inferior and 1 cm lateral to the facial nerve.

Any peripheral branch can be identified and followed back to the main trunk. Gentle manipulation with the nerve is paramount in order to avoid its functional damage. This is often called retrograde identification of the facial nerve trunk. In exceptional cases, the mastoid can be drilled to identify the facial nerve.

Most surgeons will often use a combination of landmarks as the position of some neoplasms may impair a single approach.

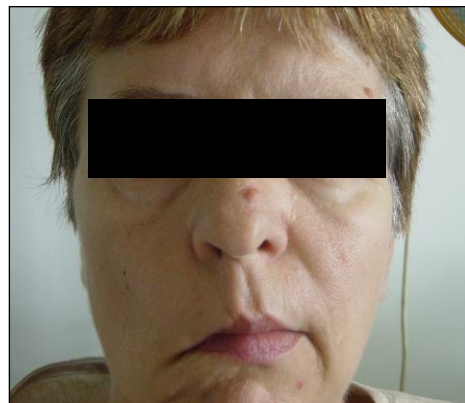### 1.6.2 Facial nerve paralysis

Facial nerve paralysis results in weakness of one half of the face, causing disfigurement (Figure 1.45). The grade of paralysis can be variable and the most common and widely used validated classification is by House and Brackmann (Table 1.10).

*Aetiology.* The cause of this type of paralysis, however, can be varied. Very commonly, facial palsy is idiopathic and is termed as Bell's palsy. There is, however, evidence to suggest that most idiopathic palsies are caused by a viral infection. If herpes zoster is identified, it is termed as Ramsay Hunt syndrome (facial palsy, vesicles, otalgia). Occasionally an ENT surgeon will come across damage to the facial nerve caused by trauma: either iatrogenic (mastoid or parotid surgery) or temporal bone fractures. Neoplasms, either benign or malignant (parotid, external and middle ear malignancies, glomus tumours, facial neuroma, CP angle tumours), may present with a facial palsy. Detailed discussion of all causes is beyond the scope of this textbook; therefore, a list of causes with a description of common pathologies is in Table 1.11.

**Table 1.10** House–Brackmann grading system of facial nerve paralysis (1985)

Grade	Definition
<b>I</b>	Normal symmetrical function in all areas
<b>II</b>	Slight weakness noticeable only on close inspection Complete eye closure with minimal effort Slight asymmetry of smile with maximal effort Synkinesis barely noticeable, contracture, or spasm absent
<b>III</b>	Obvious weakness, but not disfiguring May not be able to lift eyebrow Complete eye closure and strong but asymmetrical mouth movement with maximal effort Obvious, but no disfiguring synkinesis, mass movement or spasm
<b>IV</b>	Obvious disfiguring weakness Inability to lift brow Incomplete eye closure and asymmetry of mouth with maximal effort Severe synkinesis, mass movement, spasm
<b>V</b>	Motion barely perceptible Incomplete eye closure, slight movement of corner mouth Synkinesis, contracture, and spasm usually absent
<b>VI</b>	No movement, loss of tone, no synkinesis, contracture, or spasm



**Figure 1.45**

Facial nerve palsy, right

**Table 1.11** Causes of facial nerve paralysis

Level of lesion	Causes
Central (supranuclear and nuclear)	Lacunar infarcts of internal capsule Pontine infarcts Encephalitis Brain abscess Multiple sclerosis Opercular syndrome
Intracranial part of facial nerve (CP angle)	Facial nerve neuroma Meningioma Congenital cholesteatoma Acoustic neuroma Metastasis Meningitis Fractures of the skull base
Intratemporal facial nerve	Bell's palsy Herpes zoster oticus/Ramsay Hunt syndrome Acute and chronic otitis media Mastoiditis Cholesteatoma Malignant otitis externa Fractures of the temporal bone Surgery such as mastoidectomy and labyrinthectomy Neoplasms such as glomus tumours, external and middle ear malignancies, metastasis Melkersson syndrome
Extracranial	Parotid malignancies Parotid surgery Accidental injuries
Systemic diseases affecting the facial nerve	Diabetes mellitus Sarcoidosis Granulomatosis with polyangitis (Wegener's granulomatosis) Tuberculosis and syphilis Lyme disease Botulinum toxin Hypo/hyper-thyroidism Uraemia
At birth	Birth trauma (forceps delivery) Mobius syndrome Hypotonic infant (hypotonica dystrophica)

### 1.6.3 Bell's palsy

*Definition.* The most common cause of facial nerve paralysis worldwide is Bell's palsy. It causes 60–75% of all facial paralysis and is the most common neurological disorder affecting cranial nerves. It is of an acute onset, peripheral, lower motor neuron facial nerve paralysis. The incidence increases with age and has a positive family history in 4% of patients. Recovery is complete in 80–90% of patients.

*Aetiology.* Several causative agents have been associated with its aetiology. *Herpes simplex virus* is increasingly believed to be responsible for this. The initial infection affecting the lips allows the virus to enter the neurons and then reside in the geniculate ganglion. At times of stress, viral reactivation may cause loss of myelin and temporary paralysis of the facial nerve. Other viral aetiologies postulated include herpes zoster (Ramsay-Hunt syndrome) and Epstein-Barr virus. *Vascular ischaemia* has a role in the pathophysiology as well. Inflammation and oedema of the nerve give rise to increased pressure in the bony Fallopian canal (especially at the narrow labyrinthine segment) and further ischaemia. Besides these, borrelia infection, *autoimmune reaction*, microvascular disease or inflammation all are postulated causes of Bell's palsy.

*Clinical features.* A patient presents with an *acute onset* (over a 48-hour period) weakness of upper and lower parts of one half of the face. Progression over the initial few days is common, however, the weakness does not progress beyond 7–10 days. If paresis is progressive, other causes should be sought after. Symptoms include:

- Flattening of forehead and nasolabial fold on the side affected
- Inability to raise the eyebrow on the affected side
- When the patient smiles, face deviates to the normal side
- Poor eyelid closure
- Posterior auricular pain/ear pain may precede the weakness (60%)
- Epiphora (tearing of eyes)



Some patients may also complain about intolerance to loud sounds (30%), taste disturbances, otalgia, ocular pain, and blurred vision.

*Diagnosis* should focus on ruling out other causes of facial paralysis. Examination should include the ear, oral cavity, oropharynx, parotid gland and neck. A thorough ophthalmologic and neurological examination including all cranial nerves should be performed. Facial weakness should be graded according to the House–Brackmann grading system. Bell’s palsy is a diagnosis of exclusion. If the clinical picture fits and other causes have been ruled out clinically, a diagnosis of Bell’s palsy is made. The patient can then be reassured as most (80–90%) will recover completely.

*Treatment.* A patient should be started on medical treatment if seen within 72 hours. Eye care should be administered and close follow-up should be in place.

*Oral steroids* increase the chances of complete recovery and should be started within 72 hours to be beneficial. It can be given for a total of 10 days, being stopped gradually after tapering off the dose. Prednisolone 1 mg/kg in divided doses is usually started and then tapered off by the 10<sup>th</sup> day. Caution is required in elderly patients and in hypertensive, diabetic and peptic ulcer patients. All patients are briefed about the side effects of steroids. Antivirals (acyclovir) are often used along with steroids.

Various non-pharmacological treatments, e.g. facial exercises, relaxation, neuromuscular retraining and acupuncture, have been used as well. They have no side effects and have been proven to hasten recovery.

Patients are advised to protect the eye, as exposure keratitis and corneal ulceration can develop. Patients who do not recover completely may require plastic surgery, botulinum toxin injections, surgical eye procedures to prevent exposure keratitis, and other non-pharmacological treatments. 80–90% of patients do recover without

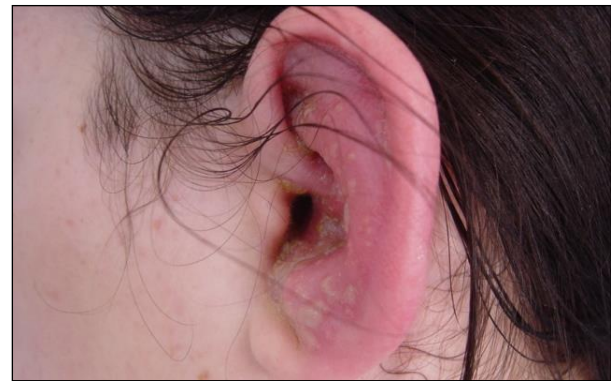any detectable residual weakness. Recovery usually starts by 3 weeks and may take months to complete.

#### 1.6.4 Herpes zoster oticus (Ramsay-Hunt syndrome)

*Definition and aetiology.* This is a viral infection caused by herpes zoster virus, resulting in facial nerve paralysis. It accounts for 10–12% of all facial paralysis.

*Clinical features.* The symptoms are more severe than Bell’s palsy and the prognosis is worse. At best, only 60% of patients recover completely. Most patients are left with residual weakness.

Clinically, there is a burning pain in and around the ear, along with vesicular rash in the ear canal and pinna (Figure 1.46 Herpes zoster oticus). The rash may also be present on the side of the face and in the hard/soft palate and posterior pharyngeal wall. There is facial palsy along with this. Dizziness, tinnitus and hearing loss may also be part of the clinical picture.



**Figure 1.46**

Herpes zoster oticus

*Management* is similar to that of Bell’s palsy. Antiviral (acyclovir 400–800 mg, five times daily) is important in this situation and should be almost always given.



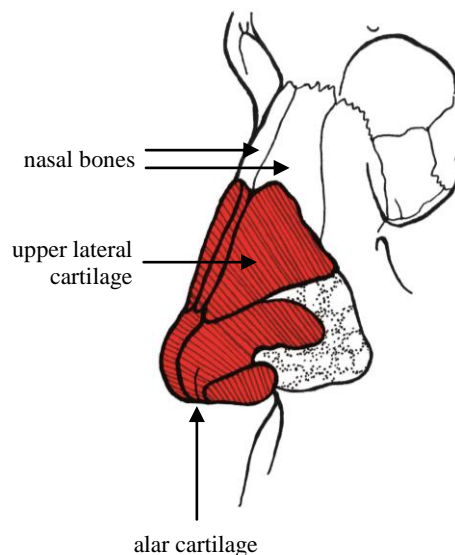
## 2 NOSE AND PARANASAL SINUSES

### 2.1 APPLIED ANATOMY

#### External nose

The external nose is shaped like a pyramid with its root superiorly and base directed inferiorly. The skeleton of the nose is composed of bone and cartilage. The upper third consists of nasal bones, nasal processes of the frontal bone, and the frontal processes of the maxilla. The lower two thirds are composed of upper lateral cartilages, lower lateral cartilages (major alar cartilage), lesser cartilages (sesamoid cartilages) and septal cartilage (Figure 2.1). This framework is covered with skin, which is very thin and freely mobile over the nasal bones and upper lateral cartilage, while that on the alar cartilage is thicker, more adherent and contains sebaceous glands.

The blood supply consists of branches of the ophthalmic and maxillary arteries. The skin of the ala and septum is supplied by the facial artery.



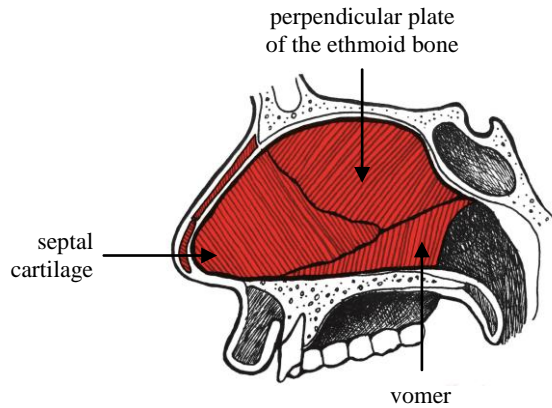
**Figure 2.1**  
External nose

Nerve supply to the external nose is provided by the infratrochlear and external nasal branches of the ophthalmic nerve and the infraorbital branch of the maxillary nerve, both of which are part of the trigeminal nerve.

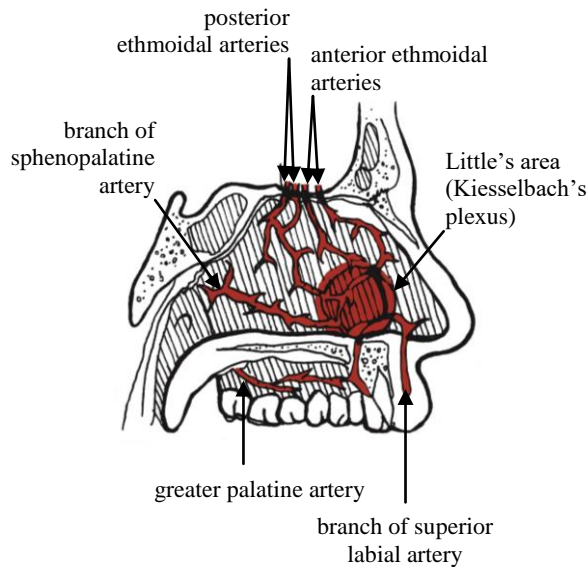
#### Nasal cavity

The nasal cavity is divided into two chambers by the nasal septum. Each cavity consists of a vestibule, which is lined with skin (containing hairs/vibrissae and sebaceous glands), and the true nasal cavity (lined with mucosa). The strip of skin running from the tip of the nose to the upper lip, which separates the nostrils, is called the columella. The narrowest part of the nasal cavity is the internal nasal valve (limen nasi). The true nasal cavity extends from the nasal valve to the choana. The true nasal cavity is bounded by the lateral wall, medial wall, roof and a floor. The floor consists of the palatine process of the maxilla and the horizontal plate of the palatine bone. The roof is formed by the nasal bones in the anterior part, the cribriform plate of ethmoid in the middle horizontal part, and by the body of sphenoid in the posterior part. The medial wall is the nasal septum. It is formed by the perpendicular plate of the ethmoid bone, the vomer, cartilage, and the nasal crests of the maxillary and palatine bones (Figure 2.2). The covering of the septum is called the mucoperichondrium when it overlies cartilage and mucoperiosteum when it overlies the bony component of the septum. The mucosa of the septum has a rich blood supply. In the antero-inferior part of the nasal septum there is Little's area, four arteries anastomose here to form Kiesselbach's plexus, the most common source of epistaxis (Figure 2.3).

The region is supplied by the anterior and posterior ethmoidal arteries, branches of the ophthalmic artery (internal carotid). Sphenopalatine, greater palatine and superior labial are branches of facial artery (external carotid).



**Figure 2.2**  
Nasal septum

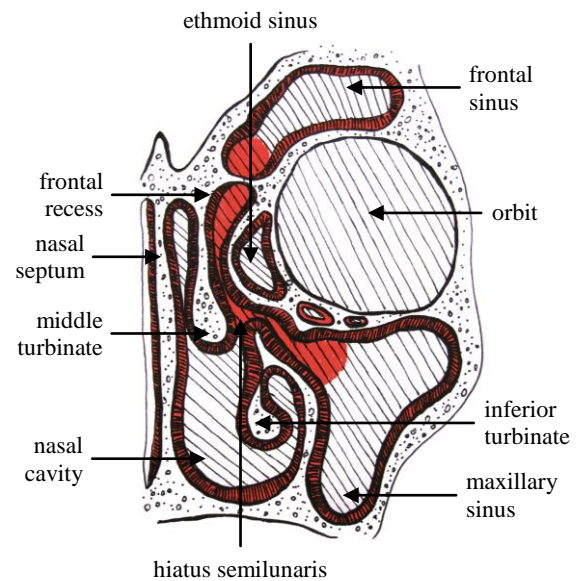


**Figure 2.3**  
Nasal septum – blood supply

### Lateral wall of the nasal cavity

The most prominent features of the lateral nasal wall are three bony projections called *turbinates* or *conchae-superior* (part of ethmoid), *middle* (part of ethmoid) and *inferior* (separate bone). They divide the nasal cavity into four passages that have openings to the paranasal sinuses. *The inferior meatus* is present between the inferior turbinate and the lateral nasal wall. The nasal

opening of the naso-lacrimal duct is located in the anterior third of the inferior meatus. *The middle meatus* lies between the middle turbinate and the lateral nasal wall. Under the middle turbinate drain lies the anterior group of sinuses: frontal, maxillary and anterior ethmoidal sinuses. Parts of the middle meatus are also the following structures: bulla ethmoidalis, processus uncinatus and hiatus semilunaris, and ethmoidal infundibulum (funnel-shaped passage through which the secretions from the anterior ethmoid cells and maxillary sinuses are transported into the middle meatus). The hiatus semilunaris is the location of the openings for the sinuses. *The superior meatus* lies between the superior and middle turbinates and has openings to the posterior ethmoidal sinuses. *The sphenoethmoid recess* lies posterior to the superior concha and has the opening for the sphenoidal sinus (Figure 2.4).



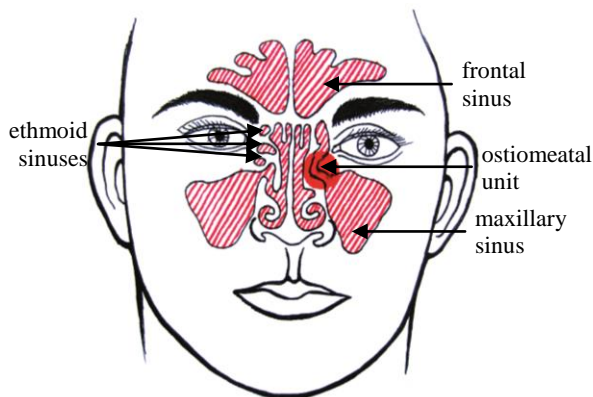
**Figure 2.4**  
Lateral wall of nasal cavity, osteomeatal unit (red)

Anatomy of *the lateral nasal wall* is highly complex and variable. The lateral wall contains several structures that are important in the function of the nose, so the understanding of its anatomy and physiology is paramount.

The nasal cavity is lined with two types of epithelium: olfactory and respiratory. The mucosa over the superior one third of the nasal cavity is the olfactory area. The olfactory nerves pass through the cribriform plate of the ethmoid bone. The respiratory part is lined with ciliated pseudo-stratified columnar epithelium (also called respiratory epithelium). The turbinates are located in this region. The respiratory portion has a vascularised lamina propria allowing the venous plexuses of the mucosa of the turbinates to engorge with blood, restricting airflow and causing air to be directed to the other side of the nose. This happens on a regular basis known as the nasal cycle.

### Paranasal sinuses

The paranasal sinuses are four pairs of air-filled cavities situated at the entrance of the upper airway. Each of these sinuses is named after the skull bone in which it is located. They are described in four pairs: frontal, ethmoid, maxillary and sphenoid (Figure 2.5). Each of these is in direct communication with the nasal cavity through their ostia. The mucosa of the sinuses is similar to the rest of the nasal cavity and respiratory tract. Ciliary transport is important in clearing secretions from the sinuses into the nasal cavity.



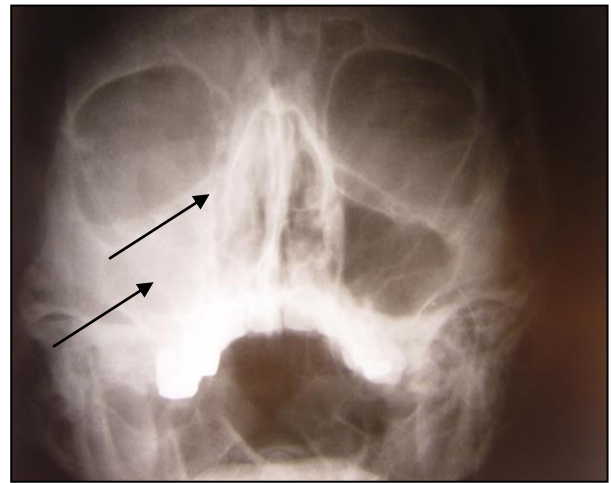
**Figure 2.5**

Paranasal sinuses – frontal view

The largest of the sinuses is the **maxillary sinus** (antrum of Highmore) with an average size of

15 ml. The roof of the maxillary sinus is the floor of the orbit. The infraorbital nerve runs through the infraorbital canal along the roof of the sinus and sends its sensory branches to the soft tissues of the cheek. It is the first sinus to develop and is filled with fluid at birth. The natural ostium of the maxillary sinus is located in the superior portion of the medial wall in the middle meatus, so the sinus, so the sinus drains against gravity.

The **frontal sinus** is the second-largest sinus with an average capacity of 4–7 ml. It is located in the frontal bone superior to the eyes in the forehead. It is paired, but is often asymmetrical, and varies in form and extent. The posterior wall of the frontal sinus, which separates the sinus from the anterior cranial fossa, is much thinner than its anterior wall. The frontal sinuses develop after birth. The growth of this sinus increases at the age of 6 and is only completely formed in the second decade of life. The frontal sinus drains into the middle meatus (Figure 2.6).



**Figure 2.6**

Paranasal sinuses – right pansinusitis; plain radiograph, Waters' view

The **ethmoid sinuses** are referred to as the ethmoidal labyrinth because of their complexity. The ethmoid sinuses arise in the ethmoid bone. They consist of numerous small cavities called ethmoid air cells. In adults, 8–12 ethmoid cells may be present. The ethmoid sinuses are divided



into anterior and posterior air cells. A thin sheet of bone — ‘lamina papyracea’ — separates these sinuses from the orbit; it is a common site of inflammatory orbital complication of ethmoid sinusitis. The anterior ethmoid air cells open into the middle meatus and the posterior ethmoid air cells open into the superior meatus.

The **sphenoid sinus** is the most posterior of the sinuses; it is located in the body of the sphenoid bone. Its superior aspect is related to the pituitary gland (and the optic nerves and chiasma), and laterally to the cavernous sinus and internal carotid artery. The sphenoid sinus drains into the sphenoid recess superior to the superior turbinate.

The **osteomeatal complex** is a functional entity in the anterior ethmoid complex that represents the final common pathway for drainage and ventilation of the frontal, maxillary, and anterior ethmoid cells. Any or all cells, clefts, and ostia, as well as their dependent sinuses, can become diseased, contributing to the symptoms and pathophysiology of sinusitis.

The nasal cavity and sinuses are supplied by branches of the external carotid (maxillary artery, sphenopalatine artery) and internal carotid (ophthalmic artery, ethmoid arteries) and their accompanying veins. The sensory innervation is provided by branches of the first and second divisions of the trigeminal nerve.

## 2.2 PHYSIOLOGY

### Function of the nose

The nose has several functions:

**Respiratory function** – it provides an airway for respiration, filtration, humidification of the inspired air, and adjusts the temperature of the inspired air. The nasal cavity contains a convoluted set of passageways called the turbinates on the lateral wall of each nasal cavity; these turbinates interrupt the flow of air into the

nasal passage, forcing it through narrow passages that are covered with moist nasal respiratory mucosa. The air is heated (or cooled) by radiation from the mucosal blood vessels. Humidification occurs by evaporation from the mucous blanket. The inspired air is a near-normal body temperature and the relative humidity is near 100%. The average ventilation through a normal nose is 6 l/minute in normal breathing and can reach 70 l/minute in maximal ventilation.

**Olfactory function** – inspired air is brought high into the nasal cavity to come into contact with the olfactory nerves. This provides the sense of smell, which is intimately associated with the taste sensation. The nerve endings responsible for smell (olfaction) are found in the nasal mucosa in the superior aspect of the nasal cavities.

**Vocal resonance** – the nose influences the sound of speech, providing the voice with a resonant quality.

**Protective function** – it is the primary organ for filtering particles in inspired air, and it also serves to provide first-line immunologic defense. The combination of the secretory film and the cilia of the respiratory epithelium by which the colloidal secretory film is transported is called mucociliary apparatus.

**Ventilation and drainage of sinuses** – ostium patency and sinus ventilation play a key role in the normal function of the sinuses.

**Nose as a reflex organ** – the nasal cycle duration is approximately four hours, during which the lumen in each half of the nose narrows and widens alternately.

### Function of the sinuses

The exact function of sinuses remains uncertain. Several reasons have been postulated for their existence, but none have been proven:

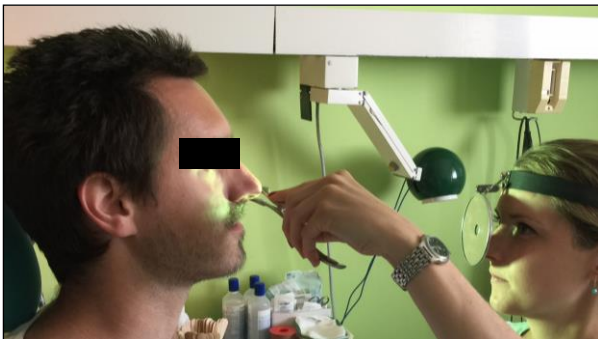- to reduce the weight of the skull;
- to increase the resonance of the voice;
- to protect the eye and brain from physical trauma;
- to separate the nasal cavity and brain as a protection of the brain from cooling from nasal airflow.

The pathophysiologic problems are caused by ostial obstruction affecting ventilation and drainage. In such a case the secretions stagnate in the sinus and they change in composition and become an ideal medium for bacteria. It often results in a vicious circle, which can be broken by dealing with the causal factors with appropriate treatment. The causal factors can be environmental (toxic gases,) or local anomalies and pathologies (septal deviation, infection,). Each of the sinuses is closely related to important structures (orbit, anterior skull base, cavernous sinus); which can become involved secondarily in diseases that affect the sinuses.

## 2.3 EVALUATION

**History, inspection and palpation** must be carried out. The otolaryngologist must pay attention to:

- changes of the skin: colour, scars, irregularities, asymmetries
- changes of the shape of the nose: congenital or acquired deformities
- crepitation and mobility of the nasal bones
- movement of nasal alae during respiration
- inspection of nasal vestibule: elevation of nasal tip
- sensitivity of trigeminal nerve branches
- palpation sensitivity: forehead, cheek

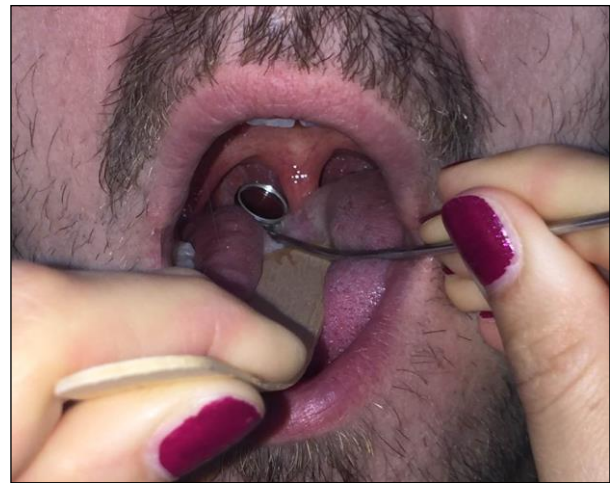

**Figure 2.7**  
Anterior rhinoscopy

**Anterior rhinoscopy** is a procedure to examine the anterior portions of the nasal cavity. A good light source, head mirror or a head light and nasal speculum are used (Figure 2.7). Each area of the nasal cavity should be examined (septum, floor of the nose, lateral wall with turbinates) and one

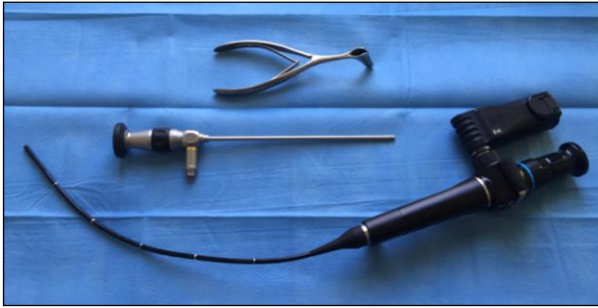
should note the appearance of nasal mucosa (colour, swelling, surface, and hydration), nasal secretions (colour, quantity, properties), presence of abnormal tissue, foreign bodies, bleeding, etc.

**Posterior rhinoscopy** is used to examine the posterior part of the nasal cavity (Figure 2.8). This method is challenging, requiring cooperation of the patient. Choana, posterior parts of the turbinates and septum, nasal polyps, secretions, tumours, obstruction of the nasopharynx (adenoids, tumour), and the shape of the Eustachian tube ostia should be noted.



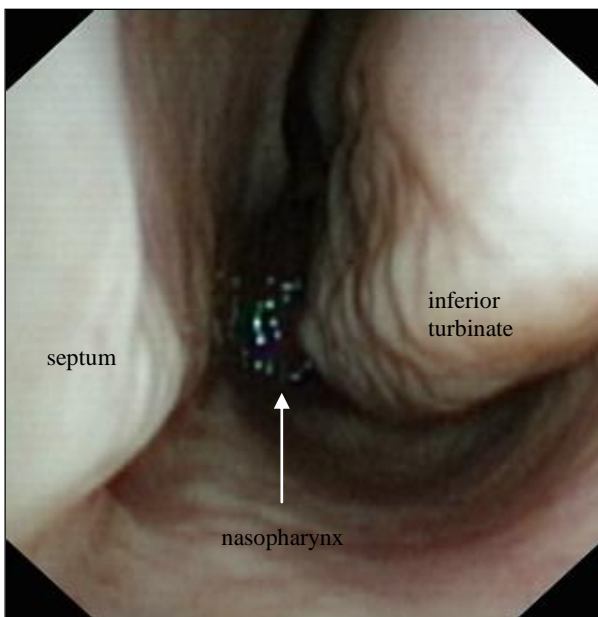
**Figure 2.8**  
Posterior rhinoscopy

**Nasal endoscopy** serves as an objective diagnostic tool in the evaluation of nasal mucosa, sinonasal anatomy, and nasal pathology. Nasal endoscopy may be accomplished with either a *flexible fiberoptic endoscope* or a *rigid endoscope* (Figure 2.9). The fiberoptic telescope has the advantage of being flexible and small in diameter, which means that it is readily manipulated in multiple directions to permit visualisation of tight areas. However, flexible endoscopy requires two hands for manipulation of the instrument. Rigid endoscopes for the nose come in diameters of 2.7–4 mm and have tips of different angles (generally 0–70°), allowing the physician to visualise the ostia of various sinuses and areas within the nasal cavity.



**Figure 2.9a**

Nasal endoscopy – nasal speculum, rigid and flexible endoscopes

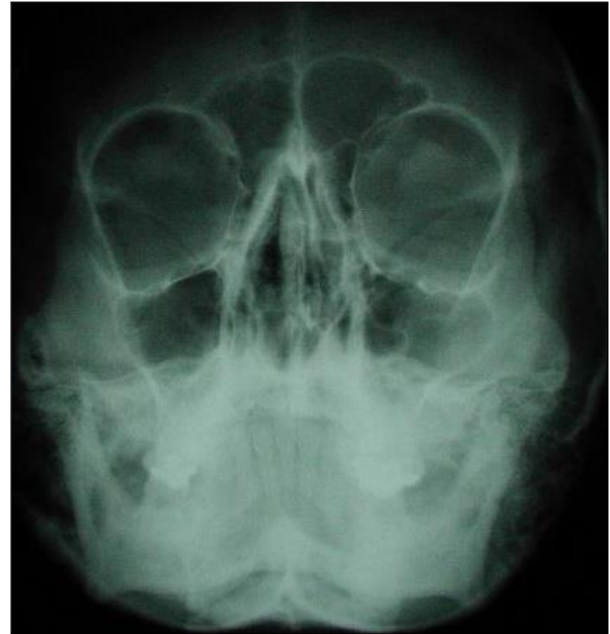

**Figure 2.9b**

Nasal endoscopy –endoscopic view

### Imaging

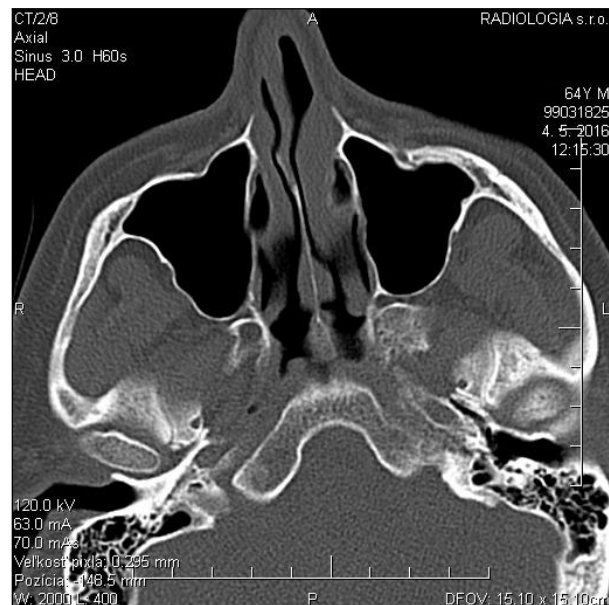
The plain X-ray is inexpensive, fast and gives a fair survey of the region under consideration. Historically, it was the mainstay of diagnosis of sinus disease. The lateral view is still requested following facial trauma to show fractures of the nasal bones as well as lateral shifts and displacements (Figure 2.10). Chronic or recurrent sinusitis, trauma, neoplastic disease, and malformations require more sophisticated imaging techniques.



**Figure 2.10**

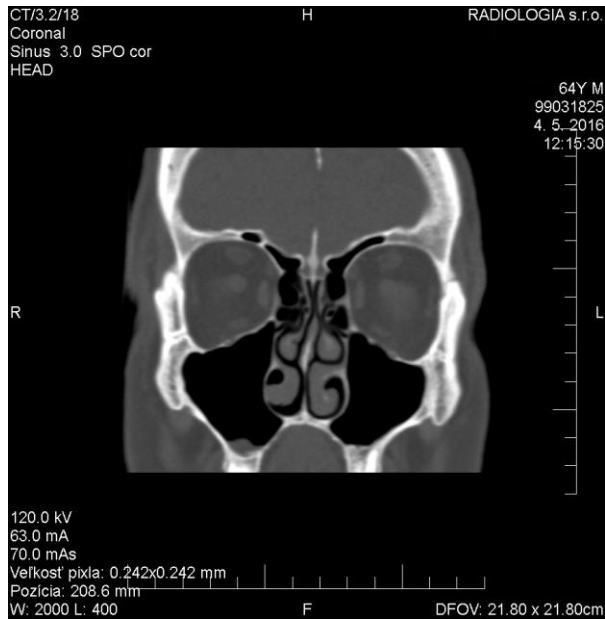
Normal facial skeleton; plain radiograph, postero-anterior view

Acute sinusitis is a clinical, not a radiological, diagnosis.

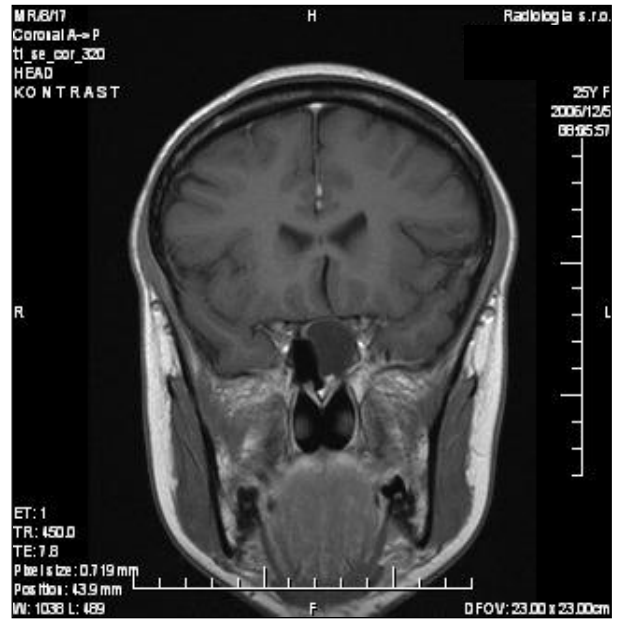

**Figure 2.11a**

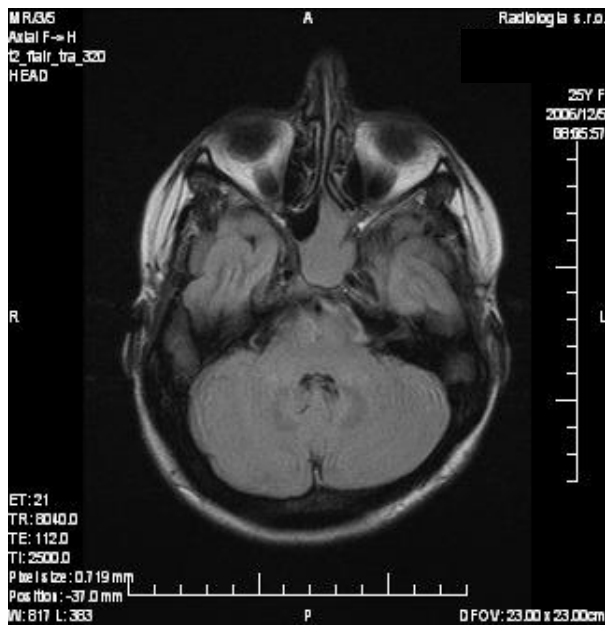
Normal paranasal sinuses; CT scan, axial plane



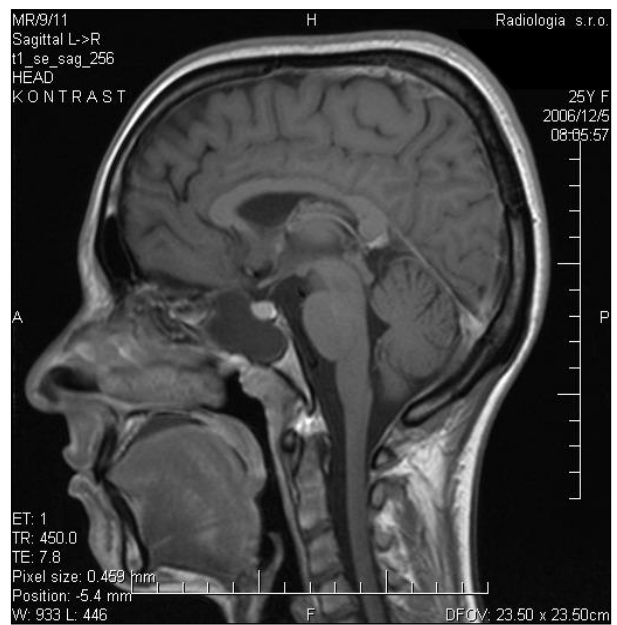**Figure 2.11b**  
Normal paranasal sinuses;  
CT scan, coronal plane



**Figure 2.12b**  
Left sphenoid sinus cyst;  
MRI scan, coronal plane



**Figure 2.12a**  
Left sphenoid sinus cyst;  
MRI scan, axial plane



**Figure 2.12c**  
Left sphenoid sinus cyst;  
MRI scan, sagittal plane



*Computerised tomography (CT)* is the best means of imaging the sinuses. CT (axial, coronal view) shows the complex 3D anatomy, the extent of disease, and the wide range of anatomic normal variations (Figure 2.11). Sinus CT shows excellent anatomical soft tissue and bony details for safe surgery.

*Magnetic resonance imaging (MRI)* is necessary in selected cases. Its superb soft-tissue contrast makes it an ideal tool for searching for mucocoeles, the delineation of tumours, and the degree of involvement of neural structures in malformations (Figure 2.12).

Before planned interventions on a malignant tumour of the sinuses/anterior skull base, both CT (bony details) and MRI (fine details of tumour margins and dura/brain involvement) scans are necessary.

#### **Diagnostics of olfactory disorders**

Quantitative measurement of dysfunctions of smell and taste is particularly important when chemosensory dysfunction is the primary symptom. The major goal of sensory testing is to assess the degree of dysfunction. Clinical testing can be time-consuming and difficult to perform precisely; it is done rarely in a standard clinical setting. Tests may include smelling of various concentrations of odours. Olfactory-evoked response has been used in research setup along with odour identification tests to evaluate aberrant olfaction in relation to neurologic disease.

## **2.4 DISEASES OF THE NOSE AND PARANASAL SINUSES**

### **2.4.1 Inflammatory diseases**

#### **Inflammatory diseases of the external nose**

Skin of the external nose can be affected by numerous typical skin diseases such as impetigo, acne, rosacea, lupus erythematosus or trichophyton. These are treated by appropriate dermatologic methods. Some diseases have a particular importance in the area of the external nose.

#### **Nasal eczematous dermatitis**

Acute lesions are composed of small vesicles that usually reside on red, swollen skin. When these vesicles break, fluid leaks out, causing characteristic weeping and oozing. Later, crusts and painful rhagades form. The nasal mucosa is never affected. Eczematous dermatitis has many causes, the most common being abnormal nasal secretions and atopic dermatitis.

*Treatment* includes anti-inflammatory medications and steroid creams. Antibiotics may clear the infection in the skin.

#### **Folliculitis and furunculitis of nasal vestibule**

*Definition.* Folliculitis is the presence of inflammation (staphylococcal infection) within the wall and ostia of the hair follicle, creating a follicular-based pustule.

*Clinical features.* Typical symptoms include pain and sensitivity to pressure, followed by redness and swelling of the tip of the nose and/or nasal ala and the upper lip.

*Treatment* consists of local antibiotic creams if a furuncle is forming — oral or i.v. antibiotics are administered.

A furuncle of the nose must never be squeezed because of the danger of intracranial complications such as thrombophlebitis and cavernous sinus thrombosis.

#### **Erysipelas**

Erysipelas is caused by streptococcus infection of the facial skin. It typically begins with fever and chills. There is a closely demarcated redness and swelling of the affected skin in a butterfly shape.

*Treatment.* Penicillin is sufficient for most cases and should be given for 10–20 days.

#### **Inflammatory diseases localised in the nasal cavity**

Sinusitis, or rhinosinusitis, is defined as inflammation of the paranasal sinuses and nasal cavity. The term “rhinosinusitis” is preferred because sinusitis is typically associated with inflammation of the nasal mucosa. Rhinosinusitis

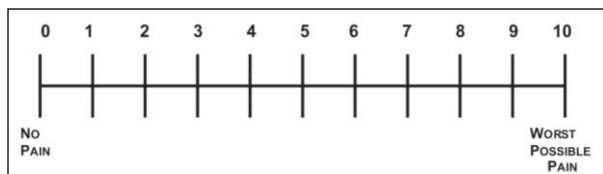


can be categorised based on the causative organism. The majority of cases are viral in origin, but a small minority are caused by bacterial and/or fungal pathogens.

Based on the *European Position Paper on Rhinosinusitis and Nasal Polyps 2012*, rhinosinusitis is generally defined as inflammation of the mucosa of the nose and paranasal sinuses. It is characterised by two or more symptoms:

- One of them should be either *nasal blockage* (obstruction, congestion) or *nasal discharge in adults* (anterior or posterior nasal drip), respectively, or a *cough in children*.
- Another symptom is *facial pain* (pressure) and/or *reduction (loss) of smell*.

An endoscopic sign of *polyps* or *mucopurulent discharge* primarily from the middle meatus and/or *oedema* (mucosal obstruction) primarily in the middle meatus must be present. On CT imaging, mucosal changes within the osteomeatal complex and/or sinuses may be present. On the VAS scale (visual analog scale 1–10), rhinosinusitis can be mild, moderate or severe (Figure 2.13).



**Figure 2.13.**

Visual analog pain scale

According to the **length of duration** of the symptoms, rhinosinusitis can be *acute*, lasting more than 10 days and less than 12 weeks with complete resolution of the symptoms. *Chronic rhinosinusitis* lasts more than 12 weeks without complete resolution of the symptoms.

### Acute rhinosinusitis

Acute rhinosinusitis can be divided into several subgroups:

**Common cold/acute rhinosinusitis** with duration of symptoms less than 10 days. This form is normally self-limiting and typically resolves without treatment.

**Acute post-viral rhinosinusitis** (previously named subacute rhinosinusitis) is defined as an increase of symptoms after 10 days with less than 12 weeks of duration. No clinical data exist for the evaluation or treatment of subacute rhinosinusitis, but it is considered to be a self-limiting disease and, as such, no antibiotic treatment is indicated.

Acute post-viral rhinosinusitis is a self-limiting disease and, as such, no antibiotic treatment is indicated.

**Acute bacterial rhinosinusitis** is suggested by the presence of at least three symptoms:

- Discoloured discharge and purulent exsudate in the nasal cavity
- Severe local pain (with unilateral predominance)
- Fever (38°C or higher)
- Elevated erythrocyte sedimentation rate/CRP
- “Double sickening” – deterioration after an initial milder phase of illness

*Aetiology.* Most of the time, bacterial sinusitis follows after a course of viral sinusitis. Typical pathogens include *Streptococcus pneumoniae*, *Haemophilus influenzae*, *Moraxella catarrhalis*, and *Staphylococcus aureus*, with 74% of cases in adult patients caused by the first two bacteria.

*Treatment in adult patients.* Supportive therapy for acute rhinosinusitis includes analgesics/antipyretics for pain and fever, intranasal saline irrigation, short-term use of intranasal steroids, especially in patients with allergic rhinitis, and topical nasal decongestants. Systemic decongestants and antihistamines are no longer recommended.

The following risk factors for antibiotic resistance should be considered for an appropriate choice of antibiotics: age older than 65 years, antibiotic use within the past 1 month, immunocompromised host, and presence of medical comorbidities. Duration of treatment should be 5–10 days or longer for severe infection.

*Treatment in children.* In the paediatric population, a recent Cochrane Review did not show any well-designed studies to determine the

effectiveness of adjuvant therapy such as nasal decongestants, mucolytics, nasal irrigation, and/or antihistamines. Intranasal steroids can be used as an adjunct to antibiotics in the empiric treatment of acute bacterial rhinosinusitis, primarily in patients with a history of allergic rhinitis.

In patients with a severe onset or those with worsening symptoms, antimicrobial therapy is recommended. Duration of treatment should be 7 days after the patient is symptom-free, with a minimum of 10 days of therapy — it should be longer in patients with severe infection.

### Allergic rhinitis

*Definition.* Allergic rhinitis is nasal inflammation caused by allergic reaction to airborne allergens and is an extremely common condition, affecting approximately 20% of the population. Although allergic rhinitis is not a life-threatening condition, complications can occur and the condition can significantly impair quality of life.

*Pathogenesis.* Allergic rhinitis is caused by an allergic reaction to an allergen, such as pollen, dust and certain animals.

### Pathogenesis of allergic rhinitis

Inflammation of the mucous membranes is characterised by a complex interaction of inflammatory mediators, but ultimately is triggered by an immunoglobulin E (IgE)-mediated response to an extrinsic protein. The tendency to develop allergic, or IgE-mediated, reactions to extrinsic allergens has a genetic component. Exposure to certain foreign proteins leads to allergic sensitisation, which is characterised by the production of specific IgE directed against these proteins. This specific IgE coats the surface of mast cells present in the nasal mucosa. When a specific protein (e.g. a specific pollen grain) is inhaled into the nose, it can bind to the IgE on the mast cells, leading to immediate and delayed release of a number of mediators (histamine, tryptase, chymase, kinins, and heparin). The mast cells quickly synthesise other mediators, including leukotrienes and prostaglandin D<sub>2</sub>. These mediators, via various interactions, lead to the symptoms of rhinorrhoea (i.e. nasal congestion, sneezing, itching, redness, tearing, swelling, ear pressure, postnasal drip). Mucous glands are stimulated, leading to increased secretions. Vascular permeability is increased, leading to plasma exudation. Vasodilation occurs, leading to congestion and pressure. Sensory nerves are stimulated, leading to sneezing and itching. All of these events can occur in minutes; thus, this reaction is called the early, or immediate, phase of the reaction. Over 4–8 hours, these mediators, through a complex interplay of events, lead to the recruitment of other inflammatory cells to the mucosa, such as

neutrophils, eosinophils, lymphocytes, and macrophages. This results in continued inflammation, termed the late-phase response. The symptoms of the late-phase response are similar to those of the early phase, but less sneezing and itching and more congestion and mucus production tend to occur. The late phase may persist for hours or days.

*Clinical features.* Most patients develop symptoms by 20 years of age. Patients with allergic rhinitis typically present with rhinorrhoea, sneezing, pruritus, and conjunctivitis. The mucosa of the nasal turbinates may be swollen and have a pale, bluish-grey colour. Some patients may have predominant erythema of the mucosa. Thin, watery secretions are frequently associated with allergic rhinitis, and thick, purulent secretions are usually associated with sinusitis.

Possible complications include otitis media, Eustachian tube dysfunction, acute sinusitis, and chronic sinusitis. Allergic rhinitis can be associated with a number of comorbid conditions, including asthma, atopic dermatitis, and nasal polyps. Allergic rhinitis can lead to significant impairment of quality of life. Symptoms such as fatigue, drowsiness, and malaise can lead to impaired work and school performance, missed school or work days, and traffic accidents.

*Diagnosis* can be made clinically on the basis of a history and rhinoscopic examination and/or skin testing.

*Treatment.* The management of allergic rhinitis consists of three major categories of treatment: environmental control measures and allergen avoidance, pharmacological management (antihistamines, decongestants, intranasal steroids and cromolyns), and immunotherapy.

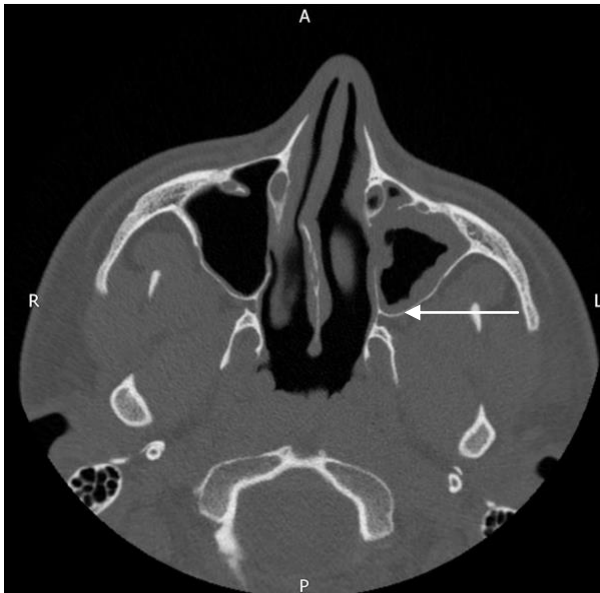*Antihistamines* control rhinorrhoea, sneezing and pruritus. Some antihistamines may cause drowsiness. *Pseudoephedrine* (oral or intranasal) is used to relieve congestion. If overused, it causes severe rebound congestion, leading to rhinitis medicamentosa. *Oral corticosteroids* are very effective in controlling the symptoms of allergic rhinitis but should be used for acute episodes which have not been controlled by other measures. *Intranasal corticosteroids* are very effective in the control of symptoms. They can also be used in the treatment of medicamentous rhinitis.

*Immunotherapy* or hyposensibilisation is used when medicamentous treatment fails to control symptoms or produces intolerable side effects. Allergen is given in gradually increasing doses until the maintenance dose is reached.

### Chronic rhinosinusitis

*Definition.* Chronic sinusitis is an inflammatory process that involves the paranasal sinuses and persists for 12 weeks or longer. Chronic sinusitis is almost always accompanied by concurrent nasal airway inflammation and is often preceded by rhinitis symptoms; thus, the term “chronic rhinosinusitis” more accurately describes this condition.

*Epidemiology.* Prevalence of chronic rhinosinusitis (CRS) in Europe is 11%. CRS is associated with asthma and allergic rhinitis.



**Figure 2.14**

Chronic maxillary sinusitis;  
CT scan, axial plane

*Clinical features.* Main symptoms are nasal obstruction, discharge, hyposmia, cough, congestion and postnasal drip. The daily use of nasal saline rinse leads to fewer periods with sinus-related symptoms and to fewer antibiotics. The minority of patients with so-called **difficult-**

**to-treat rhinosinusitis** might have persistent symptoms of rhinosinusitis despite appropriate maximal treatment (recommended medication and surgery).

*Diagnosis* is supported by the findings of a CT scan (Figure 2.14).

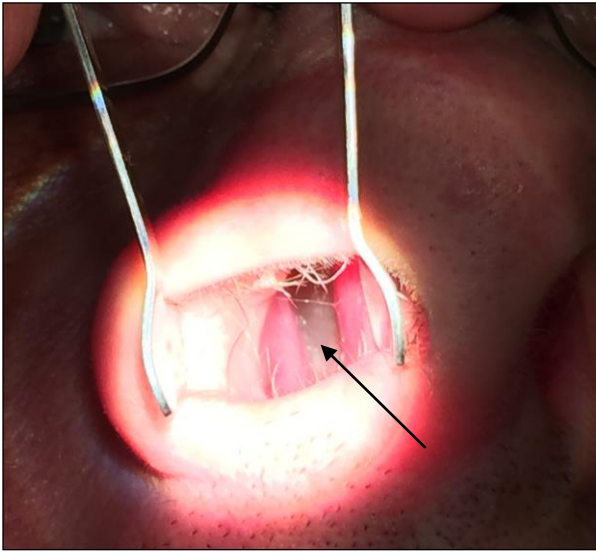
*Treatment.* The goal of treatment is to achieve and maintain clinical control. Control is defined as a disease state in which the patients do not have symptoms or the symptoms are not bothersome; if possible, it is combined with a healthy or almost healthy mucosa, with only the need for local medication. We do not know what percentage of patients with CRS can achieve control of the disease.

Patients who do not reach an acceptable level of control despite adequate surgery, intranasal corticosteroid treatment and up to two short courses of antibiotics or systemic corticosteroids in the last year can be considered to have difficult-to-treat rhinosinusitis.

Surgery is used mainly if the condition does not improve with the medical treatments. The main purpose of surgery is to improve the drainage of the affected sinuses. However, it may be necessary to remove nasal polyps or to correct a deviated nasal septum. The surgical concept is called *functional endoscopic sinus surgery (FESS)*. This involves visualisation of the nasal cavity and sinuses using rigid endoscopy. The surgeon removes any tissues that are blocking the drainage of the affected sinus. This can improve sinus drainage and ventilation and help to restore normal function to the sinuses (see Chapter 10.6).

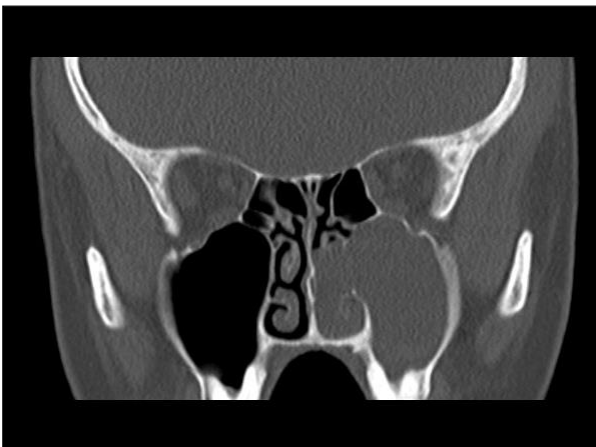### Nasal polyps

*Definition.* Nasal polyps are an end result of varying disease processes in the nasal cavity. Typically, they are benign, semi-transparent nasal lesions that arise from the mucosa of the nasal cavity or from one or more of the paranasal sinuses, often at the outflow tract of the sinuses (Figure 2.15).



**Figure 2.15**

Nasal polyps – right nasal cavity



**Figure 2.16**

Unilateral nasal polyposis, left side;  
CT scan, coronal plane

The *pathogenesis* of nasal polyposis is unknown. Polyp development has been linked to chronic inflammation, autonomic nervous system dysfunction, allergy, and genetic predisposition. *Clinical features.* The manifestation of nasal polyps depends on the size of the polyp. Small polyps may not produce symptoms. Symptom-producing polyps can cause nasal airway obstruction, postnasal drainage, dull headaches,

snoring, hyposmia and rhinorrhoea. Massive polyposis or a single large polyp (e.g. antral-choanal polyp) can cause obstructive sleep symptoms and chronic mouth breathing.

*Diagnosis* can be made on clinical examination. A CT scan of sinuses is essential to exclude the bony erosion and expansion suggestive of neoplasm. The CT scan also helps to plan surgery (Figure 2.16).

*Treatment.* Corticosteroids are the treatment of choice, either topically or systemically. Surgical intervention (FESS) is required for patients with multiple polyposis or chronic rhinosinusitis who fail maximum medical therapy.

## OTHER TYPES OF CHRONIC RHINOSINUSITIS

### Vasomotor rhinitis

Vasomotor rhinitis is believed to result from disturbed regulation of the parasympathetic and sympathetic systems in which the parasympathetic system dominates, resulting in vasodilation and oedema of the nasal vasculature. Cold air, strong odours, stress, or inhaled irritants may exacerbate symptoms. Rates of anxiety and depression are higher in women with vasomotor rhinitis than in healthy women without rhinitis.

### Occupational rhinitis

Patients with occupational rhinitis have symptoms of rhinitis only in the workplace. These symptoms are usually due to an inhaled irritant. Avoidance is preferable, but this is often not achievable. In situations, nasal corticosteroids or second-generation antihistamines have been of use.

### Hormonal rhinitis

Patients may have symptoms of rhinitis during periods of known hormonal imbalance. Estrogens are known to affect the autonomic nervous system by means of several mechanisms. The most common hormonal causes of rhinitis are pregnancy, menstruation, puberty, use of exogenous estrogen, and known or occult hypothyroidism. Therapy is guided at symptomatic care and treatment of the underlying disease.



Hormonal rhinitis in pregnancy usually manifests during the second month; it continues throughout pregnancy and ceases after delivery.

### Drug-induced rhinitis

Several medications are implicated in rhinitis, including angiotensin-converting enzyme inhibitors, methyl dopa, beta-blockers, chlorpromazine, gabapentin, aspirin, nonsteroidal anti-inflammatory drugs, inhaled cocaine, exogenous estrogens, and oral contraceptives.

### Rhinitis medicamentosa

Rhinitis medicamentosa is a drug-induced rhinitis resulting from prolonged use (i.e. >5–10 d) of sympathomimetic nasal spray. During this process, alpha-receptors in the nose are gradually desensitised to endogenous and exogenous stimulation. Patients with this disease typically present with extensive nasal congestion and rhinorrhoea resulting from a loss of adrenergic tone rather than from the original cause of rhinitis. Normal nasal function should recover within 7–21 days of sympathomimetics being discontinued. Topical nasal steroid spray may ease the transition from the sympathomimetic agents, and some suggest allowing the patient to continue using the offending agent at night for a few days or weaning one nostril at a time.

### Gustatory rhinitis

Gustatory rhinitis occurs after eating, particularly hot and spicy foods. The end result, i.e. profuse watery rhinorrhoea secondary to nasal vasodilation, is vagally mediated and generally occurs within a few hours of oral ingestion.

### Nonallergic rhinitis with eosinophilia syndrome

NARES, or eosinophilic rhinitis (i.e. perennial intrinsic rhinitis), accounts for as many as 20% of rhinitis diagnoses. Eosinophil counts are elevated in approximately 20% of nasal smears in the general population; however, not everyone with eosinophilia has symptoms of rhinitis. A distinguishing feature of NARES is the presence of eosinophils, usually 10–20% on nasal smears. In general, patients with NARES present with nasal congestion, sneezing, rhinorrhoea, nasal pruritus, and hyposmia.

## 2.4.2 Complications of sinus infections

The frequency of rhinosinusitis-related local, orbital, intracranial, and bony complications has decreased since the advent of antibiotics, but do still occur (Table 2.1). Concurrent medical and surgical intervention is the best way to achieve

resolution, necessitating the close cooperation of other specialties.

**Table 2.1.** Complications of rhinosinusitis

Local	Orbital	Intracranial
Mucocele	Preseptal cellulitis	Meningitis
Osteomyelitis	Orbital cellulitis	Epidural abscess
	Subperiosteal abscess	Subdural abscess
	Orbital abscess	Intracerebral abscess
	Cavernous sinus thrombosis	Dural venous sinus thrombosis

### 2.4.2.1 Local complications

#### Mucocele

*Definition.* Paranasal sinus mucocele is an epithelium-lined cystic mass usually resulting from obstruction of the sinus ostium.

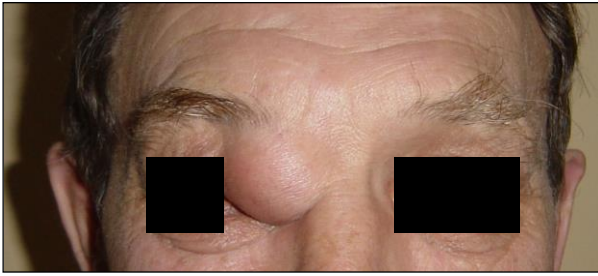*Aetiology.* There are two theories regarding the genesis of a mucocele:

- Chronic obstruction of the sinus ostium resulting in accumulation of secretions which slowly expands the sinus and destroys the bony walls of the sinus.
- Cystic dilatation of the mucous gland of the sinus mucosa due to obstruction of the duct. In this case the wall of mucocele is surrounded by normal sinus mucosa.

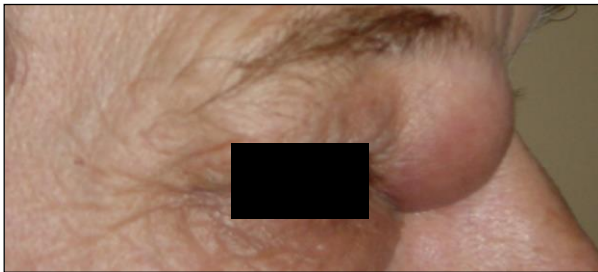
*Clinical features and diagnosis.* Frontal sinus mucocele usually presents in the superomedial quadrant of the orbit and displaces the eyeball forwards, downwards and laterally; cystic swelling of the forehead is sometimes present. Symptoms are usually headache, diplopia and proptosis. It can become infected (called a mucopyocele) and if not treated, may extend into surrounding structures. (Figure 2.17). CT or MRI helps with the diagnosis.

*Treatment* consists of antibiotics, frontoethmoidectomy with drainage of the frontal sinus into the middle meatus may be necessary.





**Figure 2.17a**  
Frontal mucocele – anterior view



**Figure 2.17b**  
Frontal mucocele – lateral view

### Osteomyelitis (“Pott’s puffy tumour”)

**Definition.** This is the presence of osteomyelitis due to frontal rhinosinusitis resulting in a subperiosteal abscess. This has a „puffy“ appearance on radiographical images.

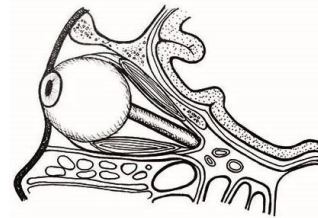
**Clinical features.** Pott’s puffy tumour is well recognised for the prominent frontal swelling on physical examination. It has a higher incidence in adolescence.

**Diagnosis and treatment.** A multidisciplinary approach involving the otolaryngology, neurosurgery, and infectious disease services is warranted to concurrently drain the abscess and responsible paranasal sinuses, remove the infected bone, and direct a six-week regimen of intravenous antibiotics, respectively.

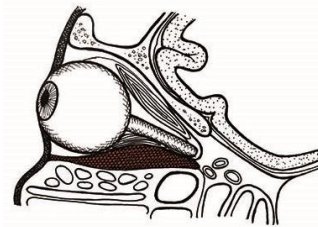
#### 2.4.2.2 Orbital complications

Its close proximity to the paranasal sinuses makes the orbit the most commonly involved structure in complications of rhinosinusitis.

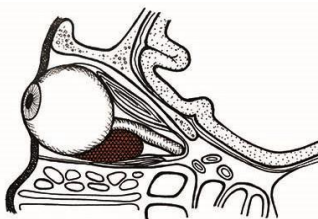
**Epidemiology.** Children tend to experience orbital complications more than the adult population, but they do not always exhibit typical clinical findings suggestive of acute infection, such as complaints of pain or general deterioration, and leukocytosis is found only in approximately half of cases.



**Figure 2.18a**  
Orbital complications of sinusitis – normal



**Figure 2.18b**  
Orbital complications of sinusitis – subperiosteal abscess



**Figure 2.18c**  
Orbital complications of sinusitis – orbital abscess

**Aetiology.** *Streptococcus* and *Staphylococcus* species are the more commonly responsible microbial agents involved in orbital complications in children, while *Streptococcus pneumoniae*, *Haemophilus influenzae*, and *Moraxella catarrhalis* usually affect adult patients.

*Classification, clinical features, diagnostics and treatment.* Chandler devised a classification scheme that categorises the various forms of orbital complications of rhinosinusitis and triages them in increasing severity: preseptal cellulitis, orbital cellulitis, subperiosteal abscess, orbital abscess, and cavernous sinus thrombosis (Figure 2.18).

### Preseptal cellulitis

Oedema and erythema of the eyelid are quite noticeable with preseptal cellulitis. A key characteristic is the integrity of both extraocular muscle movement and vision. CT images will only reveal diffuse thickening of the eyelids and conjunctiva, both of which should occur superficial to the orbital septum. Intravenous antibiotics, application of warm compresses, and elevating the head of the bed are usually sufficient treatment. Additionally, facilitating sinus drainage with nasal saline irrigations, decongestants, and mucolytics may provide some benefit.

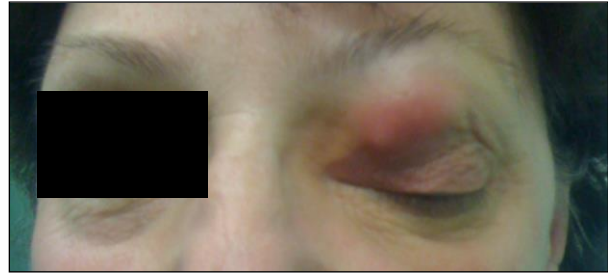### Orbital cellulitis

Progression of the inflammatory changes deep into the orbital septum constitutes orbital cellulitis. While oedema and erythema of the eyelid will also be present, proptosis and chemosis may be present (Figure 2.19). Some patients may complain of pain or diplopia but the vision itself remains unaffected. Low attenuation adjacent to the lamina papyracea is often present on CT. Management with antibiotics and nasal drainage is often successful. Clinical reassessment and surgical drainage should be considered if visual acuity is at 20/60 or worse or if there is no improvement or even progression of symptoms within 48 hours.

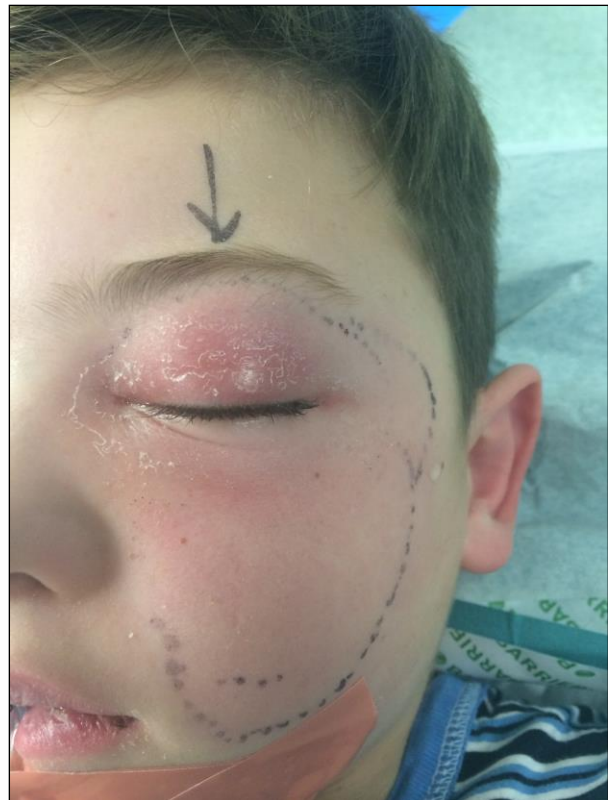### Subperiosteal abscess

A subperiosteal collection between the lamina papyracea and the periorbita typically displaces the orbital contents inferio-laterally resulting in exophthalmos. Patients will present with proptosis, chemosis, and ophthalmoplegia, leading to complaints of orbital pain, diplopia, and reduced visual acuity (Figure 2.20). A combined

medical and surgical treatment plan should achieve complete resolution in 95–100% of cases. The goal of surgery is removing the lamina papyracea and opening the ethmoid cells to drain the abscess and facilitate sinus drainage. In children up to 9 years of age with a small medial subperiosteal abscess in the absence of optic neuropathy, surgical treatment may be avoided.



**Figure 2.19**  
Orbital cellulitis



**Figure 2.20**  
Subperiosteal abscess in 8-year-old boy

### Orbital abscess

An abscess formation within the orbital tissues themselves will present with a clinical picture similar to a subperiosteal abscess. The degree of exophthalmos and chemosis is more severe compared to that experienced with a subperiosteal abscess. In conjunction with draining the responsible paranasal sinuses, incising the periorbita and draining the intraconal abscess with the assistance of ophthalmology colleagues are paramount to avoid the significant risk of irreversible blindness.

#### 2.4.2.3 Intracranial complications

*Aetiology.* Hidden infectious foci within the mucosal scarring diminish antibiotic penetration. Others include direct extension of infectious and inflammatory agents via erosion of the bony walls of the sinus or traversing through past traumatic fracture lines or naturally occurring neurovascular foramina such as for the optic and olfactory nerves.

### Meningitis

Inflammation of the meninges is the most common intracranial complication of rhinosinusitis, but it should be noted that rhinosinusitis itself is an unusual cause of meningitis. The involved sinuses are typically the ethmoid and sphenoid sinuses and are usually caused by *Streptococcus pneumoniae*, *Staphylococcus aureus*, and *Haemophilus influenzae*.

*Clinical features* tend to include fever, headache, meningismus, and an overall septic-like presentation similar to other cases of meningitis.

*Treatment.* Medical management alone is often sufficient, but facilitating sinus drainage should be considered if there is no improvement after 48 hours. Prompt treatment is important in light of the high incidence of neurologic sequelae such as sensorineural hearing loss and seizures.

### Epidural abscess

*Definition.* A collection of purulent material between the skull and the dura often spreads from

frontal sinusitis. As with meningitis, affected individuals will present with signs reflective of increased intracranial pressure, including fever, headache, nausea, vomiting, and papilledema, but others may also exhibit hemiparesis and seizures.

*Diagnosis.* A crescent-shaped hypodensity is revealed by CT with similar radiographical findings on MRI.

*Treatment.* Concurrent medical and surgical modalities and, consequently, quick neurosurgical intervention are vital. Broad-spectrum antibiotic coverage with good cerebral penetration is often initiated with a combination of a third-generation cephalosporin, vancomycin, and metronidazole for 4–8 weeks. The abscess and the affected sinuses can be surgically drained through an external approach using either a frontal sinus trephination, endoscopic procedure, osteoplastic flap or cranialisation.

### Subdural abscess

While it can originate from the frontal sinus, a purulent collection just deep into the dura mater may also arise from the ethmoid sinuses.

*Clinical features.* The presenting signs are similar to epidural abscesses and may even accompany 10% of epidural abscesses, but patients may present with lethargy or in a comatose state in more severe cases. Although it is only the third most common rhinosinusitis-related intracranial complication, this condition is notable for rapid clinical deterioration which results in mortality in up to 35% and residual neurological sequelae in 35–55% of those who survive.

*Treatment.* A long-term regimen of broad-spectrum antibiotics with good blood–brain penetration is clearly warranted, as with epidural abscesses. Lumbar punctures are contraindicated, and there is a general consensus to initiate prophylactic anticonvulsants and decrease intracranial pressure with hyperventilation or mannitol. Some have mentioned the potential benefit of steroids while citing their beneficial anti-inflammatory properties, but others have countered that they may impair the abscess encapsulation process, increase necrosis, reduce antibiotic penetration into the abscess, and alter the appearance on CT scans.

*Treatment.* Surgical drainage of the abscess and the involved paranasal sinuses should be pursued as a combined rhinosurgery/neurosurgery case. Successful medical management of abscesses less than 1.5 cm in size is possible; it is often reserved for patients less than four years of age.

### **Intracerebral abscess**

There is purulent coalescence within the brain parenchyma itself. The frontal and frontoparietal lobes are usually afflicted and may be attributed to rhinosinusitis of the frontal, sphenoid, and ethmoid sinuses (in descending order of frequency). The majority of microorganisms responsible for epidural, subdural, and intracerebral abscesses are anaerobes, accounting for 60–100% of cases, while *Staphylococcus* and *Streptococcus* species and gram-negative bacilli have been noted.

*Treatment.* A combined medical and surgical endeavour similar to subdural abscesses is the treatment modality of choice. Antibiotics, anticonvulsants, hyperventilation, mannitol, and steroids carry the same considerations.

### **Cavernous sinus thrombosis**

The cavernous sinuses are complex of veins with no valves, so infections of the face including the nose, sinuses, tonsils, and orbits can spread easily by this route. Cavernous sinus thrombosis often manifests with signs similar to an orbital abscess as the inflammatory and infectious process traverses posteriorly from the orbit towards the intracranial cavity.

*Clinical features.* Orbital pain, proptosis, chemosis, ophthalmoplegia, and impaired vision are also present, but the key distinguishing feature is that there is also contralateral involvement. Presence of heterogeneity and increased size of the cavernous sinus on MRI are considered a more confirmatory radiographical finding. Cavernous sinus thrombosis is often associated with meningismus and sepsis, and carries a mortality rate up to 30%.

*Treatment.* High-dose intravenous antibiotics that can cross the blood–brain barrier and surgical drainage of the paranasal sinuses are clearly warranted.

### **Venous sinus thrombosis**

Similar to the cavernous sinus thrombosis encountered with orbital-pertaining complications, any of the dural venous sinuses may be affected.

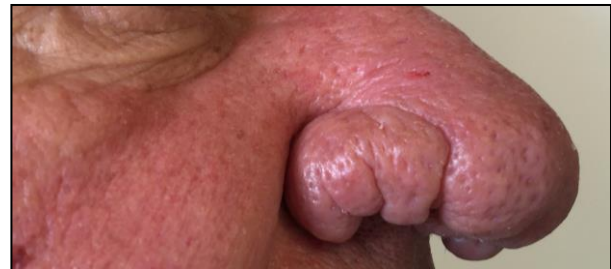## **2.4.3 Tumours**

### **Benign tumours**

Benign sinonasal tumours are non-malignant growths on the external nose, inside the nasal cavity or sinuses. These are relatively unusual. Coronal and axial contrast-enhanced CT is considered the study of choice for evaluating intranasal lesions. Biopsy is the most important diagnostic tool. It is paramount to perform imaging studies before biopsy.

### **Rhinophyma**

*Definition.* Rhinophyma is a large, bulbous, ruddy appearing nose caused by granulomatous infiltration, commonly due to untreated rosacea. Rhinophyma is much more common in men than in women (Figure 2.21 Rhinophyma).



**Figure 2.21**  
Rhinophyma

*Clinical features.* Diagnosis is obvious. Patients usually complain of the skin condition but direct enquiry may often reveal a long history of flushing.

*Treatment.* Rhinophyma may respond to medication if diagnosed in its early stages. Surgery is the preferred treatment for most cases. Surgery can be performed using a scalpel, laser, cryosurgery, electrosurgery, or dermabrasion. The aim is to



reshape a disfigured nose, remove the overgrowth of abnormal tissue, minimise enlarged blood vessels, and provide overall cosmetic improvement.

### Papilloma

*Definition and clinical features.* Papilloma is a term for a tumour of the skin or mucous membrane with finger-like projections.

*Aetiology.* Most papillomas are caused by a virus. The human papillomaviruses (HPVs) are a group of more than 150 viruses that can cause papillomas. Nasal papilloma may be caused by a tissue injury; there are also types of papillomas that do not have known causes.

*Treatment* is surgical removal.

### Inverted papilloma (Schneiderian papilloma)

*Definition.* Inverted papillomas are nasal tumours that originate in the mucous membrane of the nasal cavity and paranasal sinuses. They tend to invert into the underlying connective tissue stroma, which differs from other types of papillomas.

*Clinical features.* Unilateral nasal obstruction is the most common presenting symptom of patients with inverted papillomas. Other symptoms may include epistaxis, nasal discharge, epiphora, and facial pain.

*Diagnosis.* Physical examination usually reveals a unilateral polypoidal mass filling the nasal cavity and causing nasal obstruction. Papillomas have an irregular, friable appearance, and they often bleed when touched.

*Treatment.* Surgical removal is a primary treatment. Surgical options are either a conservative resection (recurrence rates of 40–80%), medial maxillectomy or endoscopic resection of the tumour.

Although inverted papilloma is a benign lesion in most cases, it can be a locally aggressive tumour with malignant potential. Squamous cell carcinoma may be present in the inverted papilloma.

### Haemangioma

*Epidemiology.* These tumours are usually congenital. About 30% of haemangiomas are present at birth.

*Clinical features.* A red to reddish-purple, raised sore (lesion) on the skin/mucosa.

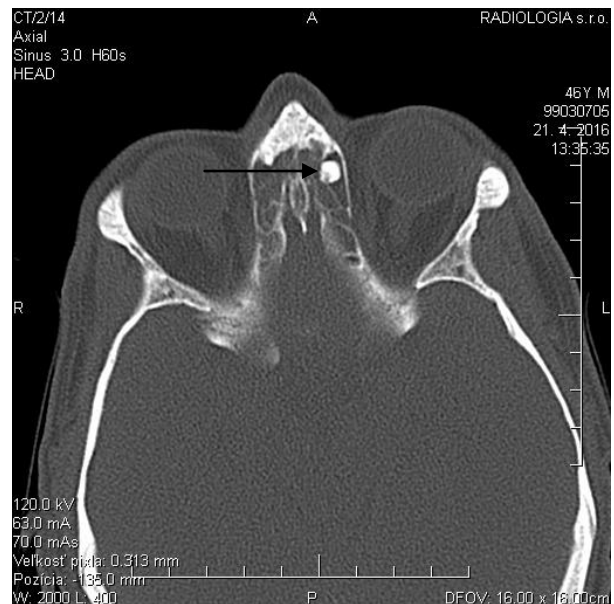*Diagnosis.* Haemangiomas are diagnosed by a physical examination. In the case of deep or mixed lesions, a CT or MRI scan may be performed. Occasionally, a haemangioma may occur with other rare conditions.

*Treatment.* Haemangiomas often are not treated since many will regress spontaneously. In some cases, a laser may be used to remove the small vessels. Other cases are successfully treated surgically.

### Osteoma

*Definition.* Osteomas are benign tumours of bone.

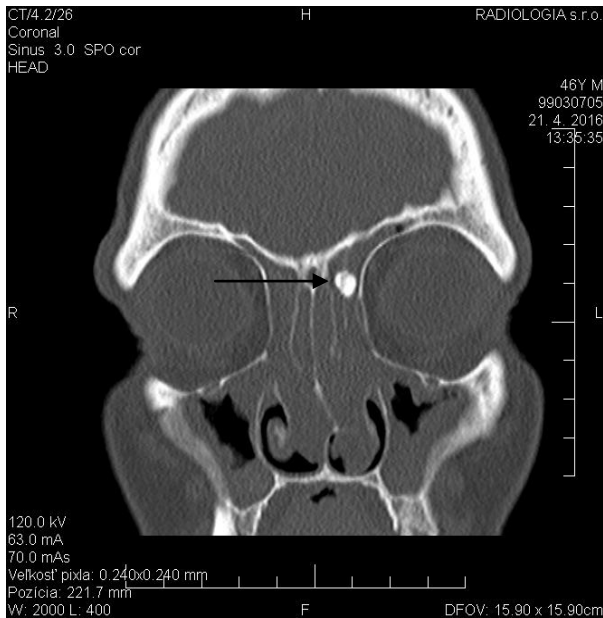
*Clinical features.* They are often incidentally found in patients who are undergoing imaging of the sinuses or the head appearing in up to 3% of CT examinations of the paranasal sinuses (Figure 2.22). They are most frequently diagnosed from 20–50 years of age. Frequency distribution within the paranasal sinuses is in frontal sinuses approximately 80%, in ethmoid sinuses 15%, in maxillary sinuses 5%, and rarely in the sphenoid sinus.



**Figure 2.22a**

Osteoma of ethmoid sinuses; CT scan, axial plane





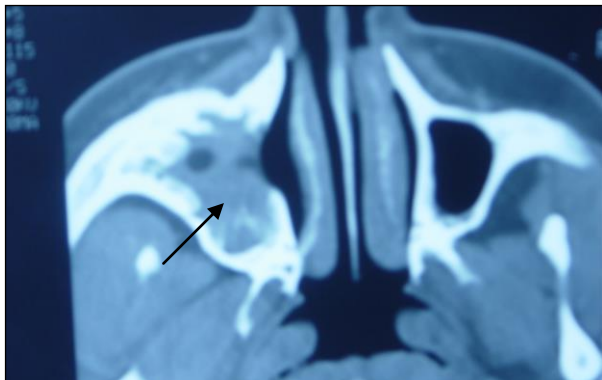**Figure 2.22b**

Osteoma of ethmoid sinuses; CT scan, coronal plane

*Treatment.* In asymptomatic cases surgical excision is not indicated. In cases where the osteoma is thought to be responsible for symptoms (e.g. mucocele), excision of the osteoma is required.

### Fibrous dysplasia

*Definition.* Fibrous dysplasia is a benign, noninherited developmental anomaly of bone in which normal bone marrow is replaced by fibro-osseous tissue (Figure 2.23).



**Figure 2.23**

Fibrous dysplasia of right maxillar sinus; CT scan, axial plane

*Clinical features.* Patients with small, monostotic lesions may be asymptomatic, with the osseous abnormality identified incidentally on radiologic studies obtained for unrelated reasons. However, bone pain, swelling, and tenderness are common presentations in symptomatic patients.

*Diagnosis.* CT scan together with clinical features.

*Treatment.* Asymptomatic patients are initially managed through observation. Surgical intervention is generally intended for cosmetic facial deformities and decompression of vital structures. The recurrence rate of surgery is high. Radiotherapy is not recommended.

## MALIGNANT TUMOURS

### Malignancies of the external nose

There are three main types after malignant tumours of the external nose. The most common skin cancer is basal cell carcinoma. A second type, squamous cell carcinoma, can metastasise and cause extensive damage. About 3–4% of people with squamous cell carcinoma of the nose die from the disease. Melanoma is probably the most familiar. It accounts for only 4% of skin cancers but 75% of skin cancer deaths. People who have had multiple basal cell cancers are at greater risk of squamous cell carcinoma and melanoma.

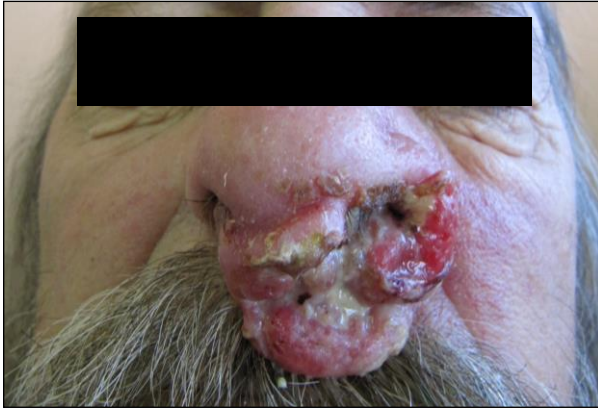### Basal cell carcinoma

*Clinical features.* Basal cell carcinoma may start by looking like a harmless blemish which bleeds easily, or won't heal. It is slowgrowing and occurs mostly in people over the age of 55. People with fair skin, blond or red hair, and blue, grey or green eyes are at greatest risk. Other risk factors include a history of ionizing radiation therapy to treat acne, eczema, or psoriasis; chronic immunosuppression for organ transplantation; long-term use of oral glucocorticoids; and a history of previous skin cancer of any type.

*Treatment.* The goal of treatment is to remove the cancer completely with the least possible cosmetic damage. The options, which include cryosurgery, surgical removal, radiation, and topical creams, have a cure rate of 90% or more for first-time cancers.

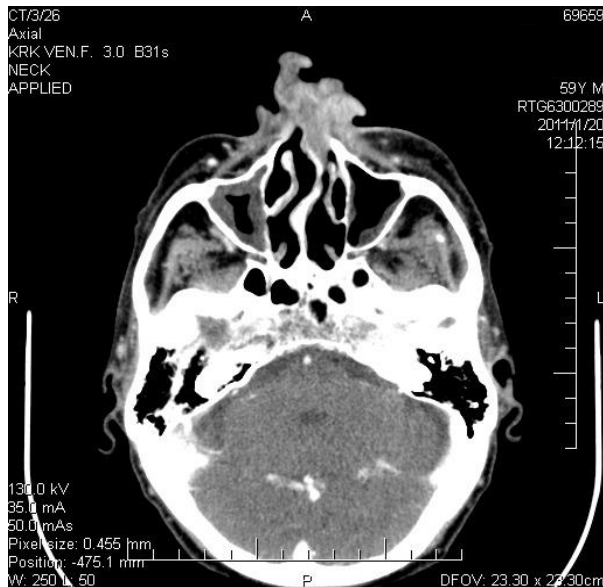
### Squamous cell carcinoma (SCC)

**Clinical features.** SCCs tend to occur on sun-exposed portions of the skin. People with chronic sun damage, scars from prior burns, arsenic exposure, chronic cutaneous inflammation (as seen in longstanding skin ulcers), and sites of previous x-ray therapy are predisposed to the development of SCC which when neglected destroys neighbouring structures (Figure 2.24).



**Figure 2.24a**

Squamous cell carcinoma of external nose; Clinical picture



**Figure 2.24b**

Squamous cell carcinoma of external nose;  
CT scan, axial plane

**Treatment.** Most squamous cell skin cancers are found and treated at an early stage, when they can be removed or destroyed with local treatment methods. Small cancers can usually be cured with excision, electrodesiccation and curettage or Mohs surgery. Occasionally reconstruction with flaps or using custom made epithesis anchored on implants in the bone may be necessary.

The Mohs surgery involves removing skin cancer layer by layer and examining the tissue under a microscope until clear margin is reached. The surgeon is specially trained as a cancer surgeon, pathologist, and reconstructive surgeon. Mohs surgery has 99% success rate, highest of all treatments for skin cancer.

Radiation therapy is often a good option for patients with advanced cancers, especially in areas where surgery is difficult (eyelids, ears, or nose). It is not used as much as an initial treatment in younger patients because of the possible risk of long-term problems. Radiation is sometimes used if the surgical margins are positive or if there is a chance that some cancer may remain.

### Malignant melanoma

**Definition.** This cancer, which accounts for 4% of all malignant tumours of skin, originates in pigment-producing skin cells called melanocytes.

**Classification.** The types of melanoma are defined by their size, colour, border shape, level of ulceration, and texture (Table 2.2).

**Table 2.2.** Malignant melanoma

Superficial spreading melanoma	Most common, 60% of cases
Nodular melanoma	10% to 15%
Acral lentiginous melanoma	5% to 10%
Lentigo maligna melanoma	5% to 10%
Amelanotic malignant melanoma	Less than 5%

Measuring the depth of a melanoma (Breslow and Clark scales) is critical in determining its treatment and outcome. **Symptoms.** Typically, the individual will report a change in the character or size of a mole, or observe a suspicious new growth.

**Treatment.** The level of penetration and potential for damage are assessed by the histopathologist. Surgical excision of the tumour is the fundamental treatment. Regional chemotherapy may be used in conjunction with surgery to destroy any remaining malignant cells. Radiation therapy and injections of Interferon are other options.

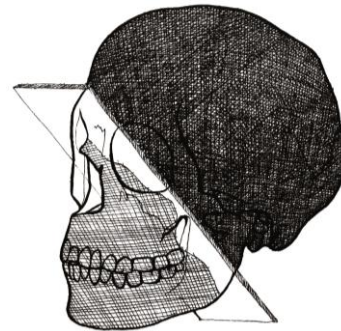
Melanoma is the least common but the most lethal of the skin cancers. Biopsy is necessary to classify any lesion unless malignant melanoma is suspected. If malignant melanoma is suspected, excisional biopsy, rather than incision biopsy, is the recommended diagnostic method. This provides the pathologist with the maximum opportunity to diagnose a malignant melanoma as well as the depth of invasion. Breslow thickness is the most powerful prognostic parameter.

### Sinonasal malignancies

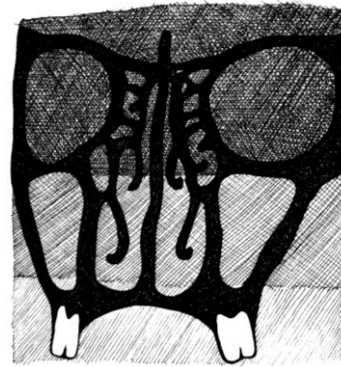
**Epidemiology.** Sinonasal malignancies (SNM) are rare. Globally, they form less than 1% of all malignancies. Exposures to wood dust, nickel refining, and leather tanning have been implicated in the carcinogenesis. Approximately 60–70% of SNM occur in the maxillary sinus and 20–30% occur in the nasal cavity itself. An estimated 10–15% occur in the ethmoid sinuses, with the remaining minority of neoplasms found in the frontal and sphenoid sinuses.

**Clinical features and diagnosis.** The location of the nasal cavity and the paranasal sinuses make them extremely close to vital structures. Aggressive therapy may be needed in areas close to the skull base, orbits, cranial nerves, and vital blood vessels. They produce few, if any, signs while the tumour is in its early stages. This problem is exacerbated by the fact that the initial manifestations (e.g. unilateral epistaxis, nasal obstruction) mimic signs and symptoms of many common but less serious conditions. Biopsy is necessary to classify any lesion. On clinical grounds, the prognosis may be classified in relation to the three levels defined by Sébilleau and in relation to Öhngren's plane (Figure 2.25). The

prognosis worsens as the tumour passes from level I to level III. In a similar manner, tumours anterior to Öhngren's plane tend to have a better prognosis.



**Figure 2.25a**  
Öhngren's plane



**Figure 2.25b**  
Sébilleau levels

**Treatment** of sinonasal malignancies is best accomplished through a multidisciplinary team. Optimally, this includes a head and neck oncologic surgeon, reconstructive surgeon, maxillofacial prosthodontist, radiation oncologist, medical oncologist, neuroradiologist, pathologist, neurosurgeon, and the patient. In general, treatment consists of surgery, radiotherapy, chemotherapy and their various combinations.

### Squamous cell carcinoma

Squamous cell carcinoma constitutes over 80% of all malignancies that arise in the nasal cavity and paranasal sinuses. The presentation is extremely



varied and may include a nasal mass or obstruction, rhinorrhoea, epistaxis, cranial neuropathies, or pain.

*Clinical features.* At first, it may be little more than a mass or small ulcer. With advanced disease, large ulceration, necrosis, heaped edges, and bone and soft-tissue invasion may be observed.

*Treatment.* Prognosis is improved in those patients presenting with the primary cancer in the ethmoids, early lesions treated with both radiation and surgery, and with a history of inverted papilloma. Lymph node involvement is rare and a lymph node dissection is not usually advocated. The overall 5-year survival rate is around 60%.

### Adenoid cystic carcinoma

Adenoid cystic carcinoma (ACC) is of a salivary gland origin and is the second most common sinonasal malignancy, accounting for 10% of cases. Cervical lymph node involvement is rare. Perineural invasion is common and is present in 40–60% of cases. Late recurrence and distant metastasis are frequent and can occur decades after initial presentation.

*Treatment.* Surgery is the mainstay of therapy, followed by postoperative radiation in particular for advanced cancer, perineural involvement or positive margins. Chemotherapy does not currently have a role in treatment.

### Adenocarcinoma and its variants

Adenocarcinoma of the nasal cavity and paranasal sinuses is associated with specific risk factors including exposure to wood dust, nickel particles, lacquers, and other organic compounds.

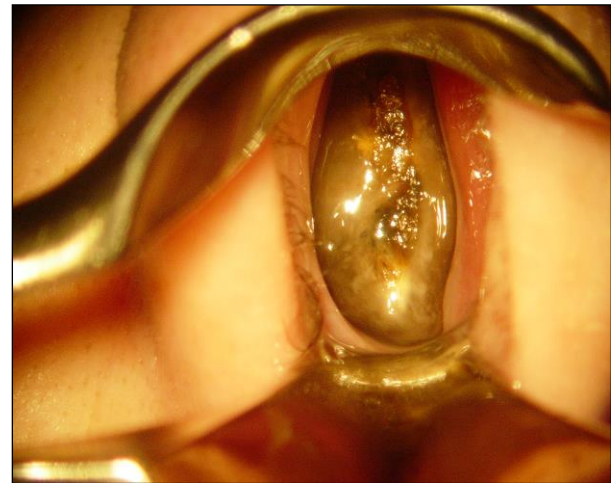Both low- and high-grade adenocarcinoma can cause obstructive symptoms, rhinorrhoea, or epistaxis. Regardless of the grade, local destruction of the orbits and skull base is frequently seen. Metastases to the cervical lymph nodes are uncommon, even with poorly differentiated tumours; distant metastases are rare.

*Treatment* is surgical excision with wide margins and postoperative radiotherapy for advanced cancers or positive margins. Endoscopic resection may also be a valid treatment option.

### Malignant melanoma

Malignant melanoma is a rare tumour of the nasal cavity and paranasal sinus mucosa. It accounts for less than 1% of all malignant melanomas and less than 4% of nasal malignancies.

*Clinical features* of the lesion are that of a firm, grey-white or pink-to-black, ulcerated mass (Figure 2.26). Black colouration is a rarity, and its absence does not rule out melanoma without biopsy. Histologically, mucosal melanoma can be extraordinarily variable in appearance.



**Figure 2.26**

Nasal malignant melanoma

Manipulation of a malignant melanoma should be avoided if possible and immediate surgery is indicated rather than biopsy alone.

The primary *treatment* is surgical resection with wide local margins. Postoperative radiation is often recommended in advanced cases. Chemotherapy is currently used for disseminated disease and palliation. Despite optimal therapy, median survival is less than 2 years.

### Esthesioneuroblastoma

*Definition and aetiology.* Esthesioneuroblastoma (ENB), frequently called olfactory neuroblastoma, constitutes 3% of all endonasal tumours. Most patients present in the fifth decade of life. ENB

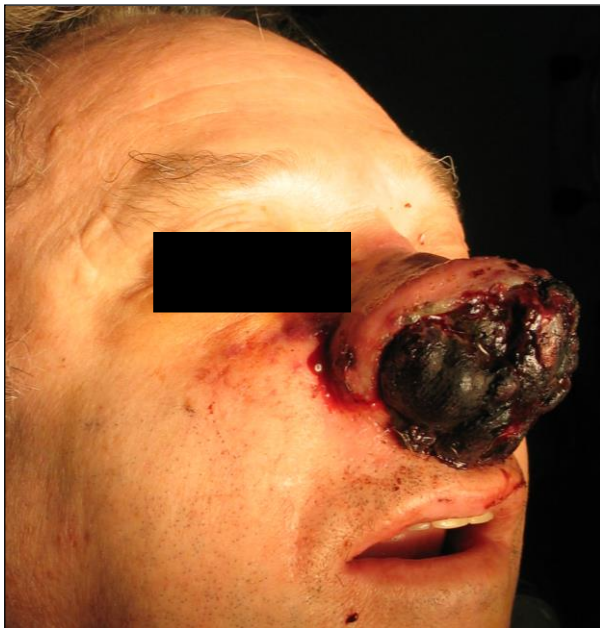most commonly originates from olfactory cells near the cribriform plate.

*Clinical features.* ENB commonly manifests at an advanced stage, possibly because early symptoms in this location are either not present or ambiguous.

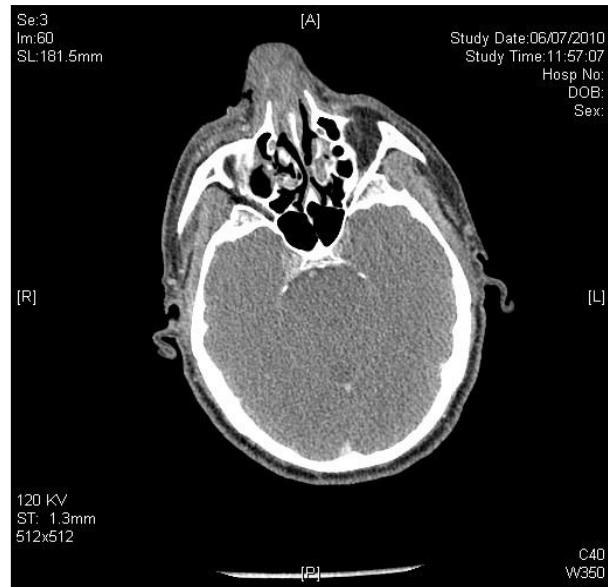
**Kadish classification of esthesioneuroblastoma**

Group A is limited to tumours of the nasal fossa; in group B, extension is to the paranasal sinuses; group C is defined as extension beyond the paranasal sinuses and nasal cavity.

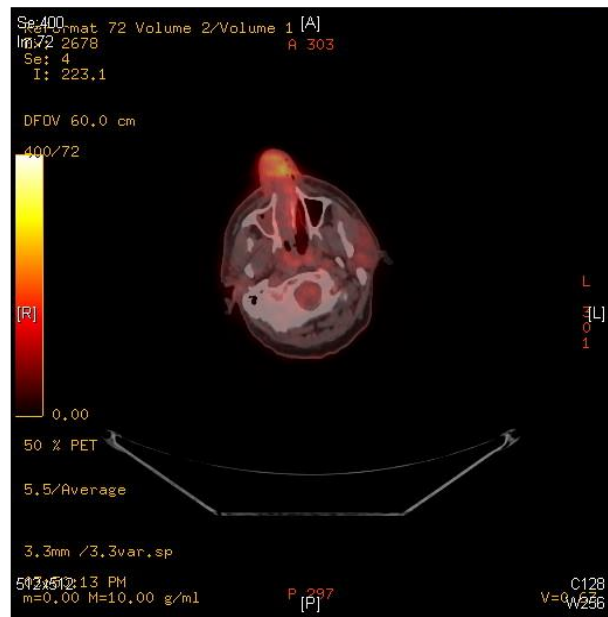
*Treatment* of ENB changed with the advent of the craniofacial resection, which significantly increased 5-year survival. Complete surgical resection of the tumour, followed by radiation therapy, is the optimal treatment. Surgery remains the primary treatment and offers the best chance of locoregional control as well as survival. Both open and endoscopic (FESS) craniofacial resection can achieve complete surgical resection with tumour-free margins. Cervical lymph node metastasis at the time of presentation is less than 5%, but long-term cervical involvement ranges from 15–30%.



**Figure 2.27a**  
Angiosarcoma



**Figure 2.27b**  
Angiosarcoma; CT scan, axial plane



**Figure 2.27c**  
Angiosarcoma; PET CT scan, axial plane

**Lymphoma**

In general, non-Hodgkin lymphomas are usually found in patients in their 60s and 70s and manifest with symptoms of obstruction. After the type of tumour is established, treatment



is usually radiation therapy and chemotherapy, as established by protocol. The prognosis is variable for patients with non-Hodgkin lymphoma and, depending on the type and stage ranges, median survival ranges from less than 1 year to close to 80% at 5 years.

### Sarcoma

Sarcomas of the sinonasal tract are rare. Given that the nasal cavity and paranasal sinuses contain nerves, blood vessels, lymphatics, smooth and skeletal muscle, fibrous tissue, bone and adipous tissue, malignant mesenchymal tumours occasionally develop (Figure 2.27). Fibrosarcomas, leiomyosarcomas, rhabdomyosarcomas, liposarcoma, malignant peripheral nerve-sheath tumours, and other lesions have been reported. Of these tumours, rhabdomyosarcoma deserves special consideration because it is one of the more frequent sinonasal malignancies in children, although it has also been reported in adults. A combination of radiation therapy and chemotherapy is used rather than surgery. Despite current optimal therapy, 50% of patients die from this disease. Sinonasal tumours in children are most commonly sarcomas and have a 70% response rate to multimodal therapy.

### Metastatic tumours

Tumours metastatic to the nasal cavity and paranasal sinuses are rare. As expected, tumours that most frequently metastasise to this bony region are those that are well known to metastasise to other bones including prostate, breast, kidney, lung, and thyroid gland.

Melanomas, GI adenocarcinoma, and hepatocellular carcinoma have also been reported to metastasise to the head and neck region.

## 2.4.4 Trauma

### Trauma of the external nose

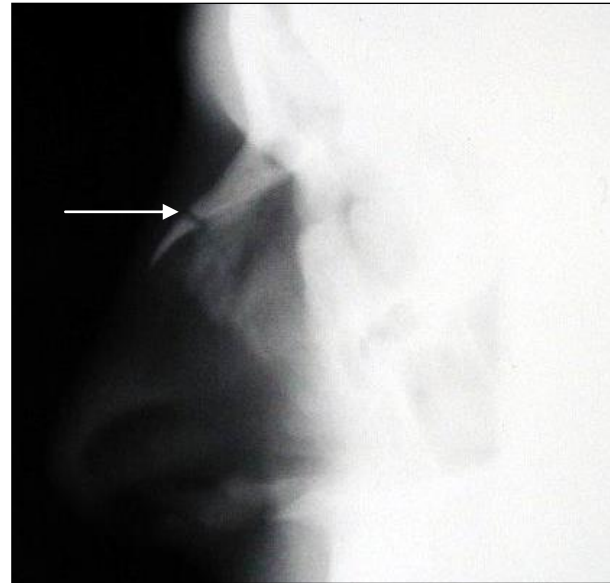
The nasal bones are the most commonly fractured bony structures of the maxillofacial complex.

*Symptoms.* Include a visible deformity, dislocation or depression of the nasal pyramid, haematoma and oedema of the soft tissues, pain on pressure on the nasal pyramid, epistaxis and nasal obstruction.

*Diagnosis.* Routine radiographs might be helpful (Figure 2.28). Computed tomography (CT) scanning provides the best information regarding the extent of a bony injury in nasal and facial fractures. A cartilaginous injury is likely to be missed on both X-ray and CT.

*Treatment.* Soft tissue injury is repaired. Antibiotics should be administered. Repositioning of a simple fracture of the nasal bone should be

carried out. If oedema is significant, it is possible to delay manipulation until after the oedema has resolved but before the setting of fracture fragments (6–10 days after injury in adults; 3–7 days after injury in children). An uncorrected deformity is planned for corrective surgery.



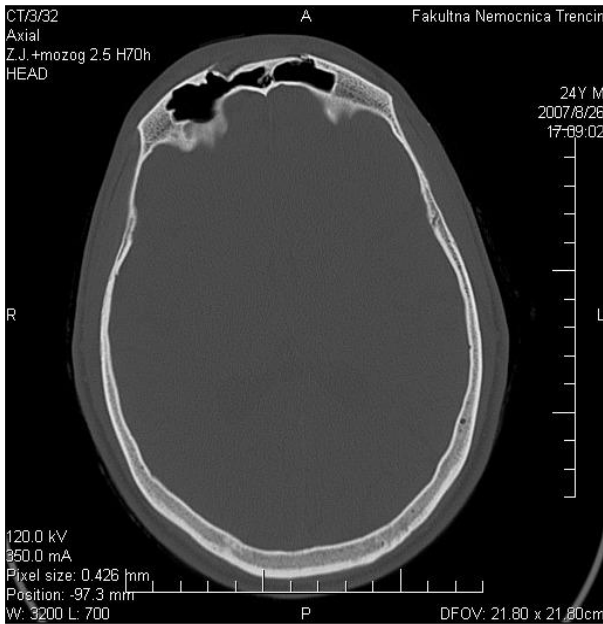
**Figure 2.28**

Nasal bone fracture; plain radiograph, lateral view

### Frontal sinus fracture

The frontal sinus is extremely resistant to injury. Motor vehicle accidents account for more than 70% of frontal sinus fractures. As many as 33% of patients have an associated cerebrospinal fluid (CSF) leak. Combined fractures of the anterior table, posterior table, and/or nasofrontal recess appear in 55–67% of cases.

*Diagnosis.* Displaced fractures of the anterior table without overlying lacerations may not be apparent on physical examination because of soft tissue oedema or haematoma. A CT scan will demonstrate the fracture (Figure 2.29). All forehead lacerations should be examined under sterile conditions to assess the integrity of the anterior table, posterior table, and dura. Examine the nasal cavity for the presence of a CSF leak. The beta-2 transferrin test is the definitive evaluation for CSF rhinorrhoea.



**Figure 2.29**

Right frontal sinus fracture; CT scan, axial plane

*Treatment.* The treatment goals of frontal sinus fractures are an avoidance of short- and long-term complications, return of normal sinus function, and reestablishment of the preinjury facial contour. Options include observation or surgical repair dependent on the findings.

**Trauma of the middle third of the face**

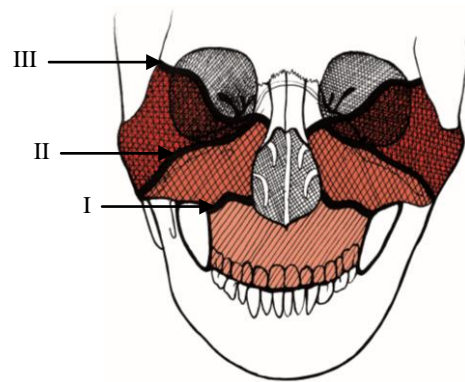
Maxillary fractures often result from a high-energy blunt force injury to the facial skeleton. Typical mechanisms of trauma include motor vehicle accidents, altercations, and falls.

*Clinical presentation.* Three predominant types are described (Figure 2.30).

**Le Fort I fractures (horizontal)** may result from a force of injury directed low on the maxillary alveolar rim in a downwards direction. The fracture extends from the nasal septum to the lateral pyriform rims, travels horizontally above the teeth apices, crosses below the zygomaticomaxillary junction, and traverses the pterygomaxillary junction.

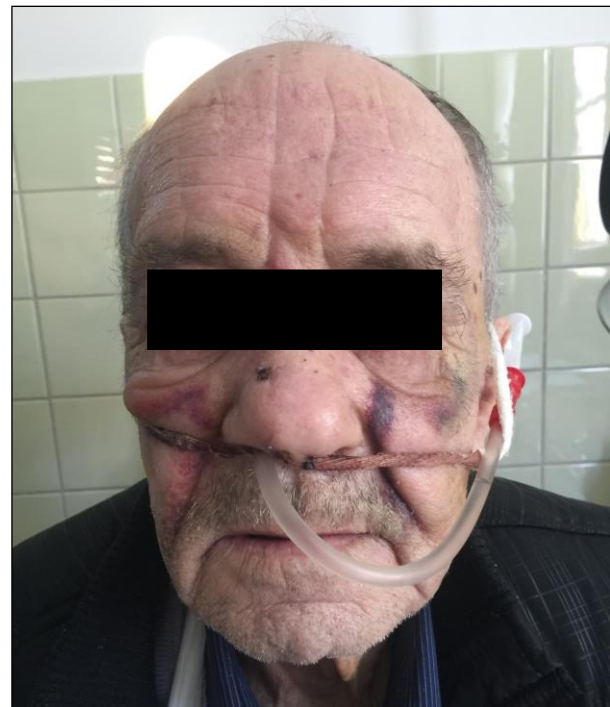**Le Fort II fractures (pyramidal)** may result from a blow to the lower or mid-maxilla. Such a fracture has a pyramidal shape and extends from

the nasal bridge at or below the nasofrontal suture through the frontal processes of the maxilla, inferolaterally through the lacrimal bones and inferior orbital floor and rim through or near the inferior orbital foramen, and inferiorly through the anterior wall of the maxillary sinus; it then travels under the zygoma, across the pterygomaxillary fissure, and through the pterygoid plates.



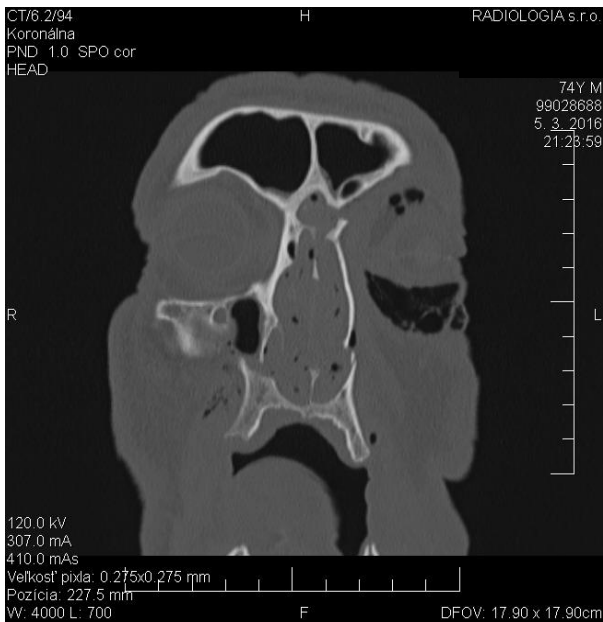
**Figure 2.30a**

Le Fort fractures – Typical fracture lines



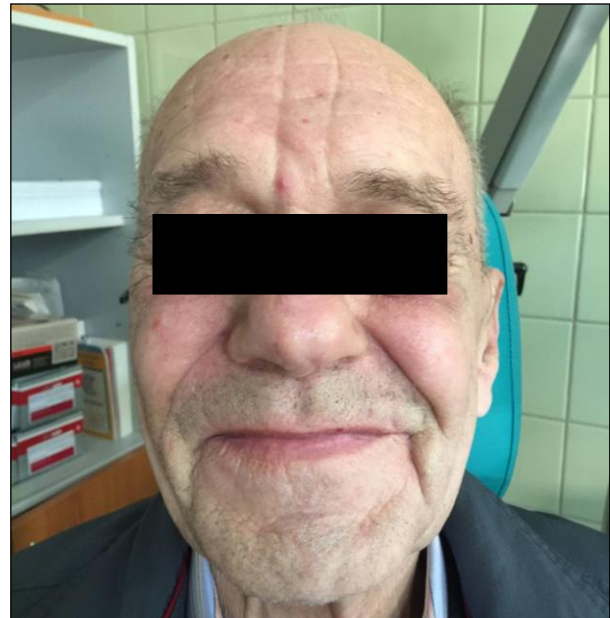**Figure 2.30b**

Patient with Le Fort II fracture



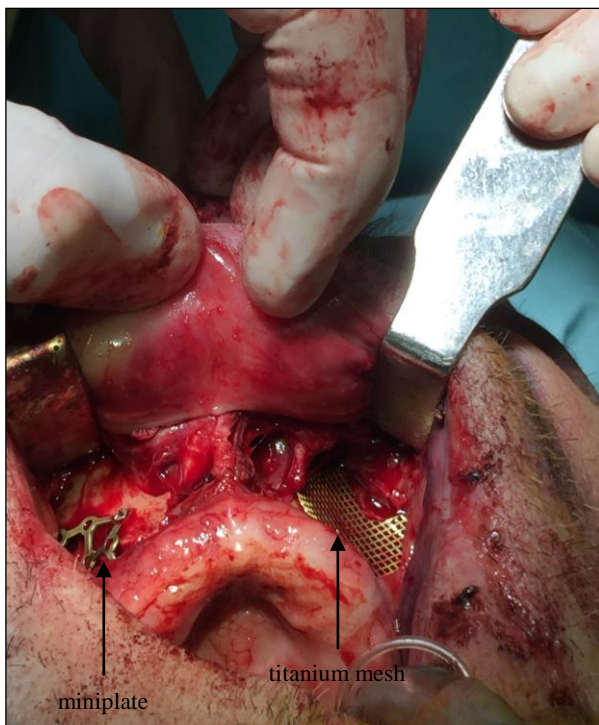
**Figure 2.30c**

Patient with Le Fort II fracture; CT scan, coronal plane



**Figure 2.30e**

One month after reconstruction



**Figure 2.30d**

Reconstruction with miniplates and titanium mesh

**Le Fort III fractures (transverse)**, also termed craniofacial disjunctions, may follow impact to the nasal bridge or upper maxilla. These fractures start at the nasofrontal and frontomaxillary sutures and extend posteriorly along the medial wall of the orbit through the nasolacrimal groove and ethmoid bones. The thicker sphenoid bone posteriorly usually prevents continuation of the fracture into the optic canal.

#### Midface trauma classification

In reality, the Le Fort classification is an oversimplification of maxillary fractures. In most instances, maxillary fractures are a combination of the various Le Fort types.

Two types of non-Le Fort maxillary fractures of note are relatively common. Firstly, limited and very focused blunt trauma may result in small, isolated fracture segments, particularly the alveolar ridge, the anterior wall of the maxillary sinus, and nasomaxillary junction. Secondly, submental forces directed superiorly may result in several discrete vertical fractures through various

horizontal bony supports such as the alveolar ridge, infraorbital, and zygomatic arches.

**Diagnosis.** In general, patients with facial fractures have obscuration of their bony architecture with soft tissue swelling, ecchymoses, gross blood, and haematoma. Mobility of the mid-face may be tested by grasping the anterior alveolar arch and pulling forwards while stabilising the patient with the other hand. The size and location of the mobile segment may identify which type of Le Fort fracture is present. CT scan images are the imaging modality of choice for facial fractures. Fractures of the cervical spine occur frequently in this setting. There might be a need to consult various specialists, including a maxillofacial surgeon, ophthalmologist or neurosurgeon.

**Treatment.** Address emergencies related to maxillofacial trauma prior to definitive treatment. These include airway compromise and excessive bleeding. The definitive surgery should be carried out as quickly as possible, since the fractures might heal in the wrong position due to formation of the callus. Fixation of unstable fracture segments to stable structures is the objective of definitive surgical treatment.

### Fracture of the zygoma and the bony orbit

**Clinical features.** Zygomatic arch fractures may result in trismus, flattening of the midface, or a reduction in oral aperture. The fracture is almost always depressed. These fractures often form part of a more severe mid-face fracture.

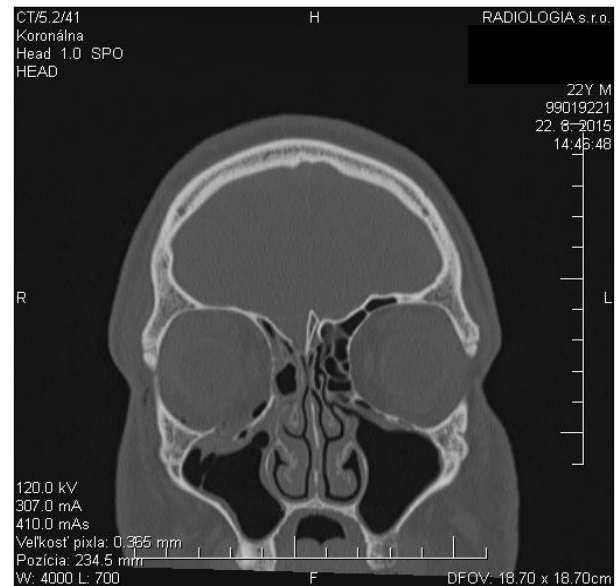
**Diagnosis.** Assess the type and direction of trauma, inspection and palpation, which shows asymmetry of the face. A CT scan is an imaging modality of choice.

**Treatment.** Fractures of the zygomatic arch have been approached by various methods. Access from the oral vestibule, through the incision in the temporal region or directly through the overlying tissues. External fixation is usually not necessary.

### Blowout fracture

**Definition.** Pure fractures of the orbital floor, referred to as isolated floor fractures, result from an impact injury to the globe and upper eyelid.

Fractures of the orbital floor are secondary to a sudden increase in intraorbital hydraulic pressure. A high-velocity object that impacts the globe and upper eyelid transmits kinetic energy to the periocular structures. Most fractures occur in the posterior medial region that is composed of the thinnest bones (Figure 2.31).



**Figure 2.31**

Blowout fracture; CT scan, coronal plane

**Clinical features.** After facial trauma, patients may describe decreased visual acuity, blepharoptosis, binocular vertical or oblique diplopia (especially in upgaze), and ipsilateral hypaesthesia, dysaesthesia, or hyperalgesia in the distribution of the infraorbital nerve. In addition, patients may complain of eyelid swelling following nose blowing. Periorbital ecchymosis and oedema accompanied by pain are obvious external signs and symptoms, respectively. Enophthalmos is possible but initially can be obscured by surrounding tissue swelling.

**Medical treatment** is warranted for patients for whom surgery is not indicated (patients who present without significant enophthalmos, absence of an entrapped muscle or tissue, a fracture less than 50% of the floor, or a lack of diplopia). The patient can be treated with oral antibiotics, a short




course of oral prednisone, and nasal decongestants. Discourage nose blowing to avoid creating or worsening orbital emphysema.

**Surgical treatment.** The orbital floor can be accessed through a conjunctival approach, cutaneous exposure, or through a transmaxillary approach. Access to this region allows for exploration and release of displaced or entrapped soft tissue, thereby correcting any extraocular motility disturbances. In addition, repair of the bony defect with removal or repositioning of bony fragments allows for restoration of the partition between the orbit and maxillary antrum.

### 2.4.5 Nasal septum

#### Deviation of the nasal septum

This may be developmental, due to unequal growth of the cartilage and bone of the septum, or it might be traumatic due to, fracture of the nose or due to injury at birth. In these cases the parts of the septum are dislocated and heal in an incorrect position, causing deviations, spurs or crests which reduce the patency of the nasal cavity (Figure 2.32).



**Figure 2.32**

Types of septal deviation

*Clinical features* include nasal obstruction, which is most often unilateral, hyposmia, anosmia, and headaches, which can vary depending on the condition of the nasal cavity. A subluxation of the septum (displacement of the ventral edge of the

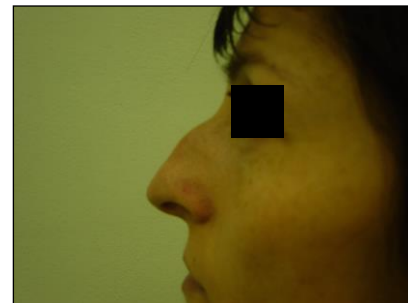
septum) can cause unilateral nasal obstruction and is especially likely after trauma.

**Diagnosis** is not difficult and it is based mainly on anterior rhinoscopy.

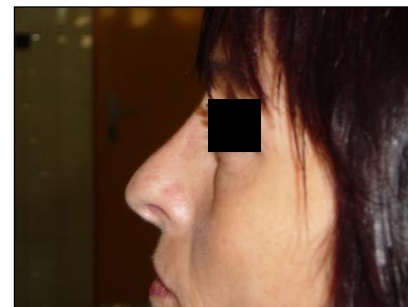**Treatment** is surgical. The principle of septoplasty is to remove all deviated/redundant portions of the cartilaginous and bony septum. Preservation of septal mucoperichondrium is paramount (see also Chapter 10.5). In the case of a twisted nose and the nasal septum the function of the nasal cavity can only be restored by simultaneous correction of the external nasal pyramid: septorhinoplasty.

#### Septorhinoplasty

Septorhinoplasty is a procedure which restores a normal form of the external nose (Figure 2.33). It harmonises with the rest of the face. By improving the nasal passages, it also restores the function of the nose with respect to respiration and olfaction. It is favourable to perform functional and aesthetic elements of the surgery at the same time. Septorhinoplasty should be carried out by a suitably trained rhinoplasty surgeon.



a



b

**Figure 2.33**

Septorhinoplasty – (a) before surgery, (b) after surgery



### Septal haematoma and septal abscess

**Definition.** Septal haematoma is the accumulation of blood between the perichondrium and septal cartilage.

**Aetiology.** It is caused by trauma to the external nose or septum. Blunt nasal trauma can lead to elevation of the mucoperichondrium/mucoperiosteum from the underlying cartilage/bone. A haematoma forms in the newly created perichondrial/periosteal space on one or both sides. Infection of the haematoma leads to a septal abscess. Septal haematoma or abscess is a possible complication of septal surgery.

**Symptoms.** Increasing nasal obstruction, tenderness, and pain. If an abscess forms, pain increases, and the patient complains of headache, fever, and redness of the bridge of the nose.

**Diagnosis.** History of trauma or nasal surgery. A septal haematoma can usually be diagnosed by inspecting the septum. Asymmetry of the septum with a bluish or reddish fluctuance may suggest a haematoma. Direct palpation may also be necessary. Blood clots should be suctioned to allow better visualisation.

**Treatment.** Urgent drainage is indicated for all nasal septal haematomas. Needle aspiration under topical anaesthesia can be performed and systemic antibiotics should then be administered. To drain the haematoma or abscess, incise the mucosa over the area of greatest fluctuance without incising cartilage. Destruction of the septal cartilage results in a saddle nose deformity.

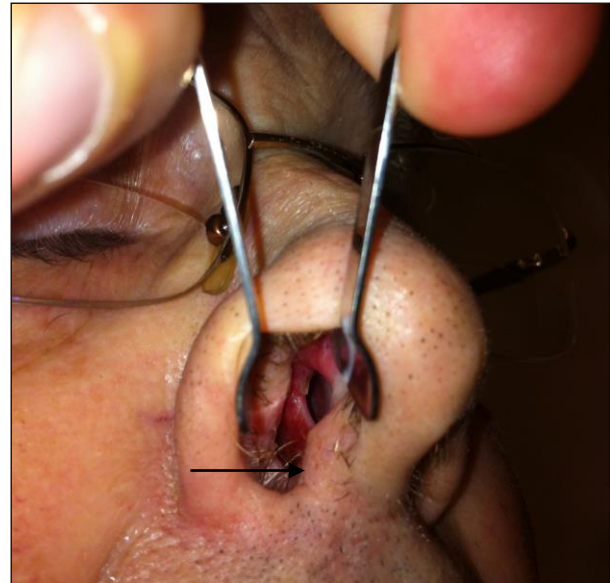
### Septal perforation

**Aetiology.** Septal perforation is usually the result of trauma, nasal surgery, rhinitis sicca anterior, cocaine sniffing, infection or occupational injury (Figure 2.34).

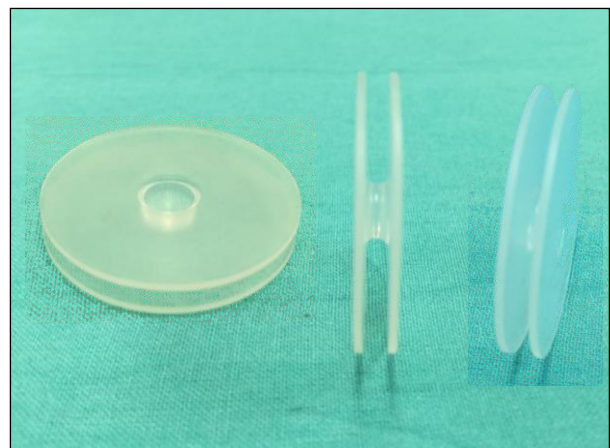
**Symptoms.** Septal perforations are usually asymptomatic. However, some patients may present with a history of nasal obstruction, crusting, intermittent episodes of epistaxis, malodorous discharge from the nose, or a whistling sound during nasal breathing.

**Treatment.** Perforations of the posterior septum are typically asymptomatic and, as such, rarely require treatment. Perforations of the anterior

septum may cause symptoms. Some help might be achieved with saline nasal irrigations or regular humidification to reduce crusting or intranasal application of antibiotic ointment. A preformed or customised silicone button obturator may relieve symptoms (Figure 2.35). Definitive treatment is a surgical closure of the perforation. The success rate of the surgery is dependent on the size of the perforation.



**Figure 2.34**  
Septal perforation



**Figure 2.35**  
Preformed silicone obturator

## 2.4.6 Epistaxis

**Definition.** Epistaxis or bleeding from the nose is a common problem that affects most people at some time. Usually it is mild, spontaneous and self-limiting, but it can be life-threatening and is often a frightening experience for the patient.

**Aetiology.** Causes of epistaxis are summarised in table 2.3. Local trauma is the most common cause, followed by facial trauma, foreign bodies, nasal or sinus infections, and prolonged inhalation of dry air. Children usually present with epistaxis due to local irritation or recent upper respiratory infection.

**Table 2.3** Causes of epistaxis

Local causes	Systemic causes
Environmental influences	Anticoagulants
Foreign body	Endocrine causes
Idiopathic causes	Haematological diseases
Infection	Hereditary haemorrhagic telangiectasia (Osler's disease)
Trauma	Hypertension
Tumour	

### First aid to stop a nosebleed:

- lean forwards
- apply digital pressure to both nasal alae for 5–10 minutes
- apply an ice pack to the nasal bridge
- avoid swallowing the blood
- deep, relaxed breathing

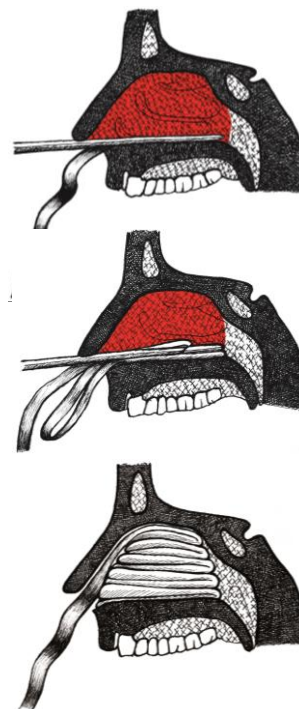
**Clinical features.** Epistaxis can be of an anterior or posterior type, on the basis of the site where the bleeding originates. The most common site of bleeding is the anterior nasal septum (90% of cases) due to its rich blood supply. The Kiesselbach plexus, or Little's area, is an anastomotic network of vessels located on the anterior cartilaginous septum. It receives blood supply from the internal carotid artery and the external carotid artery. Many of the arteries supplying the septum have anastomotic connections at this site.

Posterior epistaxis is more profuse, are often of an arterial origin, and present a greater risk of airway compromise, aspiration of blood, and greater difficulty controlling bleeding.

**Treatment.** There are several ways to stop the epistaxis.

### Cauterisation

In case of anterior epistaxis, place cotton pledgets soaked with an anaesthetic-vasoconstrictor solution into the nasal cavity for at least 10 minutes to anaesthetise and shrink the nasal mucosa. If this fails to stop the bleeding, chemical cauterisation using a silver nitrate stick applied directly to the bleeding site for approximately 30 seconds may be performed after the application of adequate topical anaesthesia. To prevent septal necrosis or perforation, only one side of the septum should be cauterised at a time. Larger vessels generally respond more readily to electrocautery. Thermal cauterisation is reserved for more aggressive bleeding and is done with the patient under local or general anaesthesia.

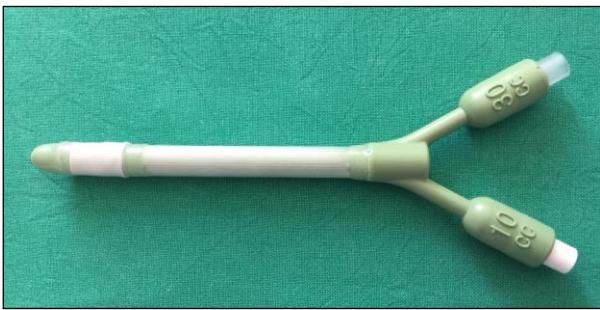


**Figure 2.36**

Anterior nasal packing

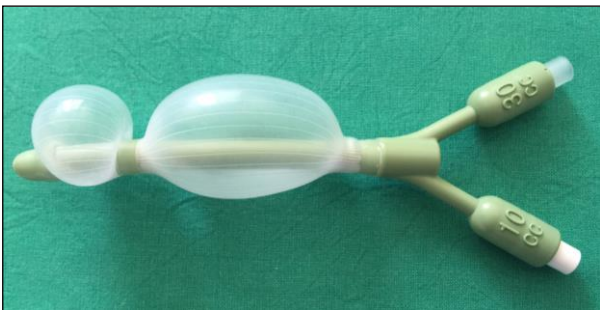
*Anterior nasal packing*

If local treatments fail to stop anterior bleeding, the nasal cavity should be packed with ribbon gauze impregnated with petroleum jelly/Vaseline. Forceps and a nasal speculum are used to approximate the layers of the gauze, which should extend as far back into the nose as possible. Each layer should be pressed down firmly before the next layer is inserted (Figure 2.36). Continue this process, layering the gauze from inferior to superior until the naris is completely packed. Both ends of the ribbon must protrude from the naris and should be secured with tape. If this measure does not stop the bleeding, consider bilateral nasal packing. Once the cavity has been packed as completely as possible, a gauze “drip pad” may be taped over the nostrils and changed periodically. Preformed systems for anterior nasal packing can be used. (Figure 2.37)



**Figure 2.37a**

Epistat Nasal Catheter – Epistat ready to be used

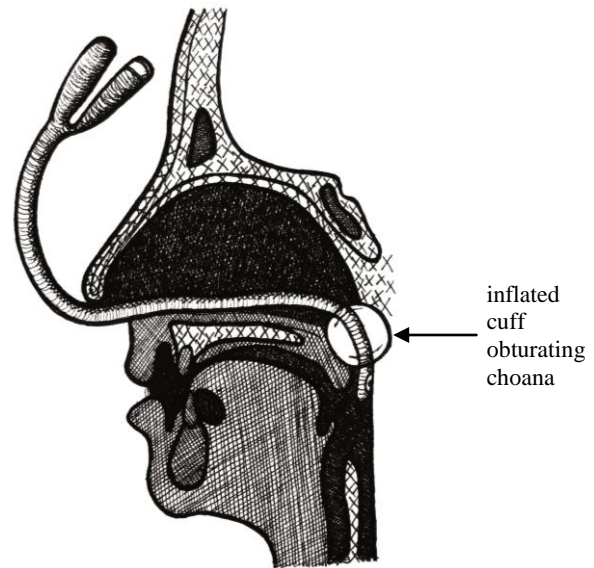


**Figure 2.37b**

Epistat Nasal Catheter – Epistat with inflated cuffs (10ml posterior, 20 ml anterior)

*Posterior nasal packing*

Bleeding from the posterior aspect of the nasal cavity is less common than anterior bleeding. Posterior packing may be accomplished by passing a catheter through one nostril, through the nasopharynx, and out the mouth. A gauze pack is then tied to the end of the catheter and positioned in the nasopharynx by pulling back on the catheter until the pack is placed in the posterior choana, sealing the posterior nasal passage and applying pressure to the site of the posterior bleeding. Cuffed catheter can be also used to seal the choana by inflation of the cuff. (Figure 2.38). The nasal cavities are then filled with Vaseline gauze. Posterior epistaxis can also be treated with double-balloon devices that have separate anterior and posterior balloons.



**Figure 2.38**

Posterior nasal packing

*Surgery*

In case of uncontrolled epistaxis, a surgical procedure might be necessary. Endonasal ligation of the sphenopalatine artery or the internal maxillary artery usually controls the bleeding. Other potential arteries to ligate are the anterior or posterior ethmoid artery, or the external carotid artery.

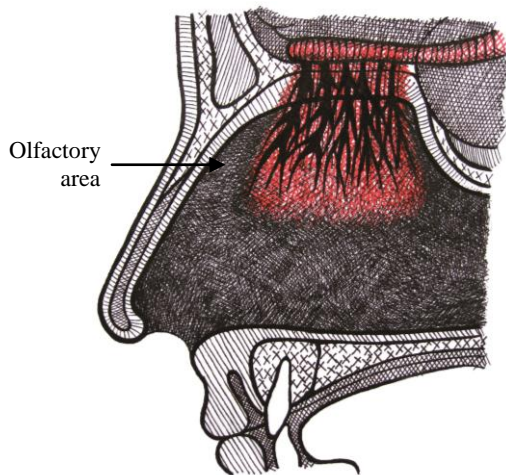


## 2.4.7 Disturbances of olfaction

**Definition.** Hyposmia is a reduced ability to detect odours. Anosmia is the complete loss of sense of smell. **Aetiology.** Olfactory receptors are located within the olfactory neuroepithelium, a region of tissue found over the cribriform plate, the superior septum and a segment of the superior turbinate (Figure 2.39). Common causes of olfactory disorders are summarised in Table 2.4.

**Table 2.4** Aethiology of olfactory disorders

Anterior skull base tumours
Exposure to chemicals (insecticides and solvents)
Head injuries
Hormonal disturbances
Idiopathic
Medications (antibiotics and antihistamines)
Polyps in the nasal cavities
Rhinosinusitis and other upper respiratory infections
Treatment of head and neck cancers (radiation, surgery)



**Figure 2.39**  
Olfactory area

**Diagnosis** is based on history and physical examination. It is important to ask about the type of olfactory disorder (anosmia, hyposmia, hyperosmia or dysosmia), health history, exposure to trauma, chemicals, use of medications, and an olfactory test. Physical examination may reveal nasal polyps, tumours or a deviated nasal septum.

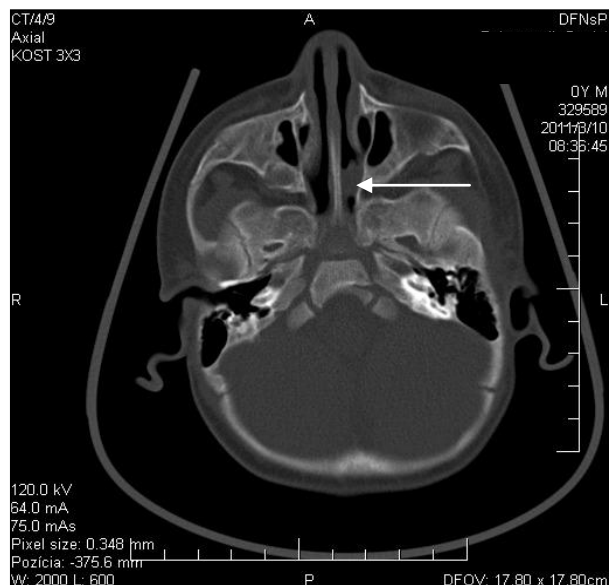Anterior skull base tumours will be diagnosed with imaging. A common diagnostic test consists of a booklet of sheets containing tiny beads filled with specific odours. Patients are asked to scratch each sheet and identify the odour.

**Treatment** depends upon the cause and can be medicaments, rehabilitation, or surgery (FESS).

## 2.4.8 Congenital defects of the nose

Developmental anomalies of the nose encompass a diverse group of conditions. Despite complicated embryological development of the nose, most significant congenital anomalies are rare.

**Choanal atresia** occurs in 1 in 5000 to 8000 live births and is a common cause of neonatal respiratory distress. It is twice as common in females as in males. About 65 to 75% of these anomalies are unilateral. About 30% are pure bony and 70% are mixed bony and membranous (Figure 2.40). Up to 75% of the bilateral cases have other associated anomalies, such as CHARGE (coloboma, heart defect, atresia choanae, retardation of growth, genital defects in males, and ear abnormalities).



**Figure 2.40**  
Choanal atresia; CT scan, axial plane

**Clinical features.** Unilateral choanal atresia, unless specifically sought at birth, may not become apparent or it presents as a unilateral nasal discharge until later childhood or even adulthood. Bilateral atresia, on the other hand, almost always presents as a respiratory emergency and is apparent at birth. Newborns are, by instinct, nose breathers. The reflexes, in the older child or adult, will result in breathing through the mouth in response to nasal obstruction; they do not develop until some weeks or months after birth. If the mouth is held open, either by insertion of an artificial airway or during crying, then mouth breathing will occur. Neonates with bilateral choanal atresia, or other causes of severe nasal obstruction, will sometimes demonstrate a cyclical change in oxygenation, becoming cyanosed during quiet periods, with normal colour returning when the child cries.

**Diagnosis** of bilateral choanal atresia is confirmed by the inability to pass a feeding catheter at least 3 cm through the nose into the nasopharynx. In addition, direct observation with nasal endoscopy and CT scanning are essential to determine the type of obstruction.

**Treatment.** Bilateral atresia is rarely emergent. The repair is generally delayed, allowing the operative site to enlarge, which reduces the risk of postoperative stenosis. Immediate management of bilateral atresia involves training the infant to breathe through the mouth with the aid of an indwelling oral appliance; a plastic oropharyngeal airway may be placed temporarily.

**Dermoid cysts** are masses that may contain skin, hair follicles, sebaceous glands, and sweat glands. They are different from epidermoids, which contain only epidermis and no elements of dermis. Unlike teratomas, which contain all three germinal layers, dermoids contain only ectoderm and mesoderm. Dermoids are the most common midline nasal mass. The treatment of choice is surgical excision after CT and MRI to evaluate for the presence of intracranial extension.

**Haemangiomas** are the most frequently occurring tumour in the head and neck in children. They may present anywhere in the head and neck. The nose is subject to external haemangiomas and

those involving the internal aspects of the nose, usually the turbinates. These lesions typically present at birth and tend to enlarge fairly rapidly. Most resolve spontaneously during the first 18 to 24 months of life. The imaging modality of choice for haemangiomas is MRI. If surgical intervention is not necessary to provide an airway or improve feeding, observation is the best initial therapy. Many lesions resolve spontaneously, usually with superior cosmetic results.

---

**Arhinia** is the congenital absence of the external nose, nasal cavities, and olfactory apparatus. This extremely rare entity is often associated with anomalies of the ocular and central nervous systems.

In **polyrrhinia**, two completely formed noses characterise this extremely rare anomaly. Duplication of medial nasal processes during embryogenesis is believed to cause polyrrhinia. Management consists of excision of the medial halves of each nose.

**Nasopharyngeal teratoma** concerns very rare lesions that contain tissues originating from the three embryological germ layers. Occasionally, teratomas display differentiation into organ systems. Such a teratoma is known as an *epignathus*. Investigations must rule out intracranial extension. CT scan and MRI are needed to determine relationship to the brain and meningeal coverings. If an intracranial component exists, a craniofacial approach is necessary. Prognosis is usually good.

**Nasal clefting** is a rare form of midline clefting commonly associated with hypertelorism and intracranial abnormalities. Nasal clefts can vary from a simple groove to complete separation of either side of the nose (median cleft), or they can present as a large furrow involving the medial canthus and ipsilateral alar. Depending on the severity of the defect, reconstruction may be warranted.

**Proboscis lateralis** (also known as congenital tubular nose) is an extremely rare anomaly in which the external nose fails to develop on one side and is replaced by a tubular structure emanating from the medial canthus.

**Heterotopic neural tissue** or **gliomas** may manifest as isolated ectopic brain tissue with only a fibrous band connecting it to the endocranium. A glioma may be of the external or endonasal type.

An **encephalocele** is caused by a defect of the foetal skull and contains an ependyma-lined cavity filled with cerebrospinal fluid.

**Pyriiform aperture stenosis** occurs secondary to bony overgrowth of the nasal process of the maxilla and presents in the first few months of life. It most commonly occurs as an isolated anomaly. The pyriiform aperture is the narrowest portion of the nasal cavity, and very small changes in the cross-sectional area may greatly increase nasal airway resistance and produce symptoms similar to bilateral choanal atresia.

---



### 2.4.9 Foreign bodies in the nose

*Epidemiology.* Foreign bodies in the nose are relatively common in the paediatric age groups (usually 18 months to 4 years of age).

*Clinical features.* A nasal foreign body should be suspected in all cases of unilateral childhood rhinorrhoea. The most common signs and symptoms are the nasal obstruction, foetor, unilateral rhinorrhoea and bleeding. Foreign bodies can be organic (nuts, vegetables, beans) or inorganic (parts of toys, batteries).

The button batteries should be removed from the nose urgently, because they can cause extreme irritation, producing chemical burns, with risk of septal perforation. The risk of aspiration is another potential complication.

*Treatment.* Most foreign bodies can be removed atraumatically in the clinic; in selected cases (very small child, agitated child), general anaesthesia may be required. The way of removal depends on the type of foreign body; the best way is to place an angled hood behind the foreign body and deliver it from the nose or by using microsuction or crocodile forceps in case of friable foreign bodies. Nasal endoscopy should be performed to ensure that the nasal cavity is free of foreign material.

### 2.4.10 Other diseases

#### **Granulomatosis with polyangiitis**

Granulomatosis with polyangiitis (GPA, previously known as Wegener's granulomatosis) is an uncommon disorder in which the walls of blood vessels become inflamed, leading to poor blood flow to tissues throughout the body. It is a serious condition that can be fatal if untreated. GPA can cause a wide range of symptoms, including sinusitis, persistent fever and night sweats.

Vasculitis mainly affects the nose, sinuses, ears, lungs and kidneys, although other organs can be affected too.

The exact cause of GPA is unknown. It is thought that GPA is an autoimmune disease; also, microbes and genetics have been implicated in its pathogenesis.

*Diagnostics.* Blood tests may be done to test levels of ANCA (antineutrophil cytoplasmic antibodies). Biopsy will show inflammation and granulomas.

*Treatment and prognosis.* High doses of steroid medications (prednisone), plus cyclophosphamide, are administered. Surgical treatment is reserved for the treatment of complications. The impact of disease can vary depending on its severity, the organs involved, and complications related to the disease or its treatment. Even with effective treatment, relapses are common.

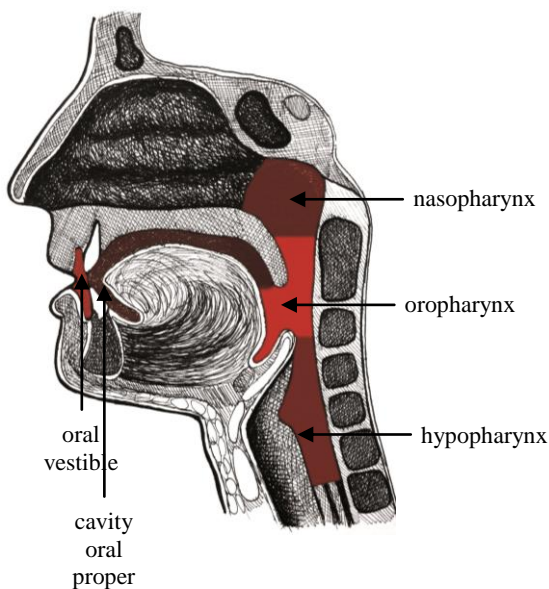


# 3 ORAL CAVITY AND PHARYNX

## 3.1 APPLIED ANATOMY

### Oral cavity

The oral cavity contains the upper and lower dentition, the tongue and floor of the mouth, the hard and soft palate, and the openings of the major salivary glands. It is bounded by the lips anteriorly, by the floor of the mouth inferiorly, by the soft and hard palates superiorly, and by the anterior faucial arch posteriorly (Figure 3.1). The oral cavity is oval-shaped and is divided into two compartments: the vestibule (vestibulum oris) and the oral cavity proper (cavum oris).



**Figure 3.1**

Oral cavity and pharynx, lateral view

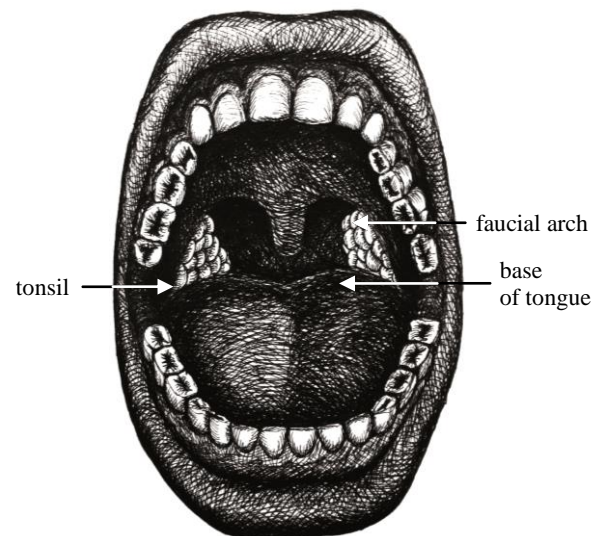
The oral vestibule is the space external to the maxillary and mandibular alveolar ridges and teeth and within the lips and buccal mucosa. The parotid duct (Stensen's duct) opens opposite the upper second molar.

When the teeth are in occlusion, the vestibule communicates with the oral cavity proper via the intermaxillary commissure behind the last molar teeth.

The lips are musculo-fibrous folds that are connected to the gums by superior and inferior frenula.

The median part of the upper lip shows a shallow external groove, the *philtrum*. The lips consist of skin, the orbicularis oris muscle, mucous glands, and mucosa. The cheeks, which contain the buccinator muscle and buccal glands, resemble the lips in structure.

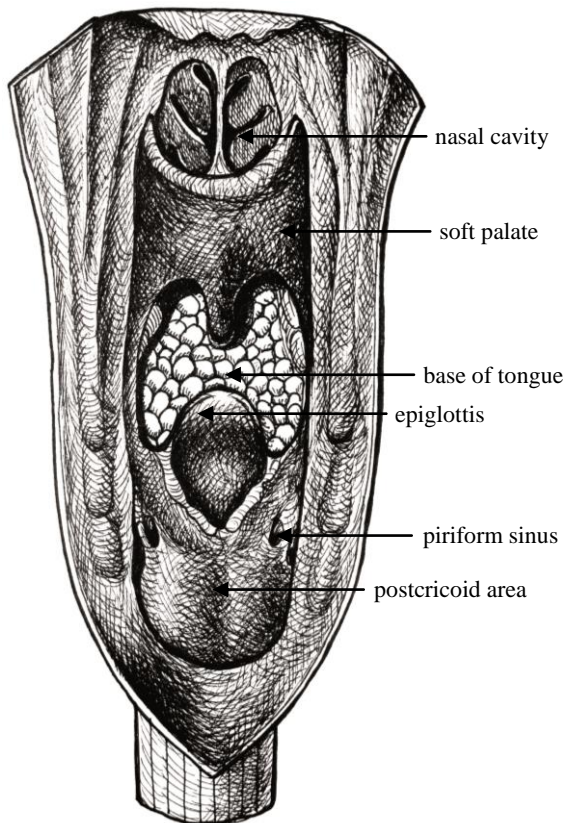
The oral cavity proper is the space bounded by the hard and soft palate superiorly and the lingual mucosa inferiorly. The palate is the horseshoe-shaped, domed roof of the oral cavity. It is divided into a hard portion and a soft portion. The hard palate is part of the oral cavity and separates it from the nasal cavities. The soft palate is part of the oropharynx and separates it from the nasopharynx. The anterior pillars of the palatine tonsils separate the oral cavity from the oropharynx. The faucial arch and the base of a tongue form *faucial isthmus* (Figure 3.2).



**Figure 3.2**

Faucial isthmus

**The tongue** is important for taste, mastication, swallowing, and speech. It is composed of skeletal muscle that is almost completely covered by mucous membrane. It occupies most of the oral cavity and oropharynx. Posterior to its tip lies the body of the tongue, which has dorsal (superior) and ventral (inferior) surfaces and lateral borders. The terminal sulcus, or groove, is a V-shaped furrow that separates the body from the base of the tongue, runs laterally and anteriorward from a small pit (the foramen cecum), and contains gustatory papillae. The foramen cecum, when present, indicates the site of origin of the embryonic thyroglossal duct. The base of the tongue contains the *lingual tonsil*. The posterior third of the tongue is continuous posteriorly with the epiglottis; between these two areas lie two small depressions known as valleculae (Figure 3.3).



**Figure 3.3**

Orohypopharynx, posterior view, posterior pharyngeal wall divided

#### Lingual papillae

The surface of the body of the tongue derives its characteristic appearance from the presence of lingual papillae. There are four types of lingual papillae: vallate (circumvallate), foliate, filiform, and fungiform.

#### Lingual muscles

The lingual muscles are extrinsic and intrinsic. The extrinsic muscles are attached to the mandibular, styloid, and hyoid bones. They are the genioglossus, styloglossus, and hyoglossus and are able to move the tongue in various directions. The intrinsic muscles are the superior and inferior longitudinal, transverse, and vertical and, because of their orientation, impart great diversity to the movements of the tongue.

**The floor of the mouth** forms the inferior limit of the oral cavity. It is supported by the mylohyoid muscles which stretch between the rami of the mandible and are joined in the midline. The inferior surface of the tongue is connected to the floor of the mouth by the frenulum. The sublingual papillae can be identified on both sides of the frenulum in the anterior part of the floor of the mouth when the tip of the tongue is raised. The excretory duct of the submandibular gland (Wharton's duct) runs in the floor of the mouth along the medial border of the sublingual gland to pierce the surface of the mouth at the paramedian sublingual caruncle. The sublingual glands have multiple small ducts that drain directly into the floor of the mouth (see Chapter 8).

The *mandible* forms the skeleton of the lower jaw and the inferior part of the face. The movements of the mandible are mainly produced by the four muscles of mastication: the masseter, temporalis, lateral pterygoid, and medial pterygoid muscles. The palatine processes of the *maxillae* and the horizontal plates of the *palatine bones* form the anterior bony part of the palate.

The mucosal lining of the oral cavity is nonkeratinised stratified squamous epithelium. The oral cavity has 500–1000 minor salivary glands imbedded within the mucosa and submucosa of the cheeks, lips, floor of the mouth, hard and soft palates, retromolar trigone, and tongue; the anterior hard palate and gingivae are devoid of these glands.

**The blood supply** is from branches of the *external carotid artery*. The main artery of the

tongue is the lingual artery. The floor of the mouth is supplied by the sublingual artery, the cheek by the facial artery, and the palate by the ascending pharyngeal and descending palatine arteries.

The arteries are accompanied by the veins of the same names and the venous drainage runs to the facial vein and internal jugular vein.

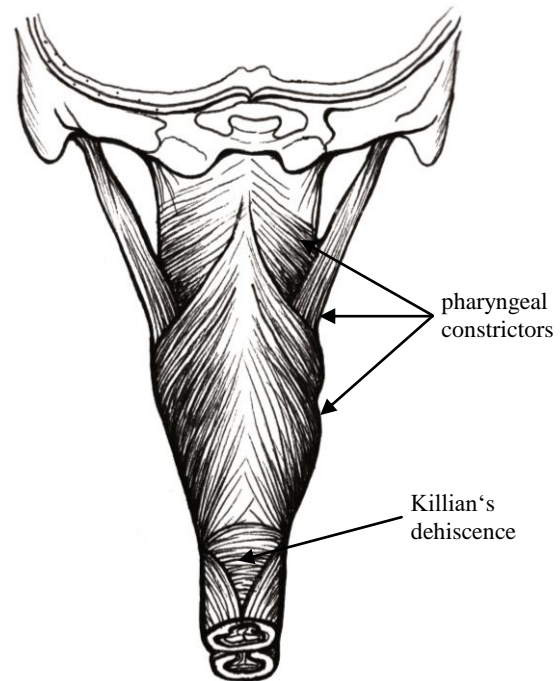
**The lymphatic drainage** of the oral cavity is composed of both superficial and deep vessels that ultimately drain into the submental, submandibular, and deep cervical nodes. The lymphatic drainage is to ipsilateral nodes in the internal jugular chain, but the anterior floor of the mouth and base of the tongue drain to both sides of the neck.

The sensory **nerve supply** of the tongue is from the *lingual nerve* in the anterior two thirds and *glossopharyngeal nerve* posteriorly. The lingual nerve, a branch of the mandibular division of the fifth cranial nerve, also receives the chorda tympani from the *facial nerve*. The motor supply is from the *hypoglossal nerve*. Sensory innervation to the lips, cheeks, gingivae, teeth, hard palate, and floor of the mouth is provided by the *trigeminal nerve*, more specifically the maxillary and mandibular divisions of this nerve. Branches of the mandibular division also supply the four muscles of mastication, but the motor innervation of the buccinator and orbicularis oris muscles is supplied by the buccal branch of the facial nerve.

### Pharynx

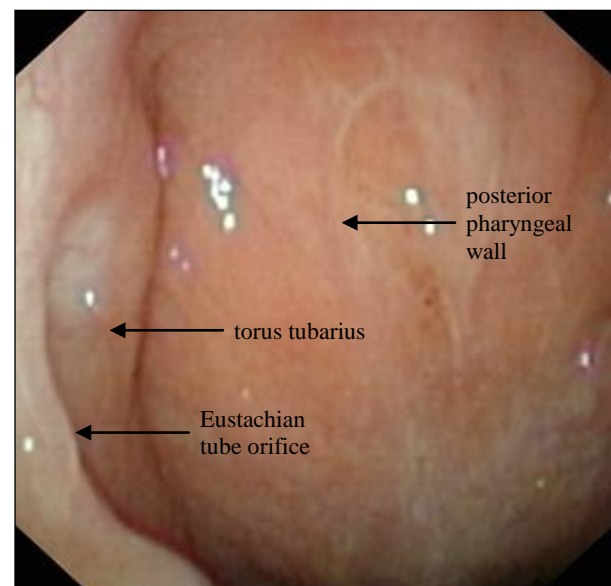
The pharynx is a fibromuscular tube approximately 12 cm long that serves both the respiratory and digestive tracts. It extends from the base of the skull to the inferior border of the cricoid cartilage. The posterior and lateral walls of the pharynx are composed of three pharyngeal constrictor muscles which form the posterior pharyngeal raphe (Figure 3.4). The pharynx has anterior openings into the nasal and oral cavities, and inferiorly it opens into the larynx and oesophagus.

The pharynx is divided into three segments: the nasopharynx, the oropharynx, and the hypopharynx.



**Figure 3.4**

Pharyngeal constrictors – posterior view



**Figure 3.5**

Nasopharynx – endoscopic view

**The nasopharynx** is a posterior extension of the nasal cavity. The choanae form its anterior limit



and it extends from the skull base to the soft palate. Its superior and posterior walls are continuous and formed by the body of the sphenoid bone, basilar process of the occipital bone, and the first two cervical vertebrae. The most prominent feature of the nasopharynx is the posterolaterally located pharyngeal ostium of the auditory tube. The torus tubarius, which is a prominent cartilaginous elevation, marks the posterior boundary of the Eustachian tube orifice. The fossa of Rosenmüller (pharyngeal recess) is a deep recess just posterior to the torus tubarius. The adenoid tissue (pharyngeal tonsil) lies on the posterosuperior surface (Figure 3.5). The epithelial lining is respiratory ciliated and stratified squamous epithelium, with transitional epithelium at the junction with the oropharynx.

---

#### **Eustachian tube**

The Eustachian tube, which opens into the nasopharynx, is responsible for protection, ventilation, and clearance of secretions from the middle ear cleft. Adequate function of the levator veli palatini and tensor veli palatini is essential for normal Eustachian tube function. Children with anatomic abnormalities of the palate, such as cleft palate, and dysfunction of these muscles are likely to develop middle ear effusion and otitis media. Enlarged, nasopharyngeal lymphoid tissue may also affect Eustachian tube function.

---

**The oropharynx** is the region between the soft palate and the base of the tongue, down to the superior tip of the epiglottis. It is continuous with the oral cavity through the faucial isthmus. The posterior boundary consists of the prevertebral fascia and second and third cervical vertebrae. The lateral wall contains the palatine tonsil, the palatoglossal and palatopharyngeal arches. The parts of the oropharynx are also the valleculae, the base of the tongue, the anterior surface of the soft palate, the uvula, and the lingual surface of the epiglottis. The epithelial lining is nonkeratinising stratified squamous epithelium.

**The hypopharynx** is situated laterally and posterior to the larynx and extends from the superior border of the epiglottis, where it is delineated from the oropharynx by the lateral glossoepiglottic folds, to the inferior border of the cricoid cartilage, where it becomes continuous

with the oesophagus. It can be divided into three sites: the pyriform sinus, the postcricoid area, and the posterior pharyngeal wall (Figure 3.6). The mucosal lining of the hypopharynx is stratified squamous epithelium and has a rich submucosal network of lymphatics.

---

#### **Anatomy of the hypopharynx**

The pyriform sinus is a funnel-shaped structure that begins superiorly at the glossoepiglottic fold and extends inferiorly with its apex at the level of the cricopharyngeus. It is bounded laterally by the thyroid lamina and posteriorly by the mucosal lateral wall of the hypopharynx which leads to the posterior pharyngeal wall. Its medial boundary is the lateral surface of the arytenoid. The posterior pharyngeal wall extends from a plane drawn at the level of the tip of the epiglottis to a plane at the inferior border of the cricoid. The superior and inferior margins of the hypopharynx blend with the posterior wall of the oropharynx and oesophagus, respectively. The postcricoid area includes the posterior surface of the aryepiglottic fold and posterior surface of the arytenoid to the inferior border of the cricoid cartilage.

---

---

#### **Pharyngeal musculature**

There are two types of muscles that form the walls of the pharynx: *circular* and *longitudinal* muscles.

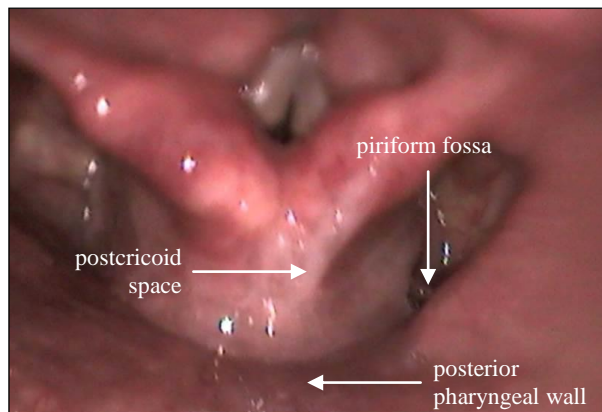
The circular or constrictor muscles contract sequentially from superior to inferior to constrict the lumen and propel the bolus of food inferiorly into the oesophagus: the superior constrictor muscle, the middle constrictor muscle, and the inferior constrictor. The inferior pharyngeal constrictor has two components: the thyropharyngeus and the cricopharyngeus. During swallowing, the thyropharyngeus contracts as the cricopharyngeus relaxes; if this coordinated relaxation of the cricopharyngeus does not occur, the intrapharyngeal pressure tends to rise and pharyngeal mucosa forms a midline diverticulum. Pharyngo-oesophageal pouches, which are pulsion diverticula (Zenker's diverticulum), may develop at this weak point (Killian's dehiscence) in the wall of the hypopharynx.

*The longitudinal muscles* shorten and widen the pharynx, and elevate the larynx during swallowing.

---

**The blood supply** to the pharynx is derived from branches of the *external carotid artery*, the ascending pharyngeal and tonsillar branches of the external maxillary artery, and from the descending palatine branch of the internal maxillary artery. The tonsillar arteries, branches from the external maxillary artery, are the chief vessels to the tonsil, although the ascending palatine sometimes takes their place. The tonsillar arteries (or ascending

pharyngeal artery) pass upwards through the superior constrictor muscle, giving off branches to the soft palate and tonsil. The dorsal lingual artery ascends to the base of the tongue and sends branches to the tonsil and tonsillar pillars. The descending palatine artery supplies the tonsil and soft palate from above, forming an anastomosis with the ascending palatine. *The venous drainage* is provided by the pharyngeal venous plexus, which drains into the internal jugular vein.



**Figure 3.6**

Hypopharynx – endoscopic view

**The nerve supply** of the majority of the pharynx is provided by the pharyngeal plexus, which is comprised of branches of the glossopharyngeal nerve, the vagus nerve, and sympathetic fibres of the superior cervical ganglion. Each of the three sections of the pharynx has a different sensory innervation. The nasopharynx is innervated by the maxillary nerve, the oropharynx by the glossopharyngeal nerve, and the laryngopharynx by the vagus nerve. All of the muscles of the pharynx are innervated by the vagus nerve, except for the stylopharyngeus, which is innervated by the glossopharyngeal nerve.

**The lymphatic drainage** is to the superior and middle deep jugular nodes. Inferiorly, the lymphatics drain is to the paratracheal and low deep jugular nodes.

The pharynx is covered by a complete ring of lymphoid tissue called *Waldeyers's ring*; it is comprised of the adenoids (pharyngeal tonsils),

the palatine tonsils, the lingual tonsil and lateral pharyngeal bands, scattered lymphoid follicles and nodules near the Eustachian tube.

#### **Waldeyers's ring**

The adenoid or pharyngeal tonsil is a lobulated mass of lymphoid tissue found on the superior and posterior walls of the nasopharynx. Unlike the palatine tonsil, the adenoid has no capsule. The incoming air from nasal breathing contacts the adenoid, and foreign substances initiate immune responses. The adenoids are capable of considerable hyperplasia and can obstruct the airway under adverse conditions.

The palatine tonsil is a large mass of lymphoid tissue located in the lateral part of the fauces, between the glossopalatine and pharyngopalatine arches. The lateral surface of each palatine tonsil is covered by pharyngeal fascia and attached to the superior pharyngeal constrictor muscle. The free surface of the tonsil is covered by a closely adherent stratified squamous epithelium that extends into blind pouches or crypts. The crypts, 8 to 10 in number extend deep into the substance of the tonsil. With swelling of the tonsil, the bottom of the crypts remains relatively fixed; thus, the crypts become longer. Above the tonsil and between the pillars is the supratonsillar fossa.

The tubarius tonsil is lymphoid tissue localised in the submucous layer in the nasopharynx, posterior to the pharyngeal ostium of the auditory tube.

The mucosa of the dorsum of the tongue, posterior to the foramen caecum and the sulcus terminalis, is rough and freely mobile over the nearby parts. It has numerous lymph follicles which form the lingual tonsil.

## 3.2 PHYSIOLOGY

The mouth and pharynx have several functions, including mastication, swallowing, taste, immune-specific function, and articulation.

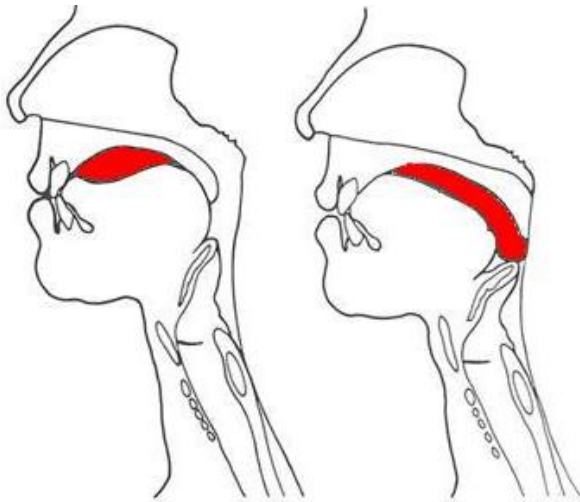
The oral cavity and its structures provide the first stage of the process of digestion. The oral cavity receives food, chews and mixes it with saliva, and then begins the swallowing process. The taste buds on the tongue provide the different sensations of taste. The oral cavity plays an important role in speech. The mouth is also used for breathing, drinking, facial expressions, and social interactions (such as kissing). It also serves as a secondary respiratory conduit, a site of sound modification for the production of speech, and a chemosensory organ. The pharynx must provide

two potentially conflicting functions. It must rapidly constrict during swallowing, yet maintain patency during the negative pressure generated by inspiration. Breathing and speech must be interrupted during a swallow.

### 3.2.1 Swallowing

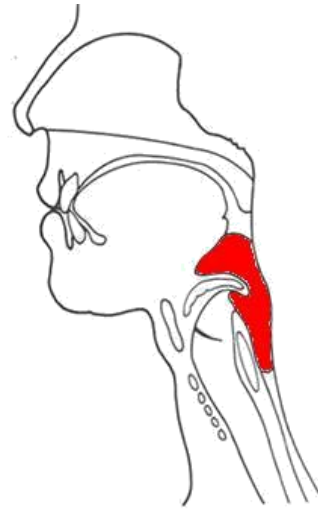
Swallowing is a complex and sophisticated function and it is divided into four overlapping phases: oral preparatory phase, oral phase, pharyngeal phase, and oesophageal phase. The first two are voluntary; the latter two are involuntary.

The oral phase is the first one and involves the preparation of a food bolus in the oral cavity using the teeth, tongue and masticatory muscles. The reflex part of swallowing is initiated by the placement of the food bolus posteriorly by elevation of the tongue and entry to the oropharynx. The soft palate is initially tensed to squeeze the bolus of food between the tongue and pharynx before elevation of the soft palate to block the nasal passages while the bolus is propelled into the pharynx.



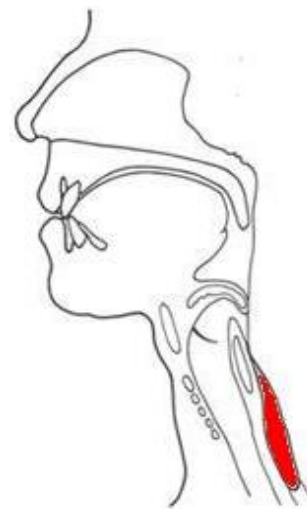
**Figure 3.7a**

Phases of swallowing – Oral preparatory and oral phase



**Figure 3.7b**

Phases of swallowing – Pharyngeal phase



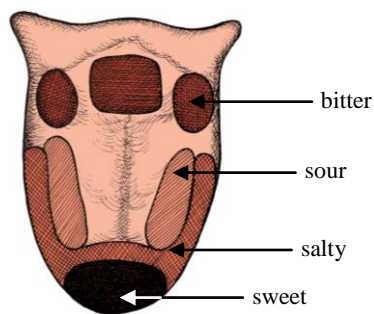
**Figure 3.7c**

Phases of swallowing – Oesophageal phase

The respiration is inhibited, the nasopharynx is closed by elevation of the soft palate, and the larynx is elevated. The pressure in the pharynx is decreased and the food passes the larynx into the piriform fossae into the oesophagus. Relaxation of the cricopharyngeus muscle and peristalsis of the oesophagus transport the food to the stomach (Figure 3.7).

### 3.2.2 Taste

The sensory organs for taste are the gustatory or taste buds. These buds are made up of four different cell types which are found in the lingual epithelium (Figure 3.8). The taste buds in the human tongue, soft palate, pharynx, larynx, epiglottis, and oesophagus are not distributed evenly. Most taste buds are found in the tongue. Taste should not be confused with flavour, as the latter is actually a combined perception of gustation and olfaction.



**Figure 3.8**  
Tongue taste areas

The basic taste sensations are *sweet*, *salty*, *sour*, and *bitter* and *umami* tastes. Umami (monosodium glutamate/5' nucleotide) is the most recently discovered taste sensation. It is a naturally occurring ingredient in many Asian foods.

The taste sensations are transmitted to the tractus solitarius in the brainstem via two different routes. Afferent fibres from anterior thirds travel from the tongue in the chorda tympani nerve, which join the facial nerve in the middle ear and pass into the posterior cranial fossa. Fibres from the posterior third pass via the glossopharyngeal nerve and enter the posterior fossa. Much of what we perceive as taste is really olfaction. Testing of taste is very difficult due to the problems of standardising stimuli.

### 3.2.3 Immune-specific function of Waldeyer's ring

Waldeyer's ring tissue serves as a defence organ against infection and plays an important role in the

development of the immune system. It comprises the first organs in the lymphatic system that analyse and react to airborne and alimentary antigenic stimulation.

The tonsils and adenoids contain four lymphoid compartments (the crypt epithelium, the follicular germinal centre with the mantle zone, and the interfollicular area), which all participate in the immune response. The generation of B cells in the germinal centres is the most essential function. Waldeyer's ring functions as part of mucosa-associated lymphoid tissue (MALT). It also shows similarities to lymph nodes and may, in addition, participate as effector organs of the local systemic type as well as mucosal secretory type of adaptive humoral immunity. Waldeyer's ring constitutes an antigen sampling centre where the extraneous antigens are caught and sampled, stimulating the immune mechanism. Antigens from inspired air are trapped by the adenoid and the tubal tonsils. These antigens, in turn, stimulate release of immunoglobulins by the B lymphocytes. To facilitate exposure and trapping of antigens the mucosa covering the adenoid is thrown into grooves called furrows. These furrows serve to increase the surface area of the adenoid tissue; similarly, antigens from ingested food are captured and sampled by the lingual and palatine tonsils. The mucosa covering the palatine tonsils is thrown into numerous crypts (about 18–20 in each tonsil). These crypts serve to increase the surface area of mucosa covering the tonsil. The palatine tonsils are part of the mucosa-associated lymphoid tissue and probably process antigen and present it to T helper cells and B cells. The tonsillar tissue mainly produces IgG and IgA. These immunoglobulins pass directly into pharyngeal secretions.

### 3.2.4 Speech

The speech process involves the speech centres of the brain, the respiratory centre in the brain stem, the respiratory system, the larynx, the pharynx, the nose and nasal cavities, and the structures of the mouth and related facial muscles.

The production of speech requires:

- a source of air flow (lungs),
- a sound generator (vocal folds),
- a resonator (pharynx and oral cavity; the nose is also included in the resonating chamber when the palate is lowered).

Articulators change the form of the vocal tract. The structures that affect articulation are the lips, tongue, mandible, teeth, palate, pharynx, and larynx.



Articulators play the dominant role in producing speech sounds represented by consonants. Along with the nose, the nasopharynx is a resonating chamber that contributes to the quality of the voice. Loss of resonating capacity due to velopharyngeal incompetence produces a hyponasal voice or rhinolalia clausa. For certain vowels, a proper velopharyngeal opening is necessary to avoid non-nasal speech.

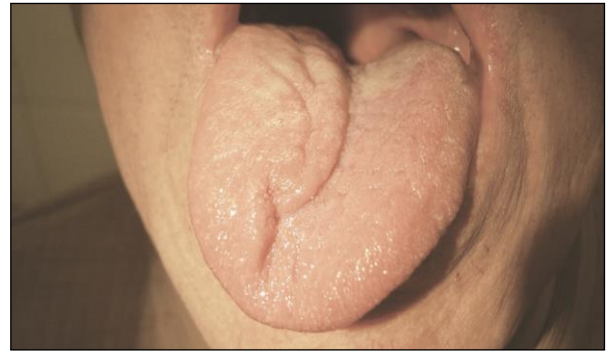### 3.3 EVALUATION

It is important to take a good *general medical history*, since a wide variety of systemic conditions can present with oral symptoms and signs. The main symptoms that indicate disease of the oral cavity and pharynx include: pain on eating, chewing, swallowing (odynophagia), pain in the neck, in the ear (referred otalgia), dysphagia, globus symptoms, disorders of speech, taste, salivary functions, respiration, foetor ex ore or halitosis, bleeding, snoring, and swelling of the neck or of the floor of the mouth. As with examination of other regions of the head and neck, the examiner should continue the examination of the oral cavity and pharynx with inspection and palpation. The examination must be systematic and methodical.

#### Oral cavity

Clinical examination requires a bright light and a tongue depressor. During the examination, attention is paid to all structures of the oral cavity; the following should be observed:

- the colour and mobility of the lips;
- the shape and upper surface of the tongue, the edges (common site of carcinomas), the under surface, and the mobility of the tongue (Figure 3.9);
- floor of the mouth with the submandibular gland duct;
- teeth and gums, mobility of the mandible, function of temporomandibular joint;
- the colour, moisture, dryness, ulcerations, and tumours of the mucosa;
- the parotid duct openings;
- hard and soft palates, movements of the soft palate, and the position of uvula.



**Figure 3.9**

Atrophy of the tongue and right-sided deviation, lesion of right hypoglossal nerve

Bimanual palpation of the floor of the mouth and base of the tongue with the index finger wearing a glove is used to palpate any suspicious area carefully for induration, infiltration, ulceration and tender areas. The contralateral hand is gently pressed against the submandibular gland and the neck (see Figure 8.6).

#### Pharynx

Physical examination of the pharynx requires a mirror or endoscope. Indirect mirror examination is limited by patient cooperation and the mirror distortion of the image.

*The nasopharynx* may be visualised using a mirror. *Nasopharyngoscopy*, either with a flexible or rigid telescope, provides excellent visualisation of most of the important structures, including the adenoid, Eustachian tubes, and choanae. This can also be done under general anaesthesia, when suspicious areas can be palpated or biopsied.

*The oropharynx* is examined using a bright light and two tongue depressors. The palatine tonsils, lingual tonsil, and mucosa of the posterior wall of the pharynx are examined. During the examination of the palatine tonsil we focus on moisture, dryness, colour, shape, size, fixation, ulceration, tumours, streams of mucopurulent secretions, bleeding, expressed contents of the tonsillar crypt, and colour and symmetry of faucial pillars.

*The hypopharynx* is examined indirectly with the mirror or preferably using a flexible endoscope in



the outpatient office or a rigid endoscope under general anaesthesia. Any abnormal areas that may be suspicious of a tumour require biopsy.

Flexible endoscopy is the method of choice in examination of the nasopharynx, hypopharynx or larynx.

### Imaging

Diagnostic evaluation of the oral cavity and pharynx is primarily done by clinical examination, endoscopy and directed biopsy. The main reasons for imaging the oral cavity and pharynx are as follows: evaluation and staging of tumours; searching for an unknown head and neck primary tumours in patients with metastasis to cervical lymph nodes; to image inflammatory and infectious diseases and their complications; to evaluate congenital lesions of this area.

*Computerised Axial Tomography (CT)* and *Magnetic Resonance Imaging (MRI)* can be employed to aid diagnosis and staging. CT scanning is more readily available; however, its main disadvantage is the use of radiation and artifacts originating from dental implants distorting the images. MRI is preferred to assess soft tissue abnormalities.

*Ultrasonography (USS)* can be used for dedicated evaluation of certain pathological conditions of the floor of the mouth and tongue, such as salivary calculi and inflammatory and congenital lesions. It is also employed to evaluate abnormal lymph nodes and to provide guidance for fine needle aspiration cytology (FNA).

*Angiography* is used for the investigation of highly vascularised tumours (juvenile angiofibroma).

---

#### Narrow band imaging (NBI)

*Narrow band imaging* is a novel endoscopic diagnostic tool that improves the visibility of vessels and other tissues on the mucosal surface. Narrow band illumination is strongly absorbed by haemoglobin and penetrates only the surface of tissues, allowing detection of neoplastic superficial mucosal lesions at the stage of dysplasia or carcinoma in situ. NBI can be used for diagnosis of oral, pharyngeal or laryngeal pathologies.

---

*Fluoroscopic studies* can be used to assess various aspects of swallowing. They include barium and water soluble swallow and videofluoroscopy (modified barium swallow, VFSS, MBS). *Flexible endoscopic evaluation of swallowing (FEES)*, *pH measurements* or *manometric analysis* can also be used, mostly in diagnostics of swallowing disorders.

---

#### Diagnosics of swallowing disorders

Several specialised diagnostic methods can be used to study the anatomy and physiology of swallowing. In general, various food consistencies, volumes, postural techniques, and swallowing manoeuvres to enhance swallowing efficiency or safety are tested during the studies, and clinical decisions (e.g. changing food viscosity, finding appropriate swallowing postures or manoeuvres) are made. The most critical finding is aspiration. **Patients with severe chronic aspiration are deemed unsafe for oral feeding!**

*Videofluoroscopy (VFSS, modified barium swallow (MBS))* focuses on the oral, pharyngeal, and oesophageal stages of swallowing, is performed by the speech and language therapist together with the radiologist and takes place in the Radiology Department.

The *Flexible Endoscopic Evaluation of Swallowing (FEES)* is a procedure used to evaluate the pharyngeal stages of swallowing. A flexible endoscope is passed transnasally to the oropharynx. Patients are seated and are offered a variety of food consistencies while the swallow is viewed on a monitor.

---

## 3.4 DISEASES OF THE ORAL CAVITY AND PHARYNX

### 3.4.1 Congenital anomalies

#### Cleft lip and palate

*Definition.* Cleft lip and palate are the most common congenital malformations of the head and neck, occurring approximately once in every 700 births.

*Aetiology.* Many syndromes have been described that include clefting of the lip and palate. The majority of clefts occur without any obvious genetic component or family history. Environmental influences that have been associated

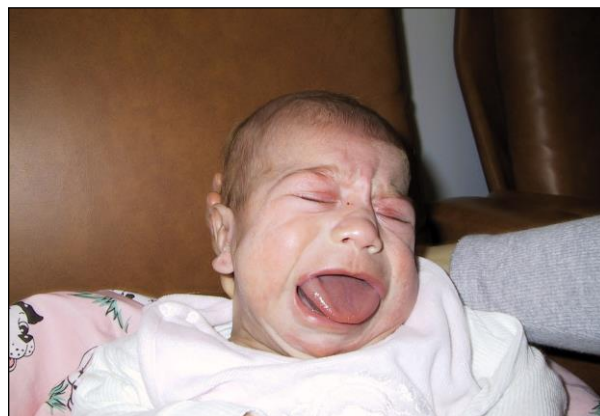
with clefts are smoking, alcohol, steroids, folic-acid deficiency, exposure to pesticides, and the use of antiepileptic drugs in pregnancy. Patients with a cleft are recognised as nonsyndromic when they have no other associated head and neck anomalies, no organ system malformations, any known teratogenic or environmental exposure history that predisposes to clefting, and normal cognitive function and physical growth.

**Clinical features.** A cleft lip can occur alone or with a cleft palate. The cleft lip can be unilateral (on one side of the lip) or bilateral. The anatomic deformity associated with a cleft lip and palate involves the soft tissues of the lip and nose, the cartilaginous and bony supporting structures of the nose and palate, and the underlying bony maxilla.

**Evaluation and treatment** of the child with a cleft lip and/or cleft palate require a long-term comprehensive and multidisciplinary approach in terms of medical, surgical, dental, and psychological intervention. The reconstructive surgery should be performed by experts working as a multi-disciplinary team. Syndromic clefts are those that are part of, or associated with, a recognised pattern of human malformation or syndrome. Surgical treatment is tailored to the given anatomic defect.

### Other congenital abnormalities

Defects in the formation and growth of the jaw, oral cavity, and pharynx lead to a variety of malformations. Congenital lesions of the tongue include *aglossia*, *microglossia*, and *macroglossia* (Figure 3.10). *Ankyloglossia* owing to varying degrees of underdevelopment of the lingual frenulum is relatively uncommon. A *congenital epulis* or *gingival granular cell tumour* arises exclusively from the alveolar ridge and is a rare lesion of an unknown origin found in newborn female infants. *Teratomas* are true neoplasms that contain tissues foreign to the site in which they arise. Teratomas grow aggressively, and in the head and neck, they most commonly occur in the cervical area, followed by the nasopharynx. Teratomas of the nasopharynx typically arise on the lateral or superior wall.



**Figure 3.10**  
Macroglossia

Four basic types are recognised:

- dermoid cyst, the most common form, composed of ectoderm and mesoderm arising as an epithelium-lined cavity with variable numbers of skin appendages;
- teratoid cyst, derived from all three germ layers but poorly differentiated;
- true teratoma, composed of ectoderm, mesoderm, and endoderm, with specific tissue and organ differentiation;
- epignathus, in which well-developed foetal parts are recognisable; this type of teratoma arises from the soft or hard palate and is frequently incompatible with life.

Clinically, dermoids are more common than true teratomas, and in the nasopharynx, the dermoid cyst is the most common developmental anomaly found.

---

### EXIT procedure

EXIT procedure (ex utero intrapartum treatment procedure), is a specialized surgical delivery procedure used to deliver babies who have airway compression. Causes of airway compression in newborns result from a number of rare congenital disorders as listed above. In many cases, the airway compression is discovered during prenatal ultrasound examination, permitting time to plan a safe delivery using the EXIT procedure. The baby is partially delivered through the opening of extended Caesarian section but remains attached by its umbilical cord to the placenta and thereby fully oxygenated, while a pediatric otolaryngologist-head & neck surgeon establishes an airway so the fetus can breathe. Once the EXIT is complete, the umbilical cord is cut and the infant is fully delivered.

---

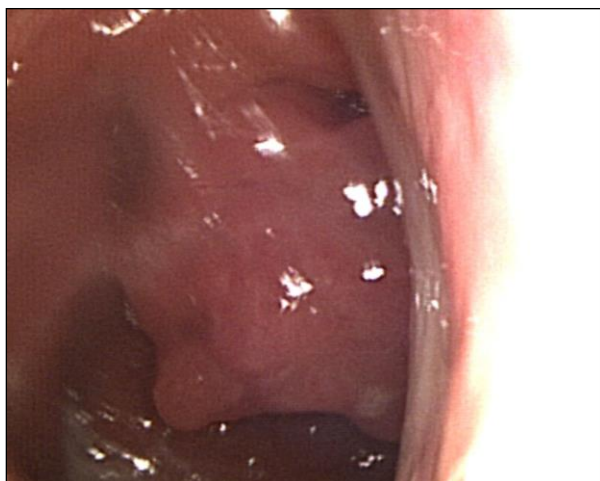### 3.4.2 Hypertrophy of lymphoepithelial organs

Enlarged adenoids and tonsils play a major role in obstructive sleep apnoea (OSA) in children. Adenoidectomy and tonsillectomy are the most common surgical procedures performed in children; however, some of their indications are controversial. When performed for the proper indication, these operations improve quality of life and can be lifesaving in children with severe OSA syndrome. Currently, the most common indications for adenoidectomy and/or tonsillectomy are enlarged tonsils and adenoids, recurrent adenotonsillitis, recurrent sinusitis, middle ear effusion, and OSA syndrome.

#### Adenoid hyperplasia

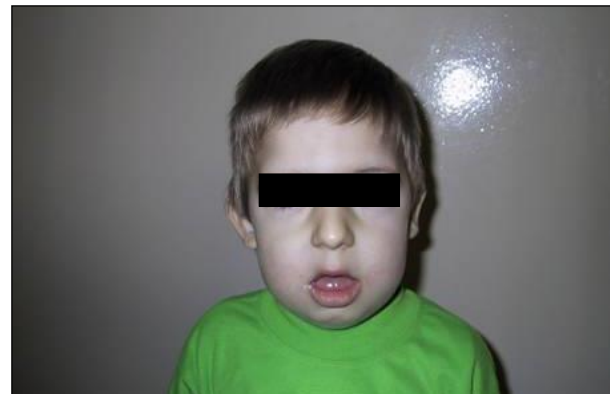*Definition.* Enlarged pharyngeal lymphoid tissue is the primary cause of sleep-disordered breathing in children.

*Clinical features.* Nocturnal symptoms include snoring, mouth breathing, sleep pauses or breath holding, gasping, enuresis, and restless sleep. During the day, the children present with behavioural problems, morning headaches, dry mouth, halitosis, audible breathing, open-mouth posture, hyponasal speech, chronic nasal obstruction with or without rhinorrhoea and middle ear effusion (Figure 3.11)..



**Figure 3.11**  
Adenoid hyperplasia

Nasal obstruction may cause abnormal dentofacial growth. Downwards growth of the mandible and repositioning of the tongue may compensate for the absence of nasal airflow. This may increase the vertical dimension of the face. "Adenoidal facies" has been defined as a long, thin face with molar hypoplasia, high-arched palate, narrow maxillary arch, and malocclusion (Figure 3.12). The patients with severe obstruction present with *sleep apnea syndrome*. Children with sleep apnea are more likely to develop problems with learning, attention, and behaviour.



**Figure 3.12**  
Adenoid face

*Treatment.* Adenoidectomy is indicated in cases (see Chapter 10.3).

#### Tonsillar hyperplasia

*Clinical features.* Tonsillar hyperplasia can contribute to obstructive sleep apnoea syndrome (OSAS). OSAS is characterised by reduction (hypopnoea) or cessation (apnoea) of oronasal airflow despite respiratory effort. Untreated OSAS can cause failure to thrive, aspiration, chest infections, and cor pulmonale.

*Treatment* is surgical — tonsillectomy or intracapsular tonsillar resection (tonsillotomy) (see Chapter 10.1).

#### OSAS

OSAS is usually multifactorial and caused by obstruction of the airway at different anatomical levels. OSAS is common in children with developmental delay, neurological impairment and craniofacial dysmorphism. Hyperplasia of the adenoids and tonsils is a common cause of nasal obstruction and mouth breathing during childhood. Snoring is a manifestation of partial airway obstruction. It may occur alone or in

association with hypopnoeas, infrequent apnoeas or as part of overt OSAS. The evaluation of a child with suspected OSAS should include the examination of the oropharynx, nasopharynx, and classification of obstruction. Flexible endoscopy of the upper airway is frequently used if the child is cooperative. Flexible endoscopy of the upper airway during sleep or during sleep induced by sedation (sleep nasendoscopy) may be useful in selected children. Not all OSAS is due to adenotonsillar hypertrophy. Polysomnography remains the gold standard for an objective correlation of ventilatory abnormalities. Sleep studies involve the simultaneous measurement of multiple physiological variables during sleep. These include oxygen saturation, the volume and frequency of oronasal airflow, spirometric volumes and flow rates, and respiratory muscle excursions. Electrocardiography, blood pressure, electroencephalography and carbon dioxide are recorded as well.

### 3.4.3 Inflammatory diseases

For didactic reasons, the inflammatory diseases in this chapter are divided according to their prevalent localisation, as follows:

- mucosa of the oral cavity
- tongue
- oropharynx/nasopharynx

Some diseases can be specific for a certain region; others can affect several areas. The length of the inflammation can be divided into acute and chronic.

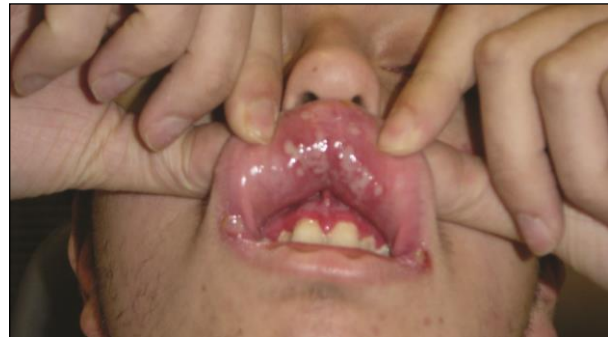#### ORAL CAVITY

Many non-specific and specific infections affect the lips, gingiva, tongue or the mucosa of the oral cavity. This chapter covers some of the most clinically relevant diseases.

**Rhagades of the commissures**, also known as **angular cheilitis**, along with slight bleeding and pain in the commissures accompanying the opening of the mouth. Causes include ill-fitting false teeth, mycotic infection, poor general resistance, diabetes, iron-deficiency anaemia, nonspecific pyogenic infections, and syphilis. If possible, the cause should be confirmed and dealt with before treatment is attempted.

**Cheilitis (inflammation of the lips)** may be solitary and acute due to trauma, thermal injury

(hot food), chemical injury (smoke), actinic damage (sunburn), or exposure to radiation. Although tuberculosis or syphilis, primary or secondary, may occur on the lips, a chronic or recurrent erosive or hyperkeratotic lesion of the labial mucosa must always be suspected of being premalignant (leukoplakia, Bowen disease). Numerous diseases affecting the oral mucosa also affect the lips (Figure 3.13).



**Figure 3.13**  
Cheilitis

**Cheilitis granulomatosa** is a chronic recurring disease which is usually associated with a complete Melkersson–Rosenthal syndrome of cheilitis, granulomatous glossitis, and facial paralysis. The pathogenesis of this triad is unknown.

**Stomatitis (inflammation of oral mucosa)**, often combined with gingivitis or inflammation of the buccal mucosa, may be a primary disease of many different causes or may be secondary to other diseases. The clinical symptoms and prognosis are thus extremely variable.

#### Ulceomembranous stomatitis

*Clinical features* are redness, swelling, and sensitivity to pressure on the gingival margins. The disease often progresses to ulceration with severe pain. The disease may spread to the pharynx, and the regional lymph nodes may be enlarged and painful.

*Pathogenesis* includes poor oral hygiene, reduced general resistance, dental damage, virus infections with possible secondary bacterial infection, mucosal rhagades or gingival pockets. Bacterio-

logic culture often reveals spirochetes and fusiform rods.

*Treatment* includes appropriate oral and dental hygiene or application of 1–2% of gentian violet. Antibiotics are given if indicated by culture and sensitivity tests.

### **Herpes simplex stomatitis**

*Definition and clinical features.* Burning sensation in the mouth, difficulty in eating, a feeling of being unwell, fever in the early stages, and clear vesicles in the mouth. The vesicles may progress to superficial circular or oval ulcers with a red centre. The disease often occurs in conjunction with febrile general infections or overexposure to sunlight and is very contagious.

*Aetiology.* The cause is infection with the herpes simplex virus and usually occurs first in childhood. 90% of the population are said to be carriers of the virus, but clinical manifestations in the form of herpes labialis or stomatitis herpetiformis occur in only 1%.

*Treatment and prognosis.* Systemic antiviral therapy is most effective. Recurrent cases can often be controlled with topical measures including anaesthetics or topical antiviral agents (acyclovir, penciclovir). This disease is usually harmless and lasts for 1–2 weeks. The vesicles heal to form crusts, but do not form scars.

**Drug-induced stomatitis (Stevens–Johnson syndrome)** is a reaction to certain drugs, leaving blisters. This may be observed particularly after the use of bromides, iodides, salicylates, antibiotics, and sulfonamides, psychoactive drugs that dry the mouth, and antiepileptic agents, and after pyrimidone, barbiturates, laxatives such as phenolphthalein, and the contraceptive pill.

### **Allergic stomatitis**

Hypersensitivity reactions on the oral mucosa and the lips, with varying severity, with or without angioneurotic oedema, may be observed in response to almost all drugs, dental material, mouthwashes, toothpaste, cosmetics, chewing gum, and also to some foods, e.g. fruit, fish, protein, and milk.

### **Candidal stomatitis**

*Clinical features.* Burning in the mouth and tongue with superficial white foci, and exudates on the mucosa.

*Aetiology.* In normal individuals, almost all cases of oral yeast infections are caused by *Candida albicans*; rarely, other agents may be involved in severely immunosuppressed hosts. Candidiasis affects individuals with diabetes mellitus, reduced resistance, and after prolonged administration of antibiotics, chemotherapy, steroids, oral contraceptives, and after radiotherapy.

*Diagnosis* is made clinically and it is characterised by membranous white or grey exudates and very inflamed mucosa. A specimen is taken for culture for fungi.

*Treatment and prognosis.* Antimycotics are administered, and good oral hygiene is also crucial. The prognosis is good if the patient is relatively healthy. In immunosuppressed individuals, there is a risk of systemic spread if treatment is not adequate.

### **Herpes zoster**

*Definition.* Herpes zoster is an infection resulting from reactivation of the varicella-zoster virus.

*Clinical features.* Unilateral rapidly progressive vesicles are quickly followed by fibrinous superficial epithelial defects, affecting the segments of the face innervated by the second and third divisions of the trigeminal nerve. The disease is very painful.

*Pathogenesis.* This is a neurotropic infection with the varicella-zoster virus, which is morphologically identical to the herpes simplex virus. The diagnosis is established on the basis of the typical segmental arrangement of the vesicles and severe pain.

*Treatment.* Prompt institution of high-dose regimens of systemic antiviral agents (acyclovir, valacyclovir, famciclovir) within 48 h has been shown to reduce the duration and severity of the acute disease and somewhat reduce the risk of postherpetic neuralgia. In severe cases or immunosuppressed patients, intravenous acyclovir should be considered. The disease is often followed by severe, therapy-resistant neuralgias,



which may persist for months after resolution of the mucosal lesions. The generalised form in older patients may be an indication of a systemic malignancy or immunosuppression.

### **Ludwig angina**

*Definition.* Ludwig angina is rapidly expanding diffuse inflammation of the floor of mouth, submandibular and sublingual spaces often caused by dental infections.

*Clinical features and diagnosis.* The patient's floor of mouth is swollen, the tongue might be swollen or elevated. A CT scan is most useful.

*Treatment.* Airway control is the first priority of treatment, followed by i.v. antibiotics and timely surgical drainage.

### **Acquired Immune Deficiency Syndrome (AIDS)**

*Definition.* Human immunodeficiency virus infection and acquired immune deficiency syndrome (HIV/AIDS) are a spectrum of conditions caused by infection with the human immunodeficiency virus (HIV).

*Clinical features.* Approximately 35–40% of HIV infections are associated with otorhinolaryngologic symptoms. Early symptoms may include angular cheilitis and Kaposi sarcoma, which may represent the first sign of the disease. HIV infection has a relatively high association with cervical lymphadenopathies, candidiasis, herpes simplex, and herpes zoster. Other potential manifestations of HIV infection include sinusitis, tonsillitis, gingivitis, pharyngitis, esophagitis, tracheitis, sudden hearing loss, facial paralysis, and facial pain.

*Treatment.* The HIV virus cannot be eliminated by any of the current treatment regimens.

Highly active anti-retroviral therapy (HAART) using multiple drugs may offer long-standing control and patients may lead normal lives.

### **Chronic aphthae (recurrent aphthous stomatitis)**

*Definition and clinical features.* These are recurrent oral ulcerations, generally small with an erythematous base. Aphthae occur intermittently,

affecting the buccal mucosa, the tongue, the palate, and the gingiva, and are very painful. The regional lymph nodes may be swollen, and concomitant stomatitis is possible.

*Aetiology.* The cause is unknown. The disease is not thought to be infectious, but instead to represent activation of intrinsic inflammation in susceptible individuals. Aphthae can be triggered by infections, hormonal factors such as menstruation, and certain foods.

*Diagnosis* of aphthous stomatitis is based on history and clinical features. No specific tests are available and prophylactic *treatment* is not known. Symptomatic treatment includes borax solution, chlorhexidine, and topical corticosteroids. The lesions heal without scarring in 1–3 weeks. The course may extend over decades, and familial occurrences are known.

### **Behcet disease**

*Diagnosis.* Behcet disease is characterised by a triple-symptom complex of recurrent oral aphthous ulcers, genital ulcers, and uveitis.

*Clinical features.* Aphthae occur in groups in the mouth and on the genitals. The cause of the disease is unknown. It may be generalised vasculitis, an autoimmune event, or a virus infection.

*Diagnosis.* The main, and often the first, symptom is involvement of the eye. Acute cochleovestibular disturbances may also occur.

*Treatment* relies on immunosuppressive medication. Oral mucosal lesions can be treated locally with topical corticosteroids, and gentle rinses. With treatment, the symptoms can be eased, the mucosal infections can be reduced, and the disease can be controlled over a lifetime.

---

### **Syphilis**

This infection is caused by *Treponema pallidum* and is treated with penicillin. All stages of syphilis can occur in the mouth.

*Stage I (primary syphilis):* primary chancres occur on the lips, tonsil, anterior part of the tongue, commissure, gingiva, and buccal mucosa. It presents as a sharply delimited nodule 2–3 mm in diameter. After a few days, a painless ulcer forms, with a very hard edge, and there is painless regional lymphadenopathy in the submandibular or jugulodigastric area. The primary lesion regresses spontaneously after 3–6 weeks.

*Stage 2 (secondary syphilis):* Eight to 10 weeks after the infection a superficial exanthema develops in the oral cavity. Dark-red mucosal spots (a few millimetres in size) form, with a tendency to merge. The lesions are of varying severity and last for several weeks. Dark-red papules form gradually, and also flat areas with a cloudy epithelial surface. The surface of the tongue looks like sugar icing with areas of loss of papillae.

*Stage 3 (tertiary syphilis):* A gumma develops (on average) 15 years after the primary infection.

*Diagnosis.* Demonstration of the organism by culture and dark-ground illumination is used in stages 1 and 2. Serologic tests become positive from the fourth week. In stage 3, serologic reactions are positive and the disease can be demonstrated by histology.

*Differential diagnosis.* In stage 1 lesions, tuberculosis, mycoses, and herpes should be considered; in stage 2, erythema multiforme and tuberculosis; in stage 3, malignant tumours and leukaemia.

### **Tuberculosis**

Tuberculosis is an infectious bacterial disease caused by various strains of mycobacteria, especially *Mycobacterium tuberculosis*. It is characterised by the growth of nodules (tubercles) in the tissues. Round, non-painful nodules occur in groups in mucosal lupus, and they demonstrate yellowish-brown flecks in the oral mucosa on pressure with a spatula. Flat, dirty, exudative, painful ulceration with undermined edges and lymph node involvement is found in ulcerative mucosal tuberculosis.

*Pathogenesis.* The oral cavity is nowadays almost never a primary site of manifestation of tuberculosis. The disease is usually due to haematogenous or intraluminal spread from the primary site, usually the lung.

*Diagnosis* is made by biopsy and culture, and chest radiography. The original focus in the lung is *treated* by antituberculous medications by respiratory physicians.

**Syphilis and tuberculosis are reportable diseases.**

### **Hyperkeratosis and leukoplakia**

*Definition and clinical features.* These are clinical terms and include a velvety or nodular epithelial lesion, hyperkeratosis, a flat epithelial plaque or white thickening that cannot be wiped off.

*Aetiopathogenesis.* It is an epithelial process with many different causes, including exogenous irritative factors such as chronic mechanical irritation by the irregular edge of teeth, irritation from a ill fitting denture, smoking, excess alcohol consumption, lichen planus, syphilis, and lupus erythematosus. There may also be no recognisable cause. The probability of malignant degeneration depends largely on the degree of histologic dysplasia. The

frequency of progression of leukoplakia to carcinoma increases with the degree of the dysplasia.

Leukoplakia is a clinical diagnosis and can represent hyperkeratosis, candidiasis, premalignant lesions and cancer. Leukoplakia should always be regarded as being potentially premalignant and should therefore be investigated and followed up carefully.

*Diagnosis* is made by biopsy and histological examination.

*Treatment* consists of surgical removal and avoidance of possible causative agents.

**Bowen's disease (erythroplakia)** is a clinical diagnosis and means "red patch".

*Clinical features.* It is a premalignant lesion or carcinoma in situ.

*Aetiopathogenesis.* This is an intraepithelial squamous cell carcinoma with an intact basal membrane; the tumour has not yet invaded the subepithelial layer. It occurs on the skin or mucosa. Progression to true squamous cell carcinoma is possible at any time and is very common.

*Diagnosis and treatment.* The lesion must be biopsied and, as a treatment option, excised with an adequate margin.

### **Lichen planus**

*Definition.* This is a fairly common, itchy, non-infectious type of rash that usually occurs in adults over the age of 40.

*Clinical features.* The mucosal appearance of lichen planus can be specific, with a lacy network of white lines or streaks. More often, there are nonspecific lesions on the buccal mucosa, gingiva, and tongue. Blue-grey, smooth, tiny papules are sometimes also found on the dorsum of the tongue. The lesions cannot be wiped off and are firm. The ulcerations can be very painful.

*Aetiology* is unknown.

*Classification.* Lichen planus was originally classified as one of six forms: reticular pattern, plaque form, papular pattern, bullous form, atrophic

form, and ulcerative form. The classification has been difficult to use because many patients may have several forms at any given time.

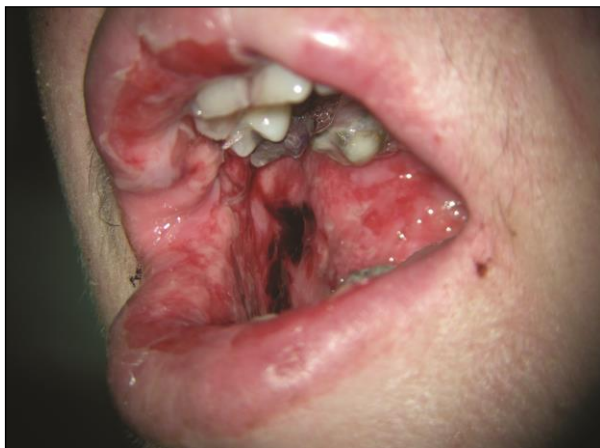*Diagnosis* is based on clinical findings, and if in doubt, patients may require a biopsy to exclude malignancy. In contrast to the skin, lichen planus in the mouth is a potentially premalignant disease.

*Treatment.* Possible predisposing agents such as sunlight, tobacco, and chemical agents should be avoided. The disease may not require any treatment if patients are asymptomatic and malignancy has been excluded. It is not curable, but is controllable with topical corticosteroids.

### **Pemphigus**

*Definition and aetiology.* Pemphigus vulgaris is an autoimmune, intraepithelial, blistering disease affecting the skin and mucous membranes. It is mediated by circulating autoantibodies directed against keratinocyte cell surfaces. A potentially life-threatening disease, it has a mortality rate of approximately 5–15%.

*Clinical features.* The first symptom is often in the mouth and takes the form of flat soft or tense vesicles. These give way to superficial epithelial erosions with a fibrin layer and epithelial tags at the edge. The course is episodic, and several stages may be present at any one time. There is oral foetor, often regional lymphadenopathy, and a bullous eruption on the skin.



**Figure 3.14**  
Pemphigus vulgaris

*Pathogenesis.* Pemphigus vulgaris is a well-established autoimmune disease.

*Diagnosis.* Histology may suggest the diagnosis. Differential diagnosis includes stomatitis, hereditary epidermolysis bullosa, erythema multiforme, lichen planus, and mucosal pemphigoid.

*Treatment.* Systemic corticosteroids and immunosuppressive agents are administered under the supervision of a dermatologist (Figure 3.14).

## **TONGUE**

### **Glossitis**

*Definition.* Glossitis is inflammation of the tongue.

*Clinical features* include a burning sensation, especially at its tip and edges, and frequent taste alteration. On the tongue itself, only minimal mucosal lesions can be demonstrated, such as circumscribed inflammation or loss of papillae.

*Pathogenesis.* Causative factors include mechanical irritation by sharp teeth, dental calculi, pressure from dentures, intolerance to dental materials, vitamin B12 deficiency (Hunter glossitis), megaloblastic anaemia, iron-deficiency anaemia (Plummer–Vinson syndrome), diabetes, and gastrointestinal diseases, including cirrhosis and mycoses.

*Diagnosis.* The diagnosis is based on the detection or exclusion of mechanical irritation, sensitivity reactions, diabetes, gastrointestinal or haematologic diseases, and also on the mycologic findings. Finally, the diagnosis can be made by exclusion of all other causes.

*Treatment.* The cause should be eliminated if possible. The patient should avoid very hot, cold, or spicy foods and heavy alcohol consumption. Often, systemic psychotropic medications are required for relief of discomfort.

### **Allergic glossitis**

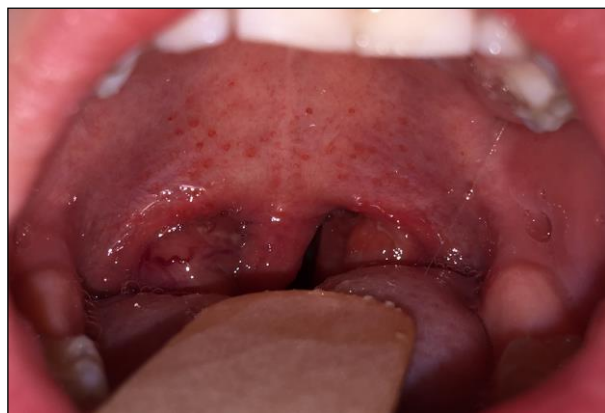The signs are similar to those of nonspecific glossitis, except that the disease begins suddenly with swelling and redness of the tongue, with swelling and pain progressing to itching. There is a danger of respiratory obstruction if the reaction progresses to oedema.

*Treatment* is both symptomatic and antiallergic.

## OROPHARYNX/NASOPHARYNX

### Acute tonsillitis

**Definition.** Tonsillitis is inflammation of the pharyngeal tonsils. The inflammation usually extends to other parts of the pharynx; therefore, the terms pharyngitis, tonsillopharyngitis and adenotonsillitis may also be used (Figure 3.15).



**Figure 3.15**  
Acute tonsillitis

**Clinical presentation.** Acute tonsillitis usually begins with high temperature and possibly chills, especially in children. The patient complains of a burning sensation in the throat, persistent pain in the oropharynx, pain on swallowing (odynophagia), and pain radiating to the ear on swallowing. Opening the mouth is often difficult and painful, the tongue is coated, and there is halitosis. The patient also complains of headaches, thick speech, a marked feeling of malaise, and swelling and tenderness of the regional lymph nodes. If the symptoms worsen and multifocal symptoms occur, a generalised disorder expressing itself, particularly in the lymphoepithelial organs, should be suspected. On the other hand, there are also tonsillar infections in which the generalised symptoms are minimal and only the local changes can be recognised.

Both tonsils and the surrounding area, including the posterior pharyngeal wall, are deep red and swollen. In *catarrhal* tonsillitis there is no exudate on the tonsil. Later, yellow spots corresponding to

the lymphatic follicles form on the tonsils, hence the term *follicular* tonsillitis. Alternatively, yellow spots occur over the openings of the crypts, a condition known as *lacunar* tonsillitis. A membrane occurs in *pneumococcal* tonsillitis, but it is seldom confluent and rarely spreads beyond the tonsil.

**Pathogenesis.** Viral or bacterial infections and immunologic factors lead to the development of tonsillitis (and its complications). Most episodes of acute pharyngitis and acute tonsillitis are caused by the following viruses: herpes simplex virus, Epstein–Barr virus (EBV), cytomegalovirus, adenovirus, and measles virus. A virus infection may prepare the way for secondary bacterial infection. The most common bacteria causing tonsillitis are  $\beta$ -haemolytic streptococci.

**Diagnosis.** The diagnosis is based on the clinical findings as described above: full blood count (FBC), the erythrocyte sedimentation rate (ESR), C-reactive protein (CRP), Paul Bunnell or infectious mononucleosis testing and urinalysis.

**Differential diagnosis.** This includes scarlet fever, diphtheria, infectious mononucleosis, agranulocytosis, leukaemia, hyperkeratosis of the tonsils, stage 2 syphilis, and, in unilateral disease, ulceromembranous tonsillitis, peritonsillar cellulitis or abscess, tuberculosis, and tonsillar tumours. Differential blood count can be done to exclude mononucleosis and leukaemia.

**Table 3.1** Other forms and types of acute tonsillitis

<b>Nasopharyngitis</b>	The symptoms are localised mainly or exclusively to the adenoids.
<b>Lingual tonsillitis</b>	Symptoms are localised to the base of the tongue.
<b>Infection of the lateral bands</b>	A specific form of infection of the lateral, tubopharyngeal bands, especially in patients who have had their tonsils removed. It may be a “substitute” infection in the absence of tonsils.

**Treatment.** The standard treatment in patients with streptococcal tonsillitis is penicillin V for 10–14



days. Oral cephalosporins or macrolides can be used in patients allergic to penicillin. As acute tonsillitis is a systemic, rather than local, disease, treatment should include bed rest, analgesics, a bland liquid diet, and ice packs. The patient should be observed for complications. Local care should include oral and dental hygiene.

### **Infectious mononucleosis (glandular fever)**

*Definition.* This is an infection caused by the Epstein–Barr virus, which chiefly affects children and adolescents.

*Clinical presentation.* Patients often present with fever in the range of 38–39°C and marked lymphadenopathy of the jugulodigastric group and the deep cervical chain, later becoming generalised. The tonsil is very swollen and is covered with a fibrinous exudate or membrane. The patient has rhinopharyngitis, hepatosplenomegaly, pain in the neck on swallowing, and a marked feeling of being unwell. The blood picture initially shows leukopenia, and then leukocytosis with a white blood cell count of 20,000–30,000 or more, 80–90% of which are mononuclear cells and atypical lymphocytes. Approximately 30% of IM develops secondary bacterial infections with *β haemolytic Streptococcus*.

*Diagnosis.* This is made from the clinical findings, the characteristic blood picture, and the Paul Bunnell test (demonstration of heterophile antibodies in the serum).

*Treatment.* Symptomatic treatment includes oral hygiene and measures to reduce fever. Antibiotics may be given in secondary bacterial infection. An allergy-like rash may occur in response to ampicillin.

---

#### **Other forms of tonsillitis**

Most of these are rare and some are almost eradicated, so clinicians hardly ever see them during their career.

**Herpangina.** Vesicles form initially, particularly on the anterior faucial pillar, but are very fleeting and are therefore not often seen. The tonsils are often only slightly red and swollen. The organism is coxsackievirus. Treatment is symptomatic.

**Scarlet fever.** The tonsils and pharyngeal mucosa are deep red; there is pain on swallowing, severe malaise, progression to lacunar tonsillitis, and regional lymph-adenopathy. After approximately 24 hours, a typical exanthema appears, beginning on the upper part of the body. At the same time, a

definite reddening of the tip and edges of the tongue appears, extending later to the entire tongue: strawberry tongue. The type A haemolytic streptococcus is responsible. Treatment is based on penicillin, oral hygiene, and analgesics.

**Diphtheria.** The infection is due to a diphtheria bacillus, *Corynebacterium diphtheriae*. Patients experience temperatures of ≈38°C and no more than 39°C. There is slight pain on swallowing and often a very high pulse rate. The tonsils are moderately reddened and swollen, with a white or grey velvety membrane that becomes confluent, extends beyond the boundaries of the tonsil to the faucial pillars and soft palate, and is fixed firmly to its base. The membrane can only be wiped off with difficulty and it then leaves a bleeding surface behind. The jugulodigastric lymph nodes are very swollen, tender, and often hard. There is a characteristic smell of acetone on the breath.

*Treatment.* On the earliest reasonable suspicion of diphtheria (possibly before bacteriologic confirmation), the patient should be isolated and treated with antiserum administered intramuscularly. In addition, i.v. penicillin G should be given, or, alternatively, erythromycin for 14 days. Diphtheria immunisation with diphtheria toxoid is protective but does not become effective for several weeks.

**Syphilitic tonsillitis.** All stages of syphilis may be encountered in the oropharynx. After 3 weeks, the primary lesion appears on the lips, buccal mucosa, tonsils, and tongue. Typically, the primary chancre is painless, consisting initially of a papular lesion that develops into an ulcer. Palpable regional lymph nodes are present. Approximately 6 weeks after the primary infection, white, hazy mucosal plaques appear on the tonsils, faucial pillars, and soft palate. The hard palate is usually spared. Later, they progress to dark-red papules. Signs of stage 2 infection are usually present in other parts of the body. The tertiary stage appears after 15–30 years.

**Tonsillar tuberculosis.** This disease causes a superficial erosive ulcer with a necrotic slough.

**Agranulocytosis.** The patient feels very sick and has a typical blood picture. The disease occurs mainly in older individuals. There is ulceration and necrosis of the tonsils and pharynx, with a blackish exudate, severe pain in the neck and on swallowing, sialorrhoea, and oral foetor. There is no regional lymphadenopathy. The patient should be in the care of a haematologist.

**Plaut–Vincent angina (ulceromembranous pharyngitis).** Unilateral pain on swallowing, and there is ipsilateral swelling of the jugulodigastric nodes. There is an ulcer, which is often deep, on one tonsil, with a whitish exudate, and the site of predilection for this is the upper pole. The local findings are often impressive in contrast to the symptoms, which are often mild. There may only be a feeling of a foreign body in the throat, and the patient also has a characteristic oral foetor. There is usually no fever. The exudate, which can be easily wiped off, may extend to the palate, buccal mucosa, and gingiva. Diagnosis is made on the basis of the clinical picture of a typical infection, usually of one tonsil, with unilateral lymphadenopathy, and on the results of bacterial culture. Fusiform and spirochetal organisms are always both present.

---



*Treatment.* Penicillin is given for 3–6 days. Local treatment with silver nitrate is applied topically with a good prognosis.

**Candida (fungal) tonsillopharyngitis.** This is common after radiotherapy or chemoradiotherapy and for patients who received a prolonged course of antibiotics.

A white superficial punctate exudate forms, which can be wiped off and later becomes confluent. There is usually only slight redness in the surrounding mucosa. Subjective symptoms are few.

### Chronic tonsillitis

The history is likely to reveal recurrent attacks of tonsillitis. There is often little pain in the neck and little or no difficulty in swallowing. There is halitosis and a bad taste in the mouth. The cervical lymph nodes are often enlarged. Chronic tonsillitis often remains more or less symptom-free. The systemic effect may become evident through reduced resistance, fatigue, unexplained high temperature, and loss of appetite.

*Pathogenesis.* A polymicrobial bacterial population is observed in most cases of chronic tonsillitis, with alpha- and beta-haemolytic streptococcal species, *S aureus*, *H influenzae*, and *Bacteroides* species having been identified. Impaired drainage of the tonsillar crypts leads to retention of cell debris, which forms a good culture medium for bacteria. From crypt abscesses of this type, the infection extends via epithelial defects in the reticular epithelium into the tonsillar parenchyma to produce a cryptic parenchymatous tonsillitis. In the long term, the tonsillar parenchyma undergoes fibrosis and atrophy.

*Diagnosis.* The history reveals recurrent acute or subacute attacks of tonsillitis. The tonsils are more or less fixed to their base, and the surface is fissured or scarred. Watery exudate and greyish-yellow material can be pressed out of the opening of the crypts by a tongue depressor. Erythema of the anterior faucial pillar is present. The size of the tonsil is also not a criterion for the presence of chronic tonsillitis; both hyperplastic and small tonsils can be affected. It is not always possible to make the diagnosis of chronic tonsillitis on the basis of the local findings. The history and general findings also need to be assessed critically. The examiner's judgment and experience are often decisive.

The fixed yellow concretions are observed when pressure is exerted on the crypts with a tongue depressor. These do not signify chronic tonsillitis, but are a physiologic phenomenon (tonsillar stones).

### Focal infection (localised infection causing disease elsewhere in the organism)

This is a persistent bacterial infection of some organ or region, especially one causing symptoms elsewhere in the body. A “focus” is any local change in the body that is capable of producing remote pathologic effects beyond its immediate surroundings. Several diseases are considered to be associated with the focal infection (Table 3.2).

**Table 3.2** Diseases associated with focal infection

Endocarditis, myocarditis, and pericarditis
Glomerulonephritis and focal nephritis
Chronic urticaria
Inflammatory disorders of the nerves and eyes (iritocyclitis)
Polyserositis
Psoriasis
Rheumatic fever
Vascular diseases (recurrent thromboangiitis, nodular vasculitis)

*Treatment.* Chronic tonsillitis requires treatment — tonsillectomy (see Chapter 10.1) — whenever it fulfills the criteria for a local pathologic process outlined above. Tonsillectomy is usually performed in childhood or young adult age. Partial tonsillectomy (tonsillotomy) can be indicated in hypertrophic tonsils (Figure 3.16). Conservative measures such as gargling, painting, and suctioning of the tonsillar crypts are of no benefit.

### Are the tonsils necessary organs? Is it not bad for the body if they are removed?

The tonsils should be removed only if they are a source of irreversible disease, if they are acting as a focus of infection, or if they are causing obstruction. In these cases, it is the tonsils' pathologic characteristics that predominate, and their original protective function has been reduced or lost. Removing irreversibly diseased or hypertrophic tonsils, and

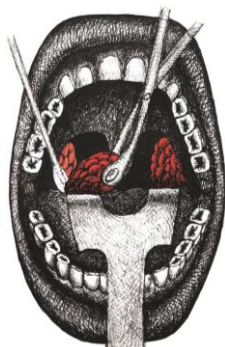those suspected of harbouring a focus of infection, is a prerequisite for good health.

**Is there a tendency to suffer from upper respiratory infections more often after tonsillectomy?**

Susceptibility to pharyngitis is not reduced by tonsillectomy itself, but it may be reduced if the tonsillectomy restores the airway to normal (e.g. in tonsillar hypertrophy) and if the flora in the mouth and pharynx are restored to normal (e.g. in chronic tonsillitis). Simple pharyngitis can therefore occur just as often after tonsillectomy as before. Classic tonsillitis can no longer occur.

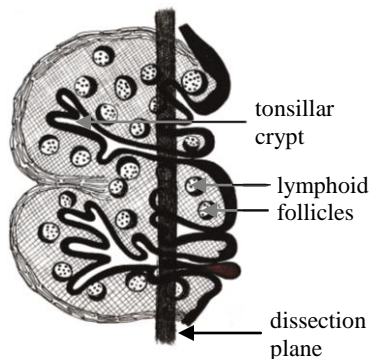
**Does tonsillectomy have any negative effects on the voice and speech?**

If it is performed with a meticulous technique, tonsillectomy usually does not have any negative effects on the voice or speech. Considerable caution is needed before recommending the operation in a patient with a cleft palate. The resonating space may be temporarily changed, which needs to be considered in singers and other voice professionals.



**Figure 3.16a**

Tonsillectomy; right tonsil partially removed



**Figure 3.16b**

Tonsillotomy

**Chronic pharyngitis**

*Definition.* This is a comprehensive term for several chronic irritative or inflammatory conditions of the pharyngeal mucosa.

*Classification.*

**Simple.** This causes a globus sensation, constant throat clearing, bouts of coughing, a feeling of dryness or phlegm in the throat, pain of varying degrees in the neck and on swallowing, and tenacious secretions. The course is intermittent, and there is no generalised upset and no fever.

**Chronic hyperplastic.** The mucosa of the posterior pharyngeal wall is thickened and granular, with prominent solitary follicles. It is smooth red to greyish-red in colour, possibly with venous telangiectasis and secretion of stringy, colourless mucus. There is usually a very disturbing, strange sensation in the pharynx with compulsive throat clearing and swallowing, gagging, and even vomiting

**Chronic atrophic.** The posterior pharyngeal wall is dry and glazed, often with dry, tough crusts of secretion. The mucosa is smooth, pink, often very tender and transparent, but may also be red and thickened. At night, there is a feeling of choking and disturbance of sleep. Older people are more often affected.

*Pathogenesis.* The disease may be due to chronic exogenous damage from dust, chemicals, and heat. Common contributing factors are marked temperature changes, voice abuse, working in a smoky environment, working in a dry or improperly air-conditioned atmosphere, heavy smoking and drinking, oral breathing, chronic nasal airway obstruction, abuse of nose drops and sprays, chronic sinusitis, and hypertrophic adenoids. Other causes include endocrine disorders (e.g. menopause, hypothyroidism) or avitaminosis A.

*Diagnosis.* The local findings are typical. The disease lasts for years, with an intermittent course. There is often a discrepancy between the unremarkable local findings and the marked symptoms.

*Differential diagnosis.* This includes Sjögren syndrome, Plummer–Vinson (Paterson–Brown–Kelly) syndrome, and malignancy of any part of the pharynx or oesophagus.

*Treatment.* The examiner should search for the local or distant causes listed above and should eliminate them. Symptomatic treatment includes moisturising the pharyngeal mucosa with steam inhalations. A change of climate is advised. Patients may even have to change their job or place of residence.

### **Pharyngeal bursitis (Thornwaldt disease)**

*Definition and clinical features.* Presents as foul-smelling drainage from the nasopharynx, particularly in the mornings. A central groove of the adenoid or formation of a pouch in the roof of the pharynx or on the posterior wall of the nasopharynx is present. It retains a yellowish-brown secretion and debris, with or without accompanying inflammation.

*Diagnosis* is made by careful endoscopic examination of the entire nasopharynx.

*Differential diagnosis.* Sinusitis, especially sphenoid or ethmoidal, or early neoplasm in the nasopharynx must be considered.

*Treatment.* Surgical obliteration of the cyst is carried out.

### **Plummer–Vinson syndrome (Paterson–Brown–Kelly syndrome)**

*Definition.* This is a rare condition characterised by difficulty in swallowing, iron deficiency anaemia, and oesophageal webs.

*Clinical features.* The mucosa of the tongue and of the pharynx is atrophic; the skin is dry, pale, and flaccid; the mucous membranes are dry; and the patient also complains of burning of the tongue. This disease occurs almost exclusively in women from 40 to 70 years of age and may occasionally cause painful dysphagia.

*Aetiology.* The basic cause is iron deficiency. Promoting factors include achlorhydria and avitaminosis, and chronic atrophic mucosal inflammation with sub-epithelial fibrosis. There is a risk of postcricoid carcinoma in 10–30% of cases.

*Diagnosis.* The dysphagia is due to oesophageal stricture. The fingernails are curved, and rhagades at the corners of the mouth are present, as well as weight loss, hypochromic anaemia,

extremely low values for serum iron, anisocytosis and microcytosis, spasm of the oesophageal opening with a notch at the level of the cricoid, and possibly also a web within the oesophageal lumen.

*Treatment.* Therapy consists of iron and vitamin B, a bland diet, and possibly dilation of the oesophageal stenosis.

## **3.4.4 Complications of infectious diseases**

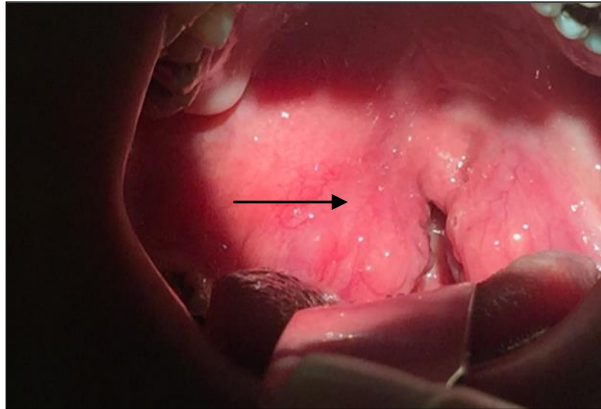
### **Peritonsillar abscess**

*Definition and clinical features.* This is usually a complication of acute tonsillitis caused by accumulation of purulent exudate (pus) in the peritonsillar space. The pain usually radiates to the ear, and opening of the mouth is difficult due to trismus. The speech is thick and indistinct. The pain is so severe that the patient often refuses to eat, the head is held over to the diseased side, and rapid head movements are avoided. The patient has sialorrhoea and oral foetor, swelling of the regional lymph nodes, increased fever with high temperatures of 39–40°C, and the general condition deteriorates rapidly. Patients also have an intolerable feeling of pressure in the neck, obstruction of the laryngeal inlet, and increasing respiratory obstruction. However, the symptoms may sometimes only be mild.

*Pathogenesis.* Inflammation spreads from the tonsillar parenchyma to the surrounding tissue; an abscess forms between the capsule of the tonsil and the tonsillar fossa (inferior constrictor muscle) within a few days. The pharyngeal constrictor muscle is usually an effective barrier against further spread.

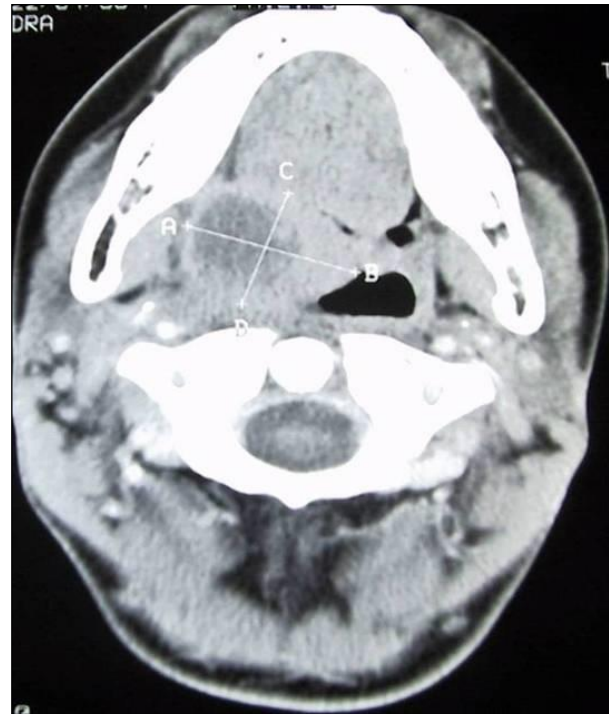*Diagnosis.* This is made on the basis of the clinical picture of swelling, redness, and protrusion of the tonsil, faucial arch, palate, and uvula (Figure 3.17). The uvula is pushed towards the healthy side, and there is marked tenderness of the tonsillar area. Inspection of the pharynx may be difficult due to severe trismus. The blood count, CRP and ESR are typical of an acute infection.

*Differential diagnosis* includes peritonsillar cellulitis, tonsillogenic sepsis, allergic swelling of the pharynx without fever (angioneurotic oedema), malignant diphtheria, agranulocytosis, specific tonsillar infections (tuberculosis and syphilis), and nonulcerating tumours of the tonsil or neighbouring tissues (malignant lymphoma, lymphoepithelial tumour, anaplastic carcinoma, or leukaemia).



**Figure 3.17a**

Peritonsillar abscess right side; please note bulging of paratonsillar space, right side



**Figure 3.17b**

Peritonsillar abscess right side; CT scan, axial plane

**Table 3.2** Surgical treatment options of peritonsillar abscess management

Procedure	Anaesthesia	Timing	Description of the procedure
“Hot” tonsillectomy	General	At time of diagnosis	Prevents further recurrence; the patient only has to undergo one course of treatment.
“Warm” tonsillectomy	General	3–4 days after diagnosis	As hot tonsillectomy; surgery is done after previous drainage on stabilised patient with days of delay
“Cold” tonsillectomy	General or local	Elective procedure	Elective tonsillectomy after initial treatment with aspiration/incision
Incision and drainage with dilatations	Topical and local	At time of diagnosis	Evacuates pus immediately; patient needs to attend for dilatations for several days after incision. Does not prevent recurrence; elective tonsillectomy is advised.
Aspiration	Topical	At time of diagnosis	Aspiration removed the pus and allows healing. Does not prevent recurrence.

The differential diagnosis also includes dental infections such as peritonsillar abscess due to impacted wisdom teeth and aneurysms of the internal carotid artery (pulsation). An absence of acute local signs of infection and of fever, and a prolonged course, suggests that a diagnosis of peritonsillar abscess is wrong.

*Treatment.* High doses of antibiotics, analgesics and diet modification. Surgical evacuation of purulent exudate (see Table 3.2 and Chapter 10.2).

*Prognosis.* Regression of the inflammation and prevention of an abscess are possible with timely administration of antibiotics. An abscess may also

drain spontaneously and heal. However, distressing pain and difficulty in eating usually make active drainage necessary. If tonsillectomy is not performed, there is a high risk of recurrent abscess in the paratonsillar scar tissue.

*Complications and risks* include extension of the inflammatory swelling and oedema to the laryngeal inlet, with increasing respiratory obstruction and a possible risk of asphyxia. The abscess may also rupture into the parapharyngeal space and cause parapharyngeal/mediastinal abscess and thrombosis of the internal jugular vein.

### **Septicaemia during or after tonsillitis (tonsillogenic sepsis)**

It starts with mild tonsillar infection and ends with life-threatening thrombophlebitis of the internal jugular vein. This severe complication can lead to additional problems including potential septic embolisation and metastatic abscesses in the lungs, liver or brain or septic arthritis osteomyelitis.

Tonsillogenic sepsis is a life-threatening disease, but the prognosis is good if treatment with antibiotics and surgery are instituted promptly.

*Clinical features.* Tonsillogenic sepsis presents as chills with a septic temperature chart, strong pain in the neck, tenderness along the internal jugular vein, which appears as a tender, firm cord under the anterior edge of the sternocleidomastoid muscle, or tenderness of the jugulodigastric lymph nodes. There is often simultaneous reddening of the tonsillar area, but this is not essential. The patient has a severe constitutional upset, a left shift in the blood count with leukocytosis, splenomegaly, possible spread to the lung, skin or liver, a dry tongue, and a weak rapid pulse.

*Pathogenesis.* Bacteria enter the bloodstream from the tonsil, or from a neighbouring focus of pus. Haematogenous, lymphogenous or direct spread of the abscess is possible.

*Diagnosis.* This is based on the picture of chills and symptoms of septicaemia due to continuous or intermittent bacteraemia. There is a history of tonsillitis and symptoms of chronic tonsillitis, the

ESR increases rapidly, and there is rapidly rising leukocytosis. A defensive spasm of the cervical soft tissues occurs, with a relieving posture in the head and neck.

*Treatment.* If severe sepsis is suspected, high-dose penicillin or broad-spectrum antibiotics are started immediately to protect the body from infective metastases. Ligature of the internal jugular vein inferior to the thrombus and resection of the diseased segment, if the internal jugular vein is involved and tonsillectomy to eliminate the focus, need to be done. Abscess of the cervical soft tissues needs to be wide open and drained.

### **Retropharyngeal abscess in children**

*Aetiology.* An abscess can form due to breakdown of lymphadenitis of the retropharyngeal lymph nodes following pharyngeal infection in children, especially during the first 2 years of life.

*Clinical features* are swelling of the posterior pharyngeal wall, difficulty in swallowing, thick speech, difficulty in eating, elevated temperature, a relieving posture of the neck (differential diagnosis: torticollis), leakage of food through the nose, possibly nasal obstruction, croup, and laryngeal oedema.

*Differential diagnosis.* Benign and malignant prevertebral tumours must be considered.

*Treatment.* This is by paramedian incision and drainage under general anaesthesia, with the head hanging to prevent aspiration of pus. The airway must be protected from aspiration by an endotracheal tube, and antibiotic cover is given.

Magnetic resonance images should be obtained whenever a retropharyngeal abscess is suspected, due to the risk of extension to the mediastinum between the superficial and deep neck fascia.

### **Retropharyngeal abscess in adults**

*Aetiology.* On many occasions it starts as a descending prevertebral cold abscess originating from tuberculous caries of a cervical vertebra, or suppuration in osteomyelitis of the temporal bone (e.g. petrositis) and in mastoiditis.



**Clinical features and diagnosis.** Symptoms include pressure in the neck, attacks of coughing, difficulty in swallowing, mild dysphagia, stiffness of the neck, and typical lesions of the cervical spine on radiographs. Imaging provides a diagnosis of an abscess and defines its extent.

**Differential diagnosis.** Benign and malignant tumours and spondylosis of the cervical spine.

**Treatment.** A test aspiration is made. If it is an abscess related to bacterial inflammation it is incised and drained and a specimen is sent for culture. Antituberculous treatment is given, and the patient is referred to a spinal surgeon.

### 3.4.5 Other non- neoplastic conditions

#### Foreign bodies

Foreign bodies of the upper aerodigestive tract often present as medical emergencies, particularly in view of the possibility of a compromised airway. Foreign bodies of the oral cavity and pharynx are less common than in the oesophagus. Small pointed foreign bodies such as fish bones, bits of wood, and bristles from a toothbrush can become impacted in the tonsil, base of the tongue, vallecula or lateral wall of the pharynx. Larger foreign bodies such as toys and food often impact on the piriform sinus. The most common *symptom* is pain and dysphagia.

**Diagnosis** is based on history, clinical examination, endoscopy and, in the case of a radiopaque foreign body, radiography.

**Treatment.** The instrumental removal of the foreign body. Serious complications (retropharyngeal abscess) can result from persistent foreign bodies.

#### Pharyngeal pouch

A diverticulum is a sac or pouch arising from lower hypopharynx. True diverticula contain all layers of the wall of the intestinal tract. False diverticula (pseudodiverticula) occur when herniation of mucosa and submucosa through a defect in the muscular wall occurs (Zenkers diverticulum).

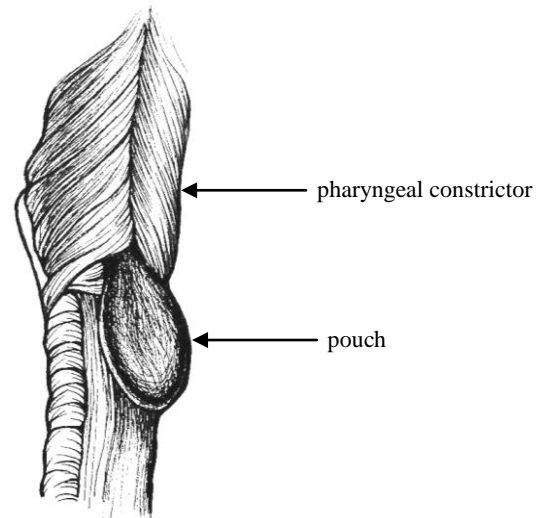
**Epidemiology.** Most oesophageal diverticula occur in middle-aged adults and elderly people. Presentation in infants and children is rare.

**Zenkers diverticulum** is an acquired pulsion-type diverticulum. It arises from the posterior hypopharynx at a point where a defect between the inferior pharyngeal constrictor muscle and the cricopharyngeus muscle (Killian triangle or dehiscence) usually exists. Zenkers diverticula actually arise from the hypopharynx rather than from the oesophagus.

**Traction diverticula** occur as a consequence of traction forces on the outside of the oesophagus from an adjacent inflammatory process.

**Symptoms.** Oropharyngeal dysphagia, usually to solids and to liquids, is the most common symptom. Retention of food material and secretions in the diverticulum, particularly when diverticula are large, can result in regurgitation of undigested food, halitosis, cough, and even aspiration pneumonia. With very large diverticula, a mass in the neck occasionally can be detected. Patients may lose significant weight.

**Diagnostics.** Barium swallow is the best investigation if a pouch is suspected. Endoscopy may be necessary to exclude malignancy. (Figure 3.18)



**Figure 3.18**

Zenker's diverticulum – pharyngeal pouch

**Treatment.** Asymptomatic and minimally symptomatic oesophageal body diverticula may not require treatment. Treatment of a Zenkers diverticulum is transoral diverticulotomy by either

endoscopic stapling, CO<sub>2</sub> laser or transcervical surgical resection or inversion. Cricopharyngeal myotomy is the most important element of the treatment; if it is not performed, the pouch will recur. Endoscopic stapling is an operation of choice and has few complications as need for NG tube, mild bleeding or perforation of pharynx.

### **Elongated styloid process (Eagle syndrome)**

*Definition and aetiology.* This is a mechanical irritation of the nerves and vessels close to the styloid process when it is excessively long (the normal length is approx. 3 cm).

*Clinical features.* Presents as dysphagia or neuralgia, usually on one side, and is most severe in the tonsillar region or behind the angle of the jaw. Pain may radiate to the ear or the temporal region. Pain may occur on swallowing, or on certain movements of the cervical spine. The symptoms can be reproduced by palpating the tonsillar cleft.

*Diagnosis.* Palpation of the tonsillar cleft, which produces the typical symptoms at this point, and by radiography. Neuralgias of cranial nerves IX and X and spondylosis of the cervical spine need to be considered in the differential diagnosis.

*Treatment.* Trans oral removal of the styloid process via a tonsillectomy or a cervical approach.

### **Glossopharyngeal neuralgia**

*Clinical features.* There is a sudden tearing pain on one side of the tongue or the neck, radiating to the ear, accompanied by discharge of tenacious saliva. This is usually a disease of the older age groups. Pain is induced by swallowing food, chewing, and also by speaking and yawning. As a result, the patient eats extremely carefully and often with the head in a typical position.

*Diagnosis* is made by inducing local anaesthesia of the trigger zones, the base of the tongue, and the lower pole of the tonsil, which interrupts the attacks of pain for a brief period.

*Treatment* is conservative — carbamazepine should be tried. Surgical treatment consists of division of cranial nerve IX in the posterior cranial fossa.

### **Pharyngeal globus (functional dysphagia, globus hystericus)**

*Definition.* Globus is a symptom complex that requires investigation even when accompanying pharyngitis. Globus is a frequent complaint in general ENT clinics.

*Clinical features* include an intermittent or continuous feeling of a foreign body being stuck in the throat that cannot be dislodged despite swallowing. Occasionally, there is also pain in the throat or radiating to the ears. Swallowing is not affected and any organic lesions are absent.

*Pathogenesis.* An incorrect psychosomatic response to stress and possibly a tendency of spasm of the muscles of the oesophageal inlet.

*Diagnosis.* Typical tenderness in the midline at the level of the cricoid arch. Clinical examination, radiography and oesophagoscopy are all normal.

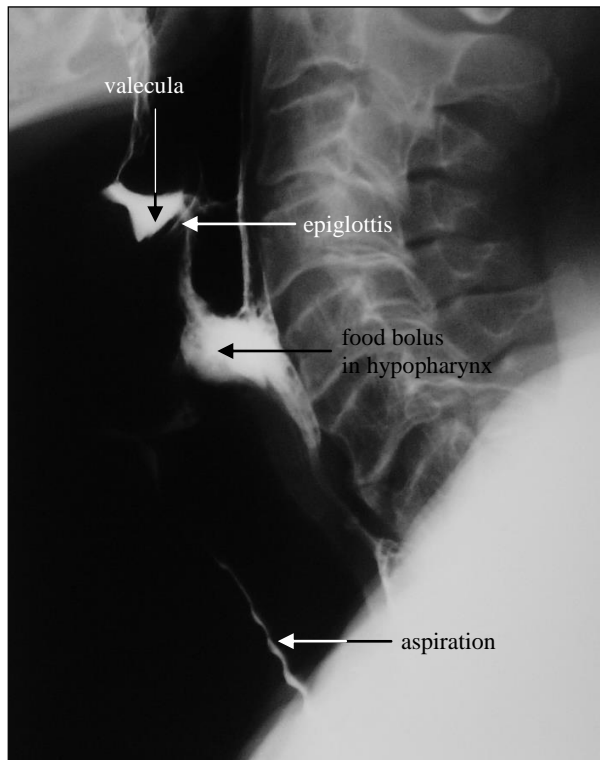
*Treatment.* The patient often has a cancer phobia, and this needs to be dealt with by counselling and reassuring. A „therapeutic“ CT scan of the head and neck may be helpful reassuring the patient. Sedatives are given, and the patient is removed from the stressful situation. If organic causes are found, they are eliminated (if possible); otherwise, the suspected cause is explained to the patient.

### **Motor paralyses of the pharynx**

*Aetiology.* Causes include cerebrovascular accidents, tumours of the base of the skull, jugular foramen syndrome (affecting cranial nerves IX to XI), pseudobulbar palsy, syringobulbia, and herpes zoster.

*Clinical features.* Absence of the pharyngeal reflexes, choking, rhinolalia aperta due to palatal paralysis, difficulty in swallowing fluids, and an escape of fluids through the nose during swallowing are present. It is impossible to suck or to blow out the cheeks. The soft palate deviates to the healthy, nonparalysed side.

*Treatment.* Nutrition has to be secured with a nasogastric tube or gastrostomy. Pneumonia must be prevented and safe swallow needs to be established. If it is not possible, the patient should not be on an oral diet to avoid aspiration into the lower respiratory tract (Figure 3.19). Prognosis depends on the underlying disease and the course.



**Figure 3.19**  
Aspiration on videofluoroscopic examination

### 3.4.6 Swallowing disorders

*Diagnosis.* Dysphagia is the term used for the symptom of difficulty in swallowing.

*Aetiology.* As swallowing is a complex process, there are many reasons why dysphagia can develop. Neurological causes such as stroke or myasthenia gravis, cancers of the head and neck and their treatment, congenital and developmental conditions, muscular conditions such as scleroderma, and many more.

*Clinical features.* Each person is different, but some of the common symptoms of this disorder are as follows: coughing, wet or gurgly-sounding voice during or right after eating or drinking, extra effort or time needed to chew or swallow food or liquid leaking from the mouth or getting stuck in the mouth, recurring pneumonia or chest congestion after eating, weight loss or dehydration from not being able to eat enough.

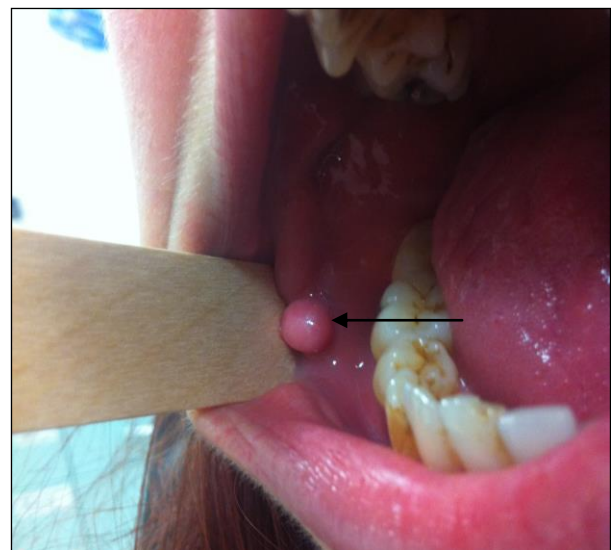
*Diagnostics.* Screening of swallowing disorders can be in place in populations of patients with a high risk of aspiration. Specialised examinations of swallowing are videofluoroscopy (VFSS) and the flexible endoscopic evaluation of swallowing (FEES) (see also Chapter 3.3).

*Treatment options* are aimed at the underlying cause of dysphagia (swallowing therapy, dietary changes, medications, botulinum toxin injections, surgical procedures, and others).

### 3.4.7 Tumours of the oral cavity and pharynx

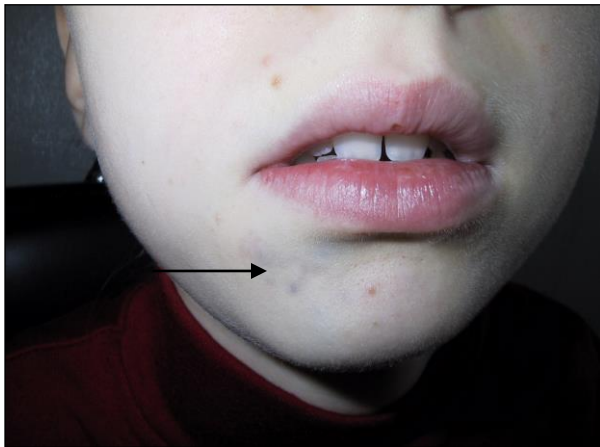#### BENIGN TUMOURS

Various types of benign tumours such as *fibromas* (Figure 3.20), *lipomas*, *myxomas*, *chondromas*, *haemangiomas*, *lymphangiomas*, *neurinomas*, and others rarely occur in this region. The more common benign epithelial tumours include *papilloma*, *keratoacanthoma* and *pleomorphic adenoma*. Surgical treatment is advisable based on the results of histology, size and other characteristics of the tumour. Biopsy is not necessary for haemangiomas and lymphangiomas.



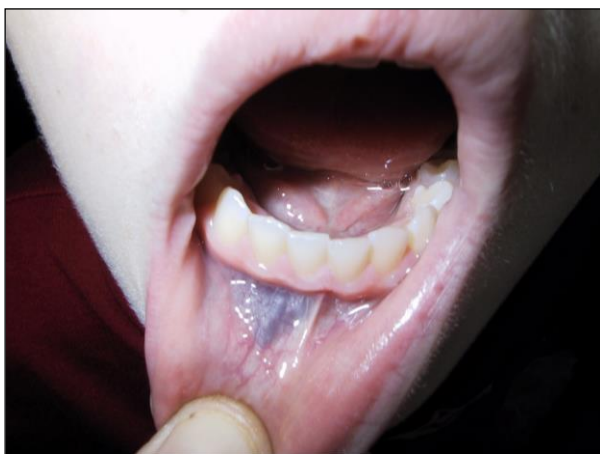**Figure 3.20**  
Oral fibroma

*Haemangiomas and lymphangiomas* are usually congenital, and 90% of them affect girls (Figure 3.21). The sites of predilection are the tongue, cheek, and parotid regions. The tumour may be life-threatening due to its size, recurrent bleeding, airway obstruction, or severe dysphagia. It often resolves spontaneously within the first 2 years of life, and surgical removal should therefore be delayed (if possible) until a later age. If surgery is required complete excision is best chance to cure. Embolotherapy and cryosurgery are options.



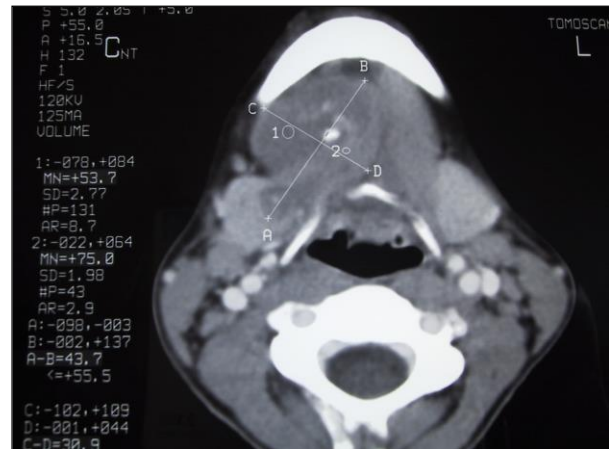
**Figure 3.21a**

Lower lip and floor of mouth haemangioma – skin



**Figure 3.21b**

Lower lip and floor of mouth haemangioma  
– intraoral portion



**Figure 3.21c**

Lower lip and floor of mouth haemangioma; CT scan,  
axial plane

Some *tumours of neighbouring organs* may invade the mouth and oropharynx or displace the pharyngeal walls. The most frequent are tumours of the parotid gland, or vascular tumours of the neck.

### Juvenile angiofibroma

*Definition and epidemiology.* Juvenile angiofibroma occurs exclusively in young males, beginning about the age of 10 years. It tends to resolve spontaneously after the age of 20–25 years.

*Clinical features.* The tumour presents with increasing nasal obstruction, purulent rhinosinusitis due to obstruction of the nasopharynx, severe epistaxis, rhinolalia clausa, headaches, obstruction of the ostium of the Eustachian tube (causing conductive deafness), middle ear catarrh, and purulent otitis media. Rhinoscopy shows occlusion of the nasopharynx by a smooth, greyish-red tumour with visible surface vessels. In later stages, there may be deformity of the face and nasal skeleton, neurological symptoms, protrusion of the cheek, and possibly exophthalmos. The tumour is firm to palpation.

*Pathogenesis.* The typical nasopharyngeal angiofibroma is histologically benign, and clinically shows expansive and invasive growth. After filling the nasopharynx, the tumour grows into the nasal sinuses, upper jaw, sphenoid sinus,



pterygopalatine fossa, cheek, ethmoid sinuses, and orbit. Finally, it may extend into the cranial cavity after eroding the base of the skull.

*Diagnosis.* This is made by endoscopy and CT or MRI. Angiography of the carotid artery is indicated for an extensive tumour. Superselective angiography of the branches of the carotid is performed to allow therapeutic embolisation. The differential diagnosis should include hypertrophied adenoids, choanal polyp (which is soft and does not bleed), lymphoma, chordoma, and teratoma.

A biopsy should be avoided or performed with extreme care if there is a suspicion of angiofibroma. The risk of massive bleeding is significant. A nasopharyngeal tumour in an individual between the ages of 10 and 25 years for which there is a suspicion that it may be a juvenile angiofibroma should only be submitted to biopsy in a hospital, and preparation should be made to proceed immediately to further surgery if massive bleeding occurs. However, angiography provides a characteristic diagnostic picture which substitutes for a biopsy.

*Treatment.* The ideal method of treatment is surgery. Different approaches are available: midfacial degloving, transmaxillary access, or transpalatal access. Extensive tumours may need a craniotomy and mandibular osteotomy. For smaller tumours, the endoscopic endonasal techniques are useful. Preoperative embolisation of the feeding vessels is helpful in preventing or reducing of bleeding. Embolisation should ideally be done within 48 hours of surgery. Radiotherapy is an effective means of treatment, with a success rate of up to 80%.

## MALIGNANT TUMOURS

### Nasopharyngeal cancer

*Definition.* Nasopharyngeal carcinoma (NPC) is a type of head and neck cancer arising from the epithelium of the nasopharynx. Almost all adult nasopharyngeal cancers are carcinomas. In children, up to half are carcinomas, and

other tumours include rhabdomyosarcomas or lymphomas.

*Epidemiology.* NPC is a prevalent malignancy in Southeast Asia. A male preponderance is observed, and the peak is in late adolescence and at the age of 50–60.

*Aetiology.* It is thought to be the result of both genetic susceptibility and environmental factors such as carcinogens and infection with Epstein–Barr virus. Possible environmental or cultural factors include the ingestion of salted fish and preserved foods, especially during childhood.

*Clinical features and diagnosis.* Early symptoms include nasal obstruction, blood-tinged sputum or nasal discharge, tinnitus, headache, a feeling of fullness in the ear, and unilateral conductive hearing loss from otitis media with effusion or recurrent acute otitis media. In advanced cases, the tumour can invade the skull base and spread intracranially through one of the many nearby foramina. Evidence of involvement of Cranial Nerve (III–VI), including diplopia, suggests invasion of the cavernous sinus.

History, physical examination, endoscopy and biopsy of the tumour will help to establish the diagnosis. Imaging studies may include a CT, MRI or PET scan.

A unilateral flat pattern on the tympanogram (type B) should always lead to direct inspection of the nasopharynx.

*Treatment.* Radiotherapy is the primary mode of management both at the primary site and in the neck. This is mainly because of the high degree of sensitivity of this tumour to radiation as well as the anatomical constraints of surgical access which make obtaining clear surgical margin difficult. The addition of the chemotherapy has markedly increased the cure rate. Surgical treatment is reserved only for treatment of NPC with limited disease and in patients with recurrent cancer.

### Squamous cell carcinoma

Any single lesion persisting for more than 3 weeks should be regarded with suspicion. Approximately



90–95% of oral and oropharyngeal cancers are *squamous cell carcinomas* (SCC). Rarely, *anaplastic carcinomas*, *adenoid cystic carcinomas*, *adenocarcinomas*, *sarcomas*, *malignant lymphomas*, *plasmacytomas*, and *malignant melanomas* are observed. The prognosis varies widely even among carcinomas, depending on the site, extent, and histologic differentiation of the lesions. The TNM classification is used for documentation, choice of treatment, and prognosis (see Appendix).

Any non-healing ulcer and any hyperkeratotic area in the mouth should be suspected of being an early malignancy and requires a biopsy for diagnosis. If the clinical suspicion of malignancy persists, a negative biopsy should not be accepted, as the material may have been sampled from tumour-free tissue. Biopsy should therefore be repeated until a satisfactory histologic explanation is found for the clinical appearance.

**Staging.** The purpose of staging is to ascertain the precise extent of the tumour spread for topographic diagnosis and to search for regional and distant metastases. For all tumours located in the head and neck region, the presence of regional metastases to the lymph nodes of the neck worsens the prognosis exponentially. Distant metastases occur in up to 20% of cases, most commonly in the lungs, liver, and bones.

**Diagnostic imaging.** CT and MRI make it possible to visualise the deep anatomic structures of the oropharynx and surrounding tissues (e.g. retropharyngeal lymph nodes, deep muscles of the tongue, prevertebral and paravertebral areas, and base of the skull). Ultrasonography can guide fine needle aspiration for cytologic assessment of suspiciously appearing lymph nodes, the base of the tongue, or the floor of the mouth.

Searching for distant metastases requires at least a chest radiograph in two planes and ultrasound imaging of the upper abdomen. CT or MRI imaging of the neck and chest should be carried out if possible. Radioisotope bone scans make it possible to identify skeletal metastases. Positron

emission tomography is the method of detecting unidentified primary tumours in patients with the syndrome of carcinoma with an unknown primary; it is also used in the evaluation of chemoradiation treatment.

**Treatment** is determined by the site and stage of the tumour. The principal goal is radical extirpation of the tumour. The most important points to consider in surgery for malignant tumours are radicality, functionality, and aesthetic appearance. Neck dissection is the essential surgical procedure to consider in the treatment of all metastatic tumours to the cervical lymph nodes.

### **Carcinoma of the lip**

**Epidemiology.** Up to 95% of cancers of the lower lip are well-differentiated squamous carcinoma. The lower lip is affected more frequently. Basal cell carcinoma is more common on the upper lip than squamous cell carcinomas. This cancer is most common in Caucasian men- the average age is 60–65 years.

**Aetiology.** Exposure to ultraviolet radiation is an important aetiological factor. Other factors are poor oral hygiene, smoking of cigarettes or pipes, and excessive alcohol consumption.

**Clinical features.** At the beginning there is usually no pain but with an increasing size of the cancer, the patient reports pain and induration and there is infiltration of the underlying tissues and cervical lymphadenopathy.

**Treatment.** Surgery is better than radiotherapy, with a 5-year survival rate of ≈85% compared with ≈80% for radiation. The principle of the operation is wedge excision and primary closure. Neck dissection of levels I, II, and III may also be necessary, depending on the stage of the cancer.

### **Carcinomas of the oral cavity and body of the tongue (oral tongue)**

**Epidemiology.** The male-to-female ratio is 70:30, but it depends on the site and race. The average age is 50–60 years.

**Aetiology.** There is a statistically significant history of smoking and alcohol abuse. Further suspected aetiological factors include poor dental care and poor oral hygiene.

Cancers of the oral cavity and the anterior two thirds of the tongue metastasise to the submandibular, superior subgastric, and middle deep jugular lymph nodes. The frequency of lymphatic metastasis increases with the stage of the cancer from 10–15% in T1 cancer to 55–75% in T4 lesions. Cancers of the gingiva and those in the mucosa of the cheek have an even higher rate of regional lymph node metastasis. Bilateral lymph node metastases can also occur can also occur if a cancer of the floor of mouth is in the midline or crosses the midline.

*Clinical features.* The symptoms of cancer in the oral cavity affecting the floor of the mouth or the tongue are initially minimal, so the diagnosis is often delayed. Later symptoms include an ulcer with raised edges, bleeding, and increasing pain radiating to the ear and neck, interference with speaking and swallowing, oral foetor, and sialorrhoea. Late symptoms include involvement of the regional lymph nodes and, finally, loss of weight, due to increasing difficulty in eating. Often, the first symptom that patients notice is their lower denture not fitting properly.

*Diagnosis.* The possibility of a cancer must always be borne in mind in any patient with a palpable tissue induration in the oral cavity or on the tongue, or with a mucosal ulcer that does not heal rapidly. A biopsy should always be taken. If the diagnosis remains uncertain, radiography and direct endoscopy should be undertaken.

*Treatment.* In the early stage (T1), surgery and radiotherapy are equally effective. Surgery is preferable for larger cancers (T2 and T3) or when lymph node metastases are present. Various routes of surgical access can be used, depending on the site of the cancer. The cancer must be excised with wide margins in three dimensions. Several techniques are available for cancer of the tongue, depending on its extent, including partial or subtotal glossectomy with partial mandibu-lectomy. Temporary median division of the lower lip and a midline mandibulotomy is often necessary to provide satisfactory exposure. The soft-tissue defect resulting from excision can be left to secondary healing or closed with regional pedicled flaps or free tissue transfer with microvascular anastomosis. Patients often require postoperative care for the many associated problems, such as

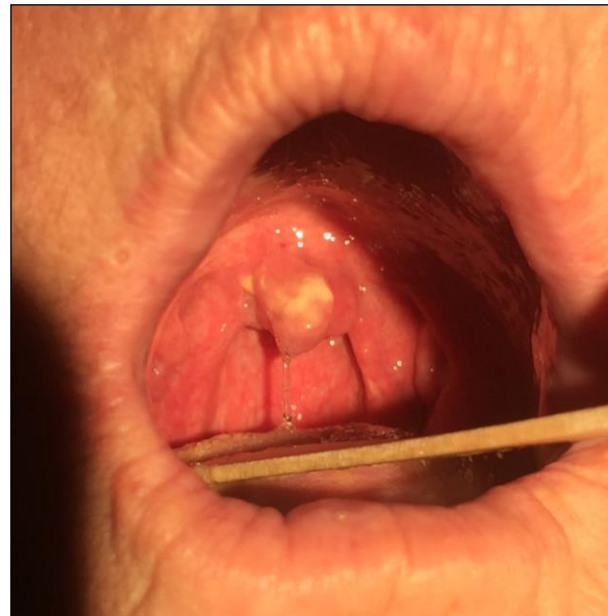difficulty with speech, mastication, swallowing, and nutrition. The prognosis is unfavourable in patients with stage T3 or bone invasion, where a combination of surgery and radiochemotherapy produce the best results.

### **Carcinoma of the uvula, tonsil or base of the tongue**

*Epidemiology.* These are relatively frequent cancers, with a male-to-female ratio of 4:1. The age of predilection is 50–70 years.

*Aetiology.* The history also often shows combined alcohol abuse and smoking.

More recently there has been an increased incidence of HPV infection-related oropharyngeal cancer in younger patients: non-smokers and mild/moderate alcohol drinkers. Sixty per cent of patients have cervical lymph node metastases, of which 15% are bilateral.



**Figure 3.22**  
SCC of the uvula

*Clinical features.* Cancers of the oropharynx cause symptoms earlier than oral cancers. Symptoms include increasingly severe pain on swallowing, which is often initially unilateral, thick indistinct speech, an ulcer or an increasing size of the tonsil

(Figure 3.22). Palpation shows induration of the affected structures. There is oral foetor, bleeding, or blood-stained sputum. The tongue is fixed, and the patient has trismus, loses weight, and often has a typical pallor.

Palpation of the cancer is necessary to evaluate for depth of invasion, in addition to direct/mirror examination.

*Treatment.* The method of choice was traditionally surgery combined with radiotherapy or chemoradiotherapy alone. Surgery could be performed either before or immediately after radiotherapy. Neck dissection may also be performed.

Currently most of the oropharyngeal cancers (especially the ones showing HPV positivity) are treated primarily by chemoradiation

---

#### **Multidisciplinary management of oropharyngeal cancer**

The principles of management will vary according to the size

of the cancer, histological features, and also the individual unit that is administering the treatment. The treatment for each individual patient is discussed at a multidisciplinary team meeting in the presence of the surgeons, medical and radiation oncologists, radiologist, pathologist and others involved in the care of the patient. Necessary imaging, histology or fine needle aspiration of any palpable lymph node is discussed and the treatment plan is agreed upon.

*Small tonsil cancers* (T1, T2) are treated with local wide excision, CO<sub>2</sub> laser excision, or robotic excision, possibly followed by radiotherapy.

*For a medium-sized cancer of the tonsil*, good results with minimal functional problems follow extended local excision/laser excision with partial excision of the tongue base after controlling the lingual artery during a neck dissection.

*Patients with advanced cancer* (T3, T4) are offered chemoradiotherapy. Primary or salvage surgery might be indicated rarely. The metastases to the neck are treated with selective neck dissection, followed in some cases by radiotherapy. Follow-up with PET CT can replace the neck dissection in some cases. Simultaneous chemoradiotherapy improves the prognosis over radiotherapy alone for inoperable patients.

---



## 4 OESOPHAGUS

### 4.1 APPLIED ANATOMY

The oesophagus is a long muscular tube that connects the pharynx to the stomach. At birth, the length of the oesophagus varies from 8 to 10 cm and measures about 19 cm by the age of 15 years. In adulthood, its length is approximately 26 cm.

Extending from the lower border of the cricoid cartilage (at the level of the sixth cervical vertebra) to the cardia at the side of the body of the 11th thoracic vertebra, the oesophagus passes through the diaphragm at the level of the 10th thoracic vertebra, accompanied by the right and left vagus nerves.

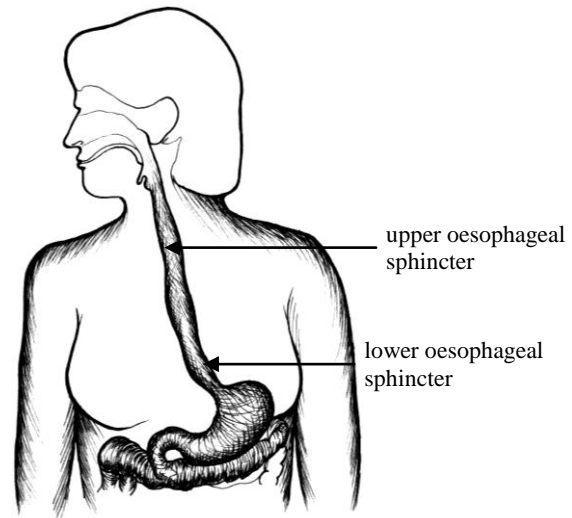
In its vertical course, the oesophagus has two gentle curves in the coronal plane. The first curve begins a little inferior to the beginning of the oesophagus and inclines to the left as far as the root of the neck, before returning to the midline at the level of the fifth thoracic vertebra. The second curve to the left is formed as the oesophagus flexes to cross the descending thoracic aorta, before perforating the diaphragm. The oesophagus also incorporates anteroposterior curvatures corresponding to the curvatures of the cervical and thoracic segments of the vertebral column.

The oesophagus has **three physiological constrictions** in its vertical course, as follows:

At 15 cm from the upper incisor teeth, where the oesophagus commences at the cricopharyngeal (upper oesophageal) sphincter (UOS); this is the narrowest portion of the oesophagus and corresponds approximately to the sixth cervical vertebra.

At 23 cm from the upper incisor teeth, where it is intersected by the aortic arch and left main bronchus.

At 40 cm from the upper incisor teeth, where it perforates the diaphragm; the lower oesophageal sphincter (LOS) is located at this level (Figure 4.1).



**Figure 4.1**  
Oesophagus

These measurements are clinically important for endoscopy and endoscopic surgeries of the oesophagus. The oesophagus is subdivided into three portions, as follows:

- The *cervical* portion extends from the cricopharyngeus to the suprasternal notch.
- The *thoracic* portion extends from the suprasternal notch to the diaphragm.
- The *abdominal* portion extends from the diaphragm to the cardiac portion of the stomach.

**Arterial blood supply.** The cervical portion is supplied by the inferior thyroid artery, the thoracic portion is supplied by bronchial and oesophageal branches of the thoracic aorta, and the abdominal portion is supplied by ascending branches of the left phrenic and left gastric arteries.

**Venous blood** from the oesophagus drains into a submucosal plexus, from which blood drains to the perioesophageal venous plexus. Oesophageal veins arise from this plexus and drain in a segmental manner, similar to the arterial supply.



The oesophagus includes a longitudinally continuous, submucosal lymphatic system. Vessels from the cervical portion drain into the deep cervical lymph nodes, while vessels from the thoracic part drain to the posterior mediastinal nodes and from the abdominal portion to the left gastric lymph nodes.

Lymphatic drainage of the oesophagus contains little barrier to spread of malignancy; therefore, carcinoma of the oesophagus can disseminate through the length of the oesophagus by accessing the lymphatic system, and may exhibit involvement of lymph nodes several centimetres from the primary lesion.

**Innervation** is mixed somatic from Cranial Nerves IX, X and autonomic from the sympathetic nervous system.

## 4.2 PHYSIOLOGY

The oesophagus transports food to the stomach by coordinated contractions of its muscular lining in an automatic and subconscious manner. In the third phase of the swallowing act, termed the oesophageal phase (see also Chapter 3), the cricopharyngeus muscle relaxes and the entrance of the oesophagus opens in response to the oncoming peristaltic wave. The cardia opens in response to the oncoming peristaltic wave.

## 4.3 EVALUATION

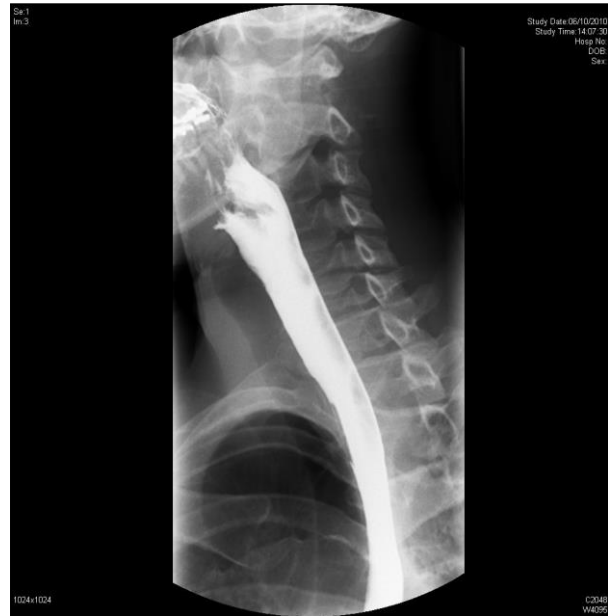### History and clinical examination

Some form of dysphagia is the most common presenting symptom of an oesophageal disorder. Other symptoms associated with oesophageal disorders are heartburn (reflux), regurgitation of food, or epigastric pain. A routine ENT physical examination should be performed with special attention given to the oral cavity, pharynx and

larynx. Pooling of saliva in the pharynx should make the examiner suspicious of oesophageal pathology. Palpation for cervical and supraclavicular lymph nodes should be performed when oesophageal cancer is suspected.

The use of a plain **radiograph** in several projections is limited to diagnostics of a foreign body.

**Oesophagography** Contrast swallow fluoroscopy (oesophagography, barium swallow) is an imaging modality used to examine the upper gastrointestinal tract, including the oesophagus. The patient swallows a contrast medium (barium suspension, water-based contrast) which coats the oesophagus with a thin layer of the contrast (Figure 4.2). Baking soda can also be given to generate gas and distend the oesophagus, thus enabling this hollow structure to be imaged.



**Figure 4.2**

Oesophagogram; lateral view

Barium must not be used if a perforation or foreign body is suspected, if there is a danger of aspiration, or in neonates with suspected oesophageal atresia. In these instances, a water-soluble contrast is substituted.

**Oesophagoscopy** is a procedure which allows visualisation of the oesophageal mucosa from the upper oesophageal sphincter to the oesophago-gastric junction, and can be performed as *rigid*, (see Chapter 10.4) *transoral flexible*, or *transnasal oesophagoscopy*. During the procedure, biopsies can be taken and foreign bodies removed. Transnasal oesophagoscopy, a relatively new method, involves the insertion of a thin, flexible endoscope through the nose and through the pharynx into the oesophagus. Although each method is associated with specific indications, flexible oesophagoscopy is typically performed by gastroenterologists and upper gastrointestinal surgeons, while rigid endoscopy and transnasal oesophagoscopy are usually performed by ENT/head and neck surgeons (rigid endoscopy under general anaesthesia). **pH monitoring** (oesophageal acidity test) measures the acidic content (pH) of the oesophagus over a fixed period of time, usually 24 h. A low pH for long periods may indicate frequent reflux of stomach acid into the oesophagus.

**Oesophageal manometry** evaluates the strength and pattern of muscle contractions in the oesophagus. This test can identify weaknesses in the LES, which allows acid to reflux into the oesophagus, weak muscle contractions, or abnormally strong contractions (spasms) that can cause chest pain or dysphagia.

## 4.4 DISEASES OF THE OESOPHAGUS

### 4.4.1 Congenital disorders

Congenital anomalies of the oesophagus occur in as many as 1 per 3000–5000 births, with oesophageal atresia (OA) and tracheoesophageal fistula (TOF) being the most common types. Other lesions, such as congenital oesophageal stenosis, duplications, and cysts, occur less frequently.

**Oesophageal atresia** is a condition in which the proximal and distal portions of the oesophagus do

not communicate. The upper segment of the oesophagus is a dilated blind-ending pouch with a hypertrophied muscular wall. In contrast, the distal oesophageal portion is an atretic pouch with a small diameter and a thin muscular wall; it usually extends 1–2 cm above the diaphragm.

**Tracheo-oesophageal fistula** is an abnormal communication between the trachea and oesophagus. When associated with OA, the fistula commonly enters the trachea posteriorly just above the carina. However, isolated TOF, or an H-fistula, can occur at any level from the cricoid cartilage to the carina. Several different types of OA and TOF have been described.

Congenital **oesophageal stenosis** is a narrowing of a region of the oesophagus. A **web**, or **diaphragm**, consists of a thin squamous epithelial membrane in the oesophageal lumen. It typically causes a partial obstruction in the middle to lower oesophagus.

**Congenital muscular hypertrophy** is characterised by submucosal proliferation of smooth muscle and fibrous connective tissue beneath a normal squamous epithelium. Individuals with congenital muscular hypertrophy may be asymptomatic.

---

An **oesophageal duplication** may be open at both ends (double oesophagus), open at one end (diverticulum), or closed (elongated cyst). **Oesophageal rests** are areas where embryonic tracheal or oesophageal cells reside in mesodermal tissues. These areas may form cysts in the muscular tissues. A **choristoma** is a distinct cartilaginous cyst that partially or completely encircles a region, typically in the lower third of the oesophagus.

**Columnar epithelium-lined lower oesophagus**. The congenital form of this condition is associated with gastrooesophageal reflux. Whether this lesion, also called Barrett oesophagus, is congenital or acquired is unclear. **Laryngotracheoesophageal cleft** is defined as a midline communication between the larynx, trachea, and oesophagus.

---

### 4.4.2 Inflammatory diseases

Common forms of oesophagitis include reflux oesophagitis, infectious oesophagitis, drug-induced oesophagitis, eosinophilic oesophagitis, and radiation and chemoradiation oesophagitis.

**Oesophageal candidiasis** is the most common type of infectious oesophagitis. Major predisposing factors for oesophageal candidiasis include prolonged use of antibiotics, radiation therapy or chemotherapy, haematologic malignancies, and AIDS. With adequate anti-candidial treatment, e.g. fluconazole, it resolves without any sequelae; however, control of this condition ultimately depends on the underlying disease.

**Drug-induced oesophagitis** is thought to be secondary to chemical irritation of oesophageal mucosa from certain medications (e.g. iron, potassium, quinidine, aspirin, steroids, tetracyclines, NSAIDs), especially when medications are swallowed with too little fluid.

Factors or conditions that may increase the risk of **reflux oesophagitis** include pregnancy, obesity, scleroderma, smoking, alcohol, coffee, chocolate, and fatty or spicy foods, amongst others.

Oesophagitis is uncommon without additional aetiologic factors.

#### 4.4.3 Trauma

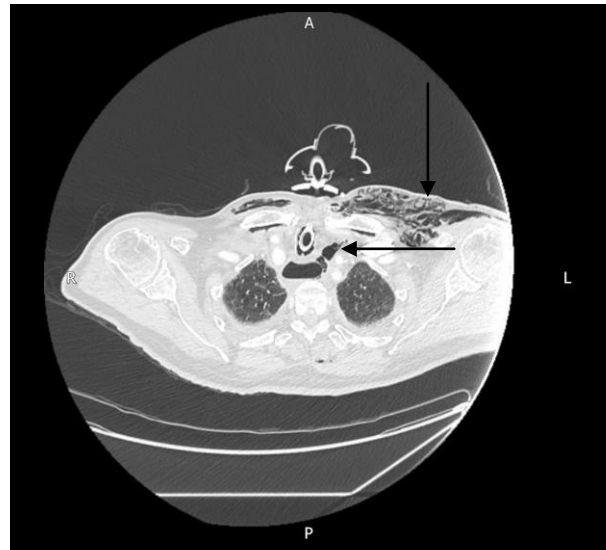
Oesophageal trauma can be classified into three major categories: iatrogenic trauma, self-induced trauma and direct trauma.

##### **Iatrogenic trauma**

*Aetiology.* This can include endoscopic perforation, trauma due to dilatation, surgical trauma, radiation trauma, and drug trauma. Iatrogenic injury through oesophageal instrumentation is the leading cause of perforation by either piercing or shearing and may be due to any number of procedures, particularly endoscopy and dilatation of strictures. Such tears often occur near the pharyngo-oesophageal junction, where the wall is weakest and the muscle can be tight.

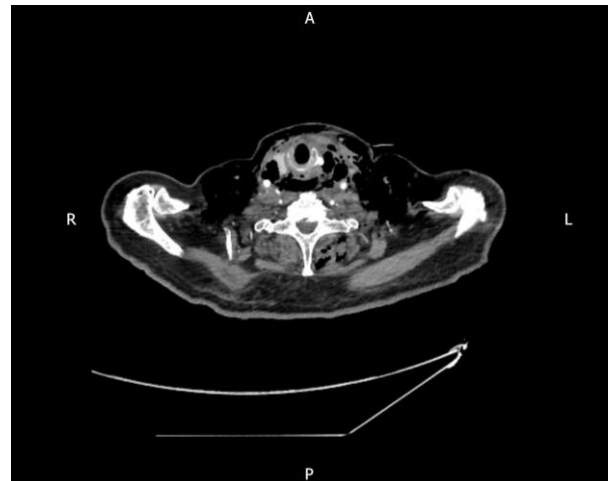
*Clinical features* are dramatic and include blood-stained vomitus, severe pain behind the sternum, between the shoulders and upper abdomen, fall of blood pressure, and rapid circulatory collapse.

Oesophageal perforation is a condition with a high mortality rate (varying from 5–75%); higher rates correlate with delays in both presentation and diagnosis. Early recognition of oesophageal perforation as a diagnosis is the first and most important step in management.



**Figure 4.3a**

Surgical emphysema – pneumomediastinum;  
CT scan, axial plane



**Figure 4.3b**

Surgical emphysema, note air bubbles in the neck;  
CT scan, axial view

*Diagnosis* is based on history, signs of surgical emphysema of the neck (Figure 4.3), dyspnoea, and acute abdominal signs.

*Treatment* includes intravenous access, supplemental oxygen (as necessary), and administration of a broad spectrum antibiotic. The patient should be made nothing by mouth and have a nasogastric tube placed to clear gastric contents and limit further contamination. Analgesia should be given as needed. While historically treated exclusively with surgery, recent evidence indicates that patients with small well-defined tears and minimal extraoesophageal involvement may be managed with conservative treatment.

### Self-induced trauma

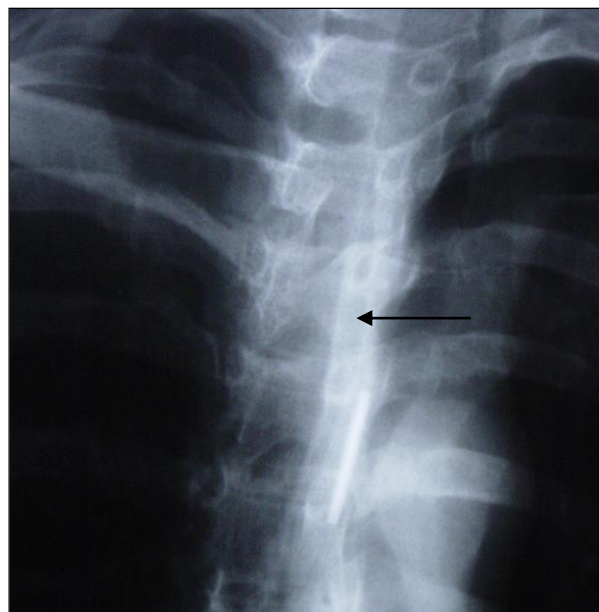
This includes foreign bodies, corrosive or drug ingestion, and post-emetic trauma.

Adults with **oesophageal foreign bodies** usually present acutely, with a history of ingestion. *Aetiology and clinical features.* Dysphagia is to be expected in adults. If the obstruction is complete, an inability to handle secretions is common. The classic adult presentation is an elderly individual with dentures who has had some alcohol and is eating meat. Adults should be asked about the use of dentures and circumstances surrounding the ingestion.

In children with oesophageal foreign bodies, the history may be less clear. As many as 35% of children with oesophageal foreign bodies are asymptomatic; the history is given by a parent who has seen the child with an object in his or her mouth and suspects the child might have swallowed it. Such reports must be taken seriously and investigated. Gagging, vomiting, and neck or throat pain are common presentations. Children with longer term oesophageal foreign bodies may also present with poor feeding, irritability, failure to thrive, fever, stridor or pulmonary symptoms, such as repetitive pneumonias from aspiration. Large oesophageal foreign bodies at the UOS can cause tracheal impingement in children, with resultant stridor or respiratory compromise.

*Diagnosis.* Suspected radiopaque foreign bodies can be easily localised on plain radiographs (Figure 4.4). For nonradiopaque foreign objects,

plain radiographs are not useful. Studies such as barium swallows or CT scanning may help to confirm or localise a foreign body, but often they only delay definitive care.



**Figure 4.4**

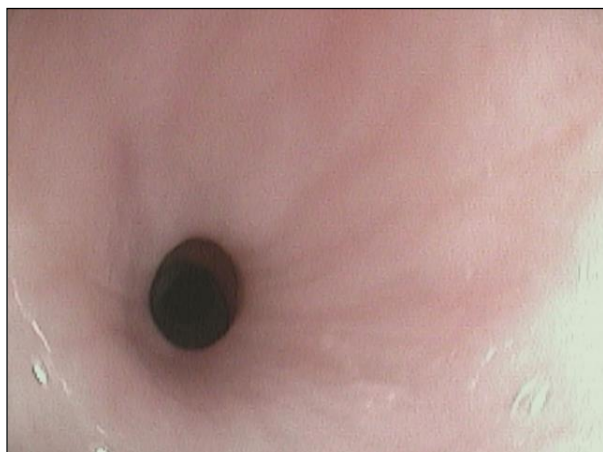Ingested coin in the oesophagus; plain radiograph, postero-anterior view

*Treatment.* Endoscopic removal with forceps during rigid oesophagoscopy under anaesthesia is the treatment of choice. Smooth-muscle relaxation agents may be used to relax oesophageal sphincters to allow the passage of foreign bodies.


**Caustics and corrosives** cause tissue injury through a chemical reaction. *Alkaline ingestions* cause tissue injury through liquefactive necrosis. Severe injury occurs rapidly after alkaline ingestion, within minutes of contact. The most severely injured tissues are those that first contact the alkali, which is the squamous epithelial cells of the oropharynx, hypopharynx, and oesophagus. The oesophagus is the most commonly involved organ, with the stomach much less frequently involved after alkaline ingestions. Tissue oedema occurs immediately, may persist for 48 hours, and may eventually progress sufficiently to create airway obstruction. Over time, if the injury is severe



enough, granulation tissue begins to replace necrotic tissue. Over the next 2–4 weeks, any scar tissue formed initially remodels and may thicken and contract enough to form strictures (Figure 4.5). The likelihood of stricture formation primarily depends upon the depth of the burn. Superficial burns result in strictures in fewer than 1% of cases, whereas full-thickness burns result in strictures in nearly 100% of cases. The most severe burns may also be associated with oesophageal perforation.



**Figure 4.5a**  
Postcorrosive stricture



**Figure 4.5b**  
Dilatators

*Acid ingestions* cause tissue injury through coagulation necrosis, which causes denaturation of superficial tissue proteins, often resulting in the formation of an eschar. This eschar may protect the underlying tissue from further damage. Unlike

alkali ingestions, the stomach is the most commonly involved organ following ingestion of acid. This may be due to some natural protection of the oesophageal squamous epithelium. The eschar sloughs in 3–4 days and granulation tissue fills the defect. Perforation may occur at this time.

*Treatment.* Some aspects of *treatment* are controversial, e.g. timing of oesophagoscopy or dilution of the injury.

- Attempt to identify the specific product, concentration, and estimated volume and amount ingested.
- Small amounts of a diluent may be beneficial if administered as soon as possible after a solid or granular alkaline ingestion, to remove any adhering particles to the oral or oesophageal mucosa. Water or milk may be administered in small amounts. It is very unlikely to be of any benefit after more than 30 minutes.
- Diluents should not be used with any acid ingestion or liquid alkaline ingestion. The risk of vomiting with re-exposure of the oral or oesophageal mucosa to the offending substance can result in a worsening injury or perforation.
- Neutralisation: do not administer a weak acid in alkaline ingestions or a weak alkaline agent in acid ingestions. There is a risk of heat production resulting from this exothermic reaction.
- Because of the risk of rapidly developing oedema of the airway, immediate assessment of the patient's airway status should be performed and continually monitored.
- Do not administer emetics because of re-exposure of mucosa to the caustic agent.
- Oesophagogastroduodenoscopy seems unnecessary in asymptomatic patients.
- An NG tube should be inserted.
- If large-volume liquid acid ingestions is identified, NG suction may be beneficial if performed rapidly after ingestion. NG suction may prevent small intestine damage.

#### Oesophageal stricture

Benign oesophageal stricture is a condition in which the diameter of the oesophagus has been narrowed by scar tissue. The most common cause of this condition is gastroesophageal



reflux disorder. Other causes include ingestion of an acidic or corrosive substance, iatrogenic damage, or radiation therapy to the chest or neck. Typical symptoms include dysphagia, unintended weight loss, and regurgitation of food or liquids. *Treatment* varies depending on the severity of the stricture as well as its underlying cause. Oesophageal dilatation with the balloon or dilators is the preferred option in most cases; in some cases a stent might be inserted. Dilatation may need to be repeated after a period of time. Proton pump inhibitors are amongst the most effective medical options for managing the reflux disease and preventing the backup of acid, which can contribute to the damage.

#### **Spontaneous rupture of the oesophagus (Boerhaave syndrome)**

Spontaneous rupture of the oesophagus can occur secondary to a sudden increase in intraluminal pressures, usually due to violent vomiting or retching, and often follows heavy intake of food and alcohol.

#### **Direct trauma**

This can be penetrating or blunt. Blunt trauma resulting in oesophageal perforation is exceedingly rare. Penetrating injuries to the oesophagus are usually caused by gunshot or knife wounds, although cervical oesophageal perforation secondary to cervical spine surgery has been recognised. Perforation of the cervical oesophagus may be diagnosed initially by the finding of extramural air on radiographic studies such as lateral views of the neck or computed tomography. *Treatment* goals are to treat infection and minimise and prevent further septic contamination; to provide nutritional support; and to restore the continuity of the digestive tract.

#### **4.4.4 Diverticulum**

See Chapter 3.4.5

#### **4.4.5 Tumours of the oesophagus**

Benign tumors of the esophagus are rare, the most common type is leiomyoma, followed by fibrovascular polyp and schwannoma.

Cancer of the oesophagus is a devastating disease, with a high index of mortality as it often presents in

late stages. The overall 5-year survival rate for cancer of the oesophagus is less than 20%. In clinical stage IV a 5-year survival rate is less than 5%. The principal histologic types are squamous cell carcinoma (any part of the oesophagus, mainly upper half) and in the distal part adenocarcinoma (typically develops in specialised intestinal metaplasia — Barrett's metaplasia — that develops as a result of gastroesophageal reflux disease). Cancer is generally more common in men than in women, and the male-to-female ratio is 3–4:1. Cancer of the oesophagus occurs most commonly during the sixth and seventh decades of life.

*Risk factors.* There are several factors that increase the incidence of cancer of the oesophagus. Smoking cigarettes and drinking alcohol are independent risk factors, but combined they increase the risk of squamous cell cancer by 20 times. A diet deficient in fruits and vegetables increases the possibility of cancer of the oesophagus. Medical conditions associated with an increased risk of cancer of the oesophagus include achalasia, Plummer–Vinson syndrome, Barrett's oesophagus, oesophageal strictures, prior radiation to mediastinum, history of head and neck cancer or HPV infection.

*Clinical presentation.* Presenting signs and symptoms of oesophageal cancer include dysphagia (most common), weight loss (second most common), bleeding, epigastric or retrosternal pain, hoarseness and persistent cough.

*Diagnosis.* Endoscopic examination allows direct visualisation and biopsies of the cancer, while endoscopic ultrasonography is the most sensitive test for determining the depth of penetration of the cancer and the presence of enlarged perioesophageal lymph nodes. In patients who appear to have localised oesophageal cancer, positron emission tomography (PET) scanning may be a useful part of the baseline staging.

*Differential diagnosis.* Oesophageal lesions other than cancer can cause dysphagia. These include peptic strictures from gastroesophageal reflux, achalasia and benign oesophageal tumours (principally oesophageal leiomyoma). Imaging studies help to differentiate these lesions from cancer of the oesophagus.

*Treatment.* Surgery has traditionally been the treatment for cancer of the oesophagus. Chemotherapy and radiotherapy for cancer of the oesophagus have some role when delivered preoperatively. Primary chemoradiation followed by salvage surgery is more common in some countries. Patients who are not amenable to radical treatment due to advanced stage or significant co-morbidities can receive symptom control treatment. These include palliative radiotherapy, laser therapy and the insertion of an oesophageal stent.

#### 4.4.6 Motility disorders

---

##### **Oesophageal peristalsis**

Peristalsis is a sequential, coordinated contraction wave that travels the entire length of the oesophagus, propelling intraluminal contents distally to the stomach. The LOS relaxes during swallows, stays open until the peristaltic wave travels through the LOS, and then contracts and redevelops a resting basal tone.

*Primary peristalsis* is the peristaltic wave triggered by the swallowing centre. The peristaltic contraction wave travels at a speed of 2 cm/s. The *secondary peristaltic* wave is induced by oesophageal distension from the retained bolus, refluxed material, or swallowed air. The primary role is to clear the oesophagus of retained food or any gastroesophageal refluxate.

*Tertiary contractions* are simultaneous, isolated, dysfunctional contractions. These contractions are nonperistaltic, have no known physiologic role, and are observed with increased frequency in elderly people. Radiographic description of this phenomenon has been called presbyoesophagus.

---

Oesophageal motility disorders are less common than mechanical and inflammatory diseases affecting the oesophagus. The clinical presentation of a motility disorder is varied, but patients usually complain of dysphagia and chest pain.

Before entertaining a diagnosis of a motility disorder, the patient must be evaluated for a mechanical obstructing lesion.

**Achalasia** is caused by the absence of relaxation of the lower oesophageal sphincter during

swallowing; the normal peristalsis is lost. Loss of ganglion cells from the wall of the oesophagus is thought to be the cause. There is a retention of food in the oesophagus causing megaesophagus, especially in children. Treatment consists of injections of botulinum toxin, dilatations or surgical treatment. Surgical treatment targets the spastic sphincter (myotomy) and relieves the high pressures at the gastroesophageal junction.

**Cricopharyngeal achalasia** is caused by defective opening or insufficient relaxation of UOS. Contrast swallow radiograph shows hold-up of the barium bolus above the cricopharyngeus. It can be associated with various pathological conditions (cerebrovascular diseases, post laryngectomy, Parkinson's syndrome), many times the reason is not fully understood. Dilatation or surgical treatment (cricopharyngeal myotomy) can be warranted in some carefully selected patients.

**Spastic oesophageal motility disorders** include a diffuse oesophageal spasm, nutcracker oesophagus, and hypertensive lower oesophageal sphincter. There appears to be a functional imbalance between excitatory and inhibitory postganglionic pathways, disrupting the coordinated components of peristalsis.

**Secondary oesophageal motility disorders** occur as manifestations of systemic diseases. They might be related to scleroderma, diabetes mellitus, alcohol consumption, psychiatric disorders, and presbyoesophagus. In scleroderma, the primary defect in this systemic process is related to smooth muscle atrophy and fibrosis. Oesophageal dysmotility develops as the smooth muscle of the oesophagus is replaced by scar tissue, gradually leading to progressive loss of peristalsis and a weakening of the lower oesophageal sphincter.

---

##### **Presbyoesophagus**

Presbyoesophagus is a radiographic term used to define asymptomatic peristaltic abnormalities in elderly patients. Manometry studies show motility disorders, including failed peristalsis, decreased LOS relaxation, and increased spontaneous contractions. Symptoms correlate poorly with peristaltic abnormalities.

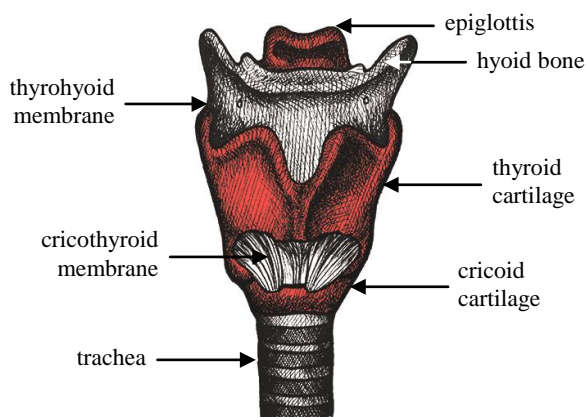
---



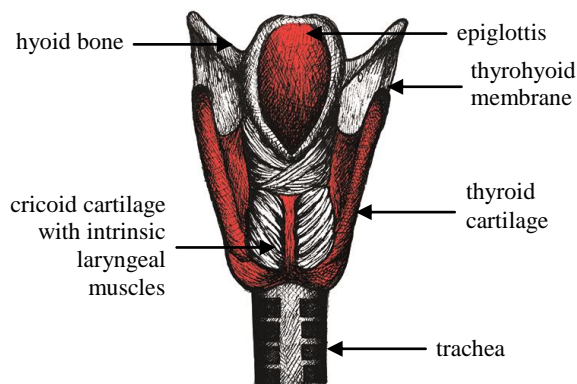
# 5 LARYNX AND TRACHEA

## 5.1 APPLIED ANATOMY

The larynx is the part of the respiratory tract between the pharynx and the trachea; it extends from the tip of the epiglottis to the lower edge of the cricoid and is composed of a cartilaginous framework, connected by ligaments, membranes and muscles (Figure 5.1). Vocal cords (vocal folds) are located inside larynx.



**Figure 5.1a**  
Larynx – anterior view



**Figure 5.1b**  
Larynx – posterior view

### Embryology

The larynx develops from the endodermal lining and the adjacent mesenchyme of the foregut between the fourth and sixth branchial arches. Prenatal development can be divided into the embryonic phase (0–8 weeks), characterised by organogenesis, and the foetal phase, characterised by organ maturation. The larynx has cartilages surrounding it and it is developing from the mesenchyme of the fourth and the sixth pairs of pharyngeal arches (from the neural crest cells). Arytenoid swelling is formed at the cranial end of the laryngotracheal tube by the proliferation of the mesenchymal tissue. It will grow towards the tongue and forms the primordial glottis. As it grows further, it changes the primordial glottis into a T-shaped laryngeal inlet. Temporary occlusion of the laryngeal inlet occurs due to rapid proliferation of the epithelial lining of the larynx. By the 10th week of gestation, recanalisation occurs and, consequently, a pair of laryngeal ventricles is formed. The laryngeal ventricles are bound by tissue, which develops into false and true vocal cords. Proliferation of the mesenchyme in the ventral part of the 3rd and 4th pharyngeal arches will form the hypopharyngeal eminence and, later, the epiglottis. The superior laryngeal nerve will supply the part of the larynx that develops from the 4th pharyngeal arch. The recurrent laryngeal nerve will supply the part of the larynx that derives from the 6th pharyngeal arch. The two nerves are branches of the vagus nerve. In children the larynx continuously descends from the level of C2 to the level of C4–C7 at the age of 6 years.

The lower respiratory system begins its development during the 4th week as an outgrowth of the ventral wall of the foregut (respiratory diverticulum). The endodermal lining of the respiratory diverticulum gives rise to the epithelial lining of the larynx, trachea, bronchi and alveoli. The cartilaginous and muscular components of the trachea and lungs are derived from the surrounding splanchnic mesoderm. The diverticulum elongates in the caudal direction and soon becomes separated from the foregut by the esophagotracheal septum. The ventral portion forms the trachea and lung buds, while the dorsal portion forms the esophagus.

### Laryngeal skeleton

The laryngeal skeleton consists of three single cartilages (thyroid, cricoid, epiglottis) and paired cartilages (arytenoid, corniculate, cuneiform).

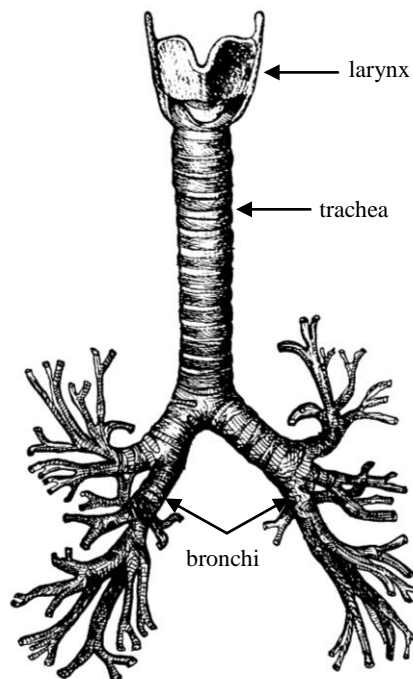
*The thyroid cartilage* is the largest cartilage of the larynx and is composed of two lamina. They are

fused in the midline (in the male they fuse at about 90 degrees, making a laryngeal prominence or Adam's apple). The thyroid cartilage is united by a joint to the cricoid cartilage.

*The cricoid cartilage* is a complete ring (the only one in the airway) and serves as the major support for the functioning larynx. Its shape is classically described as that of a signet ring. Its inferior border is nearly horizontal and is attached to the first tracheal cartilage by the cricotracheal ligament.

*The arytenoid cartilages* are paired cartilages that articulate with the posterosuperior portion of the cricoid cartilage. Each arytenoid is almost pyramidal in shape.

*The epiglottis* is a leaf-shaped elastic fibrocartilage that functions mainly as a backstop against the entrance of swallowed matter into the laryngeal aditus. Superiorly, it is attached to the hyoid bone by the hyoepiglottic ligament; inferiorly at the stem (or petiole), it is attached to the inner surface of the thyroid cartilage by the thyroepiglottic ligament.



**Figure 5.2**  
Tracheobronchial tree

*The trachea* and the two *primary bronchi* are referred to as **the bronchial tree**. At the end of the bronchial tree lie the alveolar ducts, the alveolar sacs, and finally the alveoli. The trachea is a cartilaginous and membranous tube, extending from the lower part of the larynx, on a level with the sixth cervical vertebra, to the upper border of the fifth thoracic vertebra, where it divides into the two bronchi, one for each lung (Figure 5.2).

#### Laryngeal movements during swallowing

The larynx is raised anterosuperiorly during swallowing. This action pushes the epiglottis against the base of the tongue, posteriorly displacing it over the laryngeal aditus. The muscles, ligaments and membranes of the larynx allow movements between cartilages.

The thyrohyoid membrane attaches the superior part of the thyroid cartilage to the hyoid bone. The cricothyroid membrane connects thyroid and cricoid cartilage and is the site of coniotomy (cricothyroidectomy). The lateral part of the cricothyroid ligament is called the conus elasticus; its free edge is the vocal ligament, which forms together with the vocal muscle base of the *vocal folds*. The free edge of the quadrangular ligament, connecting the epiglottis and vocal process of the arytenoids, is the base of *aryepiglottic fold*. The vestibular ligament is the base of the *ventricular fold*. The ventricle or sinus of Morgagni is the small space between the false and true vocal folds. The ventricle is often hidden during laryngoscopic examination of the larynx unless exposed by lateralisation of the false vocal fold.

#### Muscles of larynx

The **extrinsic** muscles (sternohyoid, thyrohyoid, sternothyroid, omohyoid, stylohyoid, digastric, geniohyoid) are those muscles of the laryngohyoid complex that serve to raise, lower, or stabilise the larynx.

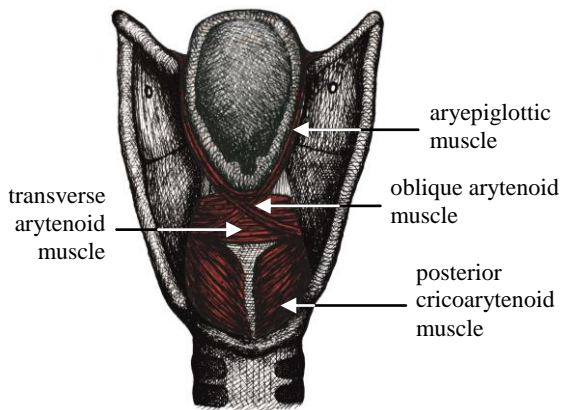
The **intrinsic** muscles are responsible for vocal cord mobility and tension and we can divide them into:

- *abductors* – posterior cricoarytenoid muscle—responsible for opening of the glottis and abduction of the vocal cord



- *adductors* – lateral cricoarytenoid muscle, transverse arytenoid muscle or interarytenoid muscle (unpaired), lateral thyroarytenoid muscle – responsible for closure of vocal cords, adduction of the vocal cords
- *tensors* – cricothyroid muscle, medial thyroarytenoid muscle (vocalis muscle) – tension of the vocal cord (Figure 5.3).

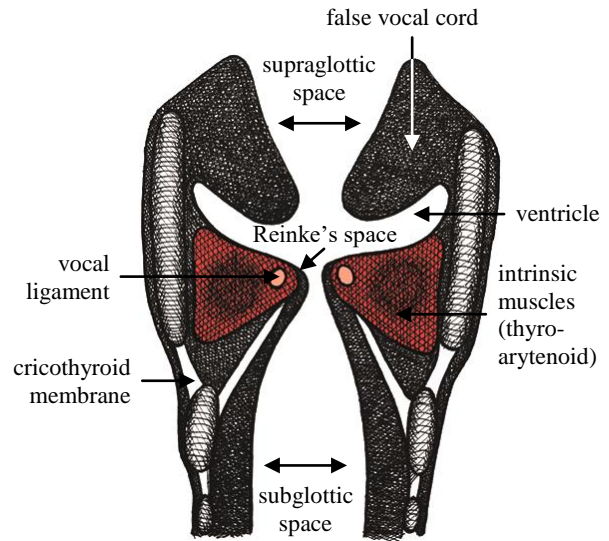
The muscles work synergistically and antagonistically to control the functions of the larynx.



**Figure 5.3**

Intrinsic laryngeal muscles

fold is in the anteroposterior aspect considered the structure between the vocal process of the arytenoid and the anterior commissure. The slit between vocal folds (rima glottidis) constitutes *the glottis*; the glottic space is formed by vocal folds and 1 cm inferiorly.



**Figure 5.4**

Section of larynx in the coronal plane

### Laryngeal histology

The larynx is lined by pseudo-stratified columnar ciliated epithelium with goblet cells (*respiratory epithelium*), except for the true vocal cords, the tip of the epiglottis and aryepiglottic folds, which are lined by non-keratinised stratified squamous epithelium.

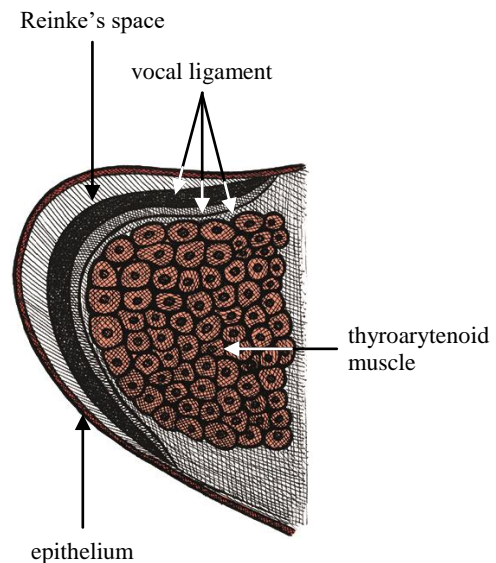
Reinke's space is a closed cleft beneath the epithelium of the vocal cord with no glands and lymphatic vessels.

### The internal anatomy of the larynx

It consists of three compartments: supraglottis, glottis and subglottis (Figure 5.4).

*The supraglottis* includes the laryngeal surface of the epiglottis, aryepiglottic fold (false vocal cords), arytenoid, vestibular folds and ventricle.

*The vocal cord* (true vocal cord, vocal fold) includes the vocal ligament, the vocalis muscle, and the mucosal covering (Figure 5.5). The vocal



**Figure 5.5**

Transverse section of the vocal fold

The movement of air upwards between the vocal folds causes the coverings of the vocal fold to be drawn together. For a fraction of a second they meet one another, until pressure builds up below the cords and they are blown apart. The resulting movements of the coverings are known as the mucosal wave.

**The trachea** is lined with *respiratory mucosa*. The mucous membrane is continuous above with that of the larynx, and below with that of the bronchi. It consists of areolar and lymphoid tissue, and presents a well-marked basement membrane, supporting a stratified epithelium, the surface layer of which is columnar and ciliated, while the deeper layers are composed of oval or rounded cells. Beneath the basement membrane there is a distinct layer of longitudinal elastic fibers with a small amount of intervening areolar tissue. The submucous layer is composed of a loose mesh-work of connective tissue, containing large blood vessels, nerves, and mucous glands; the ducts of the latter pierce the overlying layers and open on the surface.

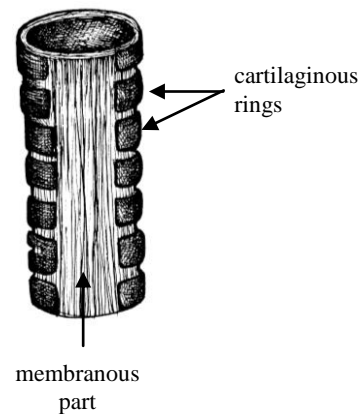
**The trachea** is attached to the *cricoid cartilage*. It is 10–13 cm long in the adult, is flattened posteriorly; its diameter is from 2 to 2.5 cm. It is bigger in the male than in the female; in the child the trachea is smaller, more deeply placed, and more movable than in the adult. *The cartilages of the trachea* vary from sixteen to twenty in number; each forms an imperfect ring, which occupies the anterior two-thirds of the circumference of the trachea, being deficient posteriorly (Figure 5.6). The posterior aspect of the trachea is formed by the membranous portion which lies in contact with the anterior wall of the oesophagus. The arch of the aorta is at first anterior to the trachea and then on its left side immediately superior to the left main bronchus. Other close relations include the brachiocephalic and left common carotid arteries.

**The carina**, the origin of the two main bronchi, lies at the level of sixth thoracic vertebra, it bifurcates into right and left primary bronchi. Each bronchus runs freely a few centimeters, then it enters the lungs. *The right main bronchus*, about 2.5 cm in length, is shorter, wider, and more nearly vertical than the left. Because it is in almost a direct line with the trachea, foreign objects traversing the trachea are more likely to enter the right main bronchus. *The left main bronchus* is smaller in caliber but longer than the right bronchus, 5 cm or more in length, crosses beneath

the aortic arch, anterior to the esophagus. Both bronchi have cartilaginous rings that are replaced by separated plates at the roots of the lungs. Each primary bronchus divides into secondary bronchi known as *lobar bronchi* (each one directly conducts the air to and from one of the lung's five lobes). They divide into tertiary bronchi known as *segmental bronchi* (they conduct air to and from bronchopulmonary segment).

*The trachea* is supplied with blood by the inferior thyroid arteries. The veins end in the thyroid venous plexus.

*The nerves* are derived from the vagus and the recurrent nerves, and from the sympathetic; they are distributed to the tracheal muscles and between the epithelial cells. The bronchi are supplied by the bronchial arteries and veins, and their innervation is similar to that of the trachea.



**Figure 5.6**

Trachea – posterior view

*The subglottis* extends from the glottis down to the inferior border of the cricoid cartilage.

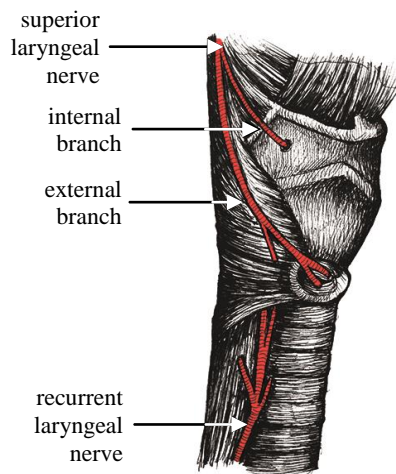
*The preepiglottic space* lies anterior to the epiglottis, which serves as its posterior boundary. *The paraglottic space* lies on each side of the glottis. This space lies above and below the true and false vocal folds and is important in the transglottic and extralaryngeal spread of neoplasms.

### Nerve supply

The nerve supply of the muscles of the larynx is provided by the recurrent laryngeal nerve and by the external branch of the superior laryngeal nerve

(Figure 5.7). The recurrent laryngeal nerves are branches of the vagus nerve; due to their embryological development, they have a long course, especially on the left side. It supplies the ipsilateral internal laryngeal musculature and contralateral part of interarytenoid muscle and sensation to the laryngeal mucosa inferior to the glottic cleft.

The superior laryngeal nerve divides into an internal branch, which supplies sensation to the interior of the larynx, and an external branch, which provides the motor supply to the external cricothyroid muscle (adjusting the tension of the vocal folds).



**Figure 5.7**  
Laryngeal nerves

### Laryngeal vessels

The arterial supply to the larynx consists of branches of the superior and inferior laryngeal arteries. The superior laryngeal artery originates from the external carotid artery and supplies the supraglottic part of the larynx. The inferior laryngeal artery is a branch of the inferior thyroid artery that comes off the thyrocervical trunk branching from the subclavian artery supplying the subglottic part. The venous supply parallels the arterial supply.

### Lymphatic drainage

Understanding the lymphatic drainage of the larynx is a prerequisite to understanding the

spread of cancer of the larynx, as well as the operative procedures designed to eradicate the cancer. Lymph from the larynx is collected in the superior and inferior deep cervical lymph nodes. The glottis forms the embryologic barrier between the superior and inferior lymphatic streams. The drainage of the supraglottic structures is rich and follows the superior laryngeal and superior thyroid vessels into the prelaryngeal node and upper deep cervical lymph nodes. The vocal cord has no lymphatic capillaries. The subglottis capillary network is not as dense as the supraglottic, and lymph is drained to the middle deep cervical nodes, as well as to prelaryngeal nodes (Delphian node), in addition to peritracheal and mediastinal lymph nodes.

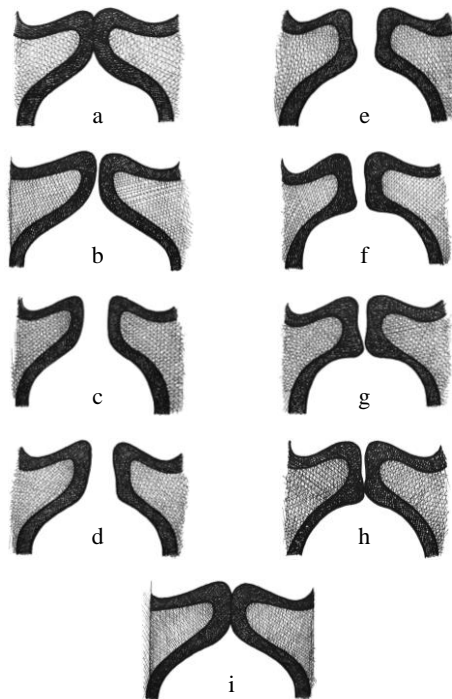
In children the laryngeal cavity is smaller than in adults, the cartilaginous support is less firm, and the mucosa is able to swell dramatically.

## 5.2 PHYSIOLOGY

The function of the larynx is complex. The function of the upper aerodigestive tract acts as a unit and not just as the sum of the activities of component organs. Eating and breathing cannot be conducted simultaneously and its coordination is a complex process.

### Phonation

The larynx can only form a sound when the vocal folds vibrate (Figure 5.8). The movement of air upwards between the vocal folds causes the coverings of the vocal fold to be drawn together (phonation position of the vocal folds). For a fraction of a second they meet one another, until pressure builds up below the cords and they are blown apart. The resulting movements of the coverings are known as the mucosal wave. Together with the covering epithelium, the lamina propria is essential for voice production. The sound is modified by the movements of the pharynx, palate, tongue, and lips to form speech.

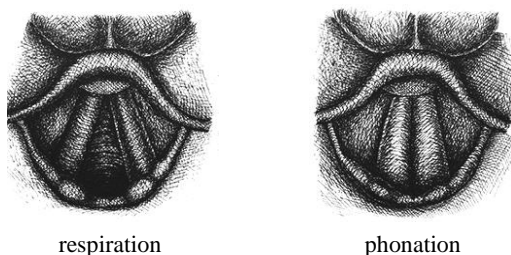


**Figure 5.8**  
Vocal cord vibrations

Hoarseness is the result of noise formed by endolaryngeal turbulence in the airstream and irregularities in the normally periodic vibrations of the vocal folds. Speech requires coordinated interaction of the mouth, pharynx, larynx, lungs, diaphragm, and abdominal and neck muscles.

### Respiration

The vocal folds are in the respiratory position; the glottis is open and is under reflex control, which depends on gas exchange and acid–base balance. (Figure 5.9)



**Figure 5.9**  
Respiratory and phonation positions of the vocal cords

### Protection of the lower respiratory tract

The sphincter function is the oldest phylogenetic function of the larynx. There are three levels of protection: epiglottis, vestibular folds and vocal cords.

The primary and most primitive function of the larynx is to protect the lower airway from contamination by foods, liquids and secretions. The base of the tongue, posterior pharyngeal wall, and faucial pillars are also involved in swallowing. The swallowing reflex, transmitted in the glossopharyngeal nerve, ensures cessation of respiration and contraction of the aryepiglottic folds, vocal folds, and vestibular folds, and tilting of the epiglottis by the thyroepiglottic muscle. Simultaneously, the suprahyoid musculature contracts, drawing the larynx anteriorly and superiorly by 2–3 cm. The food bolus is propelled backwards over the tongue; from here it passes in the piriform sinuses. Experience with surgical removal of the epiglottis shows that this structure is only of limited significance for protecting the lower airway. An intact sensory nerve supply to the mucosa of the laryngeal aditus from the internal branch of the superior laryngeal nerve is more important (see also Chapter 3.2.1).

### Cough

The cough reflex is stimulated by particles of food touching the vestibular folds or penetrating through the larynx. It consists of a deep reflex inspiration with the larynx open. The glottis closes with rising intrathoracic pressure and then opens suddenly with an explosive expiratory stream, and the foreign body is coughed out.

### Physiology of trachea

The main function of the trachea is to provide a clear airway for air to enter and exit the lungs. *Warming, cleaning and humidification* of the air begin in the nose and are completed in the lower airway. In addition, the epithelium lining the trachea produces mucus that traps dust and other contaminants and prevents it from reaching the lungs. Air to the lungs is distributed through the *bronchial tree*. The alveoli are responsible for the primary function of the lungs: exchanging carbon dioxide and oxygen. A layer of protective mucus,



called a mucus blanket, covers a large portion of the mucous membrane lining the bronchial tree. The mucus is an important air purifier. Microscopic, hair-like cilia move the cleansing mucus up to the pharynx where it can be swallowed and digested in the gastrointestinal tract. Cigarette smoke paralyzes the cilia, which allows mucus to accumulate and leads to what is called smoker's cough.

## 5.3 EVALUATION

### History

Attention is paid to symptoms such as hoarseness, change in the quality of the voice, dyspnoea, difficulty in breathing, stridor, cough, expectoration, haemoptysis, pain, dysphagia or choking.

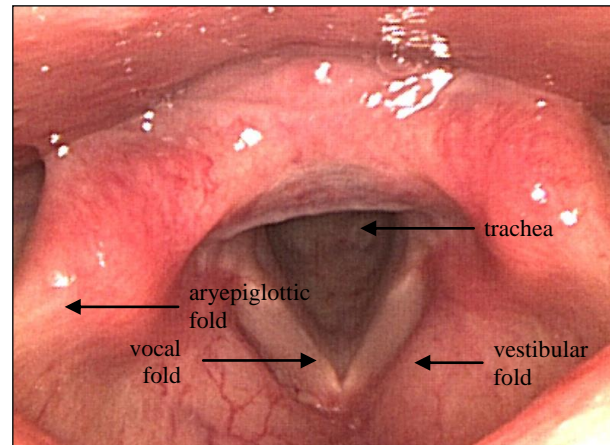
### Physical examination

Laryngeal structures are *palpated* during respiration and swallowing. We evaluate tenderness, crepitus, swelling and structures such as the thyroid cartilage, cricothyroid membrane, carotid artery, and thyroid gland.

To confirm any diagnosis the larynx must be thoroughly examined. The traditional method was *indirect nasolaryngo-scopy*. However, *direct flexible nasolaryngo-scopy* is now the preferred method. During the direct laryngoscopy we can examine the nose, nasopharynx (when using a flexible endoscope), oropharynx, piriform sinuses, glossoepiglottic and aryepiglottic folds, epiglottis, arytenoids, vestibular folds, ventricle, vocal folds, and part of the subglottis. Anatomy and function of laryngeal structures are noted (Figure 5.10). *Laryngeal videoendoscopy* uses a camera-based flexible endoscope and provides superior picture quality.

*Microlaryngoscopy* consists of the addition of a binocular operating microscope, is done under general anaesthesia, and gives an excellent view of the larynx, trachea, and hypopharynx.

*Stroboscopy* is a lighting technique that helps clinicians to examine the body-cover relationship and vibration patterns, and it is valuable for describing mucosal disease and its effect on vocal fold vibration.



**Figure 5.10**

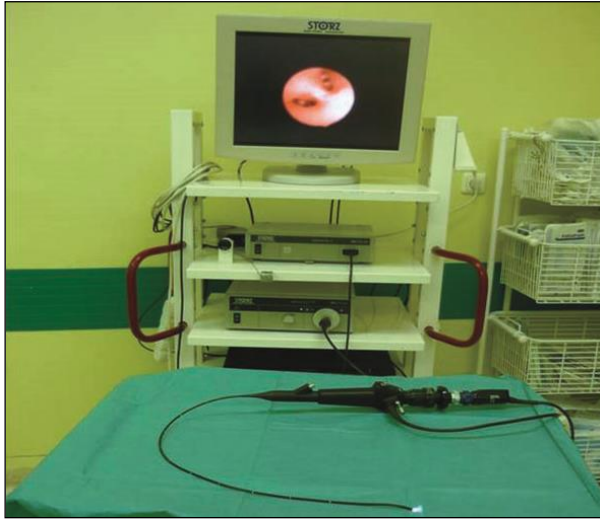Endoscopic view on flexible nasolaryngoscopy

*Tracheobronchoscopy* is direct endoscopic examination of trachea and bronchi. It can be performed as *flexible or rigid* (Figure 5.11). *Rigid bronchoscopes* are tubes with different calibers with a proximal light source. Bronchoscopy is mostly done under general anesthesia and rigid bronchoscope may be directly connected to the anesthetic machine. The advantage of rigid bronchoscopy is the larger lumen that affords access to larger instruments, which may be necessary to remove foreign bodies, to provide adequate suction in brisk hemoptysis, to place noncompressible Silastic airway stents, and to use the bronchoscope itself to core out tumors and to provide direct tamponade to a bleeding source.

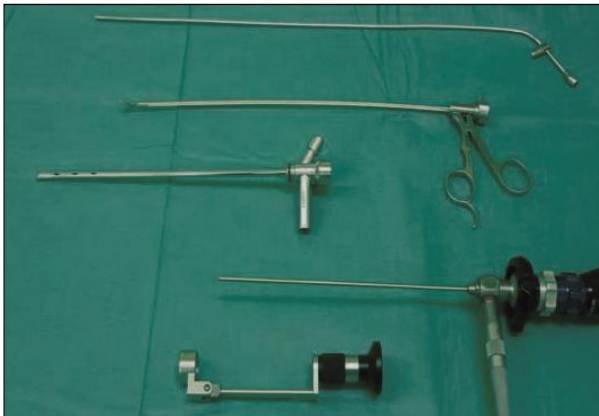*Flexible tracheobronchoscopy* may be carried out without general anesthesia; through nose, mouth or tracheostomy. In children it is mostly done in general anesthesia. In the flexible bronchoscope there is also a working channel for suction of secretions and blood, for the passage of topical medication and fluid for washing, and for the passage of various instruments. Even when there are no gross endobronchial lesions, the presence of extrinsic tracheal deviation and compression due to paratracheal masses should be noted.

*Airway endoscopy* is essential tool for the diagnosis of pharyngo-laryngeal, tracheal and bronchial pathologies.





**Figure 5.11a**  
Bronchoscopy – flexible

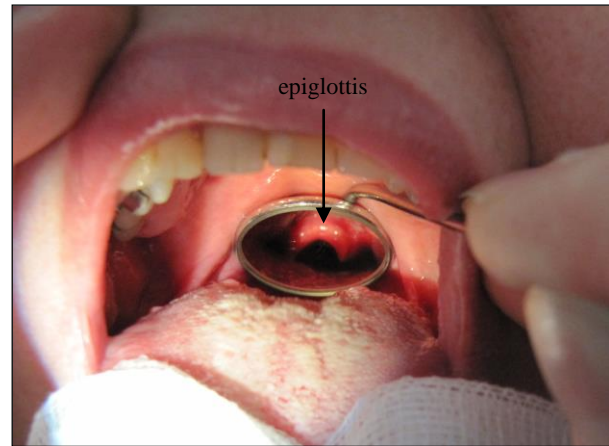


**Figure 5.11b**  
Bronchoscopy – rigid bronchoscopes

#### **Indirect laryngoscopy**

The head mirror as a source of reflected light can be used. An angled laryngeal mirror is held at the back of the mouth against the soft palate. The tongue is grasped with the thumb and middle finger of the non-dominant hand; the tongue is drawn forwards carefully. The light from the mirror is directed to the uvula, and the laryngeal mirror is warmed to the body temperature and is introduced along the palate until it reaches the uvula, which is lifted and pushed upwards with the posterior part of the mirror. The posterior part of the tongue, the pharynx, and part of the larynx are visible in the mirror. The patient is asked to say “ee” to bring the epiglottis

into a more upright position, thus giving a better view of the larynx. It also permits assessment of cord mobility as well as identification of mass lesions (Figure 5.12).



**Figure 5.12**  
Indirect laryngoscopy

#### **Imaging**

*Plain radiographs*, lateral or sagittal, have limited value and are rarely indicated.

*Computed tomography (CT)* and *magnetic resonance (MR)* imaging have become the procedures of choice for defining mass lesions and traumatic abnormalities. These procedures can supplement the findings at laryngoscopy when additional diagnostic information is required to plan treatment.

## 5.4 DISEASES OF THE LARYNX AND TRACHEA

### 5.4.1 Congenital anomalies

#### **Stridor**

*Definition.* Stridor is not a single pathology, it is a term used to describe noisy breathing.

*Clinical features.* Stridor is the main symptom of any laryngeal obstruction. Stridor is a symptom, not a diagnosis or a disease, and the underlying cause must be determined. Inspiratory stridor suggests

obstruction of the larynx. Expiratory stridor implies tracheobronchial obstruction. Biphasic stridor suggests a subglottic or glottic anomaly.

*Diagnosics.* In children, much can be learned about the nature of the laryngeal problem by close observation of the infant and listening to the noise produced as air passes through the obstruction. In most cases of stridor, besides a complete history and physical examination, along with other possible additional studies, flexible or rigid endoscopy is required for an adequate evaluation of the aetiology.

*Treatment* is dependent on the aetiology.

### **Laryngomalacia**

*Definition.* Laryngomalacia (or congenital flaccid larynx) is the most frequent congenital anomaly of the larynx. It produces partial obstruction of the supraglottic airway.

*Aetiology.* The cause is unclear.

*Clinical features.* The newborn typically will develop intermittent, inspiratory, low-pitched stridor within the first 2 weeks of life, which resolves slowly over several months. The symptom worsens during feeding.

*Diagnosis.* Laryngoscopy shows flaccidity of the epiglottis, aryepiglottic folds, or the entire larynx, which collapses during inspiration. The nature of the anatomic abnormality causing the supraglottic obstruction of laryngomalacia varies. The majority will have anterior prolapse of the mucosa overlying the arytenoid cartilages, while others will have short aryepiglottic folds that tether the epiglottis posteriorly, posterior collapse of the epiglottis, or some combination of these findings. The primary reasons for laryngoscopy and imaging are to exclude other causes of congenital stridor (e.g. cysts, webs, tumours, and stenosis). In most children, the symptoms disappear by 1 year of age.

*Treatment* consists of careful observation and reassurance of the parents. A small number of these infants seen by a paediatric otolaryngologist will require surgical intervention.

---

### **Vocal fold paralysis**

The stridor is inspiratory or biphasic, with a high-pitched musical quality. Paralysis of the vocal folds in a newborn

may be idiopathic or can result from birth trauma, central or peripheral neurologic diseases, or thoracic diseases or procedures. Approximately 70% of noniatrogenic unilateral vocal fold paralyses will resolve spontaneously, most within the first six months of life.

### **Laryngeal clefts**

Clefts which may extend to the trachea and even to the carina are rare. Interarytenoid clefts develop as a consequence of a lack of development of the interarytenoid and aryepiglottic muscles. Cricoid clefts may be partial or total. Complete clefts, those that involve the trachea, probably develop during separation of the trachea and oesophagus at four to five weeks, as suggested by the frequent association with tracheoesophageal fistulae.

### **Congenital laryngeal web**

This is a rare malformation of a variable degree. Congenital laryngeal webs account for about 5% of congenital anomalies of the larynx. About 75% occur at the glottic level, and the rest are supraglottic or subglottic. It is thought to result from a localised failure of splitting of the epithelial lamina into two walls, most likely early in the foetal period. Stridor is the major presenting clinical feature, but patients can also present with obstructive cyanosis at birth or episodes of apnea. The most severe form of a laryngeal web is total *atresia of the larynx*. Laryngeal atresia can occur at any laryngeal level or combination of levels. Death results in these infants unless a tracheotomy is performed at the time of birth.

---

### **Subglottic stenosis**

*Definition.* In a term newborn this is defined as a cricoid diameter of less than 3.5 mm. The normal subglottic lumen diameter in the full-term neonate is 4.5 to 5.5 mm and in premature babies is about 3.5 mm. A subglottic diameter of 4 mm or less in a full-term neonate is considered to be narrow. Congenital stenosis can present as a membranous and cartilaginous type and is typically the result of malformation of the cricoid cartilage.

*Clinical features.* Symptoms depend on the degree of subglottic narrowing. The stridor of subglottic stenosis may be inspiratory or biphasic and will worsen when the patient is agitated (increased airflow). A mild stenosis may be asymptomatic until an upper respiratory tract infection causes subglottic swelling and the child presents with symptoms consistent with croup.

*Diagnosis.* Direct laryngoscopy and bronchoscopy are needed to fully evaluate subglottic narrowing.

*Treatment.* Mild cases of stenosis are managed conservatively by watchful waiting and regular

follow-up because many children will outgrow the problem. More severe cases requiring airway support may be managed by surgical reconstruction.

### **Subglottic haemangiomas**

*Diagnosis.* These benign vascular lesions are twice as common in females. Benign vascular malformations are characterised by endothelial hyperplasia.

*Clinical features.* Haemangiomas grow rapidly in the first 6 months of life and stabilise for approximately a year, and then they slowly involute and typically are gone by the age of 3 years. *Diagnosis* is made at the time of direct laryngoscopy, with viewing of the subglottic area via a telescope or microscope. A CT or MRI scan can assist in the diagnosis.

*Treatment* is medical (using propranolol, systemic or intralesional corticosteroids) or surgical (CO<sub>2</sub> laser, tracheostomy, open resection).

### **Laryngocele**

*Definition.* Laryngocele refers to a congenital anomalous air sac communicating with the larynx, which may bulge outwards in the neck.

*Clinical features.* Laryngocele can be presented in both adults and children. *Internal laryngoceles* lie within the larynx in the vestibular ventricle. *External laryngoceles* are a prolongation of the ventricle through the thyrohyoid membrane to form a palpable cystic mass in the neck.

*Diagnosis.* The radiographic finding of an air-containing rounded mass in the neck or supraglottic region, sometimes with air–fluid levels, confirms the presence of a laryngocele. Laryngoceles produce intermittent upper airway obstruction and hoarseness because of episodic filling with air. Other symptoms are foreign-body sensation and cough.

*Treatment* is surgical excision using micro-laryngoscopy or through an external approach.

---

**Other congenital laryngeal lesions**, such as laryngeal duplication cysts, saccular cysts, hamartomas, choristomas, and teratomas, can present with similar symptoms and appearance.

---

### **Tracheomalacia**

*Definition.* Tracheomalacia is a weakness of the tracheal wall; deficient cartilage and increased width of the membranous tracheal wall result in less cartilage support. Primary tracheomalacia is a rare congenital deformity of the tracheal rings that can be seen in premature infants, in infants with connective tissue disorders, and in otherwise healthy full-term infants. Secondary tracheomalacia occurs with external compression of the trachea (vascular anomalies, after surgical repair of tracheoesophageal fistula).

*Clinical features.* It may present with or without laryngomalacia. The clinical presentation includes expiratory stridor, wheezing, reflex apnoea, barking cough, hyperextension of the neck. Symptoms can be mild to severe. The condition may resolve as the child grows.

*Diagnosis.* History, type of stridor and physical examination, along with other possible additional studies, flexible or rigid endoscopy is required for an adequate evaluation of the aetiology.

*Treatment.* Tracheotomy with or without continuous positive airway pressure is sometimes required to stent the airway in severe cases.

### **Tracheoesophageal fistula**

*Definition.* Congenital tracheoesophageal fistula is a manifestation of esophageal atresia and should be suspected in the infant who has difficulty with feeding, aspiration, and respiratory distress soon after birth.

*Clinical features.* The main symptoms include aspiration, coughing, apnea, or respiratory distress with feeding.

*Diagnosis.* Oesophageal atresia can be diagnosed by failure to pass a catheter beyond the upper oesophagus or by contrast oesophagography.

*Treatment.* The surgical approach must be individualized on the basis of the severity of the primary and other malformations. Primary repair consists of division of the tracheoesophageal fistula and end-to-end oesophageal anastomosis.

### **Tracheal stenosis**

*Definition.* Tracheal stenosis may result from complete tracheal rings or other cartilage

deformities. In infants and children, tracheal stenosis is frequently a fatal disease process that is often associated with other congenital anomalies and in which definitive means of surgical repair are poorly defined for patients with the most severe disease.

*Diagnosis.* Endoscopic evaluation with a rigid bronchoscope is clearly the most accurate means of diagnosing tracheal stenosis and assessing its length, degree, and character. Diagnosis, evaluation, and development of a logical management plan for a patient with tracheal stenosis are complex.

*Treatment.* Tracheal stenoses can be managed endoscopically, whereas longer stenoses are better corrected through an open approach. The trend over the last decade is for segmental resection and reanastomosis for short-segment stenosis and use of slide tracheoplasty or augmentation of long-segment stenosis.

#### 5.4.2 Laryngeal and tracheal trauma

Traumatic injuries of the larynx are diverse, uncommon, and potentially life-threatening due to airway compromise and/or aspiration. Each laryngeal injury is unique, so the management of each patient is different and can be complex. Speech and language therapy plays a vital role in the recovery and rehabilitation of patients who suffer from laryngeal trauma both in terms of rehabilitation of voice and swallowing.

Laryngeal trauma can be divided into two main groups: **blunt** trauma and **penetrating** trauma. Another entities are iatrogenic injury of the recurrent nerve during neck/thyroid surgery and caustic injury. Management of the latter is connected to the management of oesophageal burns.

Blunt laryngeal trauma most commonly results from road traffic accidents, personal assaults, or sports injuries. Knife, gunshot, and blast injuries account for most cases of penetrating laryngeal trauma. Both blunt and penetrating laryngeal injuries may present along a spectrum of severity ranging from mild to fatal.

The immediate priority in the treatment of laryngeal injuries is to establish and maintain a stable airway.

*Clinical features.* Symptoms are pain or tenderness over the larynx, voice change or hoarseness, odynophagia or dysphagia. Objective signs are dyspnoea, stridor, haemoptysis, ecchymosis of the overlying cervical skin, subcutaneous emphysema, loss of normal thyroid prominence, deviation of the larynx, and loss of laryngeal crepitus — a “click” is generally palpated when the larynx is grasped and moved back and forth over the vertebral column.

#### Principles of management

Once the airway is deemed to be stable, flexible fiberoptic laryngoscopy is a critical step in evaluating the status of the airway after laryngeal trauma. A complete trauma assessment must be performed due to the possibility of concurrent injuries associated with laryngeal trauma.

Chest radiograph is often helpful to rule out a pneumothorax, tracheal deviation, or pneumomediastinum. CT scans are helpful in diagnosing laryngeal fractures and aid in operative planning for the repair and reconstruction of the fractured larynx. Several aspects of laryngeal trauma need to be taken into consideration.

- **Inhalation injury**  
Since inhalation injuries may occur without skin burns or other external injuries, a high index of suspicion must be maintained. The upper aerodigestive tract should be evaluated serially with flexible laryngoscopy to follow the evolution of the injury. If acute upper airway obstruction is impending or imminent, the most experienced clinician in airway management should intubate the patient and secure the airway.
- **Endolaryngeal tears**  
Tracheotomy placement will generally be necessary to adequately access and repair significant mucosal tears. Even minor lacerations that involve the true vocal cord margin or anterior commissure should be closed. All exposed cartilage should be covered either primarily or with local mucosal advancement flaps.
- **Endolaryngeal oedema**  
Patients with significant laryngeal oedema, particularly if it appears to be progressing, should undergo awake tracheotomy to prevent airway loss. Adjunctive measures, such as elevation of the head-of-bed, corticosteroids, anti-reflux medications, and humidification, should be implemented.
- **Endolaryngeal haematomas**  
Small, nonprogressing haematomas with intact mucosal coverage are likely to resolve spontaneously without



significant sequelae. Adjunctive therapies, such as steroids, anti-reflux medication, humidification, and elevation of the head-of-bed, are helpful. Large or expanding haematomas may lead to airway obstruction and necessitate placement of a tracheostomy.

- Injury to the recurrent laryngeal nerve  
Injury to the recurrent laryngeal nerve may occur after both blunt and penetrating laryngeal injury. Injury to the recurrent laryngeal nerve after blunt laryngeal trauma may be due either to stretching of the nerve or nerve compression near the cricoarytenoid joint. If a vocal cord is persistently immobile after blunt trauma, the vocal fold should be observed for as long as six months to await the possible spontaneous regeneration of recurrent laryngeal nerve function. If a recurrent laryngeal nerve is severed, primary repair might be attempted in order to prevent muscle atrophy however, no return of function should be expected.
- Laryngeal fractures  
Nondisplaced laryngeal fractures may be observed. Displaced thyroid and cricoid cartilage fractures should be reduced and fixed to stabilize the laryngeal framework. Miniplate fixation of cartilage fractures is superior to suture fixation. Stents may be placed if the anterior commissure is significantly injured or if there are multiple, severe endolaryngeal lacerations.

#### Tracheobronchial tree trauma

This is mostly result of stab, gunshot or traffic accident.

*Clinical features.* The symptoms are variable and include dyspnoea, haemoptysis, subcutaneous and mediastinal emphysema, inspiratory stridor, hoarseness, coughing, localized pain or tenderness, and, in severe cases, cyanosis. Significant injury can occur with minimal evidence of trauma.

*Diagnostics* Diagnosis is made by auscultation, radiographic signs (pneumomediastinum, deep cervical emphysema, subcutaneous emphysema, pneumothorax, fractures limited to the upper rib cage, air surrounding a bronchus, and obstruction in the course of an air-filled bronchus) and bronchoscopy to establish the site, nature, and extent of bronchial disruption. Tracheobronchial trauma can occur at every level of the trachea and almost all of the major bronchi, but more than 80% of the injuries are within 2.5 cm of the carina. Tracheobronchial disruption has an estimated overall mortality of 30%. Thoracotomy and repair are indicated as soon as the patient's condition permits.

### 5.4.3 Inflammatory diseases

#### Acute laryngitis

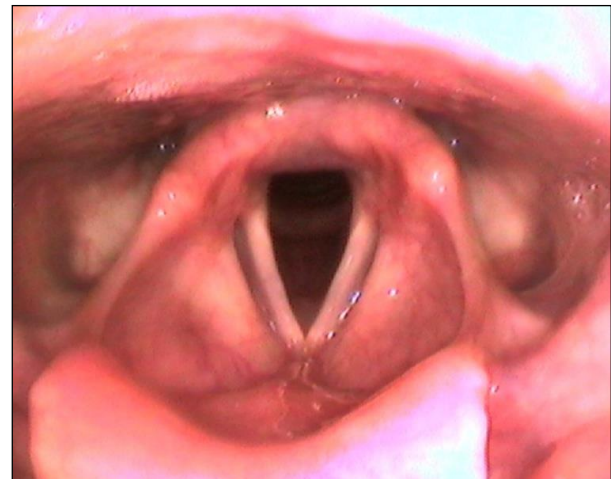
*Definition.* Acute laryngitis is an inflammatory process of the larynx, which can affect mucosa

(superficial type) or deeper laryngeal structures (muscle, cartilage).

An inflammatory process affecting deep laryngeal structures carries the risk of airway obstruction and is considered to be an airway emergency (perichondritis, epiglottitis).

*Clinical features.* Hoarseness, aphonia, pain in the larynx, and coughing attacks are the main symptoms of acute laryngitis. In children, there is a danger of airway obstruction. Acute laryngitis is usually due to ascending or descending viral infections from other parts of the airway. The cause is viral or, rarely, bacterial infection.

*Diagnosis.* Laryngoscopy reveals oedematous and erythematous vocal folds. Depending on the underlying disease, the neighbouring pharyngeal or tracheal mucosa may also be inflamed (Figure 5.13).



**Figure 5.13**  
Acute laryngitis

*Treatment.* General measures include steam inhalation, analgesia, and sufficient oral intake of fluids. Steroids are indicated for marked oedema. Acute laryngitis is mainly due to viral infections, so antibiotics should not be given unless bacterial infection is confirmed by a smear test with microbiological culture and susceptibility testing.



Voice rest is indicated, and smoking should be forbidden.

If the symptoms do not improve considerably or resolve within 3 weeks, endoscopy should be used to identify suspicious findings. Specific diseases, premalignant lesions, and tumours must be excluded by biopsy using microlaryngoscopy.

### Croup syndromes

Diphtheritic croup, beginning with laryngeal membranes and obstruction, is rarely observed these days in the Western world. Diphtheria still appears in regions where vaccination is not mandatory. Diphtheritic laryngitis with greyish-white membranes, occurring as an isolated condition, is also rare. It is usually combined with oropharyngeal lesions. Tracheostomy is required for increasing dyspnoea.

The term "pseudocroup" includes a group of acute laryngo-tracheal diseases mainly affecting children.

### Acute subglottic laryngitis (laryngotracheitis) in children

*Definition.* A dry, barking cough following an upper respiratory tract infection that rapidly becomes worse.

*Clinical features.* Hoarseness, inspiratory, expiratory or mixed stridor, retraction of the suprasternal notch and of the intercostal spaces during inspiration, and cyanosis. The severity of respiratory obstruction depends on the degree of mucosal swelling in the subglottis. Worsening symptoms in children lead to concern due to potential airway obstruction.

*Aetiology and pathogenesis.* This is a serious acute disease of early infancy, most commonly between the ages of 1 and 5 years. Within a short time, life-threatening narrowing of the child's airway can develop due to inflammatory mucosal swelling of the elastic cone in the subglottic space. The disease is caused by viral infection with accompanying secondary bacterial infection. Cool, damp, and foggy weather in fall and winter appear to increase the morbidity. However, recurrent infections in the nasopharynx and nasal obstruction due to chronically inflamed hyper-trophied adenoids and tonsils are important aetiological factors.

*Diagnosis.* The clinical picture is usually very typical. Laryngoscopy reveals glottal mucosal oedema and redness, potentially with crust formation.

*Treatment.* Mild cases, assessed by the degree of respiratory obstruction, can be managed in an outpatient setting. The efficacy of antibiotic and steroid treatment needs to be closely monitored. If treatment fails and dyspnoea increases, the child must be admitted to hospital urgently on an emergency basis for treatment with oxygen therapy and standby for an endotracheal intubation, depending on the degree of dyspnoea and the results of blood gas analysis (oxygen saturation, partial pressure of carbon dioxide). Tracheostomy is carried out when there is severe obstruction and progressive formation of the crust.

### Acute epiglottitis

*Definition.* Acute epiglottitis is essentially laryngeal supraglottitis.

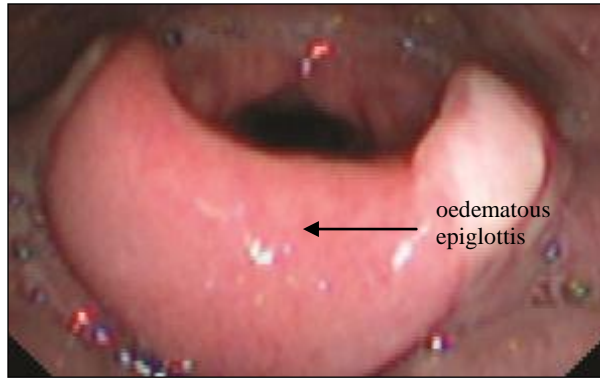
*Clinical features and pathogenesis.* There is a classic presentation with the clinical triad of drooling, dysphagia, and distress. Severe pain during swallowing and refusal of food and liquid intake may lead to dehydration and potential circulatory collapse. Inspiratory stridor usually forces the patient to sit upright in bed with the nose pointing upwards in a "sniffing the morning air position". Speech is muffled ("hot potato speech") and temperature is elevated. The main cause is infection with haemophilus influenzae. The disease can also be caused by mucosal damage resulting from swallowing sharp-edged food, allowing pathogenic organisms to enter.

Acute epiglottitis is a life-threatening disease with a mortality of up to 20% if not treated.

*Diagnosis.* Laryngoscopy or examination with a tongue depressor shows a thick, swollen, red epiglottic rim (Figure 5.14).

*Treatment.* The patient should be immediately admitted to hospital if a diagnosis of epiglottitis is suspected. If respiratory arrest occurs, the airway is secured by intubation but tracheostomy might be

required (see Chapter 10.15). Intravenous antibiotics (with second-generation or third-generation cephalosporins) at high doses and steroids are given. With these measures the disease usually improves rapidly within a few days.



**Figure 5.14**  
Epiglottitis

Diagnostic procedures may lead to complete airway obstruction in patients with partial respiratory obstruction, particularly in children. Preparations must therefore be made for intubation or tracheostomy before the examination.

### Bacterial tracheitis in children

**Definition.** Bacterial tracheitis (bacterial laryngo-tracheobronchitis, pseudomembranous croup, or membranous laryngotracheobronchitis) is a rare acute infection of the upper airway that does not involve the epiglottis but can cause life-threatening sudden airway obstruction, particularly in children. The infectious inflammatory process involves the subglottis and trachea with marked edema in the subglottis as in those with viral croup. Diffuse mucosal ulceration and pseudo-membrane formation follow, with sloughing of these membranes into the tracheal lumen further contributing to airway obstruction.

**Clinical features.** Patients, generally less than 3 years of age, develop a brassy cough, high fever, worsening inspiratory stridor. The diagnosis may be suspected on the basis of signs and symptoms, but it is confirmed by endoscopic examination of

the airway. The most commonly isolated pathogens are *Staphylococcus aureus*, *Moraxella catarrhalis* and *H. influenzae*.

**Treatment.** The majority of patients (up to 80%) with bacterial tracheitis will require intubation and ventilatory support, parenteral antimicrobial therapy is indicated.

### Laryngeal perichondritis

**Definition.** This is an inflammatory disease of the laryngeal cartilage.

**Clinical features.** Presents as severe pain in the larynx, and increases on swallowing or with external pressure, hoarseness, and dyspnoea.

**Pathogenesis.** Surgical (laser) and accidental trauma, infiltration of cartilage by tumour, infection (tuberculosis) and radiation. If the cartilage is not invaded by a tumour, it usually tolerates radiation up to 60 Gy. The difficult clinical problem is chondroradionecrosis, with inflammation of the overlying mucosa.

**Diagnosis.** A laryngoscopic picture of pallid mucosal oedema, particularly on the epiglottis and the arytenoid cartilages, is very typical along with the history. Intralaryngeal and extralaryngeal oedema, fistulas, and sequestration of necrotic pieces of cartilage can be seen.

**Treatment.** Sequestered or exposed cartilage must be removed. Broad-spectrum antibiotics are given in high doses, combined with steroids.

### Chronic nonspecific laryngitis

**Definition.** This is laryngitis caused by a recurrent irritation, or following acute laryngitis.

**Symptoms** persist for weeks or months, in contrast to those of acute laryngitis. They include hoarseness, a deeper voice, and sometimes a dry cough. The voice is less robust and there is a globus sensation in the larynx and a feeling of needing to clear the throat, but little or no pain.

**Pathogenesis.** This disease is mainly due to exogenous toxins such as cigarette smoking, occupational air pollution, and climatic influences. Another cause is vocal overuse in bartenders, construction workers, call centre agents, and other professional speakers. Nasal obstruction may also be a factor in the pathogenesis. An important

cause of chronic laryngitis is also untreated **laryngopharyngeal reflux**.

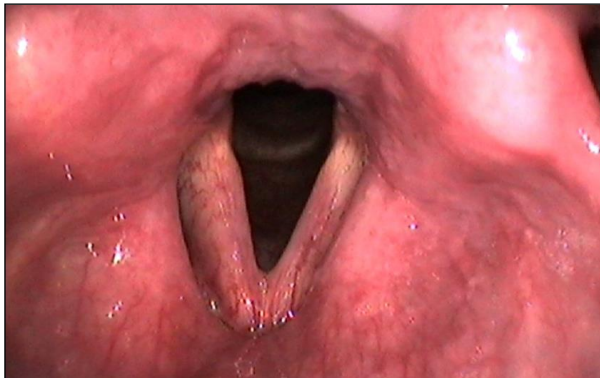
#### **Hormonally induced laryngitis**

Laryngopathia gravidarum, due to vocal fold oedema with dysphonia and deepening of the voice, is sometimes observed in the second half of pregnancy. The hoarseness almost always resolves spontaneously after delivery.

#### **Laryngopharyngeal reflux**

Laryngopharyngeal reflux (LPR) is defined as the retrograde flow of stomach content to the larynx and pharynx. LPR has been implicated in the etiology of many diseases such as chronic cough, dysphagia, postnasal drip, subglottic stenosis, laryngeal granuloma or vocal fold nodules..

*Diagnosis.* Laryngoscopy reveals oedematous and erythematous vocal folds with rough edges (Figure 5.15). There is tenacious mucus, and the rest of the laryngeal mucosa often looks similar. Microlaryngoscopy should always be performed, and biopsy should be performed to exclude malignancy.



**Figure 5.15**  
Chronic laryngitis

*Differential diagnosis.* Chronic nonspecific laryngitis must to be distinguished from the group of specific forms such as tuberculosis, granulomatosis with polyangiitis (Wegener granulomatosis) and amyloidosis.

*Treatment.* Eliminating exogenous toxins such as tobacco is the mainstay of treatment. Voice rest can be useful for a few days in case of acute exacerbations, and if necessary, normal nasal respiration should be restored (septoplasty, removal of nasal polyps). Antibiotics are not administered

unless pathogenic bacteria are identified in a smear test with microbiological culture and susceptibility testing. Steroids, saline inhalations, and mucolytic agents may be useful. Laryngopharyngeal reflux needs to be treated with proton pump inhibitors for at least 3 months. If the epithelial changes do not resolve, a biopsy should be performed to exclude malignant transformation. The epithelium must not be completely removed, as in cases of cancer. As long as there is no malignancy, the patient must be closely observed.

Regular laryngoscopic follow-up examinations are advisable in patients with chronic laryngitis, because of the possibility of the development of dysplasia particularly in patients who continue to smoke. Microlaryngoscopy and biopsy should be performed in all suspicious cases.

#### **Specific forms of chronic laryngitis**

**Laryngeal tuberculosis** is almost always secondary to active pulmonary tuberculosis. The infection is transmitted to the larynx by bacilli contained in the sputum. The posterior part of the larynx, interarytenoid area, and epiglottis are the most commonly affected. In fresh cases, microlaryngoscopy initially shows reddish-brown submucous nodules, which are partly confluent. Later, there are ulcerations or granulations. Other investigations include histology, culture, radiography, and examination by an internal medicine specialist.

**Laryngeal sarcoid** is rare as an extrapulmonary manifestation. Dysphonia and a globus sensation are caused by sarcoid deposits in the larynx. Biopsy of the larynx combined with prescalene node biopsy is necessary to establish the diagnosis. The disease is treated by an internal medicine specialist.

**Laryngeal syphilis** as an isolated disease is unusual, and it is much more often a manifestation of oropharyngeal syphilis in the secondary generalised stage of the disease. Mucous plaques or hazy, smoke-coloured mucosal lesions occur in the larynx. The patient is also hoarse. This is a notifiable disease. Respiratory obstruction only occurs in the presence of marked mucosal swelling. The laryngeal cartilages are destroyed in a gumma in the tertiary stage. Differential diagnosis from carcinoma is difficult.

**Scleroma of the larynx.** Pale-red swellings and granulations with crusts develop, mainly in the subglottic space. Subglottic, laryngeal, and intratracheal stenoses occur in stage III of the disease, causing hoarseness, cough, and increasing stridor. Scleroma is diagnosed by microlaryngoscopy, histopathology, and culture (*Klebsiella rhinoscleromatis*). Tracheotomy, followed by appropriate surgical treatment of laryngotracheal stenosis, is necessary in managing respiratory stridor.

**Pemphigus vulgaris and pemphigoid vesicles.** These conditions preferentially affect the epiglottis and are often incidental findings. The vesicles are usually painless, but may occasionally cause a globus sensation and lead to stenosis due to extensive scarring (which may also affect the adjacent pharynx). Paraneoplastic symptoms may be present. Treatment is directed towards the underlying disease.

**Generalised rheumatoid arthritis.** The cricoarytenoid joint is often affected, causing hoarseness, stridor, and pain, radiating to the ear, on swallowing.

**Amyloid** in the head and neck most often causes macroglossia. Laryngotracheal amyloid is the next most common finding. It is usually isolated and is very rarely associated with other systemic diseases. Tumour like, polypoid lesions covered with smooth mucosa, with a pale and waxy appearance, may develop in the larynx in this form of dysproteinaemia. The sites of predilection are the vocal folds and the subglottic space. Surgical removal is required for severe hoarseness and respiratory obstruction.

## 5.4.4 Benign and malignant tumours

### 5.4.4.1 Benign lesions

#### **Vocal fold polyp**

*Definition.* Polyps are fluid-filled collections that form on the edge of a vocal cord.

*Clinical features.* Polyps usually present with hoarseness, dys/aphonia, and attacks of coughing. If the polyp has a pedicle and is floating between the folds, the voice may return to normal for short intervals.

*Pathogenesis.* This is the most common benign tumour of the vocal folds, mainly affecting men between 30 and 50 years of age. It is often initiated by agents that cause laryngeal inflammation. Hyper-kinetic voice disorders and vocal overuse are important factors.

*Diagnosis.* Laryngoscopy shows the polyp usually lying on the free edge of the vocal fold, either on a pedicle or sessile. It is oedematous and occasionally haemorrhagic. Older polyps appear firm, due to fibrosis and thickening of the overlying epithelium.

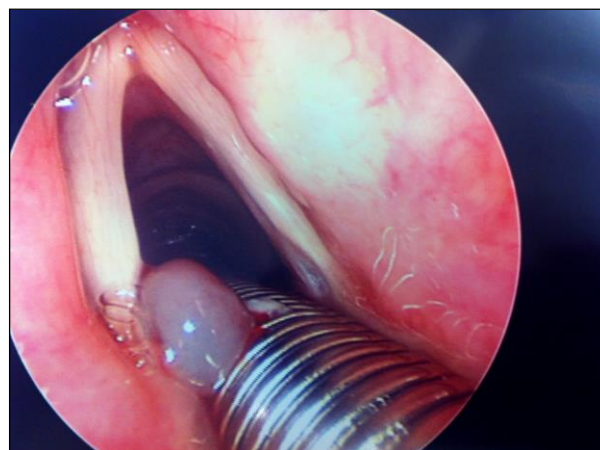
*Treatment.* The polyp is removed by endolaryngeal microsurgery, with preservation of the lamina propria. The patient is advised to rest the voice for approximately 3 days. The defect epithelialises more rapidly when the voice is resting.

#### **Contact granuloma**

*Definition.* This is a benign lesion usually located on the posterior third of the vocal cord in the area of vocal process of the arytenoid cartilage.

*Clinical features and pathogenesis.* Contact granulomas are thought to be the result of voice misuse, intubation injury or reflux. Specific granulomas are rare and could be caused by tuberculosis or syphilis.

*Diagnosis.* Symptoms include hoarseness, cough and frequent throat clearing. There is often recent history of airway intubation or reflux disease. Laryngoscopy reveals typical lesion which can be unilateral or bilateral. (Figure 5.16)



**Figure 5.16**

Contact granuloma

*Treatment.* Conservative treatment includes antireflux treatment and the cough prevention. Speech therapy is helpful. Unresponsive cases can benefit from botulotoxin injections and/or surgical removal of the lesion, unfortunately there is high recurrence rate after surgery (up to 50%).

#### **Reinke's oedema**

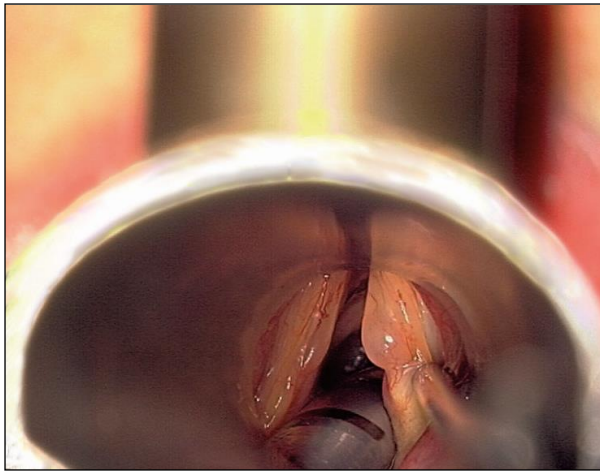
*Definition.* Reinke's oedema is a pathologic condition of the vocal fold that involves an accumulation of a gelatinous type of fluid throughout the superficial aspect of the lamina propria. In contrast to most other benign laryngeal lesions, polypoid corditis is a global, as opposed to focal, process of the vocal folds.



*Clinical features* include hoarseness and deepening of the voice. Stridor may occur, particularly on exertion, if the oedema is marked.

*Pathogenesis.* The oedema is almost always bilateral and broad-based. The oedema usually affects women over the age of 40 years who are heavy smokers and frequent voice users.

*Diagnosis.* Laryngoscopy shows a bilateral broad-based oedematous mass on the vocal folds (Figure 5.17).

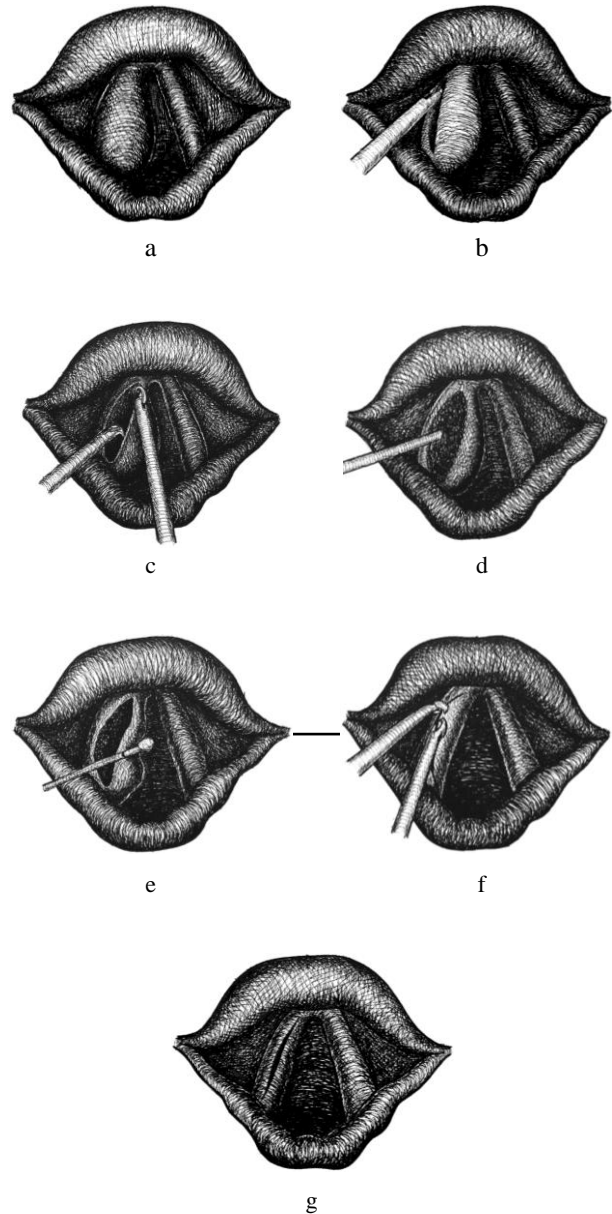


**Figure 5.17**

Reinke's oedema on the right side, partially retracted with instrument

*Treatment.* The epithelium covering the oedema has no definite border separating it from the surrounding normal epithelium. On the cranial surface, the incision, or a narrow excision of epithelium, follows the arcuate line laterally. The myxoid acellular substance of the lamina propria is aspirated with a small suction or pressed out. Redundant epithelium is trimmed and the epithelium is redraped so that the edges are adjacent (Figure 5.18). The epithelium must not be excised or stripped, as was advocated in the past.

Various microflap techniques and the limited use of the CO<sub>2</sub> laser are considered in the surgical treatment of Reinke's oedema. Treatment of laryngopharyngeal reflux is also helpful.



**Figure 5.18**

Surgical treatment of Reinke's oedema

### Recurrent respiratory papillomatosis

*Definition.* Recurrent respiratory papillomatosis is a benign disease presenting with wart-like growths in upper airway which is caused by the human papillomavirus (HPV).

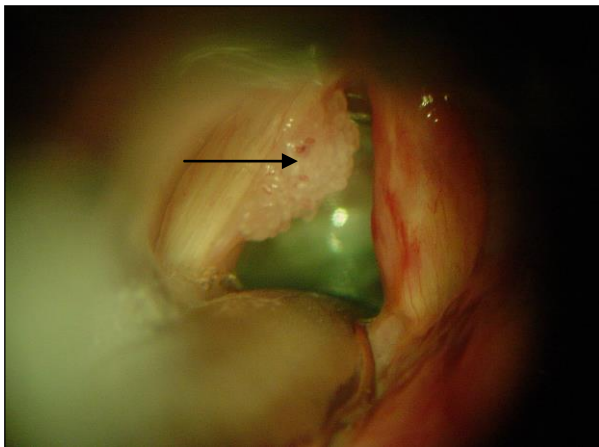
*Clinical features.* Hoarseness, often severe, and respiratory obstruction, depending on the site and extent of the lesions.



**Pathogenesis.** During normal vaginal delivery, infants may be infected through exposure of the aerodigestive tract to the cervix and vagina of a mother with genital HPV infection. Papillomas in adults may have persisted since early childhood. The course of the disease is unpredictable.

**Diagnosis.** This is established by direct laryngoscopy and histologic examination. Papillomas may be pedicled, solitary, or widespread (Figure 5.19). Their surface is pale-yellow to red, granular, villous, and often has a raspberry appearance.

**Treatment.** Spontaneous regression rarely occurs. There is currently no alternative to surgery. Removal of papillomas during microlaryngoscopy can be achieved with microlaryngeal dissection with the use of a CO<sub>2</sub> laser and/or microdebrider. In severe cases, local injection of an antiviral agent such as cidofovir or topical application of chemotherapeutic agent mitomycin C is used to try to prevent recurrence. Tracheotomy should be avoided if possible as it may lead to the disease progressing to the trachea or bronchi.



**Figure 5.19**  
Laryngeal papilloma

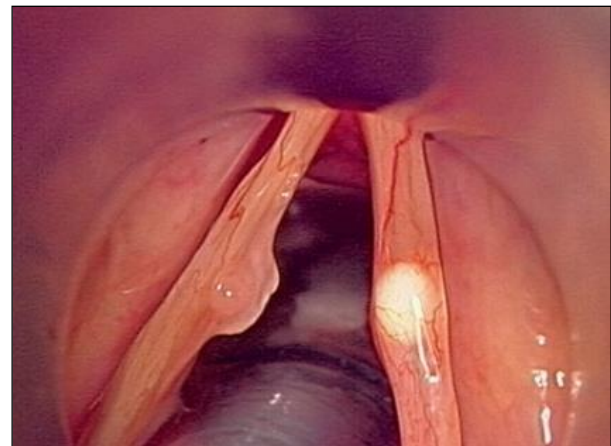
Children often require surgical excision of papillomas as often as every 2–4 weeks. Progression of a papilloma to squamous cell carcinoma is rare but can occur (<5% of cases).

### Retention cyst

**Definition.** Cysts are benign lesions derived from mucous glands.

**Clinical features.** Retention cysts present as glazed, white, or occasionally blue masses. They are localised to the vestibular fold, ventricle, epiglottis (Figure 5.20), aryepiglottic folds, and valleculae. Small cysts are sometimes found incidentally; larger cysts can cause a globus sensation, dysphonia, and dyspnoea.

**Treatment.** Removal using microsurgery with cold instruments or a CO<sub>2</sub> laser.



**Figure 5.20**  
Retention cyst on the right vocal cord, polyp  
on the left vocal cord

### Chondroma

**Definition.** A chondroma is an encapsulated benign cartilaginous tumour with a lobular growth pattern.

**Clinical features** are hoarseness, dyspnoea, dysphagia, or globus sensation, depending on the site. The tumours grow slowly and often arise from the cricoid cartilage.

**Pathogenesis.** Tumour cells (chondrocytes) resemble normal cells and produce the cartilaginous matrix, which is amorphous, basophilic material.

**Diagnosis.** Laryngoscopy usually shows a subglottic tumour covered with smooth mucosa. The tumour is sometimes palpable externally. CT demonstrates the site and extent of the tumour.

*Treatment.* Surgical resection, as chondromas are radio-resistant.

#### 5.4.4.2 Premalignant lesions of the larynx (leukoplakia, dysplasia, carcinoma in situ)

*Definition.* Leukoplakia is a clinical term that includes lesions of different histologic grades. A leukoplakic lesion may signify a premalignant or malignant process and, therefore, requires histologic examination. Histomorphologic definitions of the grades of dysplasia help to eliminate ambiguous terminology and facilitate prognostic assessment (Table 5.1).

**Table 5.1** Grading of laryngeal dysplasia

<b>Grade I</b>	Simple dysplasia	epithelial hyperplasia without nuclear atypia, without disturbances of maturation or stratification of the squamous epithelium	clinically benign
<b>Grade II</b>	Middle-grade dysplasia	epithelial dysplasia with basal cell hyperplasia, loss of basal cell polarity, moderate cell polymorphism, a slightly increased mitotic rate, occasional dyskeratosis	pre-malignant lesion
<b>Grade III</b>	High-grade dysplasia	basal cell hyperplasia, loss of basal cell polarity, cell polymorphism, increased mitotic rate, numerous dyskeratosis, abnormalities of epithelial stratification	intensification (loss of epithelial stratification, but no invasion of the stroma) leads to carcinoma in situ

Squamous cell carcinoma of the larynx arises on the basis of premalignant changes lasting various periods of time.

*Clinical features.* Hoarseness, a foreign-body sensation in the throat, and a need to clear the throat.

*Pathogenesis.* Exogenous toxins such as smoking, radiation, and working environment.

Premalignant lesions of the larynx can develop from chronic laryngitis and, if untreated, can transform into laryngeal carcinoma.

*Diagnosis.* Microlaryngoscopy reveals rough, thickened mucosa in the larynx or vocal folds, occasionally deepened by scar tissue and altered in colour. Biopsy confirms the diagnosis.

*Treatment.* The histologic classification determines the type and extent of treatment. Obvious aetiological agents should be eliminated. Lesions confined to the vocal folds are treated with subepithelial cordectomy via microlaryngoscopy. These procedures might be performed with the laser.

#### 5.4.4.3 Carcinoma of the larynx

*Epidemiology.* Carcinoma of the larynx accounts for approximately 40% of carcinomas of the head and neck. It is most common between the ages of 45 and 75 years. Men are affected 10 times more frequently than women.

*Clinical features.* Hoarseness is the first and main symptom when the cancer affects the glottis. Further symptoms, which may occur alone or in combination depending on the site and extent, include a foreign-body sensation, clearing the throat, pain in the throat or referred to the ears, dyspnoea, dysphagia, cough, and haemoptysis. Metastases to regional lymph nodes may also occur.

Hoarseness persisting for more than 2–3 weeks and not cleared by the antibiotics must always be investigated by an otolaryngologist.

*Pathogenesis.* Invasive carcinoma may develop from epithelial dysplasia, particularly carcinoma in situ. More than 90% of laryngeal carcinomas are keratinising or nonkeratinising squamous cell carcinomas (other forms are verrucous carcinoma, adenocarcinoma, carcinosarcoma, fibrosarcoma, and chondrosarcoma). Other non-carcinoma laryngeal tumours are rare (e.g. malignant

melanoma). Most patients with squamous carcinoma of the larynx were or are heavy cigarette smokers and, in addition, often heavy drinkers. Chronic exposure to irritation with heavy metals such as chromium, nickel, and uranium, or asbestos exposure and radiation exposure, are an implicated but unproven aetiology.

#### Spread patterns of laryngeal cancer

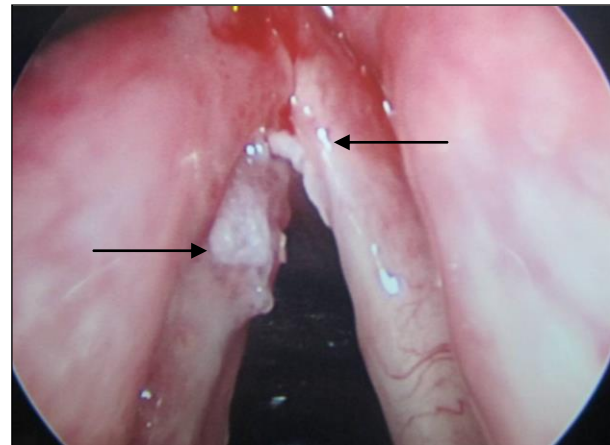
Laryngeal carcinoma infiltrates locally into the mucosa and beneath the mucosa and metastasises via the lymphatics and the bloodstream. The limits of vascular spread are embryologically determined. *Supraglottic carcinomas* therefore usually remain confined to the supraglottic space and spread anteriorly into the preepiglottic space. *Glottic carcinomas* spread into the subglottic space, rather than into the supraglottic region. *Transglottic carcinoma* is a glottic carcinoma involving the ventricle and the vestibular folds. The site of origin cannot be recognised.

The characteristics of the intralaryngeal lymphatics influence the frequency of regional lymph node metastases. Other factors influencing the frequency of metastases are the duration of symptoms, histologic differentiation, and the size and site of the cancer. Lymph node metastases are rare at the time of presentation in patients with carcinomas of the vocal fold, but are found in  $\approx 20\%$  of subglottic carcinomas,  $\approx 40\%$  of supraglottic carcinomas, and  $\approx 40\%$  of transglottic carcinomas. Contralateral metastases are unusual in unilateral glottic cancers. Bilateral metastases become more common if the carcinoma crosses the midline, at the anterior or posterior commissure or in the trachea, or if the cancer arises primarily in the supraglottic space.

Distant haematogenous metastases are relatively unusual in carcinoma of the larynx when the patient is seen for the first time.

Second primary carcinomas of the respiratory and digestive tracts (synchronous or metachronous) occur in 15–20% of cases. The lungs are the most frequent site.

**Diagnosis.** The clinical diagnosis is initially based on the findings of indirect laryngoscopy, video laryngoscopy, and stroboscopy (Figure 5.21). The site and extent of the tumour and the mobility of the vocal fold have to be assessed — TNM classification is used (see Appendix). Micro-laryngoscopy allows accurate evaluation of the site and extent of the tumour, provides a view of hidden angles such as the ventricle and the piriform sinus, and facilitates assessment of superficial characteristics of the tumour, such as nodular, exophytic, granulomatous, or ulcerating. CT and MRI are used to assess the depth of involvement.



**Figure 5.21**

Laryngeal cancer, T1b glottis

**Differential diagnosis.** Chronic laryngitis and its specific forms, and benign laryngeal tumours.

**Treatment.** If untreated, carcinoma of the larynx leads to death within an average of 12 months due to asphyxia, bleeding, metastases, infection, or cachexia. Patients are treated on an individual basis following presentation and discussion at a multidisciplinary team meeting. The indications for radiotherapy, chemoradiotherapy or surgery for carcinoma of the larynx vary depending on the site and stage of the cancer. Treatment options might be used in combination.

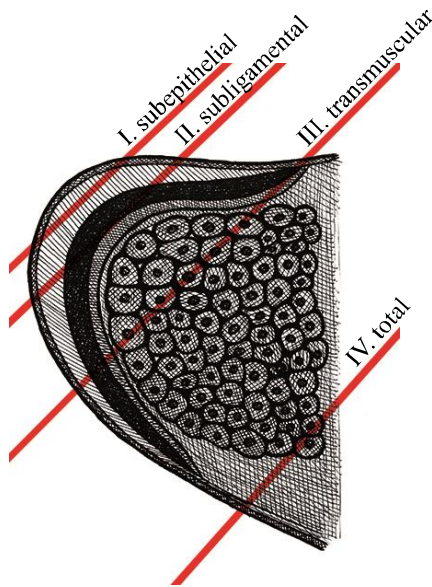
#### Treatment of laryngeal cancer

*Chemotherapy* alone has so far been proven to be ineffective with laryngeal cancer, but it is often combined with radiotherapy. Early cancers (T1, T2) are treated equally successfully with *CO<sub>2</sub> laser resection* or *radiotherapy*. More advanced cancers (T2, T3) can be surgically treated with *partial or total laryngectomy* with or without neck dissection, or, alternatively, with *chemoradiotherapy*. T4 tumours with cartilage invasion are treated with total laryngectomy. Multimodal treatment with surgery and postoperative chemoradiotherapy appears to yield the best results for selected patients in advanced stages.

#### Surgical procedures for cancer of the larynx

In selected cases, cordectomy can be carried out using *endoscopic laser surgery*, with good oncological and functional (voice) outcomes. The European Laryngological Society has published a proposed classification of endoscopic chordectomies — Type I: subepithelial, II: subligamental, III: transmuscular, IV: total or complete, Va–d: extended, which can encompass the contralateral vocal fold, the (still mobile) arytenoid cartilage, the ventricular fold, or the subglottis as

deep as 1 cm under the glottis, VI: cordectomy of the anterior commissure is an anterior commissuromy with bilateral anterior cordectomy. (Figure 5.22)



**Figure 5.22**

Types of endoscopic chordectomy

Vertical or horizontal partial laryngectomy is used for carcinomas for which a cordectomy is not suitable because of the extent or site of the cancer, but for which total laryngectomy is not necessary. Partial laryngectomies preserve vocal function and a normal airway. The prerequisites for success are careful assessment and good surgical judgment to ensure that the cancer is completely removed.

*Vertical partial laryngectomy.* Several methods are available, but the principle common to all of them is that a wide vertical segment of the thyroid cartilage, and occasionally the cricoid cartilage, is removed (together with the laryngeal soft tissues and the cancer). A hemilaryngectomy, removal of half of the larynx, can be performed for a cancer limited strictly to one side.

*Horizontal partial laryngectomy.* The supraglottic space is completely removed, with retention of the vocal folds and the arytenoid cartilage.

After a partial resection, the functional results are good and the airway is normal, as is vocal function, but the latter depends on the type of resection, the results of which are variable. The patient may have temporary difficulty in swallowing, which may persist in elderly patients. There is a danger of recurrence at the excisional margins if the tumour was incorrectly evaluated preoperatively or if the technique is inadequate.

*Total laryngectomy (TL)* is indicated for cancers that cannot be removed using cordectomy or partial laryngectomy and for cancers that have spread to neighbouring structures, such as

the tongue, hypopharynx, thyroid gland, and trachea. TL is also indicated for cancers that have recurred after radiotherapy or partial procedures.

The entire larynx is removed from the base of the tongue to the trachea, with removal of parts of the tongue, pharynx, trachea, and thyroid gland if necessary. After this operation, the patient can only breathe through the tracheal stoma. Swallowing is almost normal once the wound has healed.

*Supracricoid partial laryngectomy (SCPL)* is an alternative to total laryngectomy. SCPL has the advantages of preservation of speech and swallowing function without a permanent stoma.

The true and false cords, both paraglottic spaces, and the entire thyroid cartilage are resected in the SCPL, which is used to treat selected glottic carcinomas. The reconstruction requires suturing the cricoid to the hyoid and the epiglottis, termed a cricothyroidoepiglottopexy. If the preepiglottic space and the epiglottis are resected in addition to the above, the reconstruction is accomplished by suturing the cricoid to the hyoid, termed a cricothyroidopexy.

Neck dissection. Removal of the primary cancer using partial or total laryngectomy should be combined with neck dissection if lymph node metastases are present. If there is a known high risk of lymphatic metastases for a cancer at a particular site, such as the supraglottic larynx a selective neck dissection — even if lymph node metastases cannot be palpated — might be indicated.

## REHABILITATION OF THE PATIENT AFTER TOTAL LARYNGECTOMY

### Voice and speech

There are three ways to maintain speech after laryngectomy: *oesophageal speech*, *artificial larynx* and the *tracheoesophageal puncture* with the insertion of a speaking valve. In the latter choice an opening is made between the trachea and oesophagus at the time of laryngectomy (primary puncture) or at the later stage (secondary puncture) (see Chapter 9.6).

### Permanent tracheostomy

As breathing is only possible via the tracheostomy, aspiration of water during showering, bathing, and swimming should be prevented by special accessories such as a stoma cover or a snorkel. Once the tracheostomy has stabilised, it is usually unnecessary to use a



tracheostomy tube. There might be a tendency for tracheitis with crusts to develop, particularly in the spring and autumn, because of the absence of the air-conditioning mechanism provided by the nose.

### Social reintegration

Patients and their relatives need thorough instruction before the operation about future functional deficits. Medical and psychological training is necessary after the operation.

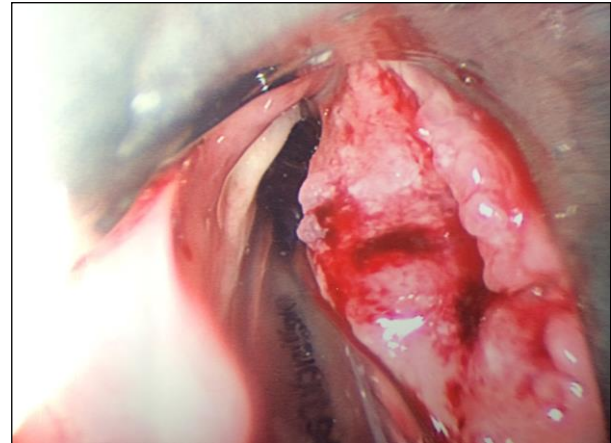
#### 5.4.4.4 Carcinoma of the hypopharynx

Hypopharyngeal anatomy and pathology are covered in Chapter 3. However, the pathogenesis, diagnostics and treatment of hypopharyngeal carcinoma are similar to laryngeal cancer, so we take the liberty of covering these topics in this chapter.

*Clinical features.* In more than 40% of cases, the patient's first presentation is lymph node metastasis to the neck. The patient also complains of nonspecific dysphagia and pain radiating to the ear. Hoarseness and dyspnoea indicate that the cancer has extended to the larynx or paralysed the recurrent laryngeal nerve. Oral foetor (degenerating cancer) and blood-stained sputum may also be present.

*Pathogenesis and epidemiology.* Alcohol and nicotine abuse are predisposing factors in the development of hypopharyngeal squamous cell carcinoma. The ratio of men to women is estimated at 3:1. Carcinoma in the postcricoid region occurs more frequently in women. About 50% of patients have T3 N1–2 tumours when first seen (TNM classification – see Appendix). Distant metastases to the lung, liver, and skeleton are found at the time of diagnosis in 10% of cases, and at autopsy in as many as 80% of patients. Virtually all of the cancers are poorly differentiated squamous cell carcinomas. With regard to the order of frequency of various sites of hypopharyngeal carcinoma, cancers in the piriform recess are the most common, followed by lesions in the posterior pharyngeal wall. Postcricoid cancers are rare.

*Diagnosis.* Early symptoms involving difficult swallowing and cervical lymph node metastases are often neglected, so the diagnosis is delayed. Endoscopic examination should always be carried out when a hypopharyngeal carcinoma is suspected. The cancer may be ulcerated or exophytic in type, and it is often surrounded by oedema and covered with retained saliva and food particles (Figure 5.23).



**Figure 5.23**

Hypopharyngeal cancer growing into right side of laryngeal inlet

Cervical lymph node metastases with an unknown primary cancer require thorough examination of the hypopharynx.

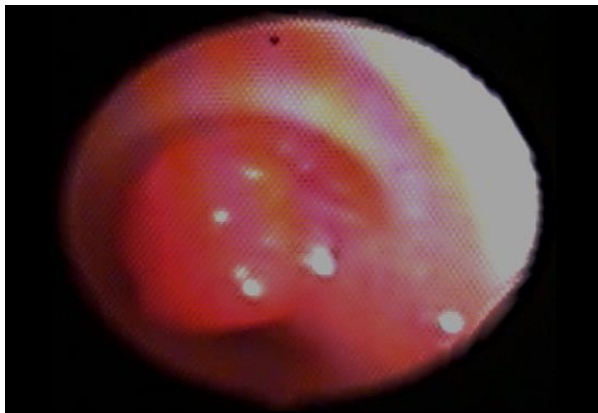
*Treatment.* Surgery depends on the site and extent of the cancer and the presence of lymphatic or distant metastases. For T1 cancers, partial resection of the hypopharynx with endoscopic access or via open surgery is appropriate. T2 tumours require partial resection of the hypopharynx, which may involve parts of the larynx and thyroid gland. Transoral resection with a CO<sub>2</sub> laser is an alternative. T3 cancers require hypopharyngectomy and laryngectomy, including the thyroid gland and reconstruction of the hypopharyngeal walls. T4 cancers usually cannot be treated surgically. Postoperative radiotherapy is indicated when there are positive resection margins, multiple pathologic



lymph nodes, or in patients with an advanced cancer stage. In patients with advanced stages of the disease who are in a poor general condition, *chemoradiotherapy* is indicated.

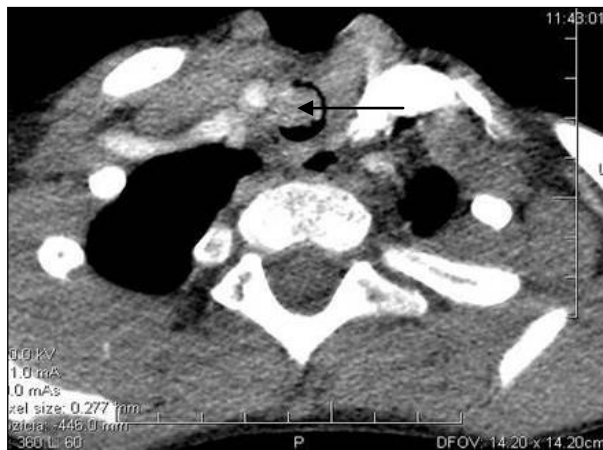#### 5.4.4.5 Tumours of the trachea

Primary tracheal tumours are uncommon and can be either benign or malignant. Secondary tracheal tumours are, by definition, malignant and involve the trachea either by direct extension or by hematogenous metastases.



**Figure 5.24a**

Adenoid cystic carcinoma of trachea – clinical picture



**Figure 5.24b**

Adenoid cystic carcinoma of the trachea – CT scan; axial scan

The benign tumors include adenomas, fibromas, lipomas, fibrolipomas, chondromas, amyloid tumor, hemangiomas and pleomorphic adenomas, hamartomas, intratracheal ectopic thyroid tissue. Although they are histologically benign, they may still cause airway obstruction.

*Recurrent respiratory papilloma* has a predilection for the larynx, but the trachea and bronchi may be involved by disseminated disease. Granulation tissue can also develop within the tracheal lumen at the superior margin of a tracheostoma. Symptoms include attacks of cough, wheezing, stridor, dyspnea and hemoptysis. The treatment is surgical.

In adults, the majority of primary tracheal tumours are malignant. 80% of primary malignant tracheal neoplasms are histologically either squamous cell carcinoma or adenoid cystic carcinoma (Figure 5.24).

Bronchogenic carcinoma is the most common malignant tumour of the lungs. Approximately 87% of all cases of lung cancer are attributable to tobacco use. It occurs typically in men between the ages of 50 and 70 years. Other malignant neoplasms of the trachea or bronchi include carcinoid, mucoepidermoid carcinomas, spindle cell, oat cell, and adenoid cystic carcinomas, adenocarcinomas, malignant melanomas, sarcomas, lymphoreticular neoplasms, and malignancies invading the trachea or bronchi from adjacent structures.

#### 5.4.5 Functional disorders of the larynx

*Definition.* Functional disorder of the larynx is a dysfunction in the presence of normal mucosal finding. They are characterised by voice disorders, dyspnoea, swallowing disorders or sensitive innervation of the larynx.

*Clinical features and diagnostics.* Voice disorders characterised by hoarseness, weakness or even loss of voice are called dysphonia. Typically, it is caused by interruption of the ability of the vocal folds to vibrate normally during exhalation. Paresis of one side of the larynx can prevent simple cyclic vibration and lead to irregular movement in one or both sides of the glottis. Aponia is the inability to produce any voice. It is considered more severe than dysphonia. Swallowing disorders often present by aspiration (see also Chapter 3).

*Aetiology of dysphonia:*

- Inflammation of the larynx over a short (acute) or long (chronic) period of time.
- Nodules on the vocal cords.
- Hypothyroidism.

- Trauma — any kind of trauma, including surgery, to the vocal cords will inevitably cause scarring and, hence, affect the vocal fold function. The risk of permanent voice change therefore needs to be discussed prior to surgery of the larynx.
- Vocal cord paralysis — some surgical procedures, including removal of the thyroid gland and surgery of the spine, heart or lung, can damage the nerves to the larynx, causing either temporary or permanent vocal cord paralysis.
- Reinke's oedema.
- Psychological — voice changes (hyperfunctional dysphonia) are not uncommon when people are under stress either at work or at home. The voice may be lost suddenly, usually overnight or following a cold. It is important to identify and remove the underlying stress.

*Treatment* should involve control of laryngopharyngeal reflux, consultation, counselling and therapy of a speech pathologist (see also Chapter 9.5 and Chapter 3).

#### 5.4.6 Foreign bodies in the upper airway

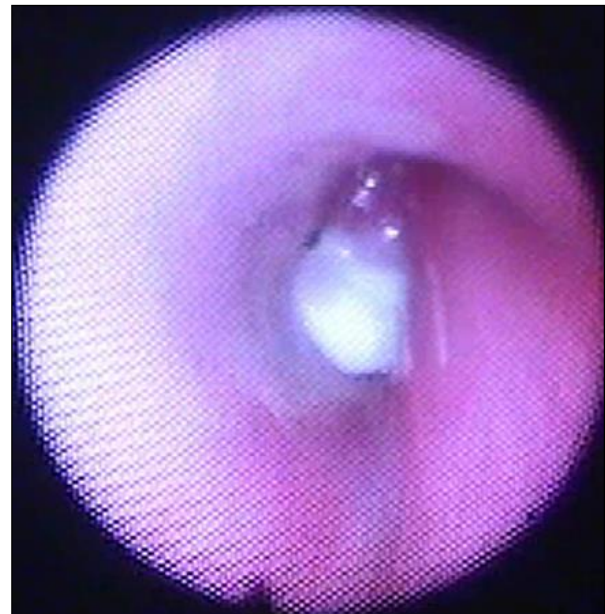Foreign bodies in the larynx, trachea, or esophagus should be considered in patients, particularly children, with symptoms of acute or recurrent airway disease. Children aged 1–3 years are particularly at risk (80 % of patients), because of their increasing independence, lessening of close parental supervision as they become older, and increasing activity and curiosity and because of hand-mouth interactions. Toddlers are at particularly high risk of potentially fatal aspiration of foreign bodies. Smaller objects, such as peanuts, nails, buttons, coins, small toys, peas and other small objects are easily aspirated into the bronchi by children.

*Clinical features.* Foreign body aspiration can result in a spectrum of presentations, from minimal symptoms, often unobserved, to respiratory compromise, failure, and even death. The main symptoms are episodes of dyspnoea, cough, wheezing, cyanosis, and pain. Total occlusion

causes sudden death. The location of the foreign body depends upon its size and shape. In general, foreign bodies are more likely to become lodged in the right main bronchus than the left, because the right bronchus is relatively straight and more in line with the trachea.

*Diagnosis.* Diagnosis is made by history, auscultation, chest radiographs and bronchoscopy. The radiopaque objects are readily diagnosed. In patients with suspected aspiration of a foreign body and a normal examination of the upper airway, inspiratory-expiratory plain chest radiography or decubitus chest radiography should be performed. These may show regional obstructive emphysema resulting from aspirated foreign bodies in the bronchi. Swallowed foreign bodies in the upper esophagus may produce airway obstruction by compressing the posterior wall of the larynx and trachea. Tracheal compression, appreciated best on lateral radiography, is the expected radiographic finding. In differential diagnosis we have to pay attention to pseudocroup, diphtheria, pneumonia, bronchial asthma, intraluminal tumors.

*Treatment.* The treatment is endoscopic removal of foreign body (Figure 5.25).



**Figure 5.25**

Foreign body in main bronchus

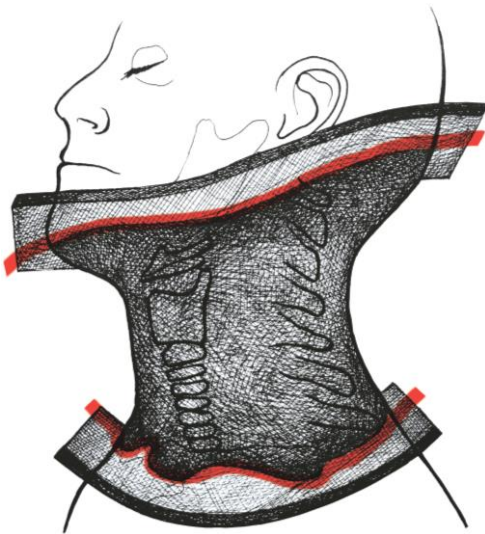


## 6 NECK

### 6.1 APPLIED ANATOMY AND PHYSIOLOGY

The neck is the part of the body that connects the head to the trunk. It supports the weight of the head and is highly flexible, allowing the head to turn and flex in different directions.

The visceral part of the neck accommodates the upper respiratory and digestive tracts. The midline has a prominence of the thyroid cartilage termed the *laryngeal prominence* (Adam's apple). Between the Adam's apple and the chin, the hyoid bone can be felt; below the thyroid cartilage, a further ring that can be felt in the midline is the *cricoid cartilage*. Between the cricoid cartilage and the suprasternal notch, the trachea and isthmus of the thyroid gland can be felt. The *sternocleidomastoid muscle* is another prominent structure, visible especially in men.



**Figure 6.1**  
Neck boundaries

#### **Anatomical boundaries**

The *superior border* runs along the inferior border of the mandible through the apex of the mastoid process to the external occipital protuberance.

*Inferiorly*, the neck ends in a plane formed by the suprasternal notch, the clavicle, and the spinous process of the seventh cervical vertebra.

*Laterally*, the borders of trapezius muscle form the boundary with the posterior part of the neck (Figure 6.1).

#### **Neck regions**

The *anterior cervical triangle* is bounded by the midline anteriorly, mandible superiorly, and sternocleidomastoid muscle inferolaterally. This triangle is subdivided into four smaller triangles by the two bellies of the digastric muscle superiorly and the superior belly of the omohyoid muscle inferiorly (submandibular triangle, carotid triangle, muscular or omotracheal triangle, submental triangle) (Figure 6.2).

The *posterior cervical triangle* is bounded by the clavicle inferiorly, sternocleidomastoid muscle anterosuperiorly, and trapezius muscle posteriorly. The inferior belly of the omohyoid divides this triangle into an upper occipital triangle and a lower subclavian triangle.

#### **The muscles of the neck**

These can be grouped according to their location. Those immediately in front of and behind the spine are the prevertebral, postvertebral, and lateral vertebral muscles, and on the side of the neck are the lateral cervical muscles. In addition, a unique superficial muscle, the platysma, exists.

**The platysma** muscles are paired broad muscles located on either side of the neck. The platysma depresses the lower lip and forms ridges in the skin of the neck and upper chest when the jaws are "clenched", denoting stress or anger. It also serves to draw down the lower lip and angle of the mouth in



the expression of melancholy. The **sternocleidomastoid muscle** is the prominent muscle on the side of the neck. It takes origin from the sternum and clavicle by two heads (sternal and clavicular heads). When only one side of the muscle acts, it draws the head towards the shoulder of the same side and rotates the head towards the opposite side. Acting together from their sternoclavicular attachments, the muscles flex the cervical part of the vertebral column. The **trapezius** arises from the spinous processes of the cervical and thoracic vertebrae and inserts on the spine of the scapula and acromion; it is innervated by the spinal accessory nerve and branches from the third and fourth cervical roots. The **suprahyoid muscles** (digastrics, stylohyoid, mylohyoid, and geniohyoid) perform two very important actions. During the act of swallowing they raise the hyoid bone and, with it, the base of the tongue; when the hyoid bone is fixed by its depressors, they depress the mandible. This is an important part of the swallowing act (see Chapter 3.2.1).

**Infracarotid muscles.** The sternohyoid muscle, sternothyroid muscles and omohyoid muscle are called the “strap muscles”. There are also groups of muscles located immediately in front and behind the spine: **anterior vertebral muscles, lateral vertebral muscles, suboccipital muscles.** These muscles are often called prevertebral muscles.

### Arteries of the neck

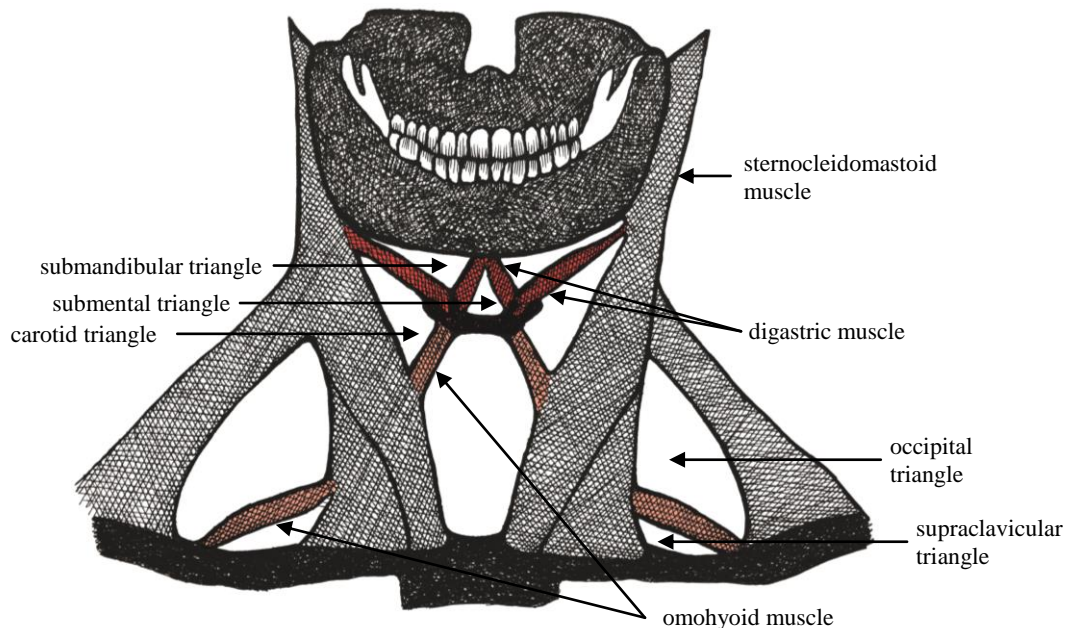
The main arteries in the neck are the common carotids arising differently, one on each side. On the right, the common carotid arises at the

bifurcation of the brachiocephalic trunk behind the sternoclavicular joint; on the left, it arises from the highest point on the arch of the aorta in the chest.

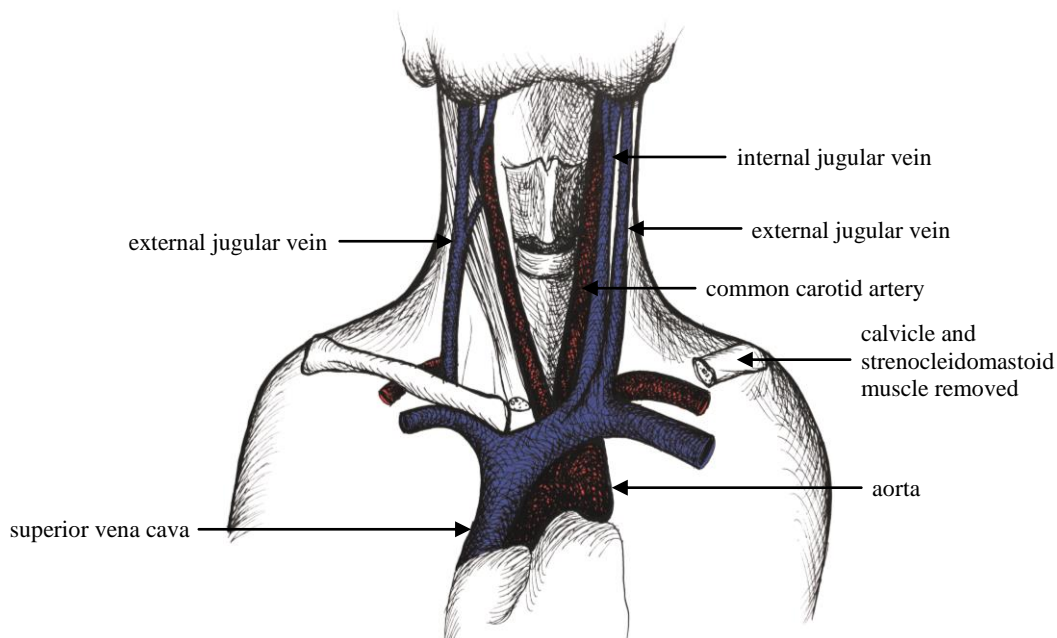
The *common carotid arteries* ascend in the neck and divide at the level of the upper border of the thyroid cartilage into two branches: the external and internal carotid arteries. The external carotid artery supplies the exterior of the head, the face and the neck, and the internal carotid artery supplies the cranial and intraorbital contents (Figure 6.3).

The common carotid artery, the internal jugular vein, and the vagus nerve are enclosed in a the carotid sheath, which is part of the deep cervical fascia.

The *external carotid artery* begins at the level of the upper border of the thyroid cartilage, and divides into the superficial temporal and maxillary arteries. Its branches are superior thyroid, lingual, facial, occipital, posterior auricular, ascending pharyngeal, superficial temporal, and maxillary.



**Figure 6.2**  
Neck regions



**Figure 6.3**

Major blood vessels of the neck

The *internal carotid artery* begins at the bifurcation of the common carotid, at the level of the superior border of the thyroid cartilage, and runs superiorly to the carotid canal in the petrous portion of the temporal bone. The cervical portion of the internal carotid does not give off any branches.

### Veins of the neck

The main veins of the neck that return the blood from the head and face are the external and internal jugular veins.

The *external jugular vein* receives blood from the exterior of the cranium and the deep parts of the face. It begins in the substance of the parotid gland, on a level with the angle of the mandible, and runs down the neck. This vein receives the occipital occasionally, the posterior external jugular, and, near its termination, the transverse cervical, suprascapular, and anterior jugular veins; in the substance of the parotid, a large branch of communication from the internal jugular may join it.

The *internal jugular vein* collects the blood from the brain, from the superficial parts of the face,

and from the neck. It is directly continuous with the sigmoid sinus and begins in the posterior compartment of the jugular foramen, at the base of the skull. It runs down the side of the neck in a vertical direction, lying (at first) lateral to the internal carotid artery and then lateral to the common carotid; at the root of the neck, it unites with the subclavian vein to form the brachiocephalic vein.

This vein receives in its course the inferior petrosal sinus, the common facial, lingual, pharyngeal, superior, and middle thyroid veins, and sometimes the occipital. The thoracic duct on the left side and the right lymphatic duct on the right side open into the angle of union of the internal jugular and subclavian veins.

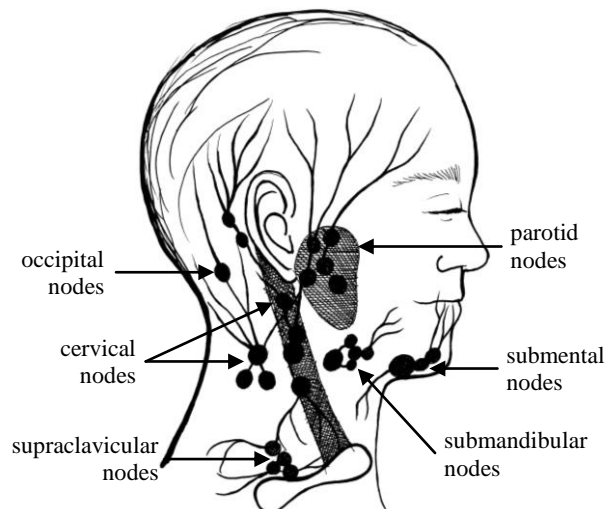
### Cervical lymphatic system

There are a total of approximately 300 lymph nodes in the adult human neck.

Lymph nodes are part of the lymphatic system, which is also an important part of the immune system. Lymph nodes are ovoid structures, and may be found singly or in groups. Most normal

lymph nodes are less than 1 cm in size. Normal lymph nodes in the neck can't be felt. Lymph channels lead from *tributary tissue areas* to regional lymph nodes or groups. The lymph nodes in the neck are incorporated in a network of lymph capillaries and lymph vessels which drain on both sides into the large lower deep cervical lymph nodes from which the lymph finally flows back into the venous system. On the left side the *thoracic duct* and on the right side the *right lymphatic duct (truncus lymphaticus dexter)* drain into the jugulosubclavian angle.

Neck lymph nodes can be classified according to the anatomical location (Figure 6.4).



**Figure 6.4**

Lymph nodes of the neck

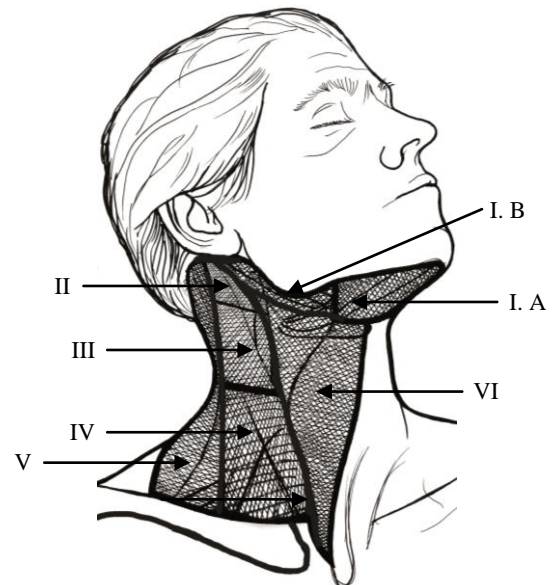
On clinical grounds, as suggested by the work at Memorial Sloan Kettering Cancer Centre, New York, the neck can be divided into six levels (Table 6.1, Figure 6.5). This classification is widely used in a treatment of cancers in the head and neck region.

#### Effects of removing the lymph nodes

Nodes that have been removed during cancer surgery (e.g. neck dissection) can leave part of the body without a way to drain off lymph in the affected area. Many of the lymph vessels now run into a closed end, where the node used to be, and fluid can back up. This is called lymphedema, and it can become a lifelong problem.

**Table 6.1** Division of neck nodes based on clinical grounds

Levels	Regions
I	Submental (IA), submandibular (IB)
II	Upper jugular
III	Mid-jugular
IV	Lower jugular
V	Posterior triangle group
VI	Prelaryngeal, pretracheal, paratracheal



**Figure 6.5**

Levels of the neck

#### Nervous system of the neck

The nervous system of the neck is complex. **Motor supply** of the cervical musculature and the diaphragm:

*The spinal accessory nerve* innervates the sternocleidomastoid and trapezius muscles. *The hypoglossal nerve* innervates the tongue. *The ansa cervicalis* innervates the infrahyoid muscles. Branches of *cranial nerves V, VII, and XII* innervate the suprahyoid musculature of the floor of the mouth. *The phrenic nerve*, arising from C3 to C5, runs inferiorly over the scalenus anterior muscle to innervate the diaphragm.

**Sensory nerve supply** of the external neck arises from the *cervical plexus*, C1 to C4, and consists of the great auricular nerve, the greater and lesser

occipital nerves, the transverse nerve of the neck, the supraclavicular nerves, and the dorsal rami over the nape of the neck.

The Erb point marks the convergence of the anterior branches at the midpoint of the posterior border of the sternocleidomastoid muscle. Infiltration at the Erb point produces local anaesthesia in the lateral part of the neck.

**The vagus nerve system (mixed nerves)** consists of the vagus nerve, glossopharyngeal nerve, and the cranial root of the accessory nerve. These nerves leave the base of the skull through the jugular foramen and have motor, sensory, and parasympathetic functions in the neck, especially for the pharynx and the larynx. The superior ganglion of the vagus nerve lies at the base of the skull, and the inferior ganglion at the level of the hyoid bone.

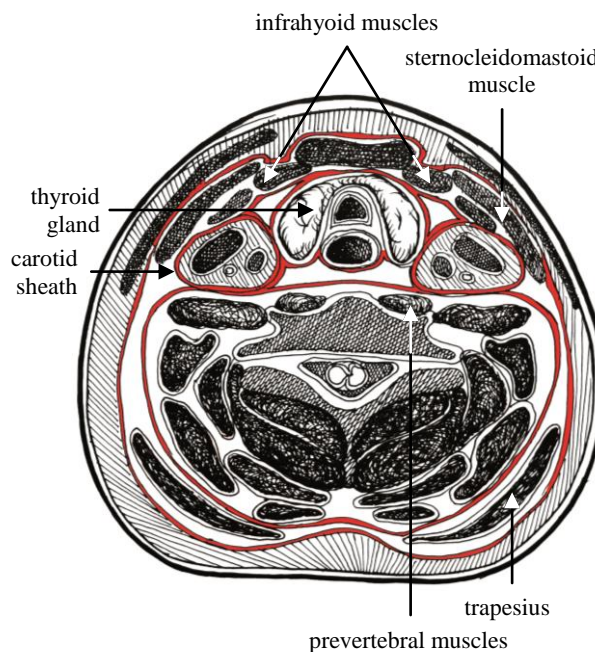
**The cranial sympathetic nervous system** is dominant during physical and mental stress. It innervates all of the smooth muscles, the various glands of the body, and the striated muscle of the heart, triggering increases in blood pressure and heart rate, dilation of the pupils, and sweating, in addition to many other somatic reactions. The cell bodies of the preganglionic neuron are located in the lateral horn of the spinal cord. The nerve fibres leave the spinal cord through the anterior root and, via a communicating branch, reach the sympathetic trunk. This consists of several ganglia and nerve fibres and extends from the neck to the sacrum along each side of the vertebral column.

### Fascial planes

The cervical muscles, viscera and carotid sheath are enclosed in a *fascia* which is partly tight, partly loose and partly incomplete.

The fascia of the neck is important in preventing the spread of infections, but they do occur, it both directs and limits the spread. A sound knowledge of the fascial layers is essential to understanding the presentation, treatment and potential complications of infections in the neck.

The cervical fascia can be divided into a simpler *superficial layer* and a more complex *deep layer* that is further subdivided into superficial, middle and deep layers (Figure 6.6).



**Figure 6.6**

Deep cervical fascia

- The **superficial layer of the cervical fascia** ensheathes the platysma in the neck and extends superiorly in the face to cover the mimetic muscles. It is the equivalent of subcutaneous tissue elsewhere in the body and forms a continuous sheet from the head and neck to the chest, shoulders and axilla.
- The **superficial layer of the deep cervical fascia** is also known as the investing or the anterior layer of the deep cervical fascia. This layer originates from the spinous processes of the vertebral column and spreads circumferentially around the neck, covering the sternocleidomastoid and trapezius muscles, attaches to the hyoid, and continues superiorly to enclose the submandibular and parotid glands. Here it also covers the anterior bellies of the digastrics and the mylohyoid, thereby forming the floor of the submandibular space.



- The **middle layer of the deep cervical fascia** is also known as the visceral fascia, the prethyroid fascia and the pretracheal fascia. Its muscular division surrounds the infrahyoid strap muscles, and the visceral division envelops the pharynx, larynx, oesophagus, trachea, and thyroid gland. The visceral division passes inferiorly into the upper mediastinum, where it is continuous with the fibrous pericardium and covers the thoracic trachea and oesophagus.
- The **deep layer of the deep cervical fascia** originates from the spinous processes of the cervical vertebra and the ligamentum nuchae. It forms a tight tube around the deep cervical muscles. The prevertebral layer is a part of the fascial system running continuously from the skull base to the inferior end of the spinal column.

---

#### The carotid sheath

The carotid sheath is a fascial layer that is associated with, but is anatomically separate from, the deep cervical fascia. It receives contributions from all three layers of the deep cervical fascia and contains the carotid artery, internal jugular vein and vagus nerve. It continues from the skull base through the neck (along the anterior surface of the prevertebral fascia), and enters the chest posterior to the clavicle.

---

#### Deep neck spaces

The various layers of the cervical fascia, as they pass around and attach to structures in the neck, form several spaces. It is reasonable to group them according to their relationship to the hyoid bone into three categories: spaces involving the entire length of the neck, suprahyoid spaces and infrahyoid spaces.

- *Spaces that run the entire length of the neck:* the retropharyngeal space, the danger space, the prevertebral space and the visceral vascular space. Posterior to the retropharyngeal space lies the danger space, thusly named because it contains loose areolar tissue and offers little resistance to the spread of infection. It is the space anterior to the deep layer of the deep fascia and runs from the skull base to the diaphragm.
- *The spaces above the hyoid bone:* the submandibular space, the parapharyngeal space, the peritonsillar space, the masticator space, the temporal space and the parotid space.
- Space limited to *below the hyoid* is the anterior visceral space, containing the thyroid gland, oesophagus and trachea.

## 6.2 EVALUATION

The important information to be gathered during **history taking** is as follows:

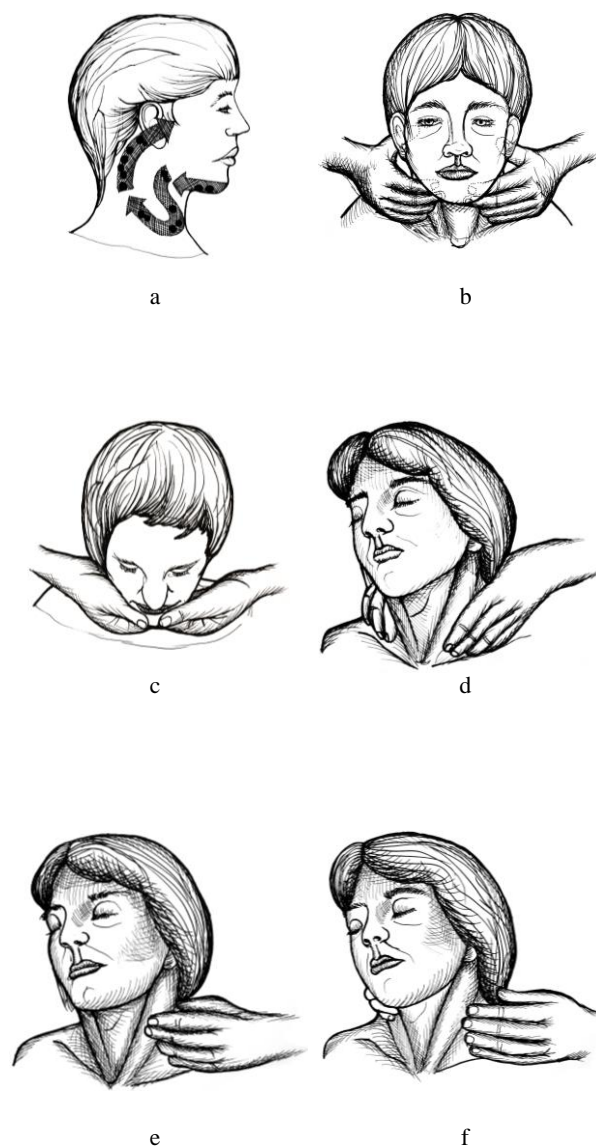
- *Onset.* The nature of onset is vital to establishing the pathology of the mass. A rapid onset painful swelling suggests an inflammatory condition; on the other hand, a slowly enlarging mass in an adult, which is not painful, suggests a neoplasm. Inflammatory swellings in the neck are commonly associated with infections in the ear, nose, throat and scalp.
- *Duration.* Inflammatory masses settle once the primary source of infection is treated. A mass in the neck which is persistent (>6 weeks) with or without associated symptoms requires further investigation.
- *Associated symptoms (dysphonia, dysphagia, dyspnoea, weight loss).* It is vital to gather information from the patient that would suggest a primary malignancy in the head and neck causing a metastatic lymph node enlargement.
- *Social history.* Occupational exposure to asbestos or wood dust is associated with an increased risk of cancers in the head and neck. Smoking is the single most important risk factor for cancers of the upper aerodigestive tract, and a detailed history regarding this habit should be sought. Alcohol consumption is also a known risk factor for cancer of the head and neck.

**Inspection** is oriented on the structures that contribute to the profile, and seeks lesions of the overlying skin (vascular signs, venous congestion, dermatitis, skin tumours), as well as fistulous



openings. The position and mobility of the head are examined while looking for spasm of the neck muscles, e.g. in an abscess, thyroiditis and torticollis.

**Palpation** is carried out from in front of or behind the patient and both sides are compared (Figure 6.7). The head should be tilted forwards to relax the soft tissues. Palpable abnormalities mostly relate to the thyroid gland, lymph nodes, salivary glands, tumours, cysts and abscesses.



**Figure 6.7**  
Palpation of the neck

### Differential diagnosis of a mass in the neck on physical examination

#### Midline masses

- *Thyroglossal cysts* are usually found at the level of the hyoid bone or thyroid cartilage. They move upwards on swallowing and on protrusion of the tongue.
- *The mass in the thyroid* is a midline swelling, but may also be present as a lateral mass if one lobe of the thyroid is involved. They are more common in adults and in females.
- *Dermoid cysts* are found at or above the level of the hyoid bone, although they can be found much lower in the neck as well. They do not move upwards on swallowing or protrusion of the tongue.

#### Lateral neck lumps in children

- The majority of masses in the neck in children are *reactive lymph nodes* secondary to infections in the head and neck. They usually settle between 4 and 6 weeks.
- Solitary neck masses are usually congenital in origin. The most common one is a *branchial cyst*.
- Neoplastic masses in children are usually due to a primary cancer (e.g. sarcoma, thyroid, lymphoma).

#### Lateral neck masses in adults

- The majority of masses in the neck in adults are *inflammatory*, and almost all of them settle between 4 and 6 weeks.
- *A metastatic neck nodes in the neck may be the first presenting sign of a malignancy!* Any persistent mass (>6 weeks) should be considered malignant (until proven otherwise) and needs urgent assessment by an otolaryngologist.
- *A mass in the parotid* classically found inferior to and posterior to the ear lobule.
- *Thyroglossal and branchial cysts*, although congenital, can also be found in adults.

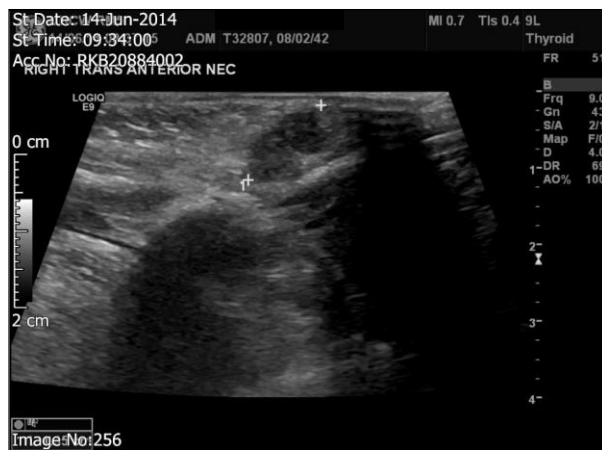**Imaging.** The neck may be imaged by ultrasound and cross-sectional imaging (CT with contrast and MRI) with axial images.

*Plain radiographs* are rarely helpful. The role of plain radiograph is limited to imaging of the cervical spine. Metallic foreign bodies can also be identified on a plain radiograph.

*Angiography* in the neck is useful mainly for evaluating vascular lesions (juvenile angiofibromas), paraganglioma and tumours fixed to the carotid artery (glomus tumour). It is also used for pre-operative embolization of large vascular tumours. Subtraction views are used to make the vessels stand out against the soft tissue and skeletal shadows.

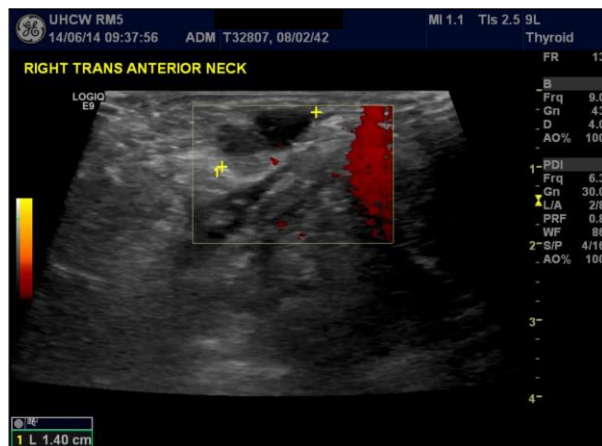*Ultrasonography (USS)* is a valuable noninvasive technique for vascular lesions and clearly

delineates thyroid and parathyroid abnormalities. It reliably differentiates solid from cystic masses. The role of ultrasound in the assessment of cervical lymphadenopathy is also well established. It has grey-scale sonographic features that help to identify metastatic and lymphomatous lymph nodes, including size, shape and internal architecture (loss of hilar architecture, presence of intranodal necrosis and calcification). Doppler sonography evaluates the vascular pattern of nodes and helps to identify the malignant nodes (Figure 6.8).



**Figure 6.8a**

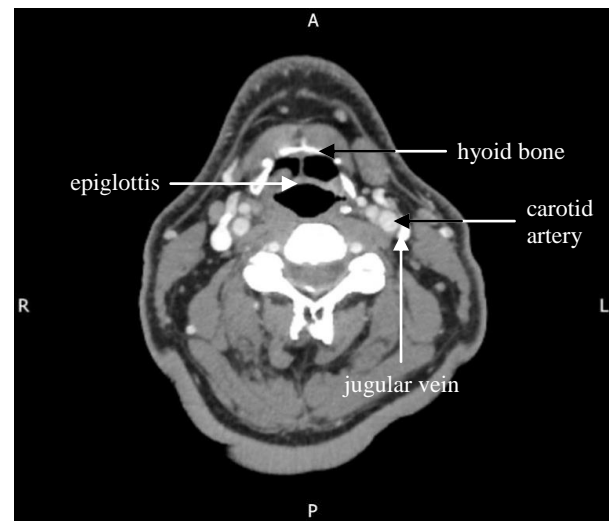
Level VI recurrent lymph node; neck ultrasonography



**Figure 6.8b**

Doppler ultrasonography

*Computer tomography (CT).* CT uses a highly collimated X-ray beam that is differentially absorbed by various body tissues. CT is fast, cost-effective and ubiquitous in most medical centres. During a scan, images are taken of cross-sections of the structures in coronal and axial planes, and slice thickness is usually 1–5 mm. CT is good at delineating the extent of the tumour and nodal disease in a cancer patient. When contrast is used, the structures are highlighted (Figure 6.9).



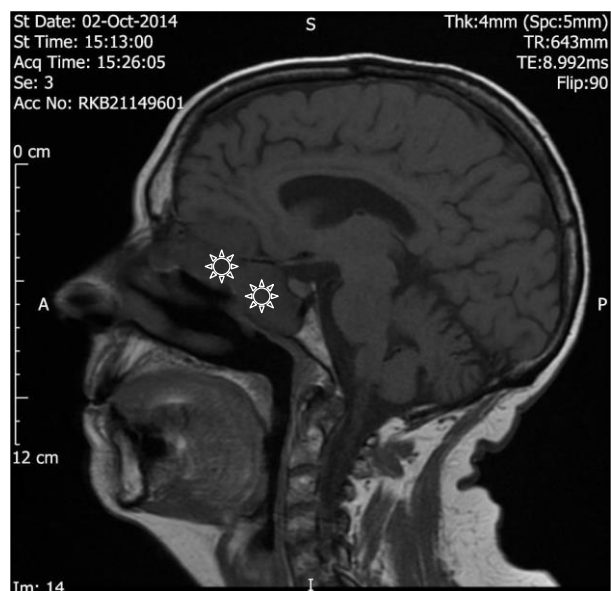
**Figure 6.9**

CT with contrast of the neck in the axial plane at the level of the hyoid bone

*Magnetic resonance imaging (MRI)* provides information similar to CT. MRI has the ability to differentiate neoplastic from inflammatory lesions. T2-weighted images with contrast (gadolinium) are particularly useful for delineating the invasion of soft tissue by tumours. The excellent soft tissue characterisation and multiplanar imaging capability results in more accurate diagnosis of both the benign and malignant process (Figure 6.10).

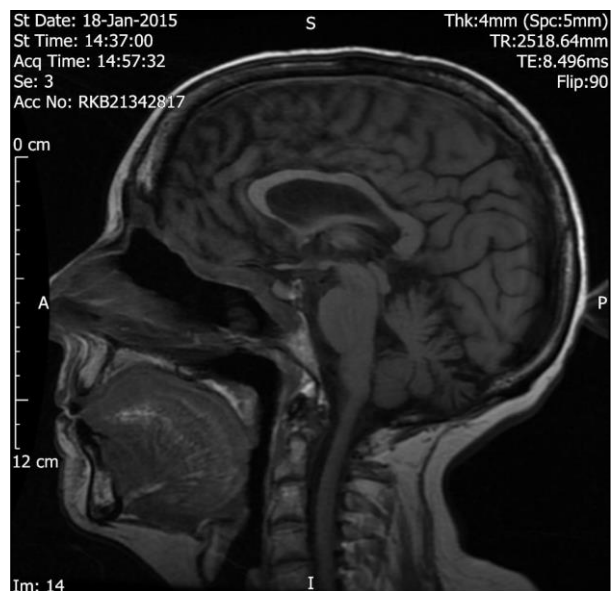*Positron emission tomography (PET)* provides functional views of tissues rather than simple anatomy.  $^{18}\text{F}$ - fluorodeoxyglucose (FDG) is taken up into tissues in proportion to the metabolic rate, which is generally increased in neoplastic processes. Focal asymmetric uptake is suggestive of a tumour but is non-specific, as FDG is also

concentrated in areas on inflammation. A PET-CT scan combines a CT scan and a PET scan into one scan to give more detailed information (Figure 6.11).



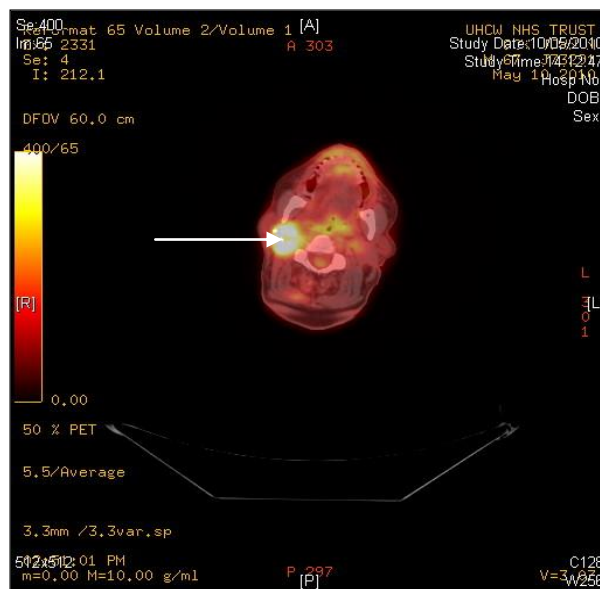
**Figure 6.10a**

Esthesioneuroblastoma – preoperative (asterisk marks the tumour); MRI scan, T1 – weighted image, sagittal plane



**Figure 6.10b**

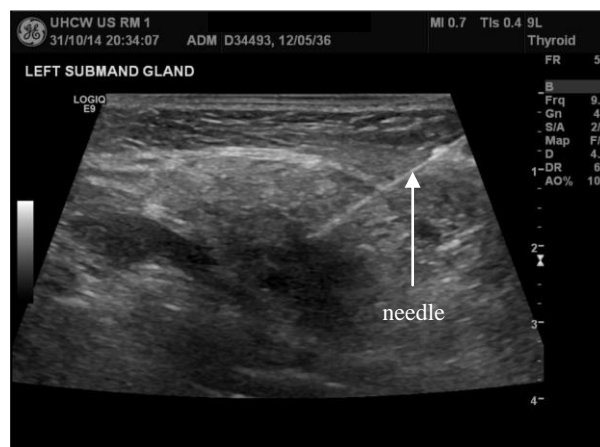Esthesioneuroblastoma – postoperative; MRI scan, T1 – weighted image, sagittal plane



**Figure 6.11**

Recurrent SCC in levels II-V right neck; PET CT, axial plane

**Biopsy.** There are several ways to obtain material for cytopathological/histopathological assessment.



**Figure 6.12**

Fine needle biopsy of submandibular gland lesion

*Fine needle aspiration biopsy (FNA).* A mass in the neck of an uncertain origin may be evaluated by FNA. This may be performed under USS guidance. The procedure is easy to perform and provides a reliable diagnosis when positive, without complicating later attempts at curative surgery.

FNA is also one of the routine examinations in the evaluation of a thyroid nodule (Figure 6.12).

*Core biopsy.* Tissue aspiration with a large bore needle obtains tissue for histologic evaluation. Only positive results can be used to establish a diagnosis.

*Open biopsy.* Excision of isolated lymph nodes or wedge excision of a solid tumour mass is the most reliable method for histological assessment.

## 6.3 DISEASES OF THE NECK

### 6.3.1 Congenital abnormalities

*Definition and pathogenesis.* Lateral cervical lesions are congenital developmental defects that arise from the primitive branchial apparatus (branchial arches, clefts, and pouches). In embryogenesis in the 3<sup>rd</sup> and 4<sup>th</sup> week, five mesodermal branchial arches, four ectodermal branchial clefts (grooves) and five endodermal branchial pouches develop in the embryo (Figure 6.13). Each arch contains a cartilaginous rod, muscular component, a nerve and an artery. The most widely accepted theory of the genesis of branchial cleft anomalies is that fistulae, sinuses, and cysts result from incomplete closure of the connection between the cleft and the pouch.

#### Pre-auricular sinus

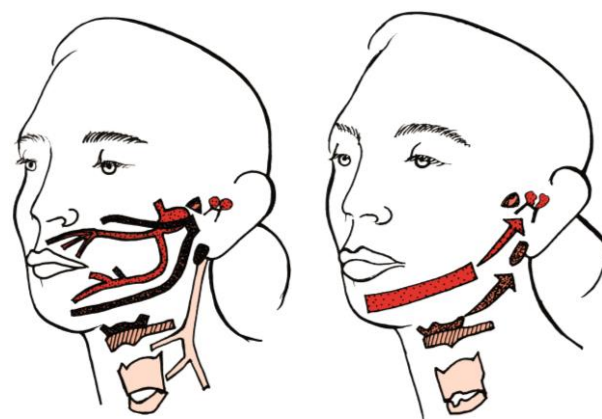
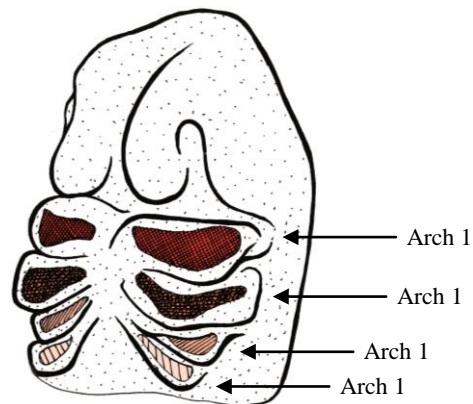
This is a result of abnormal development of the otic hillocks of the first and second branchial arches. *First branchial arch anomalies* usually present as a periauricular swelling, sinus, or mass in the external auditory canal.

#### Dermoid cyst

A dermoid cyst is a teratoma of a cystic nature that contains an array of developmentally mature, solid tissues. It frequently consists of skin, hair follicles, and sweat glands. Treatment for a dermoid cyst is complete surgical removal.

#### Epidermoid (sebaceous) cyst

This is a swelling in the skin arising in a sebaceous gland. Epidermoid cysts can be made up of keratin and adipose tissue. Sebaceous cysts are much less common and affect the sebaceous glands in the skin. Infected *sebaceous cysts* may mimic a cervical abscess. Epidermoid cysts are harmless; however, they are often removed for cosmetic reasons.



**Figure 6.13**  
Embryogenesis

#### Branchial or lateral neck cyst

*Definition.* Branchial cleft cysts tend to present before the age of 30 as a smooth, round, fluctuant, nontender mass along the anterior border of the sternocleidomastoid muscle, anywhere from the external auditory canal to the clavicle (Figure 6.14).

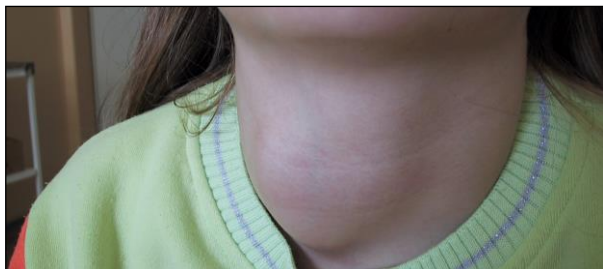*Clinical features.* During upper respiratory tract infections, a painful increase in the size of the mass due to the presence of lymphoid follicles in the wall of the cyst is common. Bilateral cysts are rare.

*Diagnosis* is made according to the history, palpation and location of the cyst. Preoperative assessment with CT scanning or MRI is indicated.

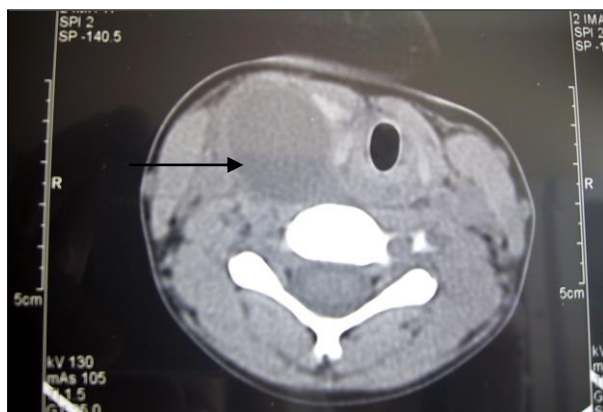
*Treatment* is by complete surgical excision and is indicated for recurrent infection or cosmetic



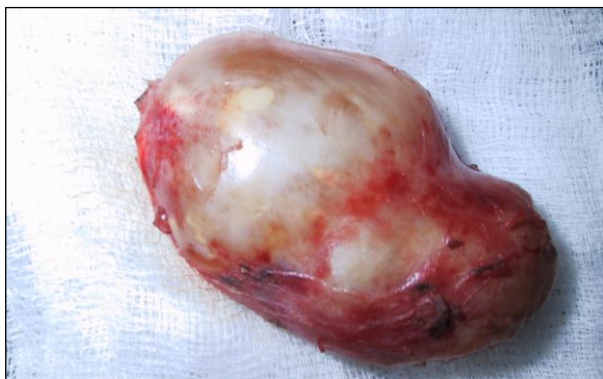deformity. The concept of cancer arising due to malignant degeneration in a branchial cleft cyst is no longer accepted. These represent a cystic form of metastatic cancer from tonsil/ base of tongue.



**Figure 6.14a**  
Branchial cyst



**Figure 6.14b**  
Branchial cyst; CT scan, axial plane



**Figure 6.14c**  
Branchial cyst; surgical specimen

A suspected cystic lesion in a patient over 40 years of age has to be investigated with a suspicion for cystic metastasis originating from oropharyngeal carcinoma.

### Branchial or lateral fistulae

*Pathogenesis.* These occur as a result of defects in fusion (incomplete obliteration) of the branchial clefts. A fistula can be bilateral in approximately 5%.

*Clinical features.* A fistula tract runs from the skin, usually at a site close to the anterior border of the sternocleidomastoid muscle, to the tonsillar or pyriform fossae. The cutaneous opening may be red and swollen, with milky or purulent, recurrent or persistent discharge.

*Diagnosis.* The subcutaneous part of the fistula can be palpable and secretion can usually be expelled from the fistula opening. Contrast medium may be injected; in the case of a complete fistula it flows into the pharynx.

*Treatment.* Complete surgical excision is necessary for prevention of recurrence. The course of the fistula is variable and the surgery can be difficult.

### Thyroglossal duct cyst and fistulae

*Definition.* A thyroglossal cyst is formed from a persistent thyroglossal duct, can develop anywhere along a duct.

*Clinical features.* *Thyroglossal cysts* are the most common congenital midline cysts, accounting for 70% of all congenital cervical lesions (see also Chapter 7.4, Figure 7.13). *Cysts, sinuses* and *fistulae* of the thyroglossal duct manifest as mass of the anterior midline of the neck from the foramen caecum to the thyroid gland, typically before 20 years of age. They are often asymptomatic but they may become recurrently infected during upper respiratory tract infections, which can cause enlargement of the cyst.

*Pathogenesis.* Thyroglossal cysts are remnants of the thyroglossal duct. Median cervical fistulae may be caused by perforation of the thyroglossal duct through the skin, by spontaneous perforation due to infection, or by surgery.

*Diagnosis.* Thyroglossal duct cysts presents as a firm elastic swelling inferior to the hyoid bone and superior to the thyroid gland. They move superiorly and move inferiorly with swallowing and protrusion of the tongue because of their connection to the hyoid bone. Ultrasound confirms the diagnosis. If a fistula is present its external opening is often inflamed; fistulography might help to establish the course of the fistula.

The *differential diagnosis* includes a dermoid cyst, hyperplasia or cyst of the pyramidal lobe, teratoma, hamartoma, lipoma, sebaceous cyst, cavernous haemangioma, hypertrophic lymph node, and malignant primary or metastatic neoplasm.

*Treatment* is surgical. It involves a transverse incision over the cyst or a fusiform incision around an external fistula. The cyst, fistula, body of the hyoid, and the fibrous cord extending to the foramen caecum, must be excised (see Sistrunk procedure, Chapter 10.10). A recurrence is common.

It is paramount to make the correct diagnosis of a thyroglossal cyst and perform the appropriate procedure at the time of initial surgery to avoid recurrence.

### 6.3.2 Inflammatory diseases

Superficial infections affecting the skin and its appendages have to be distinguished from deep infections affecting the viscera. Superficial infections are usually primary infections of the skin and its appendages, caused by staphylococci. Inflammations of the cervical visceral spaces are usually secondary to necrosis or inflammation of the regional lymph nodes, with or without suppuration, or extend from internal organs such as the airway and the oesophagus.

#### Superficial infections

*Furuncles* or *carbuncles* on the neck are most common on the nape of the neck in men and are often found in diabetic patients and in patients with alcoholism. Furuncles are treated surgically

by unroofing. Carbuncles are treated using parallel incisions and undermining of the subcutaneous septal skin, followed by drainage and concomitant antibiotic therapy.

#### Acute cervical lymphadenitis

*Clinical features.* These include acute, painful swellings of the lymph nodes. If the course is subacute, induration and decreasing tenderness occur. The site of the lymphadenitis depends on the primary site of the inflammatory disease. The lymph nodes may fluctuate if treatment is inadequate or the organisms are very virulent. Fluctuation and spontaneous perforation through the skin are possible.

*Pathogenesis.* The first frequency peak is in children up to the age of 10 years and is usually due to an upper respiratory tract infection. Streptococcal infections are the most frequent causes. Other potential causes are viruses (rubella, cytomegalovirus, Epstein–Barr, HIV) and mycobacteria. The second frequency peak is in adults between 50 and 70 years of age. In these patients, lymphadenitis is often an expression of inflammation accompanying malignancy.

If acute cervical lymphadenitis is found, a careful topographic search of the head and neck region for the primary infection has to be carried out. The primary focus may have already been resolved, but enlarged cervical lymph nodes may still persist.

Chronic lymphadenitis present for more than 4 weeks requires more thorough diagnostic testing.

*Diagnosis.* The primary focus of infection is looked for in the area of lymph node drainage. The enlarged and fluctuant lymph nodes may be tender. If there is any diagnostic doubt, biopsy of the lymph node is necessary.

*Treatment.* Broad-spectrum antibiotics are administered. If there is abscess formation, incision and drainage is necessary. Ultrasound-guided aspiration is also a recognised form of treatment. A specimen of the purulent exudate is

taken for culture and sensitivity testing, and any tissue removed is submitted to the pathologist for examination.

### Chronic cervical lymphadenitis

*Definition.* Chronic cervical lymph node enlargement that has been present for more than four weeks.

*Diagnosis.* A diagnostic procedure for cervical lymphadenopathy is mandatory, taking into consideration the presence of risk factors, the patient's age, specific and nonspecific symptoms, and disease history. Palpation and ultrasound allow initial localisation and measurement of the lymphadenopathy. FNA might help with diagnosis. Serological screening tests are helpful for differentiating specific lymphadenopathies.

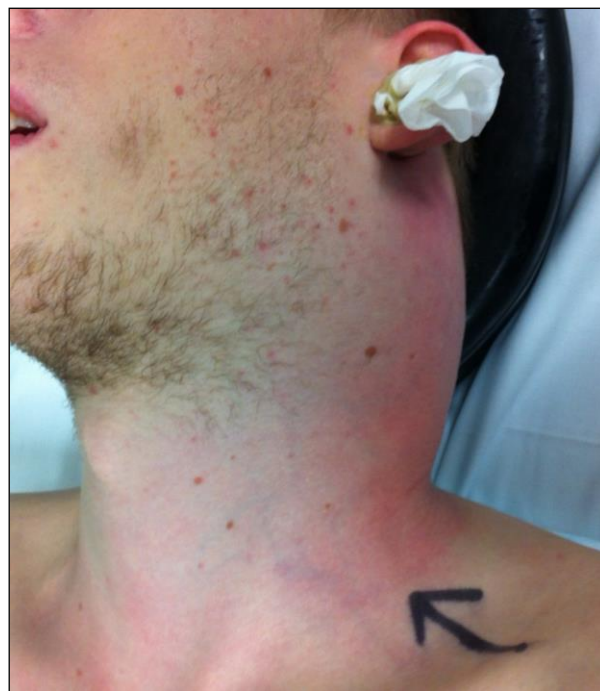*Differential diagnosis.* Chronic cervical lymphadenitis has to be distinguished from malignant diseases such as malignant lymphoma and cervical lymph node metastasis.

*Treatment.* Surgical removal of the lymph node will provide the diagnosis, but must only be carried out after a full and thorough assessment of the respiratory tract to exclude a potential primary malignancy.

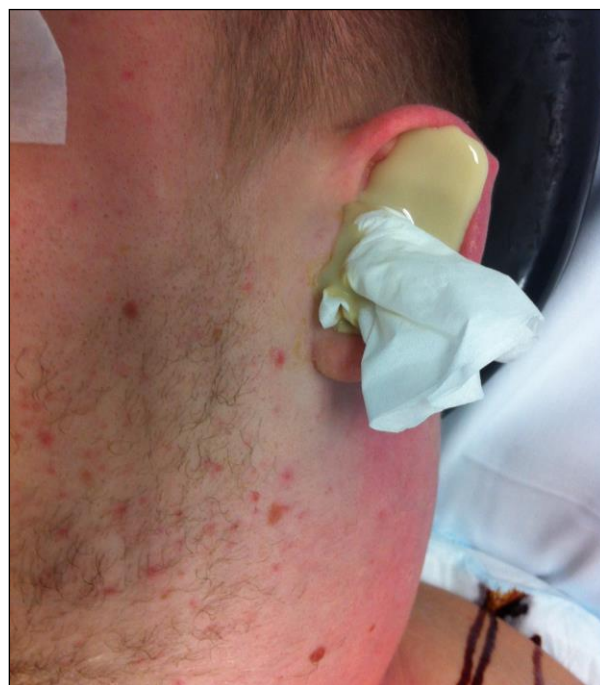### Neck phlegmona and abscess

*Definition.* This is an infection of deep neck structures requiring an urgent evaluation and treatment (Figure 6.15).

*Clinical features.* The site of an inflammatory process in the fascial spaces determines the clinical picture, and the parapharyngeal and submandibular (Ludwig's angina) spaces are most commonly involved. Retropharyngeal abscess, once almost exclusively a disease of children, is observed more in adults. Collections of purulent exsudate lying deep in the neck often cannot be palpated. The functions of the soft tissue of the neck are restricted, and deep swellings cause pain such as trismus, pain on swallowing, and muscle rigidity. Blood tests reveal the typical signs of infection. Shivering, respiratory obstruction, or mediastinitis indicates thrombophlebitis or early septicæmia. Examination of blood cultures is indicated in septic patients.

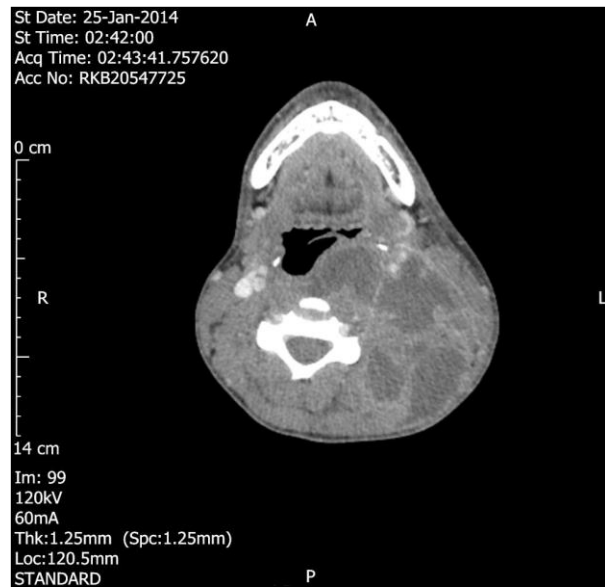


**Figure 6.15a**  
Neck abscess



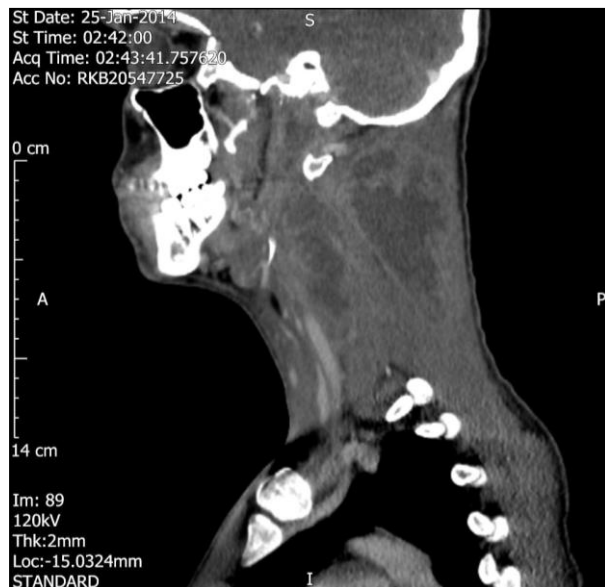**Figure 6.15b**  
Neck abscess – Detail of pus draining from the ear





**Figure 6.15c**

Neck abscess; CT scan, axial plane



**Figure 6.15d**

Neck abscess; CT scan, sagittal plane

**Aetiology and pathogenesis.** The cause is a soft-tissue infection originating from the upper respiratory tract, primary or secondary inflammation of the cervical lymph nodes or infected cysts.

**Diagnosis** is based on the history, clinical findings, imaging studies, and microbiology.

**Treatment.** Early recognition and aggressive management of the abscess are essential because this virulent infection carries significant morbidity and mortality. Broad-spectrum i.v. antibiotics (in combination) are given immediately, without waiting for the results of culture and sensitivity tests. If the abscess is present, transcervical incision and drainage are necessary.

Antibiotics only are not a substitute for incision and drainage of the abscess.

### Mediastinitis

The visceral space in the neck is not closed off from the superior mediastinum, so the inflammation of the deep neck structures may spread into this space.

**Clinical features.** Symptoms include severe malaise, fever, retrosternal or intrascapular pain, cutaneous emphysema (gas formation), and venous congestion.

**Diagnosis** is based on the history, clinical findings, and the chest imaging.

**Treatment** is complex and requires surgical intensive care unit. Antibiotics and an aggressive surgical management is warranted. Surgery includes removal of necrosis, opening of all spaces which harbor infection. The wound should be well irrigated with antiseptic and kept open. Daily wound debridement should be performed in the operating room until no more necrosis is seen.

### Necrotising fasciitis

**Definition.** Necrotising fasciitis is a rapidly progressive inflammatory infection of the fascia, with secondary necrosis of the subcutaneous tissues. *This is a surgical emergency!* It is extremely rare in the region of the head and neck. However one must keep a strong index of suspicion, especially if an infection progresses rapidly or is unresponsive to standard management principles.

**Aetiology** includes dental abscesses, supraglottitis, blunt or penetrating trauma. Patients usually possess some predisposition to infection, such as diabetes mellitus, peripheral vascular disease, cirrhosis, previous malignancy, immunosuppression, or alcoholism.

**Pathogenesis.** The infectious process may arise over a few hours or a few days after the initial event and progress rapidly. Also of note is the lack of frank purulence and the presence of thin grey exudate emanating from the necrotic area. The patient usually presents in a toxic state with hyperpyrexia, tachypnoea, tachycardia, and progressive lethargy.

**Treatment** includes antibiotics in combination and an aggressive surgical approach, including surgical debridement of necrotic tissues, bedside dressings and frequent wound debridement.



## SPECIFIC LYMPHADENOPATHY

### Tuberculosis

*Clinical features.* The superior jugular, supraclavicular, and nuchal lymph nodes are most often involved, however any group of lymph nodes in the cervical region may be affected. This specific lymphadenopathy is painless or only produces slight pain. The lesions may be solitary, multiple, small or large, firm or fluctuant. Often there may be fistulas or old retracted fistulous scars in addition to acute reactivated lymph nodes, possibly with erythema of the skin and fluctuation. This problem may affect both children and adults.

*Pathogenesis.* Tuberculosis lymphadenitis is mainly a secondary haematogenous infection, usually caused by human tuberculous mycobacteria; occasionally, it is due to atypical mycobacteria, particularly in children. The infection spreads from patients with active tuberculosis who may be apparently healthy and tuberculin-positive.

*Diagnosis.* Important features of the patient's history include the country of origin, a family history of tuberculosis, and visits to endemic areas in Asia, Africa, and south-eastern Europe. Radiographic and CT images of the neck revealing calcification of the lymph nodes are almost always pathognomonic. Chest radiography and an intracutaneous tuberculin test complete the diagnostic procedure. The diagnosis is confirmed by the histological appearance of the excised lymph nodes and by microbiology.

*Treatment.* Antituberculous treatment is in the hands of a respiratory/infectious disease specialist and usually is a combined triple drug therapy using isoniazid, rifampicin, and ethambutol. The indications for surgery are lymph nodes 2 cm or more in diameter and that show no tendency to resolve, lymph nodes with calcification, fluctuant lymph nodes, fistulas and involvement of the overlying skin.

### Infectious mononucleosis (glandular fever)

*Definition.* Infectious mononucleosis is a clinical diagnosis, caused by Epstein–Barr virus in most cases.

*Clinical features.* In adolescence and young adulthood, the disease presents with a characteristic triad: fever, sore throat (acute pharyngitis) and mobile lymphadenopathy. This is usually located in the posterior cervical lymph nodes and sometimes throughout the body. Another major symptom is fatigue. Glandular fever is a self-limiting disease (see also Chapter 3.4.3). Marked enlargement of the tonsils with a potential for airway obstruction is a major feature of this disease.

### Syphilis

Stage I, primary chancre: indolent regional lymphadenopathy appears 1–2 weeks after the primary lesion on the lips, mouth, tonsils, or facial area. In stage II: multiple cervical lymphadenopathy may occur.

### Sarcoidosis

Lymphadenopathy affects the mediastinal and supraclavicular nodes in 65–75% of cases and the peripheral nodes in 10–20%, and may include the retroperitoneal nodes. The eyes, lacrimal glands, and salivary glands are affected in 5–25% of cases. The mucous membranes of the nose and sinuses, pharynx, larynx, trachea, mouth, and oesophagus demonstrate pale-red granular areas.

### Cat-scratch disease and tularaemia

A pustulous primary focus occurs in the skin or oral mucosa, and usually ulcerates. This is followed 1–5 weeks later by a regional painless, or almost painless, lymphadenopathy. *Cat-scratch disease* is caused by *Bartonella henselae*, and tularaemia is caused by *Francisella tularensis*. History reveals contact with animals. Both conditions are confirmed by serology and antibody assay and respond to treatment with various antibiotics. However, cat-scratch disease will often resolve without antibiotics. In tularaemia, the severity and type of lymphadenopathy determine the need for surgical treatment. Lymphadenopathy may resolve spontaneously.

### Toxoplasmosis

An important clinical feature is lymphadenopathy, affecting especially the nuchal, periauricular, jugulo-digastric, and supraclavicular nodes, and rarely the axillary and inguinal nodes. Infection in humans is caused by *Toxoplasma gondii*, which is mainly acquired through consumption of raw beef or pork, but also from contact with feline faeces. However, the great majority of postnatal infections proceed without causing characteristic clinical symptoms.

### Lyme disease

The initial clinical features are erythema migrans and pain at the bite site, with lymphadenitis. The disease is caused by the spiro-chete *Borrelia burgdorferi*, transmitted mainly by the bite of the tick *Ixodes ricinus* (Central Europe). Diagnosis is done by serological proof of specific antibodies. The

antibiotic treatment of choice is doxycycline (in adults), amoxicillin (in children), and ceftriaxone for 3–4 weeks.

#### **Actinomycosis**

It is a chronic disease causing fistulas. It is relatively painless, with hard infiltrates mainly affecting the neck, but also less commonly the cheek and the floor of the mouth. The skin undergoes livid discolouration. The infection responds to penicillin.

#### **HIV**

During the acute HIV syndrome, swollen lymph nodes are a common symptom. After other symptoms have disappeared the lymph nodes remain enlarged, felt as small, painless lumps in the neck, axilla or in the groin.

### 6.3.3 Trauma

Injuries to the larynx, trachea and oesophagus are described in appropriate chapters.

Depending on the force involved, **blunt trauma** to soft tissues leads to oedema of the soft tissue or haematoma, and to surgical emphysema if a defect occurs in the mucosal continuity of the subglottis, trachea, or hypopharynx. The degree of injury is determined by the direction and varying degrees of force.

**Open injuries** to the respiratory or digestive tracts are only slightly less dramatic than a tear in the carotid artery or internal jugular vein. The danger associated with opening one of the major veins is air embolism. If the volume of air aspirated is more than 10–20 ml, the result will be fatal. Emergency treatment of air embolism consists of immediate digital compression, flat body posture, and subsequent surgical repair.

Patients with **carotid artery haemorrhage** usually die at the time of injury due to haemorrhagic shock. Even with immediate digital compression and rapid surgical treatment, a high proportion of the survivors of open injuries to the common and internal carotid arteries have residual cerebral defects. Successful treatment depends on interdisciplinary management involving trauma surgeons, anaesthesiologists, and vascular surgeons.

**Injuries to the cervical spine** can present directly or indirectly. Indirect injuries are often accompanied by other injuries to the head and neck area, and lead to chronic damage to the senses of

hearing and balance. Diagnosis and therapy of injuries to the cervical spine always require interdisciplinary management involving otolaryngologists, orthopaedic and emergency surgeons, neurologists, and neurosurgeons. Patients with a suspected injury to the cervical spine should undergo specific investigation, starting with plain radiographs of the neck and moving on to CT and MRI. These injuries require multidisciplinary expertise from the fields of orthopaedics, emergency medicine and possibly neurosurgery.

#### **Cervical spine syndrome**

This is frequently diagnosed, and simply indicates that the patient has pain in the area of the spine. Possible causes of pain include muscular strain caused by physical stress or incorrect posture. Protrusion or dislocation of an intervertebral disk, or arthrosis and inflammation of the facet joints, can also cause this syndrome. Clinical symptoms can also be caused by exaggerated motion in single segments of the cervical vertebrae, due to abrasion of stiffened neighbouring segments. Additional clinical symptoms caused by disturbances of the cervical spine are acute cochleovestibular disorders with hearing difficulties, tinnitus, and vertigo.

Chiropractic measures and manual therapy form the basis of treatment for disorders of the cervical spine and include soft-tissue techniques to relax the muscles, passive mobilisation of individual joints, stretching of muscles, manipulations, and therapeutic use of local anaesthesia. All of these can be supplemented by physical measures (application of warmth), physiotherapy, and additional prescription of medications such as anti-inflammatory drugs, antirheumatics and muscle relaxants.

### 6.3.4 Vascular malformations

#### **Haemangiomas**

*Definition.* A haemangioma is a benign tumour made up of blood vessels.

*Clinical features.* The lesions tend to bleed spontaneously and in response to mild trauma. The most common site is the face and the nape of the neck (Figure 6.16, see also picture 3.21, Chapter 3). Two thirds are cutaneous haemangiomas, which are evident at birth. The remainder lie subcutaneously or deeper, with a particular tendency to penetrate the masseter muscle. They are mainly flat haemangiomas that grow rapidly in the first months of life but later tend to involute spontaneously.



### Aneurysms

*Clinical features.* A pulsating cervical swelling (“pseudotumour”), causing a hissing noise on auscultation, usually lies anterior to the sternocleidomastoid muscle. In rare cases, the cause is birth trauma or congenital anomalies. Acquired aneurysms are usually due to trauma or syphilis.

*Diagnosis* depends on palpation and auscultation of the neck and oropharynx. The diagnosis can be established using angiography and ultrasonography.

*Treatment.* Vascular surgery is performed when indicated.

**Malignant vascular tumours** in the neck include angiosarcoma, which is very uncommon, and hemangiopericytoma (a soft-tissue sarcoma arising from capillary pericytes), which is more frequent. The prognosis is poor, as the lesions are not usually resectable, tend to recur, and metastasise. They are resistant to radiotherapy and chemotherapy.

### Paraganglioma (carotid body tumour, chemodectoma, glomus tumours)

*Definition.* A paraganglioma is a rare neuroendocrine neoplasm that may develop at various body sites.

*Clinical features.* The tumour mass is usually painless and well-defined located in the carotid triangle. It grows slowly and usually causes no symptoms in approximately 70% of cases. In some patients it may cause a feeling of globus or dysphagia. About 20% of patients have Horner’s syndrome. The carotid sinus syndrome includes vertigo, tinnitus, and attacks of sweating in a small number of cases, particularly on turning the head. It is bilateral in 2–5% of patients.

*Pathogenesis.* The tumour of the carotid body consists of precapillary arteriovenous anastomoses, and contains a collection of chemoreceptor non-chromaffin paraganglion cells. These cells belong to a group with a similar appearance in the area of distribution of the vagus and glossopharyngeal nerves: tympanic, jugular, vagal, or periaortic glomus. The tumour may grow around the external or internal carotid artery narrowing the vessel. Malignant changes or metastases develop in 1–10% of patients.

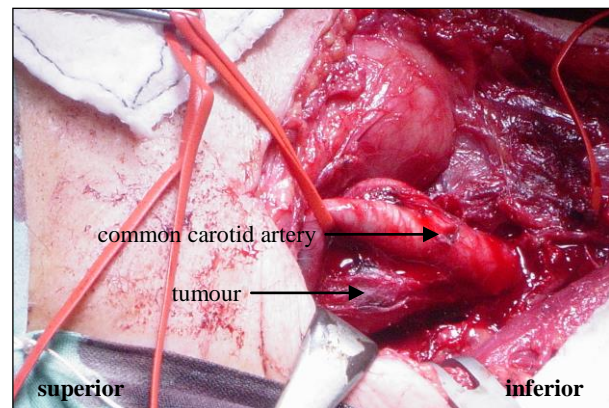
*Diagnosis.* Auscultation reveals a vascular bruit. Carotid angiography and Doppler ultrasonography are definitive. On MRI or CT, a typical egg-

shaped splaying of the carotid bifurcation, caused by a displacement of the internal and external carotid arteries, may be visible with large tumours. MRI (T1) may show a “salt and pepper” appearance — salt being blood products from haemorrhage and pepper being flow voids due to high vascularity.

Biopsy of a suspected carotid body tumour is contraindicated, due to the danger of severe bleeding. The diagnosis is based on clinical evaluation and appropriate imaging.

*Differential diagnosis* includes aneurysms, branchial cysts, neurogenic cervical tumours, lymph node metastases, and lymphoma.

*Treatment.* The carotid body tumour is radiopaque and should be treated surgically, as its future growth is unpredictable (Figure 6.18). Advances in vascular surgery have reduced the incidence of neurologic deficits and death. Embolisation significantly reduces intraoperative bleeding and is routinely advised before surgery.



**Figure 6.18**

Carotid body tumour, perioperative picture

## 6.3.5 Musculoskeletal defects

### Torticollis

*Definition.* Torticollis is a condition in which the neck is held to the affected side and the chin is



turned to the healthy side. It is almost always unilateral.

**Pathogenesis.** Muscular torticollis is the most common form. In congenital torticollis, it is assumed that there was intrauterine damage or birth trauma causing a muscle tear or haematoma, so the sternocleidomastoid muscle is shortened by fibrosis. All forms of torticollis in early childhood, if untreated, cause damage to the growth of the face and the base of the skull, or scoliosis of the cervical spine. The pathophysiology of acquired torticollis depends on the underlying disease process. Cervical muscle spasm causing torticollis can result from any injury or inflammation of the cervical muscles or cranial nerves from different disease processes.

**Diagnosis.** In muscular torticollis, the sternocleidomastoid muscle is thickened, usually in its lower third, and is hard and tender.

**Treatment.** Congenital muscular torticollis should be treated before the beginning of the second year of life (at the latest) if there has not been spontaneous remission or if conservative orthopaedic measures have proven unsuccessful.

---

**Klippel–Feil syndrome** is a congenital synostosis of the cervical spine, often accompanied by a high spina bifida. The ears are set low on the head, and the patient may have a hearing defect or be totally deaf.

**Oculoauriculovertebral dysplasia** involves the fusion or absence of a cervical vertebra, auricular tags, and middle ear anomalies, occasional unilateral hypoplasia or aplasia of the ascending ramus of the mandible, a coloboma of the iris, and an epibulbar dermoid.

**Cervical rib** is present in about 1% of the general population, usually arising from the seventh vertebra. Only approximately 10% of these cause symptoms, mainly compression of the brachial plexus or of the subclavian artery and vein: thoracic outlet compression syndrome. Surgery is only carried out when conservative measures have failed, particularly when there are severe neurologic signs or intermittent venous thrombosis.

---

### 6.3.6 Benign tumours

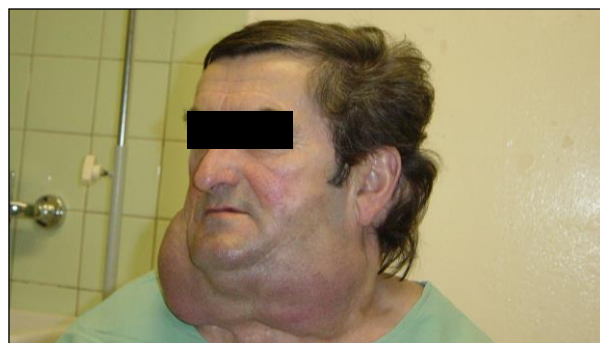#### Lipoma

**Definition.** Lipoma is a benign tumour caused by an overgrowth of adipose tissue cells.

**Clinical features.** Simple lipomas may arise in all parts of the neck and may be solitary or multiple. They are subcutaneous, grow slowly, and are clinically benign, causing few symptoms.

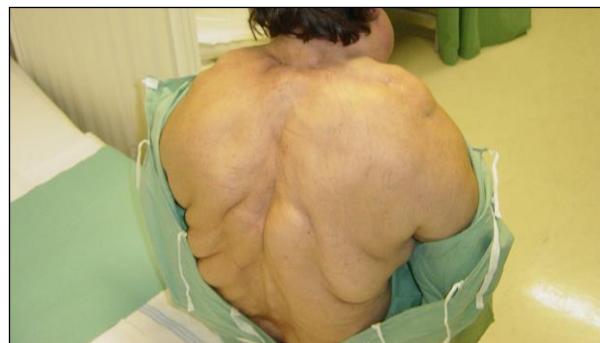**Lipomatosis of the neck (Madelung's disease)** mainly affects the nuchal region. The adipose tissue deposits may become so large that the patient has to hold the head forwards. On the neck, the tumours are typically occipital and notched in the midline, and there may be coexisting lipomas on the trunk (Figure 6.19). Anterior lipomatosis often begins as a double chin, grows slowly inferiorly in the neck, and tends to infiltrate the muscles.

**Treatment.** Simple lipomas are often removed for cosmetic reasons. Madelung's disease requires removal in one or more stages, as patients are unable to hold the head in the correct position and the condition interferes with the function of the neck.



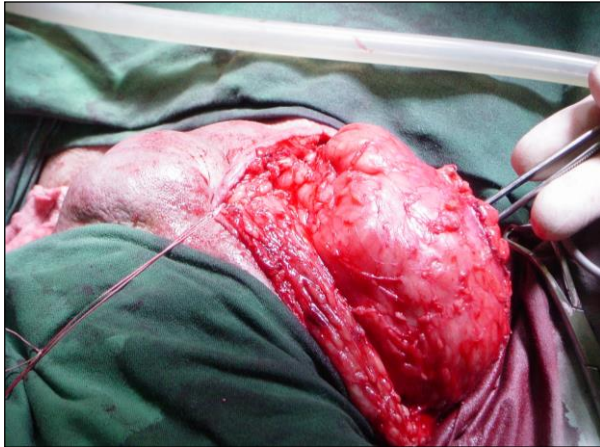**Figure 6.19a**

Madelung's disease – neck



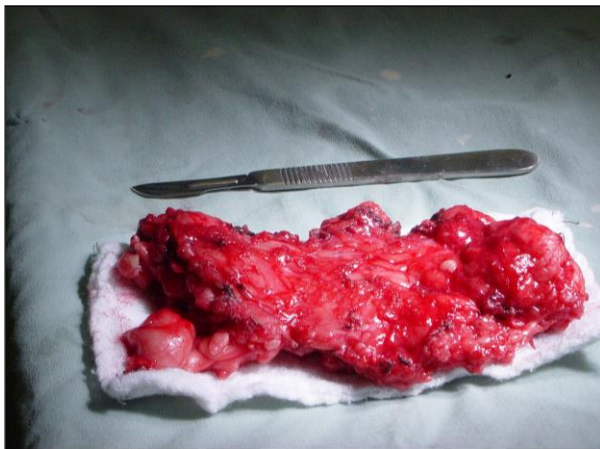
**Figure 6.19b**

Madelung's disease – view of the back



**Figure 6.19c**

Madelung's disease – perioperative picture



**Figure 6.19d**

Madelung's disease – specimen

### Neurinoma

*Definition.* Neurogenic tumours occur relatively often in the neck. Neurinoma is a benign tumour of the nerve sheath.

*Pathogenesis.* Neurinomas arise either from the autonomic nervous system or from the sheaths of peripheral nerves. Neurofibromas and schwannomas arise from the Schwann cells of the peripheral nerves.

*Clinical features.* Schwannomas are firm to palpation, which usually causes fairly severe pain. Their size varies from several millimetres to 20 cm, tumours arising from the vagus nerve that are mobile only in the horizontal plane. They grow slowly and only rarely cause neurologic deficits.

*Diagnosis* is provided by histology of tissue removed at surgery, if necessary.

The *differential diagnosis* includes paraganglioma, lymphoma, and metastases.

*Treatment* options are observation or surgical resection.

---

### Von Recklinghausen disease

This is a generalised neurofibromatosis. Solitary tumours are unusual. Twenty-five per cent of schwannomas occur in the head (vestibular neurinoma) and in the neck. The lesions in the neck arise from the sheaths of the glossopharyngeal, accessory, and hypoglossal nerves. The most frequent site of origin is the vagus nerve, and these lesions are known as parapharyngeal neurilemmomas.

---

## 6.3.7 Malignant tumours

### Lymphoma

*Definition.* Lymphoma is a tumour arising from lymphoid tissue.

*Epidemiology.* Currently, malignant lymphoma is the fifth most common malignant disease, after lung, breast, colon, and prostate cancer (20 per 100,000 population). Malignant lymphomas typical for the neck are **Hodgkin** or **Non-Hodgkin** lymphoma.

*Clinical features.* The generalised symptoms are often not very typical and consist of fatigue and generalised pruritus. Weight loss, night sweats, and fever are of prognostic and therapeutic significance (type B symptoms). The disease might be initially seen as localized, affected nodes might be found multifocally. At the time of diagnosis, the cervical lymph nodes are affected in approx. 70% of patients. The affected lymph nodes are indolent, firm, usually mobile, and tend to occur in groups. Pain is often noticed in these lymph nodes after consumption of alcohol. Spontaneous fluctuation in size is observed fairly commonly and can lead to an incorrect diagnosis.

*Diagnosis.* Ultrasound and FNA to start with; however, often the histological examination is the only way to establish a diagnosis and identify the tumour subgroups by immunohistology. PET-CT and bone marrow biopsy are used to complete staging.

*Treatment.* Treatment options consist of chemotherapy and radiotherapy. The disease should be treated in a haematology-oncology centre.

### Metastasis into cervical lymph nodes

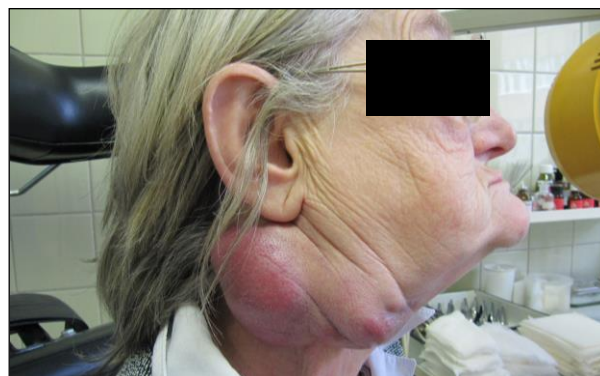*Definition.* Metastasis is the spread of a cancer from a primary malignant tumour in one organ to another organ not directly connected with it.

*Aetiology.* Lymph node metastases in the neck most frequently originates from squamous cell carcinoma (SCC) of the mucous membranes of the upper respiratory and upper alimentary tract (Figure 6.20). Rarely, metastases of other histological types can be found, as well as tumours from outside the head and neck area as Virchow's lymph node found in the left supraclavicular fossa indicative of the presence of abdominal cancer. A special form is cervical metastatic spread from a carcinoma of unknown primary.

#### Lymphogenic spread

Lymphogenic spread of an SCC requires invasive growth of a primary tumour, with penetration of tumour cells into the lymph vessels. These cells proceed into the next regional lymph node via drainage through afferent lymph vessels. Only a few tumour cells are able to evade the immune system and local influences. These usually proliferate in the subcapsular sinus of the lymph node, before proceeding to form a micrometastasis (<3 mm), but clinically obvious changes in the lymph node are not yet evident. With continued proliferation, a macrometastasis can develop, with extracapsular and extranodal expansion, as well as further lymphogenic or haematogenic spread. The probability of lymphogenic spread of cancer of head and neck correlates with its site and the various underlying densities of the lymph vessel network. This is why, for example, cancers of the nasopharynx and tonsils are associated with a higher incidence of metastases than carcinoma of the vocal cord. The probability of metastatic spread is influenced by several factors such as the size and depth of invasion of the primary tumour, its histological differentiation (grades I–IV), evidence of tumour cells in blood and lymphatic vessels, and tumour invasion into the perineural sheath. Contralateral or bilateral cervical metastatic invasion is observed particularly with a primary tumours located in the midline (e.g. nasopharynx, tongue base, palate, postcricoid region).

The presence of lymph node metastases in cancer of the head and neck (N+) reduces the 5-year survival rate down by 50%.



**Figure 6.20**

N3 metastasis

*Classification.* The extent of lymphogenic spread is classified using the TNM nomenclature. In addition to the T classification, which describes the extent of the primary cancer, and the M classification, which indicates either the absence or presence of distant metastases, there is also an N classification indicating the presence and extent of lymphogenic spread (see Appendix 1).

*Treatment* of cancer of the head and neck consists of surgery, radiotherapy, chemotherapy, or a combination of these. Treatment needs to encompass treating both the primary tumour and the metastasis.

**Surgery** may address the primary cancer as well as cervical metastasis. Neck dissection (ND) is most commonly used in the management of cancers of the upper aerodigestive tract. It is also used for malignancies of the skin of the head and neck area, the thyroid, and the salivary glands.

#### Neck dissection

ND consists of removal of the lymphatic and possibly non lymphatic structures depending upon the stage of the metastases.

**Radiation therapy** involves the delivery of high-energy ionising radiation to targeted tissues. Radiation doses can be delivered by different methods, including fractionation, hyperfractionation, accelerated fractionation, and intensity-modulated radiotherapy (IMRT). **Chemotherapy**



for SCC is used in combinations and involves the systemic administration of cytotoxic drugs that target rapidly dividing cells. Of them, cetuximab is an IgG1 chimeric antibody directed against the epidermal growth factor receptor (EGFR). Different regimens of **chemoradiotherapy** are often used as primary or postoperative treatment options. Other therapeutic methods for cancer of the head and neck include molecularly targeted agents, photodynamic, immune, gene, and targeted therapies against EGFR and HPV.

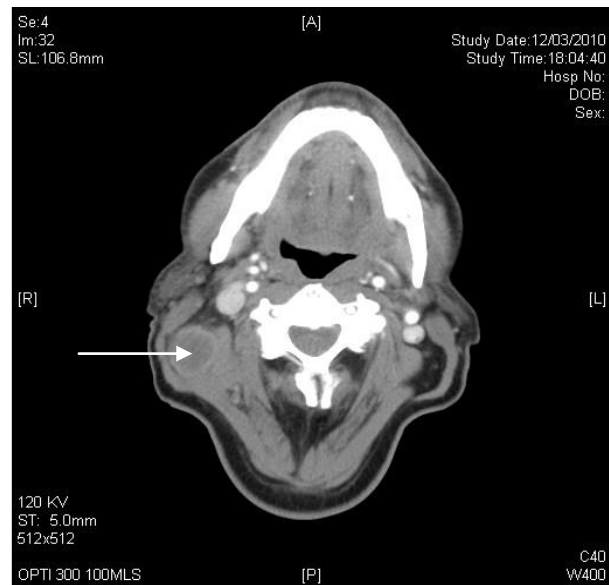
### Cancer from an unknown primary

*Definition.* In some patients with cancer of the head and neck the origin of the primary cancer is not known. This is known as cancer of unknown primary (CUP), carcinoma of unknown primary origin, or occult primary malignancy (carcinoma *e loco ignoto*).

*Clinical features.* A primary cancer is considered unknown only after a thorough investigation (including physical examination, imaging, and biopsies) has been completed. It has become an increasingly rare presentation as diagnostic tools have become more sophisticated and sensitive. Previously undetected primary carcinomas are now being discovered due to improved diagnostic techniques such as cross-sectional imaging, molecular diagnostics and investigations such as positron emission tomography (PET) scanning.

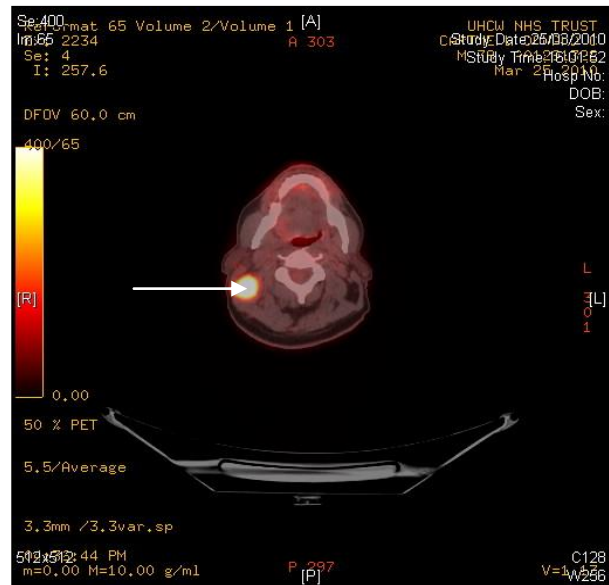
*Diagnosis.* Evaluation of possible CUP begins with a thorough history and physical examination. FNA of the mass of the neck provides a cytologic diagnosis, which may assist in finding the primary tumour, but 90% are attributable to SCC. Imaging studies can assist in localization of the primary site. CT is more cost-effective, but MRI has a higher sensitivity for small cancers, given its better soft tissue delineation. PET-CT may help to rule out primary sites below the diaphragm (Figure 6.21). The next step is to perform panendoscopy with biopsies whether or not the primary site was located on imaging. If no obvious primary cancer is visualised, bilateral tonsillectomy and guided biopsies from the nasopharynx and the base of the tongue are performed. The most common sites of CUP include the palatine tonsil and the base of the

tongue, followed by the nasopharynx and pyriform sinus. Each of these sites should at least be inspected with consideration of guided biopsies.



**Figure 6.21a**

Solitary metastasis to the neck (N2a); CT scan, axial plane



**Figure 6.21b**

Solitary metastasis to the neck (N2a); PET CT scan, axial plane

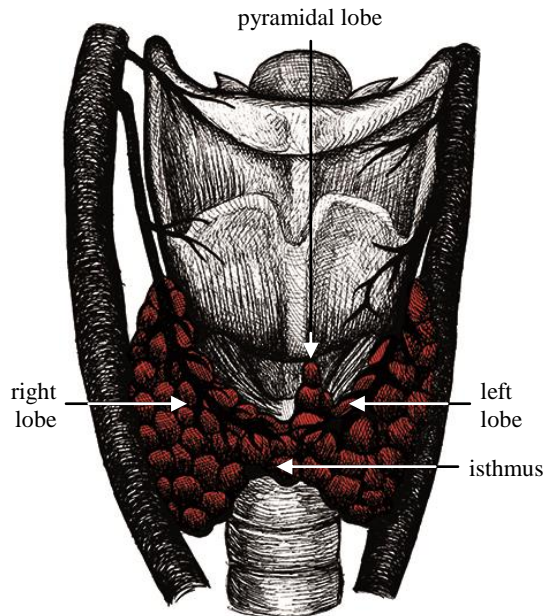




# 7 THYROID AND PARATHYROID GLANDS

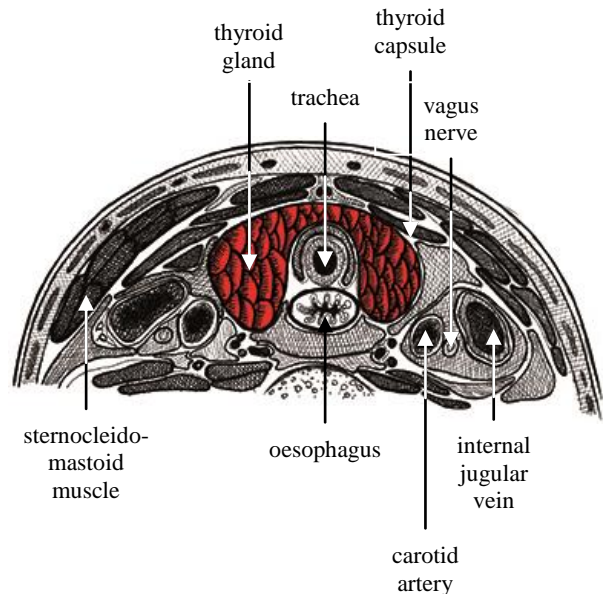
## 7.1 APPLIED ANATOMY

The **thyroid gland** consists of two lobes that lie lateral to the trachea, with a central midline isthmus connecting the lobes (Figure 7.1, Figure 7.2). The lobes are typically 5.0 cm in length. The most posterior extension of the lateral lobes – *the tubercles of Zuckerkandl* – maintains an important relationship to the recurrent laryngeal nerve. A *pyramidal lobe* is present in approximately 50% of the population and is usually connected to the isthmus or one of the lobes. Fibrous connections from the gland to the cricoid and thyroid cartilage and to the upper tracheal ring explain the mobility of the thyroid gland, which accompanies all movements of the larynx, particularly on swallowing. A normal size thyroid gland is not visible externally.



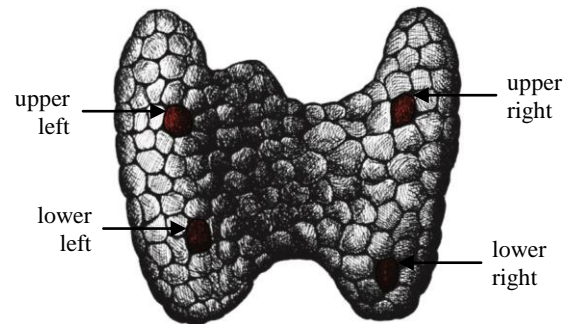
**Figure 7.1**

Thyroid gland – anterior view



**Figure 7.2**

Cross-section of the neck at the level of thyroid gland



**Figure 7.3**

Parathyroid glands in relation to the thyroid gland

– posterior view

The **parathyroid glands** can exhibit a wide variation in location secondary to migration patterns during embryogenesis. The *superior* parathyroids migrate a shorter distance than the inferior glands and are found at the posterior part of the middle third of the thyroid lobes.

Approximately 61% of *inferior* parathyroid glands are found inferior, lateral, or posterior to the lower pole of the thyroid gland (Figure 7.3).

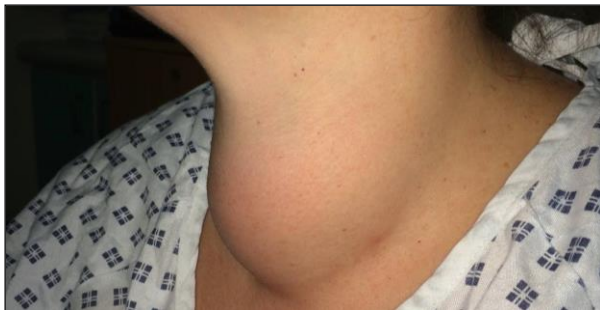### Goitre

The term “goitre” refers to the abnormal enlargement (diffuse or nodular) of the thyroid gland (Figure 7.4). The presence of a goitre does not necessarily mean that the thyroid gland is malfunctioning. A goitre indicates that there is a condition present which is causing the thyroid to grow abnormally. The term “goitre” has long been associated with the endemic type of thyroid disease that occurs in regions with low-iodine soils.

*Multinodular goitre* (MNG) is defined as an enlarged thyroid gland containing multiple nodules.

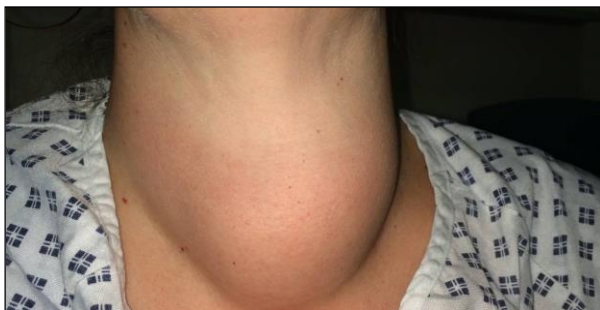The incidence of MNG when screened by ultrasound is between 10 and 20% and when using high-resolution US can be up to 70%. The incidence of occult malignancy within MNG is between 10 and 35% in surgical series. Younger patients and men have higher rates of malignancy, as do patients with a family history, prior radiation and those with signs of compressive or invasive disease.

Large *retrosternal goitres* can cause considerable compression and displacement of the trachea or oesophagus and can thus affect breathing and swallowing.



**Figure 7.4a**

Diffuse goitre – lateral view



**Figure 7.4b**

Diffuse goitre – anterior view

### Vascular supply

The thyroid is an extremely vascular gland. Meticulous control of bleeding during thyroid surgery is a must. Main blood supply comes from the paired superior and inferior thyroid arteries.

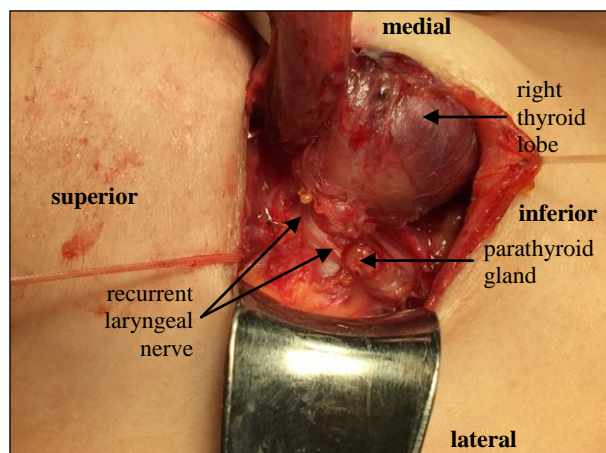
The *superior thyroid artery* is the first branch of the external carotid artery, and arches inferiorly to penetrate the upper pole of the gland. Shortly after its origin, the superior thyroid artery lies in fairly close relation at the level of this curve to the external branch of the superior laryngeal nerve. The *inferior thyroid arteries* arise from the thyrocervical trunk, curve medially at the level of the sixth cervical vertebra, and reach the lower pole of the thyroid gland after dividing into two, and occasionally more, branches. The recurrent laryngeal nerves are located on both sides, close to the inferior thyroid artery or its branches in the region of the lower pole of the thyroid gland. More than 25 anatomic variations of the relationship between the nerve and the artery have been described.

The thyroid gland is drained by *two or three large pairs of veins* – *superior, inferior and middle* – that anastomose within the parenchyma of the gland. The middle thyroid vein is present in approximately 50% of individuals. The thyroid veins typically drain into the internal jugular and brachiocephalic veins.

The *lymphatic drainage* of the thyroid gland travels with the venous and arterial vasculature of the gland. An intraglandular lymphatic network also exists, connecting the two lobes of the gland. This intraglandular network is subcapsular and significant in that it facilitates the spread of the tumour within the gland.

### Superior and recurrent laryngeal nerves

The relationship of the recurrent and superior laryngeal nerves to the the thyroid gland to is of major importance to the thyroid surgeon (Figure 7.5). Injury to these nerves can lead to dysphonia, dysphagia, and dyspnoea. Identifying and protecting the recurrent laryngeal nerves during surgery are of paramount importance.



**Figure 7.5**

Recurrent laryngeal nerve during thyroidectomy  
– right side

The vagus nerve exits the jugular foramen and descends in the neck within the carotid sheath. The *superior laryngeal nerve* (as one of its branches) divides into internal and external branches near the internal carotid artery. The internal branch of the superior laryngeal nerve provides sensation to the portion of the larynx above the vocal folds. The external branch of the superior laryngeal nerve provides motor innervation to the cricothyroid muscle. The cricothyroid muscle raises the pitch of voice by producing a rocking motion at the joints between the thyroid and cricoid cartilages, thus increasing the tension in the vocal ligaments by pulling the front of the cricoid upwards.

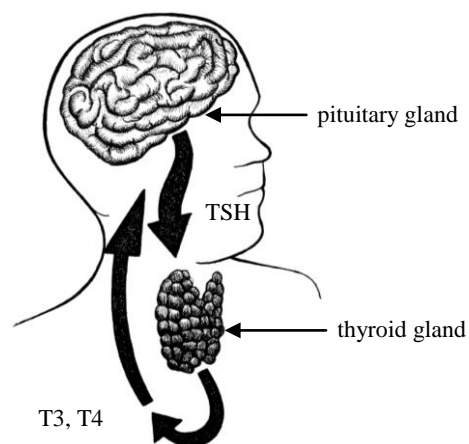
The *recurrent laryngeal nerves* (RLN) provide sensory, motor, and parasympathetic innervation. These nerves innervate all of the muscles of the larynx, except for the cricothyroid. There is some variation in the course of the RLN between the left and right sides. The right recurrent laryngeal nerve descends in the neck and loops around the subclavian artery, and then ascends in the neck to innervate the larynx. The left recurrent laryngeal nerve originates from the vagus in the superior mediastinum anterior to the aortic arch. It then usually ascends in the tracheoesophageal groove to innervate the larynx. A “nonrecurrent” recurrent laryngeal nerve can occur secondary to a vascular

anomaly, but it is rare, occurring in less than 1% of cases; it occurs more often on the right side.

## 7.2 THYROID AND PARATHYROID PHYSIOLOGY

The main functions of the *thyroid gland* are the regulation of metabolism, control of oxygen consumption, and regulation of heat, body growth, and mental development.

The thyroid gland produces two hormones — thyroxine, T4, and triiodothyronine, T3 — in which iodine is bound to the amino acid tyrosine. The hormone is bound mainly in follicular colloid and is stored as thyroglobulin. Hormone reserves are sufficient to last approximately two months without an active thyroid gland. Hormone secretion is activated by proteolytic enzymes of thyroid-stimulating hormone (TSH) and thyrotropin-releasing hormone (TRH) (Figure 7.6). Parafollicular cells (also called C cells) are located adjacent to the thyroid follicles and reside in the connective tissue. These are neuroendocrine cells and secrete hormone calcitonin, which counteracts the function of parathyroid hormone.



**Figure 7.6**

Thyroid function regulation



The sole purpose of the *parathyroid glands* is to control calcium in the blood within in a very tight range. In doing so, parathyroids also control how much calcium is in the bones and, therefore, how strong and dense the bones are. Calcium is the element that allows the normal conduction of electrical currents along nerves, and the brain works by fluxes of calcium into and out of the nerve cells. Calcium is also the primary element which causes muscles to contract.

## 7.3 EVALUATION

### Clinical examination

The consistency, fixation, and size of the thyroid swelling in the neck should be documented. The larynx and trachea should be examined for any deviation from the midline. A large asymmetrically enlarged cervical goitre would typically push the larynx and trachea to the contralateral side. In patients with a short neck, palpation of the cervical goitre is difficult. It is of note that with a recurrent goitre the physical examination typically underestimates extent of the goitre. The neck should also be examined for any cervical lymphadenopathy. It is imperative to examine the vocal cords endoscopically. Vocal cord palsy without previous surgery can be suggestive of the presence of invasive thyroid cancer until proven otherwise.

### Blood tests

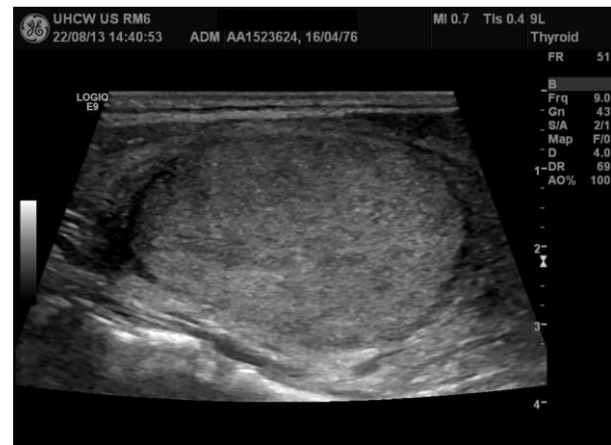The TSH assay is the screening test of choice for thyroid function. T3 and T4 are routinely used to test the thyroid function. Thyreoglobulin is used as part of the follow-up monitoring in thyroid cancer.

### Ultrasonography

Thyroid sonography must be performed in all patients with a known or suspected thyroid nodule.

Sonography is the primary imaging modality for the evaluation of the thyroid disease; it provides

the highest resolution and, therefore, is best able to detect and characterise thyroid abnormalities (Figure 7.7). The thyroid gland is imaged in its entirety both in transverse and longitudinal planes. The sonographer should also image the lateral cervical lymph nodes, particularly when malignancy is suspected (see Chapter 7.4.5).



**Figure 7.7**

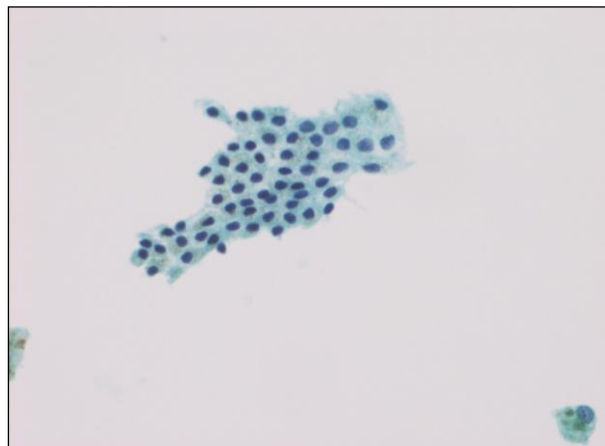
Solitary 4.5cm well-defined relatively isoechoic nodule;  
USS thyroid

Limitations of sonography include the high degree of operator dependency and the inability of sonography to detect retrotracheal and intrathoracic extension of an enlarged thyroid due to overlying air or bone. Ultrasound is also limited in detecting extension of thyroid malignancy into the adjacent trachea, oesophagus, or other adjacent soft tissue structures of the head and neck. Ultrasound may also be used to guide fine needle aspiration of nodular disease within the thyroid.

### Fine needle aspiration biopsy

Thyroid fine needle aspiration (FNA) biopsy is the only non-surgical method that can differentiate malignant and benign nodules in most, but not all, cases. The needle is placed into the nodule several times (preferably under ultrasound guidance) and cells are aspirated into a syringe. The cells are placed on a glass slide, stained, and examined by a pathologist. The nodule is then classified as non-

diagnostic, benign, suspicious, or malignant (Figure 7.8).



**Figure 7.8**

Fine needle aspiration biopsy – cytology specimen, Thy2 (Bethesda II), minimum six normal follicles visible, enlargement x60. Courtesy of Dr. Yen Yeo, Consultant Histopathologist, UHCW Coventry

#### Fine needle aspiration biopsy

There are two widely used classification systems available: the classification of the British Thyroid Association (Thy 1–5 classification) in the UK and the Bethesda System for Reporting Thyroid Cytopathology (Bethesda I–VI) of the National Cancer Institute in the USA.

**Non-diagnostic (Thy1, Bethesda I)** indicates that there are an insufficient number of thyroid cells in the aspirate and no diagnosis is possible. Overall, 5 to 10% of biopsies are non-diagnostic.

**Benign (Thy2, Bethesda II)** thyroid aspirations are the most common (as we would suspect since most nodules are benign) and consist of benign follicular epithelium with a variable amount of thyroid hormone protein (colloid).

**Atypic (Thy3a, Bethesda III)** aspirations show a certain degree of atypia.

**Suspicious of follicular neoplasm (Thy3f, Bethesda IV).** The thyroid cells on these aspirates are neither clearly benign nor malignant. Up to 30% of suspicious lesions are found to be malignant when these patients undergo thyroid surgery. These are usually follicular or Hurthle cell cancers.

**Suspicious of malignancy (Thy4, Bethesda V).** This group carries 60–75% risk of malignancy.

**Malignant (Thy5, Bethesda VI)** thyroid aspirations can diagnose the following thyroid cancer types: papillary, follicular variant of papillary, medullary, anaplastic, thyroid lymphoma, and metastases to the thyroid. Follicular carcinoma and Hurthle cell carcinoma cannot be diagnosed by FNA biopsy.

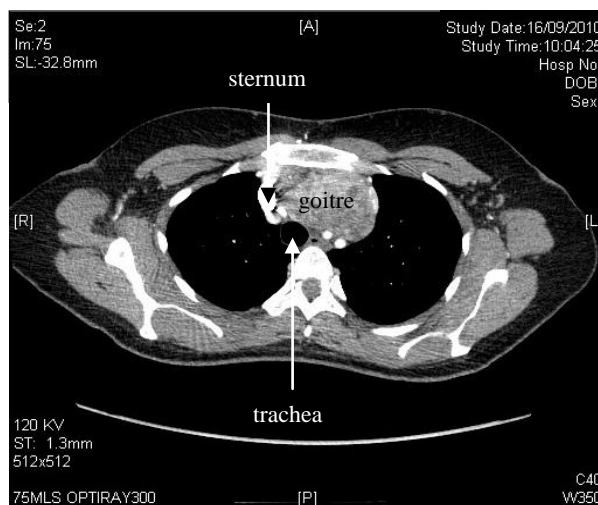
#### Cross-sectional imaging

CT and MRI provide important adjunctive anatomic information in select clinical scenarios, especially in assessing advanced thyroid carcinomas at presentation as well as a retrosternal or intrathoracic goitre (Figure 7.9) and the evaluation of recurrent thyroid cancer following thyroidectomy (Figure 7.10). These modalities may play a critical role in the detection of lymph node metastases, especially nodal metastases in areas poorly assessed by ultrasound (retropharynx and mediastinum), and are critical in evaluating the extension of thyroid disease to adjacent tissues in the neck. Specifically, invasion of the paraspinal musculature, oesophagus, trachea/larynx, and jugular vein may be assessed.

#### CT, MRI

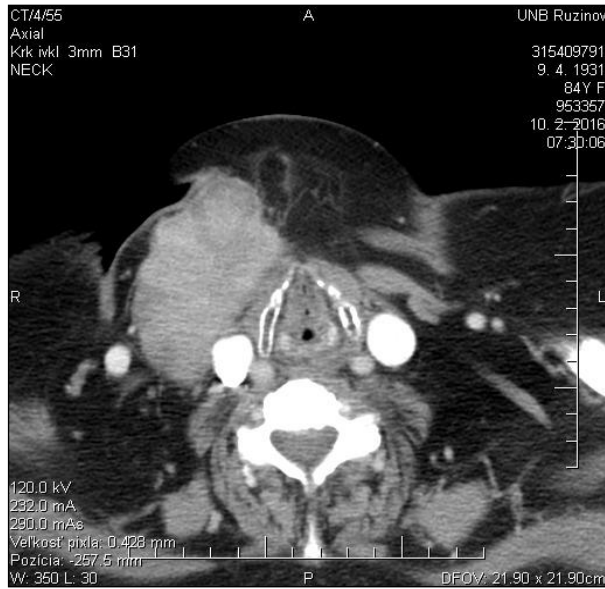The normal thyroid gland has a density of 80 to 100 Hounsfield units on CT due to its iodide content. The intravenous injection of iodinated contrast material usually diffusely increases the density of the gland. Although iodinated contrast material may provide additional information about lesions within the gland, because the contrast contains iodine it will alter radioactive iodine uptake measurements for up to 6 weeks following the study. Therefore, in patients in whom nuclear scintigraphy is also going to be performed, contrast should not be administered.

Magnetic resonance imaging is performed with an anterior neck coil centred over the thyroid gland, which provides high-quality images with the best soft tissue resolution. Nodules as small as 4 mm may be detected.



**Figure 7.9**

Retrosternal goitre; CT scan, axial plane



**Figure 7.10**

Papillary thyroid cancer, neck recurrence; CT scan, axial plane

### Scintigraphy

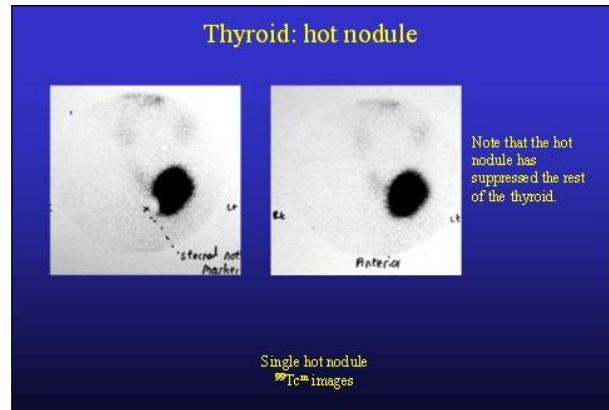
Scintigraphy is a nuclear medicine diagnostic method using a very small quantity of radioactive agent, known as a radiotracer, which attaches itself specifically to the organ to be investigated.

The primary role of scintigraphy is in the evaluation of patients with abnormal thyroid function tests, particularly hyperthyroidism. Scintigraphy is able to demonstrate if the cause of hyperthyroidism is a diffuse process such as Graves disease or an autonomously functioning nodule. Scintigraphy of a focal thyroid mass in euthyroid patients may be used to determine whether a lesion is functioning (extremely low incidence of malignancy) or nonfunctioning “cold”, a feature carrying a reported risk of malignancy ranging from 8 to 25% (Figure 7.11).

Morphologic detail of the thyroid gland is obtained using technetium-99m (Tc-99m) pertechnetate, or iodine 123 (I-123). The normal thyroid gland shows homogeneous radionuclide uptake and distribution. The isthmus may demonstrate slightly less activity than the thyroid lobes.

Iodine 131 is used in both the evaluation and treatment of patients with thyroid cancers that

concentrate iodine. It is particularly useful in the follow-up of patients after thyroidectomy to evaluate for residual thyroid tissue in the operative bed as well as to assess for recurrent or distant metastatic disease.

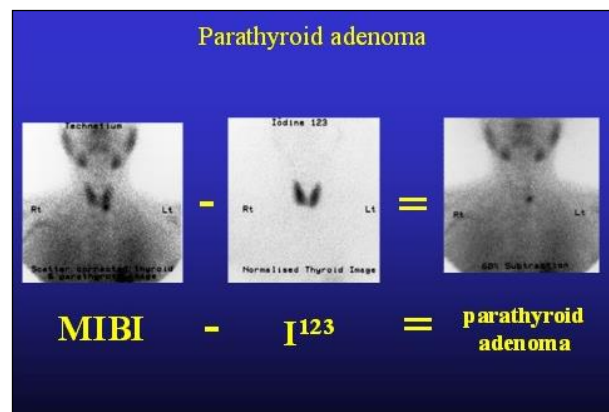


**Figure 7.11**

Hot nodule in the left lobe of thyroid; thyroid scintigraphy. Courtesy of Dr. Olu Adesanya, Consultant Radiologist, UHCW Coventry

### Parathyroid imaging

The vast majority of primary hyperparathyroidism results from single-adenoma disease, with the remaining cases resulting from four-gland hyperplasia.



**Figure 7.12**

Left lower parathyroid adenoma; MIBI scan, subtraction technique. Courtesy of Dr. Olu Adesanya, Consultant Radiologist, UHCW Coventry

Parathyroid imaging methods have been evolving. Normal parathyroid glands are not detectable with any imaging modality due to the small size and structural patterns similar to adjacent thyroid tissue. However, when biochemical evidence of hyperparathyroidism exists, *ultrasound* can localise parathyroid adenoma. Localisation of hyperfunctional glands has led to the development of directed surgery and, ultimately, minimally invasive parathyroidectomy. *Nuclear medicine techniques (Sestamibi, SPECT)* focus on localisation rather than diagnosis (Figure 7.12).

## 7.4 THYROID AND PARATHYROID DISEASES

### 7.4.1 Thyroid dysfunction

The thyroid gland can be producing too much hormone (hyperthyroidism), too little hormone (hypothyroidism), or the correct amount of hormone (euthyroidism).

#### **Hypothyroidism**

*Definition and aetiology.* *Primary hypothyroidism* is spontaneous and is due to loss of the thyroid after total or subtotal resection without subsequent hormonal replacement, congenital hypoplasia or aplasia, ectopic thyroid in children, or disordered synthesis of thyroid hormone.

*Secondary hypothyroidism* is caused by the absence of TSH stimulation from the pituitary gland.

*Clinical features.* General symptoms include mental motor inactivity, increased need for sleep, dry scaly skin, and myxoedema. Specific ear, nose, and throat symptoms include a rough voice, hoarseness, a deep, monotonous voice, and slow speech with a nasal twang. Symptoms also include difficulty in swallowing and globus sensation, particularly in the presence of goitre. Deafness and dizziness may occur in prolonged hypothyroidism.

*Diagnosis* is based on thyroid tests results.

*Treatment.* Hypothyroidism can be adequately treated with a constant daily dose of levothyroxine (LT4). It is imperative to take the thyrodine first thing in the morning and at least half an hour before breakfast.

---

#### **Hypothyroidism in children**

Hypothyroidism is the most common endocrine disorder in children after diabetes mellitus. In addition to aplasia and ectopia, Pendred syndrome includes sensorineural deafness combined with disorders of iodine metabolism, leading to the formation of a goitre.

---

#### **Hyperthyroidism**

*Definition.* Hyperthyroidism is simply an overactive thyroid.

*Aetiology.* The most common forms of hyperthyroidism include diffuse toxic goitre (Graves–Basedow disease), toxic multinodular goitre (Plummer disease), and toxic adenoma (see Chapter 7.4.5).

*Clinical features* include loss of weight, tremor in the fingers, fluttering of the eyelids, tremor of the tongue, attacks of sweating, and sleeplessness. Goitre, tachycardia, and exophthalmos are classic symptoms of primary thyrotoxicosis. However, thyrotoxicosis demonstrating only one of these symptoms or mild symptoms is more common.

---

#### **Endocrine orbitopathy**

Endocrine orbitopathy with exophthalmos, conjunctivitis, swelling of the lids, chemosis, periocular oedema, and oculomotor paralysis can occur on one or both sides and is most often accompanied by thyrotoxicosis. However, exophthalmos also occurs without evidence of abnormal thyroid gland function. Endocrine orbitopathy is caused by increased volume in the retrobulbar tissues, probably stimulated by immunologic processes or by abnormal levels of thyrotropic hormone. Malignant exophthalmos leads to blindness if untreated. In addition to specific treatment of the thyroid disorder and medical treatment of exophthalmos with cortisone, transnasal endoscopic decompression of the orbit may also be necessary.

---

*Diagnosis* is based on palpation of a diffuse or nodular goitre, scans, radioiodine studies, and blood tests with hormone determination. Orbitopathy is imaged on CT.



*Treatment.* There are several ways to treat thyrotoxicosis. Medical treatment with antithyroid drugs can have very rare but serious adverse effects, including agranulocytosis or aplastic anaemia. Another option is radioactive iodine, which destroys the thyroid tissue. The third option is surgical (total thyroidectomy).

#### **Thyroid storm**

Thyroid storm is a rare and potentially fatal complication of untreated hyperthyroidism. Approximately 1–2% of patients with hyperthyroidism progress to thyroid storm. It is a state of severe thyrotoxicosis, in which there is an exaggeration of the manifestations of hyperthyroidism. It is a life-threatening condition. Thyroid storm usually occurs in the setting of undiagnosed or inadequately treated thyrotoxicosis and an added precipitating event such as surgery (both thyroid and nonthyroid), infection, trauma, iodinated contrast dyes, and radioiodine therapy. The condition causes high fever (39°C), tachycardia, cardiac arrhythmia, thromboembolic events, congestive heart failure, confusion, agitation, psychosis, extreme lethargy, coma, diarrhoea, nausea and vomiting, and abdominal pain.

### **7.4.2 Parathyroid adenoma**

*Definition.* Parathyroid adenoma is a benign tumour of the parathyroid gland and the most common disorder of the gland. The gland increases in size and produces PTH in excess.

*Aetiology* is unknown.

*Clinical features and diagnosis.* In most cases, patients are unaware of the tumours, and they are found when routine blood test results have elevated blood calcium and PTH levels. In more serious cases, the bone density will diminish and kidney stones can form. Other non-specific symptoms include depression, muscle weakness, and fatigue. A specific test for parathyroid adenoma is sestamibi parathyroid scintigraphy, the sestamibi scan, which reveals the presence and location of pathological parathyroid tissue.

*Treatment.* Every effort is made to medically treat or control these conditions prior to surgery. These efforts include avoiding calcium-rich foods, proper hydration, and medications to avoid osteoporosis. Surgery is the only cure for parathyroid adenomas; it is successful more than

90% of the time. The standard of treatment of primary hyperparathyroidism was formerly a surgical technique called bilateral neck exploration, in which the neck was opened on both sides, the parathyroids were identified, and the affected tissue was removed. Now, unilateral exploration is more common (see Chapter 10.12).

### **7.4.3 Congenital abnormalities**

The most common congenital thyroid disorder is congenital hypothyroidism. We will, however, concentrate on diseases with surgical impact.

#### **Lingual thyroid**

*Definition.* The lingual thyroid is a type of ectopic thyroid localised at the base of the tongue.

Although rare, it is the most common location for functioning ectopic thyroid tissue. It occurs more commonly in women than in men, and is frequently associated with a lack of a normal cervical thyroid in 70% of cases.

*Clinical features.* It can become symptomatic if it enlarges by provoking dysphagia, dysphonia, dyspnoea, or a sensation of choking. A small percentage of lingual thyroids will be malignant.

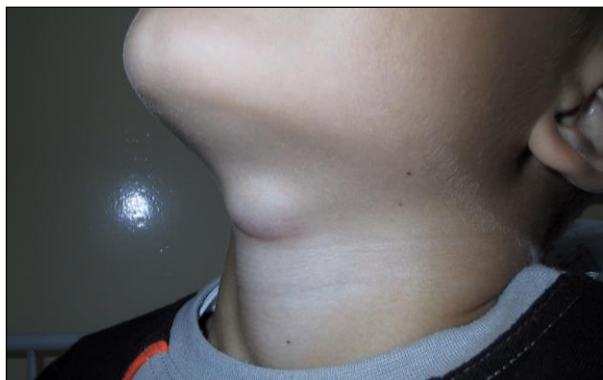*Diagnosis* is usually made in an asymptomatic patient with the incidental discovery of a mass in the base of the tongue. The diagnosis is made with radioisotope scanning or ultrasound, and it should be suspected whenever a mass is found in the foramen cecum area of the tongue.

*Treatment.* Suppressive therapy with exogenous thyroid hormone should be tried first in order to decrease the size of the gland. In case of airway obstruction/dysphagia, surgery might be indicated.

#### **Thyroglossal duct cyst**

*Aetiology.* The thyroglossal duct (see also Chapter 6.3.1) is usually obliterated during embryonic life by the end of the fifth week of development, but it can persist as a cyst or a draining sinus tract into adulthood. A cyst or a sinus tract can develop anywhere along the course of the descent of the thyroid, and occurs secondary to persistence or incomplete obliteration of the thyroglossal duct.

Anomalies of the thyroglossal duct are the most common congenital neck masses in children and young adults.



**Figure 7.13**  
Thyroglossal cyst

*Clinical features.* The lesions usually appear in the midline or just off the midline between the hyoid bone and the isthmus of the thyroid (Figure 7.13).

A cyst or sinus tract may not be apparent until it becomes infected or spontaneously ruptures, usually after an upper respiratory tract infection.

*Treatment.* The standard treatment is the Sistrunk procedure, with recurrence rates of 4–5% (see Chapter 10.10). Thyroid carcinoma can develop within a cyst, especially if the individual has received low-dose irradiation to the head and neck region in the past; thus, all specimens should undergo histologic examination.

#### 7.4.4 Thyroiditis

Thyroiditis is a broad category of inflammatory diseases (not an infection) of the thyroid gland. Several types of thyroiditis exist, and the treatment is different for each. The different types of thyroiditis are similar only in relation to the histological findings. The aetiology is very different and ranges from infectious to autoimmune causes (Table 7.1). Acute and giant cell thyroiditis is very rare. Subacute disease is found mainly in females.

**Table 7.1** Inflammation of the thyroid gland (according to Behrbohm et al., Ear, Nose, and Throat Diseases, Thieme, 2009)

	<b>Acute thyroiditis</b>	<b>Subacute thyroiditis</b>		<b>Chronic thyroiditis</b>
		Giant cell thyroiditis	Hashimoto thyroiditis	Riedel thyroiditis (chronic fibrous thyroiditis)
Symptoms	Swelling, pain, redness, fever	Fever, pain, long term of overlying skin, fever course	Relatively few symptoms, myxoedema after years if untreated	Hard thyroid swelling; infiltration of surrounding tissue with compression of trachea
Pathogenesis	Viral infection or by extension of cervical bacterial infection	Paramyxovirus infection, genetic predisposition	Autoimmune disease, genetic factors	Arteritis of the gland and the periglandular tissue, followed by sclerosis and fibrosis
Diagnosis	Ultrasound, CT scan	Palpation, ultrasound, serology	Immunological evidence of microsomal antibodies	Biopsy shows severe inflammatory infiltrate, especially in the periglandular tissue
Treatment	Antibiotics, steroids, thyroid hormones	Nonsteroidal anti-inflammatory drugs, corticosteroids in severe cases	Replacement of thyroid hormones	Hemithyroidectomy (to reduce the compression syndrome)

## 7.4.5 Benign thyroid nodules and thyroid cancer

The lifetime risk of developing a palpable thyroid nodule is estimated to be 5–10%, affecting more women than men. Autopsy studies have incidentally found thyroid nodules — “incidentalomas” — in 30–60% of the general population. Roughly 4% of palpable thyroid nodules are malignant; the remainder represent a variety of benign diagnoses, including colloid nodules, degenerative cysts, hyperplasia, thyroiditis, or benign neoplasms.

Management of a thyroid nodule is based on the clinician's ability to distinguish the more common benign diagnoses from malignancy in a reliable manner. Further management depends on ultrasound features together with FNA and other factors.

### Management of thyroid nodule

The most important aspects of the diagnostic evaluation of solitary thyroid nodules include thorough history and physical examination, measurement of the serum TSH level, ultrasound, and FNA of the nodule.

**Ultrasound** features such as microcalcifications, hypoechoic, increased nodular vascularity, infiltrative margins, and a taller-than-wide shape on the transverse view are considered to be suspicious of cancer. This is now incorporated into the U1 – U5 scoring system for assessing malignancy and guiding FNA recommended by the British Thyroid Association guidelines published in 2014. FNA should be performed in U3, U4 and U5 lesions.

Table 7.2 outlines the signs that differentiate benign from malignant nodules. These signs should be used to guide the decision as to whether or not to carry out an FNA based on the likelihood of malignancy in a nodule. The signs are grouped to identify: a normal thyroid gland (U1), benign nodule (U2), equivocal/indeterminate nodule (U3), suspicious nodule (U4) and malignant nodule (U5).

**Table 7.2** U1 – U5 ultrasound classification of thyroid nodule

	Classification	US feature
U1	Normal	<ul style="list-style-type: none"> <li>• no nodule visible</li> </ul>
U2	Benign	<ul style="list-style-type: none"> <li>• cystic change +/- ring down sign (colloid)</li> <li>• halo, hyper-/iso-echoic</li> <li>• micro-cystic/spongiform</li> <li>• peripheral egg shell calcification</li> <li>• peripheral vascularity</li> </ul>
U3	Indeterminate/ equivocal	<ul style="list-style-type: none"> <li>• homogenous, iso-/hyper-echoic, solid, halo (follicular lesion)</li> <li>• hypo-echoic, equivocal echogenic foci, cystic change</li> <li>• mixed/central vascularity</li> </ul>
U4	Suspicious	<ul style="list-style-type: none"> <li>• disrupted peripheral calcification, hypo-echoic</li> <li>• lobulated outline</li> <li>• solid, hypo-echoic</li> <li>• solid, very hypo-echoic</li> </ul>
U5	Malignant	<ul style="list-style-type: none"> <li>• solid, hypo-echoic, lobulated/irregular outline</li> <li>• micro-calcification (papillary carcinoma)</li> <li>• solid, hypo-echoic, lobulated/irregular outline, globular</li> <li>• calcification (medullary carcinoma)</li> <li>• intra-nodular vascularity</li> <li>• shape (taller &gt; wide)</li> <li>• characteristic-associated lymphadenopathy</li> </ul>

**Fine needle aspiration biopsy (FNA).** Subsequent management of a solitary thyroid nodule largely depends on the diagnosis from FNA results (see also Chapter 7.3 and Table 7.3), together with ultrasound features.

**Other methods** as *elastography* or examination of *molecular markers* might be of use in the future.

**Other factors** also need to be taken into consideration in risk assessment of a thyroid nodule (Table 7.4).

Even in the case of benign diagnosis, thyroid surgery is reasonable for patients with symptoms, such as dysphagia and discomfort, or concerns about cosmesis.

**Table 7.3** Management of the thyroid nodule based on the FNA results

FNA result	Suggested action	
Thy1	Bethesda I	Repeat FNA
Thy2	Bethesda II	Routine follow-up or discharge if no other concerns
Thy3a	Bethesda III	Other factors (ultrasound, size of the nodule, patient concerns, age, gender) may help to decide between surgery and repeat FNA
Thy3f	Bethesda IV	Diagnostic hemithyroidectomy
Thy4	Bethesda V	Hemithyroidectomy or total thyroidectomy
Thy5	Bethesda VI	Total thyroidectomy +- level VI neck dissection

**Table 7.4** Risk factors in assessment of the thyroid nodule

Factors	Benign	Malignant
Age	20 – 40	<20 or >40
Gender	Female	Male
Previous radiation	No	Yes
Dysphagia	No	Yes
Hoarseness	No	Yes
Airway obstruction	No	Yes
Mass consistency	Firm or cystic	Hard
Extra thyroid mass	No	Yes
Vocal cord paralysis	No	Yes
Fixation	No	Yes
Pain and tenderness	Yes	No
Hyperthyroidism	Yes	No
<sup>131</sup> I scan	Hot or warm	Cold

**Multinodular goitre (MNG)**

*Definition.* Based on the function there are two forms of multinodular goitre: nontoxic and toxic. A toxic nodular goitre contains autonomously functioning thyroid nodules and is the most common cause of hyperthyroidism (Plummer disease).

*Aetiology.* The exact causes of thyroid nodules or multinodular goitres are unknown. In general, the development of goitre is due to a complex mix of genetic and environmental factors. Iodine deficiency as a cause of goitre is rare in North America and most of Europe. However, even in

areas of iodine deficiency, most patients do not develop goitres.

*Clinical features.* Nontoxic goitres usually grow very slowly over decades without causing symptoms. Most patients with toxic nodular goitre present with symptoms typical of hyperthyroidism, including heat intolerance, palpitations, tremor, weight loss, hunger, and frequent bowel movements.

*Treatment.* Non-toxic goitre without evidence of rapid growth or obstructive symptoms (e.g. dysphagia, stridor, cough, shortness of breath) does not require treatment. The optimal treatment of toxic nodular goitre remains controversial. Unlike Graves disease, nodular toxic goitre is not an autoimmune disease and rarely, if ever, remits. Therefore, patients who have autonomously functioning nodules should be treated definitely with radioactive iodine or surgery.

**Thyroid cancer**

*Definition.* Thyroid cancer is a malignant growth originating from follicular or parafollicular thyroid cells.

*Epidemiology.* Despite the relatively low incidence of thyroid cancer, it has increased in frequency over the years. Solitary nodules are most likely to be malignant in patients older than 60 years and in patients younger than 30 years. Thyroid nodules are associated with an increased rate of malignancy in males. Rapid growth of a nodule may suggest malignancy.

*Clinical features.* Thyroid carcinoma most commonly manifests as a painless, palpable, solitary thyroid nodule. Patients or physicians discover most of these nodules during routine palpation of the neck, and some are found incidentally during unrelated thyroid or other imaging of the head and neck.

There are four basic histological forms of thyroid carcinoma: papillary, follicular, medullary, and anaplastic or undifferentiated.

The thyroid can also rarely be the site of tumours such as lymphoma, teratoma, malignant mela-



noma, or sarcoma, and it may also be a depository of secondary carcinoma. The tendency of laryngeal carcinoma to directly invade the thyroid gland through direct penetration of the thyroid lamina is well known.

**Differentiated thyroid cancer (DTC).** Papillary and follicular cancer are also called differentiated thyroid cancers. Together, they make up 95% of cases of thyroid cancer.

**Papillary carcinoma.** The predominance of papillary carcinoma agrees within most series; the incidence is approximately 65 to 90%. Papillary carcinoma makes up almost all of the thyroid cancers in children. It is the most common and the most benign-behaving malignancy of the thyroid gland. Although early metastases to cervical lymph nodes are common, the progress of the disease is slow, with 5- to 10-year survival rates in the 90 to 95% range. Even with distant metastases the progression is protracted. The tall cell variant of papillary carcinoma is more aggressive with increased risk of involvement of mediastinal lymph nodes.

**Follicular carcinoma.** This is the second most common thyroid malignancy. It tends to be of a firmer consistency than the papillary cancer and less curable.

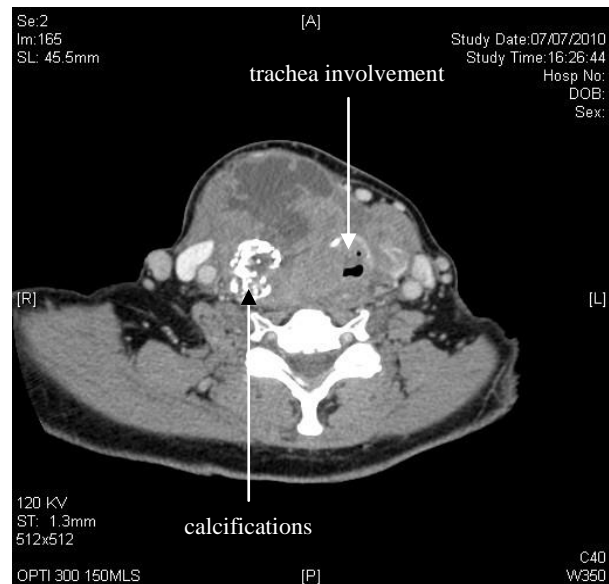
**Medullary carcinoma.** Medullary carcinoma makes up approximately 5 to 10% of all thyroid malignancies, arising from parafollicular calcitonin-producing C cells. Medullary carcinoma is a hard, dense, solid tumour. Unlike the differentiated malignancies, it is generally not well encapsulated and is locally infiltrative. One of its characteristic features is gross angioinvasion. The tumour has a strong familial tendency and is associated with several other tumour states and endocrinopathies. The tumours may occur spontaneously as part of a genetic syndrome. Metastases to lymph nodes and through the bloodstream to distant site are common. Over half of the cases demonstrate cervical metastases on first presentation. The tumours are also highly locally invasive, extending into the trachea, larynx and oesophagus. The most consistent laboratory test for following patients with medullary cancer is the monitoring of calcitonin levels.

### MEN syndromes

The multiple endocrine neoplasia (MEN) syndromes of the type 2 variety are autosomal dominant syndromes that are responsible for the development of 75% of cases of medullary carcinoma. MEN2A is characterized by medullary carcinoma of the thyroid, pheochromocytoma, and parathyroid chief cell hyperplasia or adenoma. MEN2B is composed of medullary carcinoma, pheochromocytoma, multiple ocular and gastrointestinal ganglioneuromatosis, and skeletal abnormalities.

In contrast to the sporadically appearing tumours, the MEN type 2 tumours tend to present in childhood or under the age of 20. These tumours are also usually bilateral compared with the unilaterality characteristic of the sporadic tumours.

**Anaplastic carcinoma.** The incidence of undifferentiated carcinoma varies from 1 to 15%. The average age of presentation is 60 to 65 years of age. A preexisting enlarged or nodular gland is almost always present (Figure 7.14). It is a highly aggressive neoplasm with a poor prognosis. Local invasion into the opposite lobe and into adjacent structures is the rule. Most of the patients die of their disease in less than 6 months.



**Figure 7.14**

Anaplastic carcinoma of thyroid gland, involvement of trachea; CT scan, axial plane

**Treatment.** DTC is treated by total thyroidectomy (completion thyroidectomy in the presence of a previous partial procedure). There is recent

evidence to suggest that T1 and T2 DTC patients with low risk may be treated with hemithyroidectomy only. Dissection of lymphatic nodes in level VI has controversial indications; it is indicated in certain clinical situations (involved nodes or advanced primary cancers staged as T3 and T4). Postoperatively, thyroid hormones are replaced in order to suppress TSH release. According to the American Thyroid Association guidelines, some cancers may need postoperative radioiodine treatment. Selective compartmental neck dissection is performed in the case of lymph nodes present in levels I–V.

The standard of care for all patients with *medullary thyroid cancer* is total thyroidectomy with prophylactic or therapeutic level VI neck dissection with or without postoperative radiotherapy.

*Anaplastic carcinoma* has a very bad prognosis; early, aggressive surgery coupled with external irradiation and chemotherapy may be the only possible means of salvaging any afflicted patients. Unfortunately, even the most radical local treatment on these tumour usually fails because of distant metastases. End-of-life issues, comfort, and care options are essential considerations during initial treatment planning.

External beam radiotherapy may be considered for patients with gross residual disease after surgery and for those with distant metastasis in any type of thyroid cancer.

## 7.5 THYROID AND PARATHYROID SURGERY

Nodulectomies, wedge resections or subtotal thyroidectomy are of historical interest only and should be avoided.

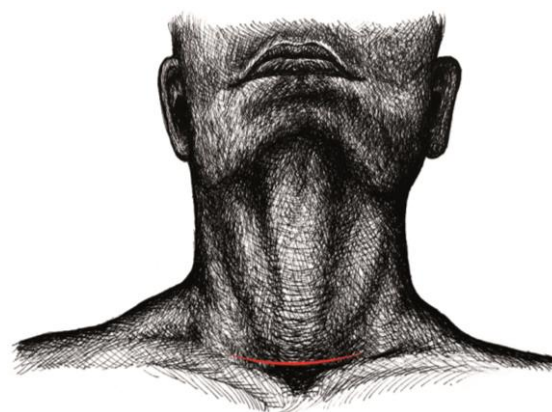
**Hemithyroidectomy** is defined as the removal of one thyroid lobe and the thyroid isthmus. The technique described in Chapter 10.11 refers to a capsular dissection of a thyroid lobe.

**Total thyroidectomy** involves the surgical removal of all of the thyroid gland.

In **near-total (hemi) thyroidectomy**, one or both lobes are removed, except for a small amount of thyroid tissue (on one or both sides) in the vicinity of the recurrent laryngeal nerve entry point. This procedure however is suboptimal and total or hemithyroidectomy should be performed instead.

**Completion thyroidectomy** is a term being used for removal of the second lobe of the thyroid gland in the presence of previous hemithyroidectomy.

A thyroid **isthmusectomy** is sometimes performed when just the isthmus requires removal for a nodule in the isthmus. Most of these procedures are performed through typical Kocher incision (Figure 7.15).



**Figure 7.15**  
Kocher incision

**Parathyroid surgery.** Although a comprehensive 4-gland parathyroid exploration has traditionally been the standard, operating time can be decreased by performing targeted parathyroid surgery (see Chapter 10.12).

**The minimally invasive video-assisted thyroidectomy** technique was developed by Miccoli at the University of Pisa. The approach uses endoscopes and endoscopic instrumentation through a 20mm incision. This approach has limited indications.

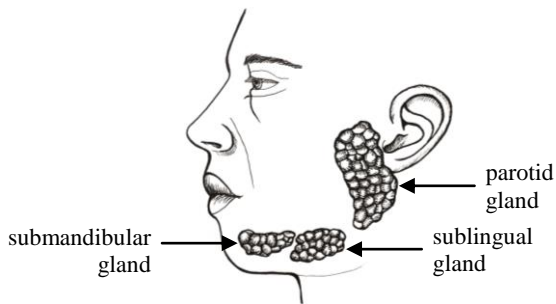
**Robotic-assisted thyroidectomy** can be used to avoid a neck incision for thyroidectomy, and transaxillary approaches have been described. Despite achieving a better cosmetic result without an incision on the neck, the technique is more invasive with a wider dissection necessary. A total thyroidectomy through a single-sided transaxillary incision provides significant technical difficulties.



## 8 SALIVARY GLANDS

### 8.1 APPLIED ANATOMY

There are three main paired salivary glands: the parotid gland, the submandibular gland and the sublingual gland (Figure 8.1).



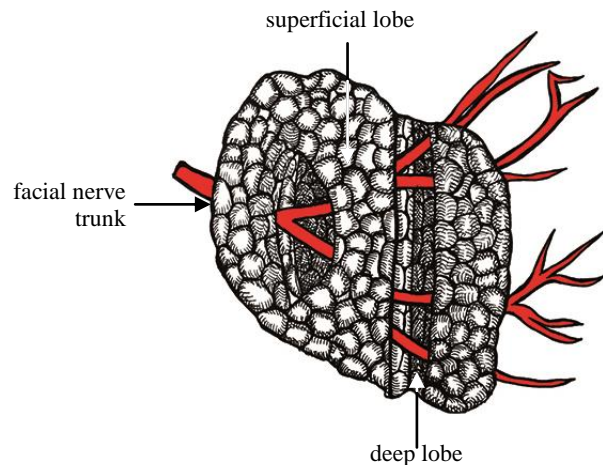
**Figure 8.1**  
Salivary glands

#### Minor salivary glands

There are hundreds (600–1000) of small, unnamed minor salivary glands distributed throughout the upper aerodigestive tract. The minor salivary glands are most prominent in the oral cavity and are located in the hard and soft palate, lips, buccal mucosa, floor of the mouth, and tongue. These glands are both mucous and serous types, and each has its own small duct draining directly to the mucous membrane of the oral cavity. The submandibular glands account for approximately 70% of the total volume of saliva. The parotid glands produce approximately 25%. Microscopically, the salivary glands are composed of acini, secretory tubules, and collecting ducts.

**The parotid gland** is the largest of the paired salivary glands; it is located in the cheek, lying in the space between the mastoid process, external auditory canal and the mandible. Deep to it lies the styloid process and the mandible. The carotid artery and internal jugular vein are medial to the styloid process. Laterally, the gland is flat, covered by the thick parotid fascia, and lies close to the skin. It is a serous gland producing watery saliva. The parotid duct (Stensen's duct) is

approximately 6 cm long, and the orifice lies opposite the second upper molar tooth. The facial nerve exits the skull through the stylomastoid foramen, which lies at the deep posterior border of the gland and the enters the gland as a short trunk 0.7–1.5 cm long (Figure 8.2). It divides into two or three main branches and then divides peripherally into the terminal five branches, which supply the muscles of the face and platysma. The facial nerve divides the gland into a deep and superficial portion. Parotid gland secretions are stimulated by parasympathetic fibres originating in the inferior salivatory nucleus of the brainstem. These fibres join the glossopharyngeal nerve and then the lesser petrosal nerve, before joining the otic ganglion just outside the foramen ovale. The auriculotemporal nerve picks up these parasympathetic fibres and distributes them to the parotid gland.



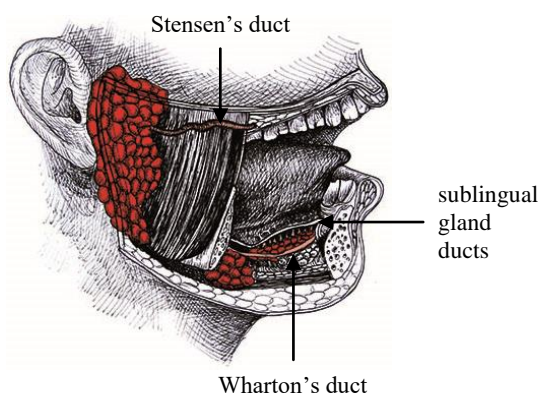
**Figure 8.2**  
Facial nerve and its relation to the parotid gland

**The submandibular gland** is a mixed serous and mucous gland that lies within the submandibular triangle of the neck. It is bordered anteriorly by the digastric muscle, posteriorly by



the stylomandibular ligament, and superiorly by the mandible. Like the parotid gland, it is covered with a fascial capsule, which originates from the superficial layer of the deep cervical fascia. The gland is made up of a large superficial lobe (that lies on the mylohyoid muscle) and a deep lobe. The submandibular duct (Wharton's duct) is about 5 cm long, running in superior and anterior direction from the deep lobe to open in the mouth as the papilla in the floor of the mouth next to the frenulum of the tongue. The lingual nerve is located just medial and superior to the gland within the sublingual space. The hypoglossal nerve courses between the medial portion of the submandibular gland and the hypoglossus muscle deep into the digastric muscle. The marginal mandibular branch of the facial nerve overlies the lateral aspect of the submandibular gland. It is positioned in a plane deep into the platysma muscle, but superficial to the fascia of the submandibular gland. The blood supply is from facial and lingual arteries, which are accompanied by the facial and lingual veins.

**The sublingual gland** is the smallest gland; it lies on the floor of the mouth and it is mucus-secreting. There are 10 to 15 smaller ducts draining into the floor of the mouth rather than a single duct. The sublingual glands are innervated by parasympathetic fibres of the chorda tympani nerve (Figure 8.3).



**Figure 8.3**

Salivary glands with the ducts

## 8.2 PHYSIOLOGY

The function of salivary glands is to provide lubrication for the oral mucosa and begin digestion by moistening of the food bolus, the protection of dental structures, the control of oral cavity bacterial counts, and the immune system function. The salivary glands are reflexively stimulated to produce saliva and may secrete up to one litre of saliva in 24 hours. Chemically, normal saliva typically includes 99% water, electrolytes, and organic compounds (including proteins, urea, lipids, and amino acids). Included in the protein portion of saliva are amylase, albumin, immunoglobulin A (IgA), and lysozyme.

## 8.3 EVALUATION

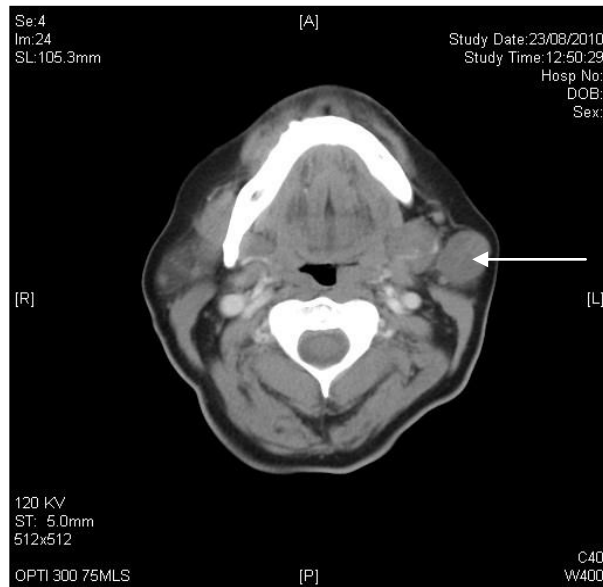### History

Salivary gland diseases can often be diagnosed on the basis of history, the patient's age and clinical findings. A diseased salivary gland typically becomes enlarged due to the accumulation of saliva. Swelling is often accompanied by pain. Swelling which is intermittent and related to eating suggests intermittent obstruction such as a calculus (stone), while permanent or progressive swelling suggests the presence of a tumour. Less commonly, a patient may present with dryness of the mouth. It is important to know the duration of symptoms, which gland is affected, and if other symptoms of systemic disease are present.

### Clinical examination

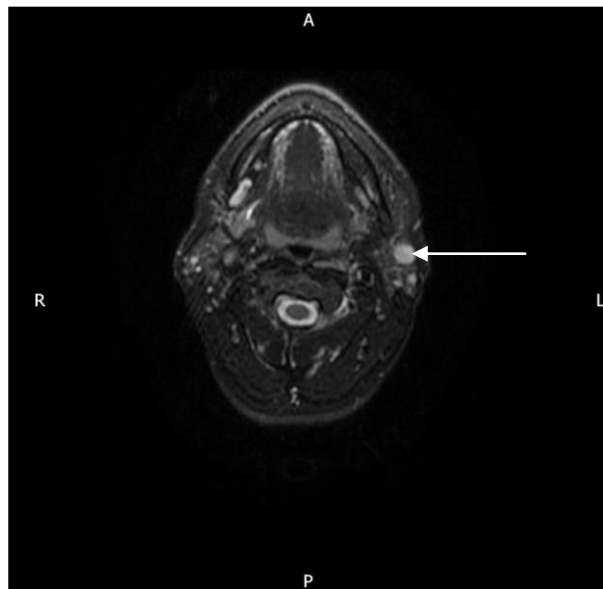
*Inspection* and *bimanual palpation* are very helpful, both externally and intraorally. It is important to examine the openings of the duct. The parotid gland duct opens into the buccal mucosa at a small papilla opposite the second upper pre-molar. The submandibular duct opens into the floor of the mouth at a small papilla. It is important to examine the facial nerve in parotid gland disorders. *Plain radiography, ultrasonography, sialography, radionuclide scanning, CT*

scanning, and magnetic resonance imaging (MRI) have all been employed to image the salivary glands (Figure 8.4, Figure 8.5).



**Figure 8.4**

Pleomorphic adenoma of left superficial lobe of parotid gland; CT scan, axial plane



**Figure 8.5**

Pleomorphic adenoma in the left parotid gland; MRI scan, T2-weighted image, axial plane

Ultrasonography is an inexpensive, noninvasive way to evaluate submandibular or parotid calculi. Up to 90% of calculi greater than 2 mm in size can be detected. Ultrasonography also demonstrates the location of the calculus and can be used in acute sialadenitis when sialography is contraindicated. Sialography has been replaced by CT and MRI for evaluation of neoplastic parotid masses. Histological diagnosis is very important in salivary gland disease; fine needle aspiration biopsy is useful but is often difficult to interpret. It is good practice to perform fine needle aspiration biopsy under ultrasound control; the evaluation must be done by an experienced cytopathologist.

## 8.4 DISEASES OF THE SALIVARY GLANDS

### 8.4.1 Inflammatory diseases of the salivary glands

The salivary glands may be affected by a wide range of diseases. Disease may be limited to a single gland, multiple glands or all salivary glands. The usual symptoms are swelling and pain. Differential diagnoses are in Table 8.1.

#### Viral infections

The most common cause of bilateral enlargement of the parotid gland is *mumps*, caused by paramyxovirus. The symptoms include swelling of the gland, pain, erythema and swelling of the duct, without purulent secretions and displacement of the auricle. Mumps occurs most commonly in children. The incubation period is  $20 \pm 10$  days. Typically, the disease involves the parotid glands primarily, but the submandibular and sublingual glands may be involved on occasion. The disease is usually self-limited and uncomplicated, however meningitis or sensorineural hearing loss can occur. The swelling of the glands characteristically subsides within 2 weeks. *Treatment* of viral salivary gland infection is

supportive. Live attenuated mumps vaccine as part of mumps, measles and rubella immunisation is given to children after 12 months of age.

**Table 8.1** Differential diagnosis of diseases of salivary glands (according to Profant, 2000)

Symptom	Disease	
Swelling	Painful	Inflammation
	Non-painful	Tumour, sialosis
Overlying skin	Erythematous, warm	Inflammation
	Erythematous, normal temperature	Tumour
Gland enlargement	Diffuse	Inflammation
	Localised mass	Tumour
Xerostomia	Sialosis, postradiation, drug-induced	
Sharp pain during meals	Sialolithiasis	
Facial nerve palsy	Suspicious for malignancy	
Rapid growth	Suspicious for malignancy	
Blood-stained saliva	Suspicious for malignancy	

### Acute bacterial infections

These may occur either by retrograde transmission of bacteria from the oral cavity or by stasis of salivary flow. It may involve any salivary gland, although the parotid gland is affected most frequently. It presents with pain, swollen gland, pyrexia, and systemic upset. The skin above the gland may be erythematous and fluctuation may be felt. The purulent exudate can be seen coming from the opening of the duct, which is erythematous and oedematous; trismus may be present. Acute parotitis commonly affects older, weakened, dehydrated patients with poor oral hygiene. Reduction of salivary flow is the most common underlying condition for bacterial infection ascending the duct. *Staphylococcus aureus* is the most common microorganism causing acute bacterial parotitis.

Treatment is with high-dose antibiotics, improving salivary flow, rehydration and oral hygiene. In case bacterial sialadenitis progresses to abscess

formation, CT scans are indicated followed by incision and drainage.

### Chronic sialadenitis

Chronic sialadenitis is characterised by recurring inflammation and swelling of the gland, minor pain, and sialorrhoea (which may be slightly purulent). *Streptococcus viridans* is the usual infecting microorganism. Common symptoms are pain and swelling after a meal. Trismus is often present. Attacks occur at variable intervals. Treatment of an acute episode is helpful. Surgical incision is reserved for refractory recurrent infections or in cases with a suspicion of malignancy.

---

Kuettner's tumour is chronic sialadenitis with symptoms including hardness and enlargement without pain, with chronic changes and scarring of the architecture of the gland.

---

### 8.4.2 Sialosis

Sialosis refers to diffuse, non-inflammatory, non-neoplastic recurrent enlargement of the major salivary glands. It is uncommon and has a variety of systemic causes.

### Sjögren's syndrome

Sjögren's syndrome is a chronic autoimmune disorder of many organ systems, including the exocrine glands, which affects predominantly the salivary glands. It is the second most common autoimmune disease, following rheumatoid arthritis. Xerostomia (dry mouth) and keratoconjunctivitis sicca (dry eyes) are characteristic; diffuse enlargement of the parotid gland affects a large number of patients. Other symptoms include chronic recurring joint disorders, rheumatic purpura, periarteritis nodosa and scleroderma. Both major and minor salivary glands are affected, which leads to reduced flow of saliva and xerostomia. Diagnosis is made according to clinical findings supplemented by biopsy of the mucous gland of the lower lip. Because the aetiology is unknown, treatment is symptomatic.

Those individuals who have recurrent episodes of acute sialoadenitis which do not respond to intensive medical management will require parotidectomy.

### Mikulicz disease

Mikulicz disease affects salivary and lacrimal glands, but it is not systemic. It is characterised by slow-growing, soft, painless swelling of the parotid gland and may affect men or women beginning at the age of approximately 40. *Mikulicz syndrome* is characterised by symmetrical swelling of salivary and lacrimal glands and any of the following: lymphadenopathy, chronic lymphatic leukaemia, Hodgkin's and non-Hodgkin's lymphoma, and haematogenous metastases. A biopsy is necessary to establish the diagnosis.

### Heerfordt syndrome

This syndrome presents as parotid swelling and swelling of the lacrimal glands, facial nerve paralysis, uveitis, and meningoencephalitis. The pathogenesis is extrapulmonary spread of sarcoid. Diagnosis is made according to sarcoid tissue changes in the gland parenchyma. Steroids are used for treatment.

## 8.4.3 Sialolithiasis

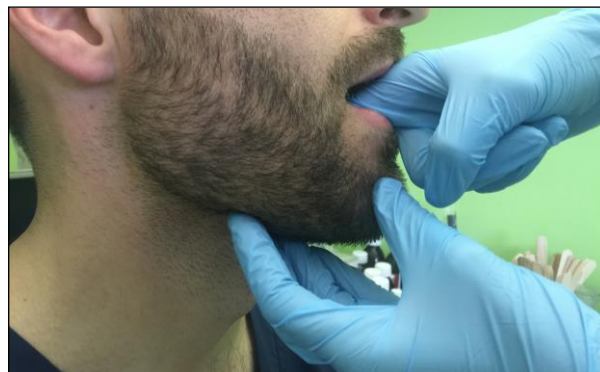
*Diagnosis.* Sialolithiasis is the formation of calculi within the salivary gland or duct into which the salivary gland drains (85% of cases in the submandibular gland, 15% in the parotid gland). Salivary duct calculi are the accumulation of calcium and phosphate crystals. Calculi can be present in any one of the glands.

*Aetiology and pathogenesis.* Calculi are much more likely to develop when the water content of saliva is decreased. Certain medications also predispose to the formation of calculi. These medications include antihistamines, antidepressants and diuretics.

*Clinical features.* Pain and swelling of the affected gland are typical. The pain usually worsens at mealtimes, when more saliva is produced. It is

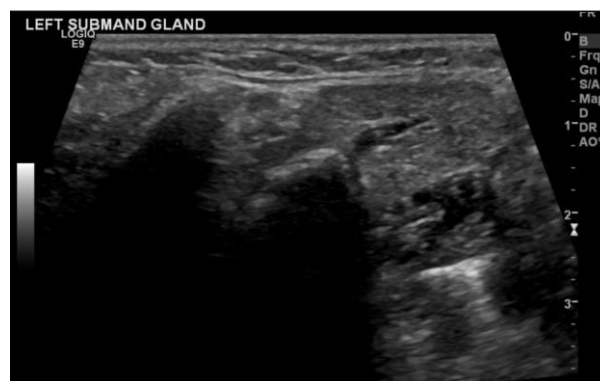also worse when a person eats sour or acidic food. Sometimes the saliva may have an unusual gritty feel or taste. The salivary gland swelling and pain usually subsides after several hours. In some instances the patient may have difficulty opening the mouth or swallowing, and in some cases may also have an unusually dry mouth. Sometimes the calculus completely occludes the duct and causes a bacterial infection. If an infection occurs in the gland it becomes severely swollen, extremely painful and very tender to the touch. The person may even sometimes exhibit a fever.

*Diagnosis.* Salivary calculi can often be palpated, especially in the submandibular gland. Bimanual palpation is used (Figure 8.6). Ultrasound helps to localize the calculus (Figure 8.7).



**Figure 8.6**

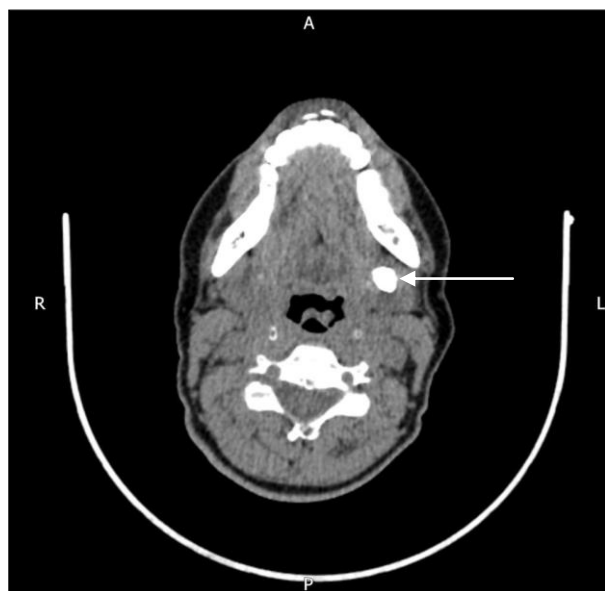
Bimanual palpation of the submandibular gland



**Figure 8.7a**

Sialolith in the left submandibular gland; ultrasound scan





**Figure 8.7b**

Sialolith in the left submandibular gland CT

*Treatment.* The calculus may be pushed or milked out of the duct by a firm massage if it is small enough. However, for larger calculi that cannot completely pass from the opening of the duct, a small incision may be made to remove it or the salivary duct may be probed, thereby widening the opening of the duct. If a chronic bacterial infection affects the gland, there may be scar formation in the area and the calculus is likely to be more difficult to remove. After extracting the calculus, the salivary gland usually returns to normal. In instances of recurrent calculi or chronic infection, the gland may need to be excised.

#### Sialendoscopy

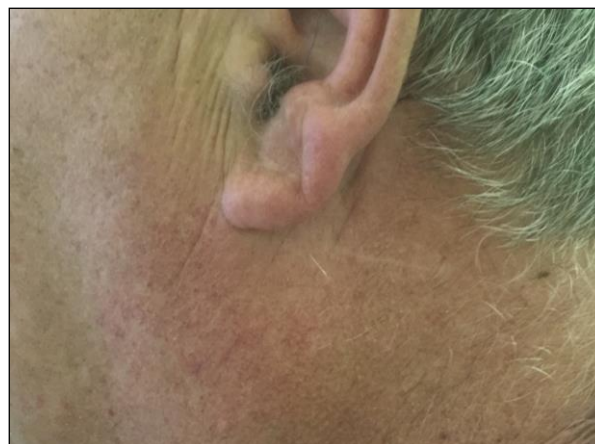Sialendoscopy is a novel technique introduced in the last few years. Sialendoscopy uses minimally invasive surgical techniques which allow for optical exploration of the salivary ductal system via the natural ostium and are able to identify and treat pathology under endoscopic view. Sialendoscopy uses semi rigid endoscopes with diameters 0.8-1.6 mm and incorporates diagnostic and therapeutic procedures, as dictated by the clinical findings. It is possible to remove the calculus with a basket, destroy it with micro burr or dilate the stenosed duct with a balloon dilatator. This technique can be performed in most cases under local anaesthesia as an ambulatory, outpatient procedure. In some cases it can be used as combined approach with open surgery.

### 8.4.4 Tumours of the salivary glands

*Definition.* Neoplasms that arise in the salivary glands are relatively rare. They represent a wide variety of both benign and malignant histologic subtypes (Table 8.2).

**Table 8.2** Common primary epithelial salivary gland tumours

Benign tumours	Malignant tumours
Pleomorphic adenoma (mixed tumour)	Mucoepidermoid carcinoma
Warthin's tumour (cystadenoma lymphomatosum)	Adenoid cystic carcinoma
Oncocytoma	Acinic cell carcinoma
Monomorphic adenoma	Carcinoma ex pleomorphic adenoma
	Squamous cell carcinoma
	adenocarcinoma

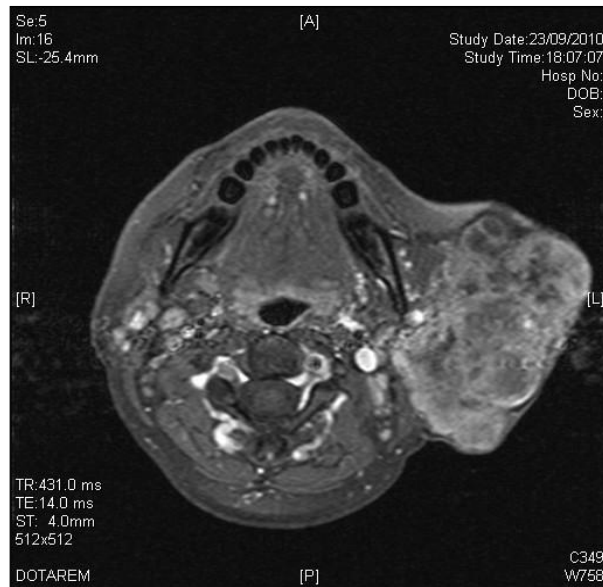


**Figure 8.8**

Tumour of the parotid gland

*Epidemiology.* Salivary gland neoplasms make up 6% of all tumours of the head and neck and most commonly appear in the sixth decade of life (Figure 8.8). Patients with malignant tumours typically present after the age of 60 years, whereas those with benign tumours usually present when older than 40 years. Benign neoplasms occur more frequently in women than in men, but malignant

tumours are distributed equally between the sexes. Among tumours of the salivary gland, 80% arise in the parotid glands, 10–15% arise in the submandibular glands, and the remainder arise in the sublingual and minor salivary glands. Most series report that about 80% of parotid tumours are benign, with the relative proportion of malignancy increasing in the smaller glands. A useful rule is the 25/50/75 rule. That is to say, as the size of the gland decreases, the incidence of malignancy increases in approximately these proportions.



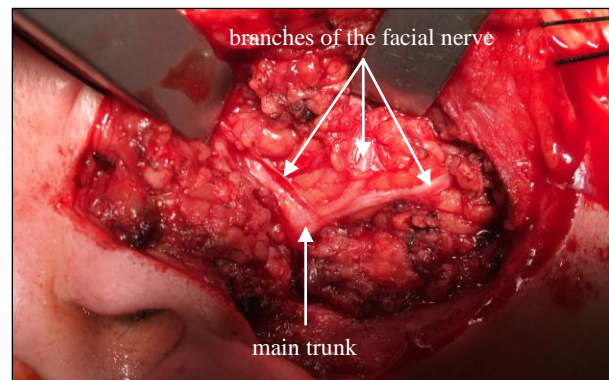
**Figure 8.9**

Malignant tumour of the left parotid gland; MRI scan, axial plane

**Diagnosis.** Most patients with tumours of the salivary glands present with a slowly enlarging painless mass. A discrete mass in an otherwise normal-appearing gland is the norm for tumours of the parotid gland. Tumours of the submandibular glands often appear with diffuse enlargement of the gland, whereas tumours of the sublingual glands produce a palpable fullness in the floor of the mouth. Tumors in minor salivary gland tumours have a varied presentation, depending on the site of origin. Facial paralysis or another neurologic deficit associated with a salivary gland mass indicates malignancy. Pain is a feature

usually associated with malignant tumours. Bimanual palpation for submandibular and sublingual masses also reveals the extent of the mass and its fixation to surrounding structures. Facial nerve palsy usually indicates a malignant lesion with infiltration into the nerve. *Fine needle aspiration biopsy (FNA)* is a valuable diagnostic adjunct in evaluation of a mass in the head and neck. *CT* or *MRI* is useful for determining the extent of large tumours, for evaluating extraglandular extension, and for determining the actual depth of parotid tumours (Figure 8.9). *Ultrasonography* can delineate the location, homogeneity or heterogeneity, shape, vascularity, and margins of salivary gland tumours in the periauricular, buccal, and submandibular areas. PET can be used to detect metastases to the lymph nodes.

**Treatment.** Surgical excision is the primary treatment for all primary tumours of the salivary glands (both benign and malignant) (see also Chapter 10.13). Superficial parotidectomy with identification and dissection of the facial nerve is considered to be the minimum operation for diagnosis and treatment of parotid masses (Figure 8.10). Recently, extracapsular dissection of benign parotid masses has been advocated by some authors. Benign neoplasms of the submandibular gland require complete excision of the gland.



**Figure 8.10**

Branches of facial nerve during superficial parotidectomy

Neither incisional biopsy nor enucleation should be performed for a mass in the parotid gland.

Malignant tumours of the salivary glands require surgery as the primary treatment modality. This is often combined with postoperative radiation therapy, depending on the specific characteristics and stage of the tumour. The extent of surgery is based on the size of the tumour, local extension,

and neck metastases. The facial nerve should always be spared unless it is directly involved. Radiation therapy is usually recommended for high-grade tumours, in case of unfavourable histological features and when surgical margins are directly involved by cancer.





## 9 BASICS OF PHONiatrics

Phoniatrics is the medical specialty which deals with disorders related to communication, including problems with the voice, speech, hearing and deglutition.

### 9.1 SPEECH AND LANGUAGE DEVELOPMENT

Early speech and language intervention produces better outcomes than does late intervention. Deficits in language have far-reaching and life-altering consequences, including decreased reading ability, lower academic achievement, and limited career choices. Hearing loss is a severe detriment to normal communication development and should be identified and treated as early as possible. The first three years of life, when the brain is developing and maturing, are the most intensive and rich with sounds, sights, and consistent exposure to the speech and language of others. There appear to be critical periods for speech and language development in infants and young children when the brain is best able to absorb language. If these critical periods are allowed to pass without exposure to language, it will be more difficult to learn.

#### **Speech and language development**

Children vary in their development of speech and language skills. Sometimes a delay may be caused by hearing loss, while other times it may be due to a speech or language disorder. The first signs of communication occur when an infant learns that a cry will bring food, comfort, and companionship. The 2- to 4-month-old baby calms and responds to a familiar voice or sound-making toys, the 4- to 9-month-old baby responds to her or his name, and by 9 months of age they begin to produce babble. The 12-month-old baby usually responds to "no" or comprehends verbal routines such as "wave bye-bye" and uses gestures and vocalisation to satisfy her or his need. Severe to profound hearing loss has devastating consequences for the

development of speech and language. The newborn hearing screening has lowered the average age at which a child with hearing loss is identified, but it does not identify hearing loss that is acquired after the newborn period. The recommendation from a position statement from the Joint Committee on Infant Hearing is that all infants who pass newborn hearing screening but who have risk indicators for other auditory disorders and speech delay should receive ongoing audiological surveillance and monitoring of their communication development.

Hearing loss is the most common cause of delayed communication development; therefore, it should be identified and treated as early as possible. Problems of speech and language development have negative consequences. Children with hearing loss have been shown to experience substantial delays in their mastery of all aspects of communication. Deficiencies in vocabulary, grammar, concepts, pragmatics and speech intelligibility have been documented in hearing-impaired children.

Early speech and language intervention produces better outcomes than late intervention. After implementation of universal newborn hearing screening the average age at which paediatric hearing loss is identified has been lowered dramatically.

### 9.2 SPEECH AND LANGUAGE DISORDERS

A speech disorder is a type of communication disorder in which "normal" speech is disrupted. A language disorder is a disorder that involves the processing of linguistic information. Both children and adults can have *speech and language disorders*. These can occur as a result of a medical problem or have no known cause. The

components of *speech* are phonation, resonance, fluency, intonation and voice. The components of *language* include: phonology (manipulating sound according to the rules of a language), morphology (understanding and using minimal units of meaning), syntax (constructing sentences by using grammar rules), meaning and pragmatics (social aspects of communication).

A **speech disorder** is present when a person is unable to produce speech sounds correctly or fluently, or has problems with his or her voice. Difficulties pronouncing sounds, or articulation disorders, and stuttering are examples of speech disorders. The known causes of speech disorders are hearing loss, neurological disorders, brain injury, intellectual disability, drug abuse, and physical impairments (cleft lip and palate). However, in many cases the cause is unknown.

- *Childhood apraxia of speech* (developmental verbal dyspraxia) is a motor speech disorder, concerning problems saying sounds, syllables, and words; the brain has problems planning to move the lips, jaw or tongue, needed for speech, and the child knows what he or she wants to say, but his/her brain has difficulty coordinating the muscle movements necessary to say those words.
- *Apraxia* may result from stroke or progressive illness, and involves inconsistent production of speech sounds and rearranging of sounds in a word; production of words becomes more difficult with effort, but common phrases may sometimes be spoken spontaneously without effort.
- *Dysarthria* — weakness or paralysis of speech muscles — is often caused by damage to the nerves and/or brain, which is often caused by strokes, Parkinson's disease, amyotrophic lateral sclerosis, head or neck injuries, surgical accidents, or cerebral palsy.
- *Speech sound disorders* includes difficulty in producing specific speech sounds, most often consonants "s" and "r", and are subdivided into articulation disorders and phonemic disorders. *Articulation disorders* or *phonetic disorders* are characterised by difficulty learning to produce sounds physically. *Phonemic disorders* are

characterised by difficulty in learning the sound distinctions of a language, so one sound may be used in the place of many.

- *Stuttering* is characterised by disruptions in the production of speech sounds. It affects the fluency of speech, begins during childhood and, in some cases, lasts throughout life. It affects approximately 1% of the adult population.
- *Muteness* is a complete inability to speak.

**Language disorder** is when a person has trouble sharing thoughts, ideas, and feelings completely (expressive language) and understanding others (receptive language). A stroke can result in aphasia, or a language disorder. Problems that may be experienced can involve grammar (syntax and/or morphology), semantics (meaning), or other aspects of language. These problems may be receptive (involving impaired language comprehension), expressive (involving language production), or a combination of both.

- *Aphasia* (communication disorder that results from damage to the parts of the brain that contain language, typically in the left half of the brain; it may cause difficulties in speaking, listening, reading, and writing, but does not affect intelligence. Aphasia can be caused by stroke, brain tumours, traumatic brain injury, and progressive neurological disorders).

## 9.3 HEARING LOSS

Hearing loss is one of the most serious impediments to normal communication development. The impact of permanent childhood hearing impairment can be devastating; congenital hearing loss may lead to poor development of spoken language and this, in turn, can lead to poor literacy skills, poor educational achievement with subsequent low income and socio-economic status. Hearing loss may be conductive, sensorineural or mixed (see also Chapter 1). Reference has already been made to the most common cause of hearing loss in childhood, otitis media with effusion, which precludes neither the presence of sensorineural hearing loss nor the converse.

### 9.3.1 Types of hearing loss

- **Conductive hearing loss** has normal bone-conduction thresholds, but air-conduction thresholds are elevated by at least 10 dB. This type of hearing loss may be secondary to an outer ear or middle ear abnormality. The abnormality reduces the effective intensity of the air-conducted signal reaching the cochlea, but it does not affect the bone-conducted signal that does not pass through the outer or middle ear. Examples of abnormalities include occlusion of the external auditory canal by impacted cerumen, a foreign body, a mass, middle ear infection and/or fluid, perforation of the tympanic membrane, or ossicular abnormalities.
- **Sensorineural hearing loss** has bone- and air-conduction thresholds within 10 dB of each other, and thresholds are higher than 25 dB. Because, in this type of hearing loss, the outer ear and middle ear do not reduce the signal intensity of the air-conducted signal, both air- and bone-conducted signals are effective in stimulating the cochlea. It is secondary to cochlear abnormalities and/or an abnormality of the auditory nerve or central auditory pathways. Examples include congenital hearing loss, presbycusis, noise-induced hearing loss, and retrocochlear lesions such as vestibular Schwannoma.
- **Mixed hearing loss** has both conductive and sensorineural components. Pure tone air-conduction thresholds are poorer than bone-conduction thresholds by more than 10 dB, and bone-conduction thresholds are less than 25 dB.

### 9.3.2 Degrees of hearing loss

- **Normal hearing** (0–20 dB): Hearing considered to be within normal limits.
- **Mild hearing loss** (21–40 dB): Mild hearing loss may cause inattention, difficulty suppressing background noise, and increased listening efforts. Patients with this degree of hearing loss may not hear soft speech. Children

may be fatigued after listening for long periods.

- **Moderate hearing loss** (41–55 dB): Moderate hearing loss in childhood may affect language development, syntax and articulation, interaction with peers, and self-esteem. Patients with this degree of loss have trouble hearing some conversational speech.
- **Moderate-severe hearing loss** (56–70 dB): Moderate-severe hearing loss may cause difficulty with speech and decreased speech intelligibility. Patients with this degree of loss do not hear most conversational-level speech.
- **Severe hearing loss** (71–90 dB): Severe hearing loss may affect voice quality.
- **Profound hearing loss** (>90 dB): With profound hearing loss (deafness), speech and language deteriorate.

Hearing loss may also be classified as **hereditary and acquired**.

---

#### Hereditary hearing loss

The cause of hereditary hearing loss is genetic. The hearing loss may be syndromal and non-syndromal. Syndromes affecting the ear may produce either a conductive or a sensorineural loss (or possibly both). Hereditary hearing loss may be autosomal dominant or autosomal recessive, or as a sex-linked recessive trait. Almost 90% of genetic hearing loss is an autosomal recessive form. Mutations in the GJB2 gene that encodes protein connexin 26 have now been shown to account for up to 30–50% of recessive deafness.

---

**Acquired** hearing loss is classified according to the timing of its onset in relation to birth: pre-natal, perinatal, and post-natal. This may influence diagnostic and management strategies.

- Prenatal causes of sensorineural hearing loss include intrauterine infections such as cytomegalovirus, toxoplasmosis and rubella, intrauterine exposure to ototoxic and teratogenic agents, and other developmental anomalies.
- Perinatal hearing loss causes include prematurity, low-birth weight, hypoxia and hyperbilirubinemia.
- Post-natal acquired causes of hearing loss are variable and may cause conductive or sensorineural hearing loss (or both). They

include: bacterial meningitis, infections, complications of otitis media and otitis media with effusion, immunisation, and genetic causes.

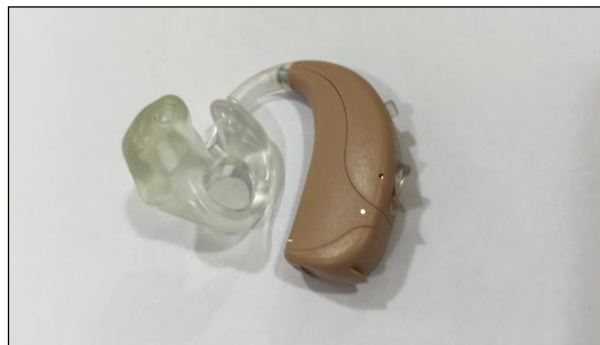The purpose of the audiological assessment of children is to identify accurately those with hearing loss as early as possible, and to try to minimise the disability caused by deafness. The assessment of hearing in children requires several different testing techniques to be available. The choice of test will depend upon the age of the child and the medical state. The ideal test will provide an objective assessment of the entire auditory pathway, which is frequency-specific, highly sensitive and specific, and provide reliable results in a variety of settings. The OAE test is ideal for newborn hearing screening, but it tests only cochlear function and in further assessment other investigation is needed. ABR testing is standard for assessment of children with a high risk of hearing loss. ASSR testing may provide more accurate and frequency-specific results. Behavioural testing remains important for the assessment of children with hearing loss, especially as it tests the entire auditory pathway, including an understanding of the relevance of the sound stimulus.

## 9.4 TREATMENT AND REHABILITATION OF HEARING LOSS

Treatment and rehabilitation of hearing loss depend on a variety of factors, including the age, degree and type of hearing loss and any other associated disability. In almost all children with permanent hearing loss the treatment includes provision of appropriate, typically post-auricular hearing aids. In case of an anomaly of the external auditory canal or a middle ear anomaly, bone-conduction hearing aids are relevant. When the child is older, possibly bone-anchored hearing aids are more appropriate.

Some patients with conductive hearing loss may also benefit from the use of hearing aids. A potential major benefit of early diagnosis of hearing loss is early referral for cochlear implantation. Cochlear implantation has transformed the management and potential of children with the more severe and profound degrees of sensorineural hearing loss. It is important to give a child an adequate trial of acoustic hearing aids, but it is becoming increasingly apparent that implantation should be done until two years of age. Early implantation is also ideal for patients with deafness following meningitis.

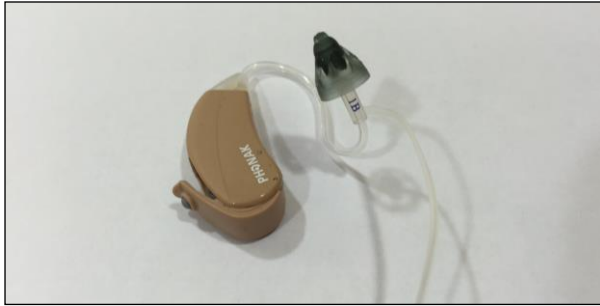**A hearing aid** will not restore normal hearing because it cannot fully overcome the complex fundamental impairments of auditory function. However, optimum communication will be achieved only by the provision of the most appropriate aid. The prescription of a hearing aid is indicated if hearing loss cannot be relieved or improved by other means such as surgery; it should be prescribed by the specialist after a thorough audiometric investigation. A hearing aid is a device that processes sound in such a way that it makes the information it conveys more accessible to the user. It is an integral part of the receptive communication chain, which includes the signal source and the listener. It should be seen as only one important part of a programme to minimise disability and handicap arising from hearing impairment by optimising the partially hearing or deaf user's access to acoustic information (Figure 9.1).



**Figure 9.1a**

Hearing aid – With mould





**Figure 9.1b**  
Hearing aid – “Open tip” hearing aid

When profound hearing loss exists that cannot be adequately amplified, a **cochlear implant** can provide some help. A normal cochlear structure is essential.

The cochlear implant is a surgically placed device that converts sound to an electrical signal.

All cochlear implants consist of five basic parts: a microphone, speech processor, transmitting coil, internal receiver/stimulator, and an electrode array.

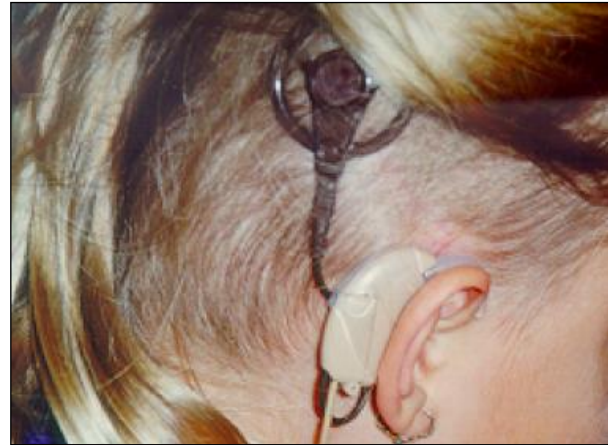#### **Cochlear implant**

A cochlear implant bypasses the damaged hair cells in the cochlea, and directly stimulates the remaining spiral ganglion cells. With a few exceptions, it is the cochlear hair cells, rather than the cochlear nerve fibres, that are absent or damaged in both congenital and acquired profound sensorineural hearing loss. A multi-channel electrode is inserted into the cochlea surgically. This directly stimulates the cochlea when electrical signals are applied. Each channel corresponds to a different frequency. The electrode is attached to an external auditory processor through the skin via a magnetic coupler. Sound is collected, processed and fed to the channels on the electrode. Following surgery to place the receiver-stimulator and electrode array, the incision is allowed to heal for approximately 4 weeks. The patient attends a series of appointments with the specialist to program the external speech processor (Figure 9.2).

*The indications for cochlear implantation include:*

- Congenital bilateral profound hearing loss (>90 dBHL). Children should be referred to a cochlear implant centre by 6 months of age.
- Progressive hearing loss (congenital rubella, CMV infection, wide vestibular aqueducts).

- Severe-to-profound hearing loss: children who do not benefit from hearing aids may benefit more from a cochlear implant.
- Sudden hearing loss (meningitis, autoimmune disease, chemotherapy, ototoxicity and head injuries).



**Figure 9.2**  
Child with cochlear implant

Successful cochlear implantation requires a multidisciplinary team. The team members include the audiologist, teachers of the deaf, speech and language therapists, psychologists, medical members, and parents and the family of the child. Cochlear implantation is now a mainstream option for the management of children with severe-to-profound hearing loss. Cochlear implants are suitable for children from the 1<sup>st</sup> year of life. Cochlear implants replace the sense of hearing and can aid an appropriate candidate in developing spoken language.

Delaying the referral of a child suitable for a cochlear implant will inevitably lead to loss of potential long-term benefits in terms of oral speech and language development. Current trends in cochlear implantation include bilateral implantation for adults and children. The degree of success of cochlear implantation is largely dependent on having an experienced cochlear implant team involved from the beginning of the assessment.

There are two ways in which we hear sound: through air conduction and through bone conduction. They both work together to help to listen to and perceive sound. With conductive or mixed hearing loss, sound cannot take the natural path through the outer and middle ear to the inner ear.

**Bone-anchored hearing systems** are designed to use natural ability to transfer sound through bone conduction. The sound processor picks up sound, converts it into vibrations, and sends it through your skull bone, directly to the inner ear. This bypasses problems in the outer ear canal or middle ear. **The bone-anchored hearing aid (BAHA)** is an implant used for conductive and mixed hearing losses and also for single-sided sensorineural hearing loss. The BAHA works on the principle of efficient coupling of the sound processor to the underlying bone through a small connector across the skin: an osseointegrated implant. It is based on two main principles: osseointegration and direct bone conduction. The device is composed of three main parts: a titanium implant, an external abutment, and a sound processor. A tiny titanium vibrator is inserted into the skull behind the ear. A microphone and hearing aid components form the rest of the package. Incoming sounds cause the implanted portion to vibrate. These vibrations are transmitted to the inner ear via bone conduction and produce sound sensations.

Implantable hearing devices are designed to help to increase the transmission of sound vibrations entering the inner ear. They are an option for hard-of-hearing people who cannot use cochlear implants or hearing aids, or who may simply prefer not having any visible external parts for a hearing device.

**The Bonebridge** is an active bone conduction implant system. It can be an effective solution for people with lasting hearing loss following a middle ear operation, malformations, or generally for conductive hearing loss and mixed hearing loss or single-sided deafness. The sound waves are transmitted via bone conduction directly to the inner ear. The implant is implanted under the skin behind the ear; it is not visible from the outside and complication rates are very low.

**The Vibrant Soundbridge** can be an effective solution for cases of mild to severe sensorineural hearing loss, as well as for conductive or mixed hearing loss. It converts the signals from the environment into mechanical vibrations. This mechanical energy directly stimulates the structures of the middle ear. This implant consists of the externally worn audio processor, and a surgically implanted component. The implantable component consists of the Vibrating Ossicular Prosthesis (VORP) and the Floating Mass Transducer (FMT). The signal sent by the audio processor is processed by the VORP and converted by the FMT into mechanical vibrations that are transmitted directly to the middle ear structures.

## 9.5 VOICE DISORDERS

*The larynx* consists of the laryngeal framework and the true vocal folds. The laryngeal framework (laryngeal and cricoid cartilages) provides a buttress upon which the intrinsic and extrinsic laryngeal muscles can exert their effect. The larynx changes in position and structure, and it descends in the neck in relationship to the cervical vertebrae from infancy (inferior part of cricoid at the level of C4) to the mature position (C6–C7).

**Human voice production** involves the synchronisation of optimal glottic positioning with the control of the airflow from the lungs to the oropharynx. Vocal fold vibration provides a sound source for spoken language. When we inhale, the vocal folds are at rest and, thus, are apart from each other. When we speak, during exhalation, there is a build-up of pressure beneath the vocal cords which brings them together, the vocal folds are adducted (closed), and air is exhaled upwards and blows apart the vocal folds, setting them into a rapid vibratory pattern. The voice is further modified by the processes of resonance and articulation. The resonating system is comprised of the pharynx, oral cavity and nasal passages. The resonating system gives the individual a personal quality to the voice.

*Voice problems* are relatively frequent in the average population. It is estimated that a properly functioning voice is essential for approximately one third of current job descriptions. Many people ignore voice problems and only seek medical assistance in late stages of the disease. Symptoms of a voice disorder range from hoarseness and a chronic dry, scratchy throat to limitations in the ability to speak clearly or periods of voice loss. There are many ways in which the vocal cord may be injured, e.g. talking too much, screaming, or smoking. This can also lead to problems such as nodules, polyps, and chronic oedema on the vocal cords. Other causes of voice disorders include infections, reflux of stomach acid into the throat, growths due to a virus, cancer, external trauma and diseases that paralyze the vocal cords. Treatment for voice disorders varies depending on the cause. Most voice problems can be successfully treated when diagnosed early. The gold-standard examination of an adult patient with a voice complaint is a video and stroboscopic examination using a 70° rigid endoscope. This provides invaluable information regarding the anatomy and function of the true vocal folds. In children, flexible fibre-optic laryngoscopy can be performed.

A **voice disorder** can be defined as a problem involving an abnormal pitch, loudness or quality of the sound produced by the larynx. Voice disorders may be caused by different factors, events, physical ailments and diseases. Voice disorders may be present in both adults and children. Symptoms may include any of the following: hoarseness, shortness of breath, harsh or rough voice, breathy voice, decrease in pitch range, decrease in loudness, deterioration of the voice as the day goes by, loss of voice, increased strain to speak, and tension in neck muscles. One of the most common causes is when a person with the potential of having a normal voice abuses his/her voice and, thus, develops a chronic voice disorder. Continuous vocal abuse may cause chronic laryngitis, nodules, polyps, cysts and oedema (swelling) of the vocal folds (see Chapter 5). If symptoms persist for more than three weeks, one should seek advice.

- *Dysphonia*: a term for a voice that is disordered in some way.
- *Aphonia* is a total loss or lack of voice.
- *Hypofunction*: Vocal folds are under-functioning and have inadequate tension, so air escapes through. Breathiness, hoarseness, or no voice at all is present.
- *Hyperfunction*: Vocal folds are overly tense and compress too tightly together, too loud, too high, and/or too strained, spasticity of the voice.
- *Diplophonia*: Vocal folds produce two different pitches simultaneously.

A voice disorder often requires both medical and surgical treatment and speech therapy sessions. Therapy involves exercises that generally focus on breath support, movement of the vocal cords, resonance of the voice, relaxation of those muscles involved in voice production, and posture.

Voice disorders could be divided into three categories: *organic*, *functional*, and *psychogenic*.

### **Organic voice disorders**

*Structural disorders* are caused by a physical abnormality of the larynx; something is physically wrong with the mechanism, often involving tissue or fluids of the vocal folds, eg nodules, polyps, cysts, laryngitis, papilloma, trauma, leukoplakia or hyperkeratosis. Vocal abuse is a chronic or intermittent overuse or misuse of the vocal apparatus (talking in noisy environments, frequent coughing, using caffeine products, screaming, giving speeches, spending time in smoky environments). Vocal fold nodules are typically caused by vocal misuse. Polyps can be caused by vocal abuse or gastro oesophageal reflux disease.

*Neurogenic disorders* are caused by some problem in the nervous system as it interacts with the larynx. They result from illness, damage, or disease to the neurological systems associated with voice production. The most important nerve of the larynx, the recurrent laryngeal nerve, is vulnerable to damage during cardiac, pulmonary, spinal and thyroid surgeries; when the nerve is damaged, it causes a paresis (weakness) or

paralysis (complete lack of movement) in the vocal fold of the affected side. Other neurogenic voice disorders are related to other kinds of problems in the central nervous system.

### Functional voice disorders

Functional disorder means that the physical structure is normal, but the vocal mechanism is being used improperly or inefficiently. Functional disorders are caused by poor muscle functioning. All functional disorders fall under the category of muscle tension dysphonia.

### Psychogenic voice disorders

Psychogenic disorders are nonorganic disorders, resulting from emotional or psychological characteristics. They exist because it is possible for the voice to be disturbed for psychological reasons. In this case, there is no structural reason for the voice disorder, and there may or may not be some pattern of muscle tension.

## 9.6 VOICE AND SPEECH AFTER LARYNGECTOMY

The laryngeal cancer commonly presents at a stage necessitating total laryngectomy, which significantly alters speech production (see also Chapter 5.4.4.3). After total laryngectomy the sound source is removed and the lungs are disconnected from the vocal tract. There are three basic options for voice restoration after total laryngectomy.

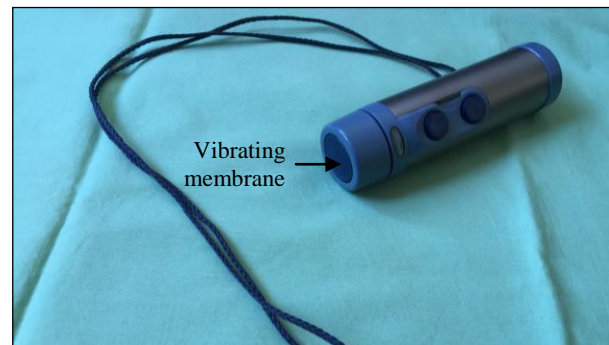- esophageal speech
- artificial larynx speech
- tracheoesophageal speech

The selection of a method should be made together with the patient, keeping in mind the communicative needs, physical and mental status, and personal preference.

Approximately 20% of laryngectomy patients can learn *oesophageal speech*, or use nonvocal speech. The air is released by eructation after it is squeezed into the oesophagus from the mouth.

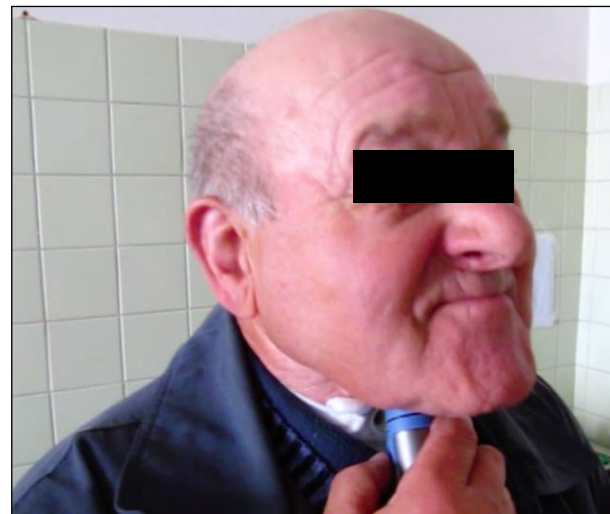The upper oesophageal sphincter vibrates; air moves into the pharynx then into the mouth and is used to produce a voice. Movements of the lips, cheeks and tongue shape the sound into words. Learning the technique is taught by a speech therapist.

A widely used (55%) form of voice rehabilitation after total laryngectomy is the *artificial larynx* (Figure 9.3). This electronic device produces sound by conducting externally produced vibrations via the skin and tissue of the neck to the pharyngeal wall or the floor of the mouth. Speech in the vocal tract is articulated in the usual manner. Voiced parts can be heard at a conversational volume.



**Figure 9.3a**

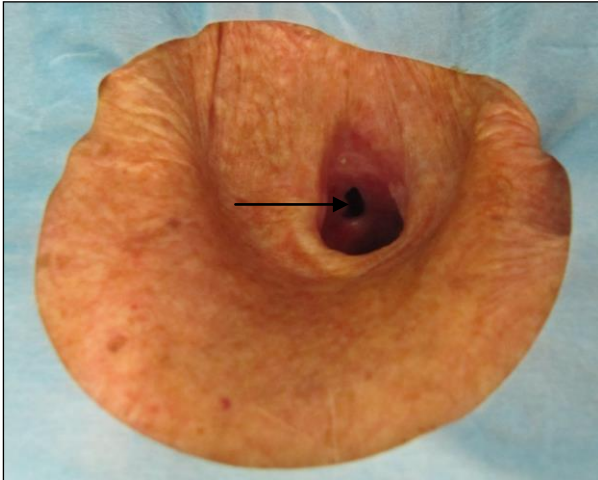
Artificial larynx – Electrolarynx



**Figure 9.3b**

Artificial larynx – Patient using the device

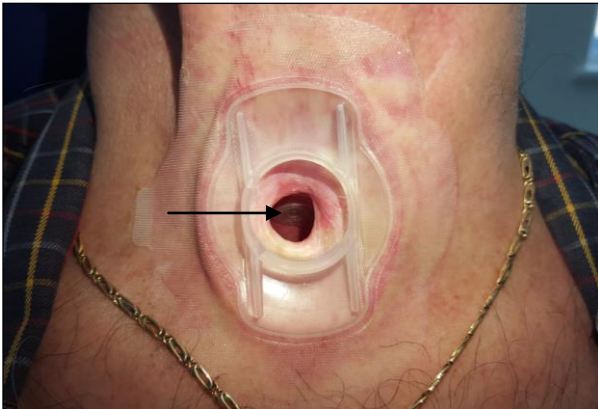




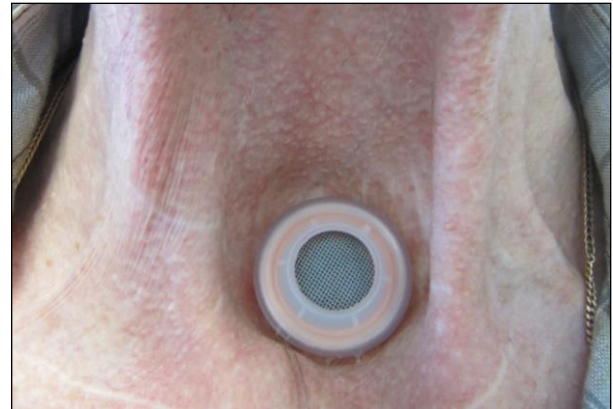
**Figure 9.4**  
Tracheo-oesophageal shunt

*Tracheoesophageal puncture* (TEP) with a valve insertion is currently the method of choice. An opening between the trachea and the oesophagus is made during laryngectomy (primary puncture), or in separate surgery after laryngectomy (secondary puncture) (Figure 9.4). A small plastic or silicone valve fits into this opening (Figure 9.5). The valve keeps food out of the trachea. After TEP, patients can inhale, cover the stoma with their finger, and force air into the oesophagus through the valve. The air produces sound by making the walls of the pharynx vibrate, and can be used to create understandable speech.

Tracheal ostium can be covered by special button called the Heat and Moisture Exchanger or “Artificial nose”. (Figure 9.6) Artificial nose filters and moisturizes the air, increases airway resistance and improves pulmonary physiology.



**Figure 9.5**  
Voice prosthesis



**Figure 9.6**  
“Artificial nose”



# 10 PRINCIPLES OF SELECTED SURGICAL PROCEDURES IN OTORHINOLARYNGOLOGY

This chapter is not aimed to teach the medical student or junior doctor to independently perform the listed surgeries. Presented steps of the selected surgical procedures try to illustrate the nature of discussed procedures.

## 10.1 TONSILLECTOMY

### *Definition and indications*

Tonsillectomy is a surgical procedure in which the tonsil is removed from the tonsillar fossa. The extent of surgery can be broadly divided into two major categories: intracapsular (partial tonsillectomy) and extracapsular (total tonsillectomy, subcapsular).

- **Intracapsular** (subtotal tonsillectomy or tonsillotomy). It is the removal of most of the tonsil, while preserving a rim of lymphoid tissue and tonsillar capsule. Intracapsular tonsillectomy has limited indications and can be recommended for very young children with tonsillar hypertrophy.
- **Extracapsular** tonsillectomy involves dissecting lateral to the tonsil in the plane between the tonsillar capsule and the pharyngeal musculature, and the tonsil is generally removed as a single unit. This is one of the most frequently performed surgical procedures.

### *Preoperative considerations*

General anaesthesia is used almost exclusively. It is given using endotracheal intubation with an angled tube or with a laryngeal mask. The patient is in the supine position, and the shoulders are

supported by the shoulder bag/roll to achieve extension of the neck.

### *Incision and approach*

A mouth gag is inserted and opened to expose the oropharynx; the ventilation tube and tongue must be in the midline. Infiltration anaesthesia with 1% lidocaine plus 1:200,000 epinephrine is used. The most common extracapsular techniques incorporate the use of a “cold” knife (sharp dissection), monopolar electrocautery, bipolar cautery, harmonic scalpel, or coblation-assisted technique. A frequently used method for tonsillectomy is the “cold” or sharp dissection technique.

### *Main procedure*

The incision is made in the mucous membrane of the anterior faucial pillar near the upper pole of the tonsil. The tonsil is grasped with forceps at its upper pole and is pulled inferiorly and medially. The tonsil with the capsule is dissected from surrounding tissue using scissors, a knife, or a dissector; bipolar-assisted dissection is also possible. The tonsil is amputated at the inferior pole with a tonsil snare or bipolar coagulation, and the inferior pole can be secured with a tie. Bipolar cautery is used to control bleeding, and tonsillar fossas are left to heal by secondary intention.

### *Postoperative care*

The patient can eat and drink once fully awake from anaesthesia. Different diets are being advocated by different surgeons, but we prescribe a soft diet for 14 days. Monitoring postoperative bleeding is necessary. Analgesia needs to be given

for 14 days. The patient/parents must be aware of up to 10% of the risk of postoperative bleeding.

## 10.2 PARATONSILLAR ABSCESS DRAINAGE

### *Definition*

Paratonsillar abscess (quinsy) is a complication of acute tonsillitis with accumulation of purulent exsudate between the tonsil and the muscular tonsil fossa.

### *Preoperative considerations*

There are several ways in which to surgically manage the paratonsillar abscess (see also Chapter 3.4.4):

- “Hot” tonsillectomy (tonsillectomy without delay) is used by our group.
- *Aspiration* of the purulent exsudate is also widely used.
- *Incision and drainage* under topical and local anaesthesia used to be the procedure of choice and are described below.

### *Incision and drainage*

The patient is positioned in the chair, and topical anaesthesia is induced with 1% topical lidocaine (Xylocaine) through the open mouth. Infiltration anaesthesia with 1% lidocaine plus 1:200,000 epinephrine is used at the site of the intended incision, and the purulent exsudate often drains from the puncture site when the anaesthetic is introduced. The anaesthetic has to be allowed approximately 5 minutes to act before the incision is made. The incision is made at the point of maximum protrusion of the tonsil, usually between the uvula and the second upper molar tooth. A test aspiration may be carried out before the incision.

### *Main procedure*

A long-handled pointed scalpel is used for the incision. All but 1.5–2.0 cm of the point might be wrapped in sterile adhesive tape to prevent the

point of the blade from penetrating too deeply and injuring the major vessels of the neck. The incision is made parallel to the ascending ramus of the mandible and must not pass externally, as the internal carotid artery and internal jugular vein are in the immediate vicinity. If the diagnosis is correct, purulent exsudate gushes out and must be removed with a suction to prevent aspiration into the trachea. After the abscess has been drained, a haemostat is introduced into the abscess cavity and opened widely, usually producing a further gush of purulent exsudate.

### *Postoperative care*

The abscess cavity must be opened up daily for a few more days until no more purulent exsudate drains from it.

## 10.3 ADENOIDECTOMY

### *Definition and indications*

Adenoidectomy is a common surgery in children used to remove the adenoids (hypertrophic nasopharyngeal tonsil).

### *Preoperative considerations*

The patient is in the supine position, and general anaesthesia with endotracheal intubation using an angled tube or with a laryngeal mask is given, with shoulders being supported by the shoulder bag/roll to achieve extension of the neck. A mouth gag is inserted, opened and secured in the position; the ventilation tube and tongue are in the midline; and the soft palate is retracted with bilateral rubber catheters passed from the nose to the mouth, with the two ends clamped tightly by artery forceps.

### *Approach*

A 70° 4-mm nasal endoscope is introduced through the mouth, and the adenoid mass is identified. Alternatively, a 30° endoscope can be used through nasal cavity. A camera can be mounted on the endoscope and the endoscopic view is projected on a monitor.



*Main procedure*

There are several ways for the adenoid tissue to be removed:

- Curettage of the main adenoid mass is carried out using an *adenoid curette*, with removal of residual adenoidal tissues using forceps, while suction is used to maintain exposure.
- A *microdebrider* can be used (powered rotary shaving device with continuous suction), and the endoscope is used along with a microdebrider in the oscillating mode with saline irrigation to curette and shave off the adenoid tissue.
- *Suction diathermy adenoidectomy* is another method that aims to remove the adenoids while minimising intraoperative blood loss and risk of secondary haemorrhage. It incorporates the use of heat generated by an electric current to ablate or liquefy adenoid tissue, which is then removed using suction.

The bleeding is usually minimal, especially after complete removal of all nasopharyngeal lymphoid tissue. Bipolar or monopolar cautery is used to stop bleeding from the raw surface of the adenoid bed (if necessary).

*Postoperative care*

The patient can eat and drink once fully recovered from anaesthesia and may be discharged on the same day taking a simple analgesia.

## 10.4 RIGID PHARYNGOSCOPY, LARYNGOSCOPY AND OESOPHAGOSCOPY

*Indications*

These endoscopic procedures can be performed for diagnostic or therapeutic purposes.

*Diagnostic* indications include visualisation of the larynx, pharynx and oesophagus in order to evaluate mucosal lesions and take a biopsy.

*Therapeutic* indications include removal of foreign bodies, injection of vocal cords, and

treatment of benign and malignant tumours by excision with/without a laser.

*Preoperative considerations*

General anaesthesia with orotracheal intubation with a microlaryngeal tube is used. Laryngopharyngoscopy is done with the patient's neck flexed and extension of the atlanto-occipital joint (*sniffing the morning air position*). Oesophagoscopy is done with the neck extended. Silastic gum guards or a wet swab can be used to protect the upper teeth/gum. Care should be taken not to dislodge loose teeth.

*Main procedure*

A *laryngoscope* connected to the light source is inserted along the dorsum of the tongue. The laryngoscope is held by the left hand (for a right-handed surgeon) and the right hand is used for suction and use of other instruments. Once the posterior third of the tongue is reached, the scope is passed anterior to the endotracheal tube, pushing the tube posteriorly (to view the larynx); the epiglottis is then visualised. The base of the tongue, valleculae and lingual surface of epiglottis are inspected at this point. The scope is inserted further, beyond the epiglottis. The epiglottis is lifted up by the scope. It is important not to support the laryngoscope on the upper teeth, as this might damage them. The rest of the endolaryngeal structures are visualised in a systematic manner. The scope is passed behind the tube, pushing the tube anteriorly — the posterior pharyngeal wall, pyriform fossae and post-cricoid region are visualised.

To visualise the *oesophagus*, the neck is extended and the oesophagoscope is used. The method of insertion is similar to that of pharyngoscopy. When the crico-pharynx is reached, the scope is used to lift the larynx anteriorly. This opens up the hypopharynx and the scope is passed beyond the cricopharyngeal sphincter into the oesophagus. It is important to stay strictly in the midline. The entire oesophagus can be inspected by slowly inserting the scope. The distance from the incisor teeth to the crico-pharyngeal sphincter is 15 cm (confirmed by checking the markings on the oesophagoscope),

and till the gastro-oesophageal junction is 40 cm. The oesophageal mucosa is inspected again while slowly withdrawing the scope.

#### *Postoperative care*

A patient can eat and drink once safely awake and be discharged on the same day. If there is a suspicion of perforation of the oesophagus, the patient needs to be nil by mouth and the water-soluble contrast swallow examination needs to be performed.

## 10.5 NASAL SEPTOPLASTY

#### *Indications*

Nasal septoplasty is usually performed to correct a deviated nasal septum causing nasal obstruction.

#### *Preoperative considerations*

It is performed under general anaesthesia. A patient is lying supine with the head-end elevated.

#### *Incision and approach*

The incision is placed just deep into the caudal end of the septal cartilage unilaterally and should include the mucosa and perichondrium of the septal cartilage (caudal septal incision, previously called hemitransfixion incision).

#### *Main procedure*

A flap containing the mucosa and the perichondrium is elevated using a Freer elevator on one side only. Posteriorly, the septum becomes bony, and the same instrument is used continue to elevate the muco-periosteum. Inferiorly is the maxillary crest, over which the periosteum is quite tightly adherent. It might be difficult to elevate the flap here initially, and tears in the flap are common. Loss of the mucoperichondrial flap should be avoided as much as possible. Deviated bony areas of the septum can be dealt with by partial removal or fracturing and straightening of the deviated bone. The maxillary crest can be excised or fractured into the midline. Cartilage

should be preserved. If deviated, it can be scored or shaved or minimally excised. Sutures can be used to hold it in the midline. Every operation is slightly different, and the technique might differ according to the need.

#### *Closure*

The flap is replaced towards the midline and incision is sutured with absorbable sutures. A nose may or may not be packed according to the preference of the operating surgeon. Care must be taken to avoid a septal haematoma — resorbable transseptal sutures or plastic splints can be used.

#### *Postoperative care*

It is advised to use oil-based drops and nasal douching with normal saline for several weeks after surgery. Splints stay in the nasal cavity for 5–7 days. Short-term decongestants might help with nasal congestion.

## 10.6 BASIC PRINCIPLES OF FUNCTIONAL ENDOSCOPIC SINUS SURGERY (FESS)

#### *Indications*

The most frequent indication for this operation are sinus diseases such as polypoid, chronic sinusitis, fungal sinusitis and recurrent acute sinusitis. The aim is to clear the sinuses of pathology and widen their ostia, to improve subsequent ventilation and drainage of secretions.

#### *Preoperative considerations*

The procedure is usually performed under general anaesthesia. The patient is placed in the supine position with slight elevation of the head. The nasal mucosa is decongested using patties soaked in diluted adrenaline (1:10,000) and kept in the nose for a few minutes.

*Main procedure*

An endoscope is passed through the nose. The important structures to visualise are the inferior turbinate, nasal septum, floor of the nose, choanae, middle turbinate, and structures in the middle meatus (uncinate process, bulla ethmoidalis and hiatus semilunaris). The procedure involves removal of structures in the middle meatus in order to widen the natural ostia of the sinuses. Usually, the first step is the removal of the uncinat process, which is called **uncinectomy**. This can be performed using a sickle knife, Freer elevator or back-biting forceps. Once the uncinat is removed, usually the natural ostium of the maxillary sinus can be visualised. This can be widened and antral pathology can be cleared. This is called **middle meatal antrostomy**. The bulla ethmoidalis is a part of the anterior ethmoid air cell system, and can be penetrated antero-inferiorly with a ball tip probe or Blakesley forceps. It can then be opened widely and removed. The rest of the anterior ethmoid air cells are removed: **anterior ethmoidectomy**. The ground lamella (attachment of middle turbinate to the lateral wall) can then be punctured to enter the posterior ethmoid air cells and, subsequently, into the sphenoid sinus (**posterior ethmoidectomy, sphenoidotomy**). If the frontal sinuses are involved, then the frontal recess must be opened in order to clear the frontal drainage pathway. The extent of surgery depends on the patient's pathology. In the case of polyps, a micro-debrider is extremely helpful. A micro-debrider cuts and removes the tissue at the same time to clear mucosal pathology. More complex surgeries may involve drilling of bone. Removable or dissolvable nasal packing is usually used at the end of the procedure.

During this procedure, the limits of surgical dissection are: superiorly the skull base and laterally the lamina papyracea. If the skull base is damaged, it can result in a cerebro-spinal fluid leak through the nose and the possibility of meningitis. If the lamina papyracea is breached, the orbital contents can be damaged. This can result in periorbital bruising and oedema, double vision, decreased visual acuity and even complete blindness. These are serious complications of the

procedure and need to be mentioned to the patient before the procedure.

*Postoperative care*

Nasal packing is removed on postoperative day 1. Nasal douching, decongestants and oil drops might be helpful in the postoperative period.

## 10.7 MYRINGOTOMY, GROMMET INSERTION

*Definition and indications*

Myringotomy is a surgical procedure making an incision in the eardrum. It is also called myringocentesis, tympanotomy, or paracentesis of the tympanic membrane. It is both a diagnostic and therapeutic procedure, and is used in the management of a wide range of otological disorders (acute otitis media, chronic otitis media with effusion, tympanic membrane retraction). The purpose of the myringotomy is to relieve symptoms, to restore hearing, to take a sample of the fluid to examine in the laboratory in order to identify any microorganisms present, or to insert ear tubes.

*Preoperative considerations*

In adult patients, the procedure can be done in the outpatient setting with the use of topical anaesthesia; children and infants require a brief general anaesthesia. The patient is in a supine position, and general anaesthesia with endotracheal intubation or with a laryngeal mask is given; the head of the patient is rotated away from the surgeon, to allow visualisation of the tympanic membrane.

*Incision and approach*

The operating microscope is brought into the field and focused on the external auditory canal. An appropriately sized speculum is carefully placed into the external auditory canal, and cerumen is removed so that the entire tympanic membrane can be visualised.

### *Main procedure*

The posteroinferior quadrant of the tympanic membrane is carefully incised with a myringotomy knife through the layers of the tympanic membrane. The incision should be approximately 3–5 mm in length. This permits direct access to the middle ear space and allows the release of middle ear fluid.

A myringotomy is often used to place middle ear ventilation tubes, which permit the incised drum to remain open and allow better drainage of middle ear fluid. Grommets, ear tubes, or tympanostomy tubes are small tubes open at both ends that are inserted into the incisions in the eardrums during myringotomy. They come in various shapes and sizes and are made of plastic, metal, or both. Because of the rapid healing properties of the tympanic membrane, myringotomy with aspiration of effusion has a shorter-lived benefit than myringotomy performed in conjunction with grommet placement.

### *Closure*

A single dose of antibiotic drops can be used after grommets are placed.

### *Postoperative care*

While the tubes are in place, they keep the incision from closing, which allows fresh air to reach the middle ear, allowing fluid to drain out, and preventing pressure from building up in the middle ear. They are left in place until they fall out by themselves or until they are removed.

## 10.8 MYRINGOPLASTY

### *Indications*

This operation is performed to repair a perforation of the tympanic membrane.

### *Preoperative considerations*

The procedure can be done under local or general anaesthesia. The operation is done using an operating microscope. The patient is put in a

supine position with the head turned to the side opposite the of surgery.

### *Incision and approach*

The approach can either be from behind the ear (retroauricular incision) or through the ear canal (endomeatal or endaural incision). A use of graft material is necessary to close the perforation. Commonly used grafts are: temporalis fascia, perichondrium (from tragal or conchal cartilage), fascia lata, vein grafts, adipose tissue or synthetic material such as AlloDerm. The graft is harvested at the beginning of the procedure. The next step is to freshen the margins of the perforation. This means that a few millimetres of the eardrum around the perforation are removed. An incision is made in the ear canal, from the 6 o'clock to 12 o'clock position posteriorly. The canal skin is elevated from the underlying bone until the annulus is reached.

### *Main procedure*

For simplicity, myringoplasty by an underlay technique will be described here. In the underlay technique, the annulus along with the remnant tympanic membrane is elevated laterally and anteriorly. This meatal skin and the tympanic membrane are called the tympano-meatal flap. Middle ear structures are inspected and the ossicular chain is checked. If repair of the ossicular chain is required, then some type of ossiculoplasty is performed. The middle ear can then be packed with Spongostan and the graft placed in situ. The tympano-meatal flap is replaced back on the graft. Care should be taken that the graft underneath extends beyond the edge of the perforation and no gap is left behind.

### *Closure*

The ear canal can be packed with Spongostan. The incision is closed in layers. Appropriate dressing is applied.

### *Postoperative care*

The packing of the ear canal is removed as part of the follow-up according to the type of surgery and the operating surgeon.

## 10.9 BASIC MASTOIDECTOMY

### *Indications*

Mastoidectomy on its own is performed for mastoiditis, otherwise it is usually performed as a part of various ear surgeries. The primary goal of the surgery is to completely remove infection so as to produce an infection free ear. There are several different types of mastoidectomy procedures that may be used depending on the surgeon's preference and the extent of infection present.

### *Preoperative considerations*

The surgery is performed under general anaesthesia, with endotracheal intubation. The patient is in the supine position, with the head rotated approximately 30–45° away from the surgeon.

### *Incision and approach*

The planned postauricular incision area is infiltrated with local anaesthetic with diluted adrenaline. A simple mastoidectomy consists of opening the mastoid cortex, and removing the infected cells. The operation is performed through the ear canal or through an incision behind the ear. The eardrum is incised to drain the middle ear. A postauricular incision from the mastoid tip to the linea temporalis is made 5–10 mm posterior to the postauricular sulcus. The skin and subcutaneous tissue are elevated off the mastoid periosteum and temporalis fascia with either sharp dissection with a scalpel or with monopolar cautery.

### *Main procedure*

An operating microscope with a 200–250mm objective and a high-speed electric or pneumatic drill with various bits and attachments are used in conjunction with copious suction and irrigation. A facial nerve monitor may be used, to help ensure that the facial nerve is not damaged. Drilling commences at the level of and parallel to the linea temporalis, and suction irrigation is used to keep the surgical area free of bone dust. Successful and safe mastoid surgery requires routine identification of key anatomic structures, including (but not limited to) the tegmen (middle fossa floor),

sigmoid sinus, external auditory canal, lateral semicircular canal, and facial nerve. A complete or canal wall up mastoidectomy necessitates the removal of all of the mastoid air cells along the tegmen, sigmoid sinus, presigmoid dural plate, and posterior wall of the external auditory canal – the posterior wall of the external auditory canal is preserved. Canal wall down mastoidectomy includes a complete mastoidectomy in addition to removal of the posterior and superior osseous external auditory canal – the tympanic membrane is reconstructed to separate the mucosal-lined middle ear space from the mastoid cavity and ear canal. A modified radical mastoidectomy is identical to a canal wall down mastoidectomy, except that the middle ear space and native tympanic membrane are not manipulated. A radical mastoidectomy is a canal wall down mastoidectomy in which the tympanic membrane and ossicles are not reconstructed.

### *Closure*

The postauricular incision is closed in layers using resorbable sutures to close the periosteum and subcutaneous tissues. The skin can be closed with absorbable or nonabsorbable sutures, a drainage tube, and a mastoid dressing is applied.

### *Postoperative care*

The facial nerve is checked after surgery. The patient needs to understand that early on sounds may echo and hearing might not be good because of blood, fluid, or bandages in the ear. Dressing care is administered.

## 10.10 EXCISION OF THE THYROGLOSSAL CYST (SISTRUNK PROCEDURE)

### *Indications*

This operation includes excision of the thyroglossal cyst in the midline neck in continuity with the mid portion of the body of the hyoid bone, together with a small block of muscle around the foramen caecum.



### *Preoperative considerations*

The patient is in the supine position, general anaesthesia is administered, and the patients shoulders are supported by the shoulder bag/roll.

### *Incision and approach*

A skin incision is made in a natural skin crease near the cyst; any previous incisions or sinus tracts are included in the elliptic incision.

### *Main procedure*

A superior skin flap is raised to the level of the hyoid bone, and an inferior flap is raised until the inferior aspect of the cyst is identified. The strap muscles are retracted, and the cyst is dissected from the surrounding structures until it is attached only to the hyoid bone superiorly. The body of the hyoid bone is skeletonised and then transected on each side of the pedicle. A curved retractor can be placed transorally, which facilitates excision of the tract up to the base of the tongue with the inclusion of a 5–10mm core of muscle.

### *Closure*

Meticulous haemostasis and closure of the wound in layers are performed. Usually, no drain is necessary.

## 10.11 THYROIDECTOMY

### *Definition and indications*

Hemithyroidectomy is removal of a thyroid lobe together with the isthmus. Total thyroidectomy is removal of all thyroid tissue. This chapter refers to capsular dissection of the thyroid gland. Indications for thyroid surgery include certain types of hyperthyroidism, nodular goitre and tumours of the thyroid (see also Chapter 7.4).

### *Preoperative considerations*

The patient is in a supine position, general anaesthesia is given, both shoulders are supported by the shoulder bag/roll, and the neck is in hyperextension.

### *Incision and approach*

A collar incision is made in the skin crease in the midline of the neck (Kocher incision). Skin flaps are developed and secured.

### *Main procedure*

The strap muscles are divided in the midline and retracted, and the avascular plane is developed on both sides; the superior laryngeal nerve is identified and the upper pole vessels are secured (harmonic scalpel, ligatures, clips). The recurrent laryngeal nerve needs to be identified and preserved in the tracheoesophageal groove or near ligamentum Berry. There are more ways in which to identify the nerve. A nerve monitor or nerve stimulator may be helpful, especially in revision surgery. Superior and inferior parathyroid glands are identified and preserved. In the case of blood supply compromise the gland is replanted into the muscle. One lobe of the thyroid gland together with the isthmus is removed. In the case of total thyroidectomy the same steps are repeated on the contralateral side. Meticulous haemostasis is performed in the Trendelenburg position using a Valsalva manoeuvre to minimise the risk of postoperative bleeding, and a suction drain may be used in certain patients.

### *Closure*

The strap muscles and platysma are reconstituted and the skin is closed atraumatically. A suction drain may be used.

### *Postoperative care*

Routine observation until the patient is fully awake. Several aspects need attention:

- *Postoperative bleeding* is a surgical emergency as it can lead to a compromised airway. Sutures need to be released immediately and the patient transferred to the operating room.
- In the case of total thyroidectomy, calcium levels need to be monitored every 12 hours and supplemented if hypocalcaemia develops.
- The function of the vocal cords needs to be checked.
- Drain if used can be removed if draining less than 30 ml in 12 hours.

- Thyroid hormone needs to be replaced in case of total thyroidectomy. A patient undergoing hemithyroidectomy usually does not require supplementation with thyroxine.

## 10.12 PARATHYROIDECTOMY

### *Definition and indications*

Parathyroidectomy is the removal of one or more parathyroid glands. Patients with primary hyperparathyroidism may either be symptomatic or asymptomatic.

### *Preoperative considerations*

The patient is in the supine position, general anaesthesia is given, both shoulders are supported by the shoulder bag/roll, and the neck is in hyperextension.

### *Incision and approach*

An approach similar to thyroidectomy can be used. Alternatively, if there is a well-localised parathyroid adenoma on preoperative scanning, a 2.0–2.5cm incision may be made directly over the location of the gland.

### *Main procedure*

Dissection continues through the platysma muscle, and the subplatysmal flaps are raised. If a localisation study suggests a unilateral abnormality, then the thyroid is mobilised first on that side. Some experienced surgeons advocate the return of bilateral parathyroid surgery. Most normal parathyroid glands are light brown in colour; this colouration helps to distinguish them from the surrounding adipose tissue, which is more yellow. In most situations, 10–15 minutes after the abnormal gland is removed, the PTH sample should be within normal limits and should have decreased by more than 50% from the initial baseline value. If it is not the case, a search for an adenoma should continue. If the patient has 4-gland hyperplasia or secondary hyperparathyroidism, then either 3.5 glands are removed or four glands are removed and autotransplantation subsequently performed.

### *Closure*

The wound is closed in layers, meticulous haemostasis is necessary, and usually no drain is needed.

### *Postoperative care*

Attention should be given to calcium levels, which can drop below the norm.

## 10.13 PAROTIDECTOMY

### *Definition and indications*

A parotidectomy is the surgical removal of the parotid gland. Most of the time, not all of the glandular tissue needs to be removed. In a superficial parotidectomy the part of the gland superficial to the level of the facial nerve is removed. In some cases, only the mass (with a good cuff of normal tissue) is removed without identification of the facial nerve (extracapsular dissection). For indications see Chapter 8.4.

### *Preoperative considerations*

General non-paralysing anaesthesia is given, and a facial nerve monitor is used.

### *Incision and approach*

The anterior skin incision can be placed in the preauricular crease, and the incision is continued inferior to the earlobe posteriorly and may be extended into the hairline or curved down to a natural skin crease in the neck. The incision is carried beyond the extent of the tumour.

### *Main procedure*

An anterior subplatysmal/subsuperficial musculoponeurotic system (SMAS) flap is made by using the natural plane on the surface of the gland. A posterior flap is then raised at the level of the sternocleidomastoid (SCM) fascia. The branches of the greater auricular nerve and the external jugular vein are identified, and a plane is developed superficial to these structures.

The tail of the parotid gland is elevated off the SCM until the posterior belly of the digastric

muscle is identified. The posterior portion of the gland is separated from the cartilage of the tragus and the external auditory canal. The facial nerve must be identified and preserved — any unnecessary stimulation of the nerve must be avoided. There are several ways to identify the main trunk of the facial nerve. Smaller branches are then followed carefully with the intention of mapping their relation to the tumour until all branches in the area of the tumour are dissected free and the tumour is mobilised for removal. A common technique for nerve dissection is to use fine forceps to elevate the parotid tissue in the natural plane just superficial to each nerve. The tissue lateral to and between the tines of the instrument is sealed with a bipolar cautery and divided. If the entire gland is to be removed and not just the cuff of the gland around the tumour, all of the facial nerve branches are dissected and mobilised, and the deep parotid tissue is then removed from between the branches.

#### *Closure*

Haemostasis is performed and the wound is closed in layers. A suction drain is used at the discretion of the surgeon.

#### *Postoperative care*

A drain is usually removed on postoperative day one, and the patient can then be discharged home.

## 10.14 MAIN PRINCIPLES OF THE NECK DISSECTION

#### *Definition and indications*

The neck dissection is a surgical procedure done under general anaesthesia and performed for the control of metastasis to the neck lymph nodes. This can be done for clinically or radiologically evident lymph nodes or as part of curative surgery where the risk of occult nodal metastasis is deemed sufficiently high. Nomenclature of neck dissections is still evolving.

#### *Preoperative considerations*

The neck is extended, head back, a shoulder roll inserted, and head slightly turned into the contralateral side. Local anaesthetic is injected in the proposed incision line.

#### *Incision and approach*

The type of incision is used according to the patient and extent of surgery. Incision is to be designed in such a way as to reach all of the dissected levels, and the superiormost aspect of the incision should reach the mastoid.

#### *Main procedure*

– *Levels IA* (between bilateral anterior bellies of digastric muscle and mandible) and *IB* (between anterior and posterior belly of the digastric muscle and the body of the mandible).

Landmarks to identify are the mandible, digastric muscle and hyoid bone. The marginal mandibular nerve and lingual and hypoglossal nerves are to be preserved. The submandibular gland is removed as part of the dissection.

– *Levels II* (between skull base and the hyoid bone), *III* (hyoid bone to omohyoid muscle), and *IV* (omohyoid muscle to clavicle)

Landmarks to be identified and structures to be preserved: anterior border of the sternocleidomastoid muscle (SCM), digastric muscle, omohyoid muscle, accessory nerve, jugular vein, carotid artery with branches, transverse cervical vessels, and vagal, phrenic and hypoglossal nerves. Care should be taken to preserve the thoracic duct in the left level IV to avoid a chyle leak. All of the adipose tissue is kept as one specimen and is lifted medially from above the level of the cervical plexus nerves and removed.

– *Level V* (between posterior border of sternocleidomastoid muscle and the anterior border of trapezius muscle and above the clavicle)

The deep limit is the plane of the prevertebral muscles. The accessory nerve must be identified in Erb's point (approx 1 cm cranially from the greater auricular nerve, where the nerve crosses the posterior aspect of the SCM in the same direction) and preserved.

– *Level VI* (anterior compartment between great neck vessels and recurrent nerves)

This level is usually cleared to treat some types of thyroid cancer. The anterior compartment group comprises lymph nodes surrounding the midline visceral structures of the neck extending from the level of the hyoid bone superiorly to the suprasternal notch inferiorly. Parathyroid glands and recurrent laryngeal nerves have to be identified and preserved. Perithyroidal lymph nodes, paratracheal lymph nodes, lymph nodes along the recurrent laryngeal nerves, and precricoid lymph nodes are being removed.

#### *Closure*

Meticulous haemostasis is paramount during and at the end of the procedure. A saline/water wash, Valsalva manoeuvre, and the positioning of the patient help with haemostasis. A suction drain should be used and the wound is closed in layers.

#### *Postoperative care*

The drain is taken care of — it can usually be removed once draining is less than 30 ml over 12 hours. Sutures/clips are taken out in 7–14 days.

## 10.15 SECURING AIRWAY – TRACHEOSTOMY, CONIOTOMY, ENDOTRACHEAL INTUBATION

#### *Definition and indications*

**Tracheostomy** is a surgically created opening in the trachea. The term for the surgical procedure to create this opening is **tracheotomy**. Most commonly it is performed as an elective procedure. Indications for tracheotomy have changed over the years and the procedure can be performed

due to the airway obstruction (tumours, craniofacial malformation, congenital abnormalities, trauma, bilateral vocal cord palsy, acquired laryngeal/tracheal stenosis) or for need of artificial ventilation (neuromuscular disease, central nervous system disorder, respiratory distress syndrome).

#### *Preoperative considerations*

With advances in technology and increasing interest in minimally invasive procedures, variations of the standard open tracheotomy have evolved (percutaneous dilatational tracheotomy). Standard tracheostomy is performed in operating theatres or at the bedside. The patient is typically under general anesthesia, intubated, in supine position with head extension.

#### *Incision and approach*

Skin incision is in front of trachea and can be horizontal or vertical.

#### *Main procedure*

The subcutaneous tissue and platysma are divided, the strap muscles are separated in midline, the thyroid isthmus is divided if needed. A hole between the second and third (or third and fourth) tracheal rings is done and tracheostomy tube is inserted.

---

#### **Tracheostomy in children**

A horizontal skin incision is made halfway between the cricoid cartilage and the sternal notch. The subcutaneous adipose tissue is removed and the deep cervical fascia is exposed, and incised. The isthmus is divided with the cautery. Sometimes, it is possible to expose the trachea by simply retracting the isthmus superiorly. Nonabsorbable sutures are placed through the tracheal rings on each side (these sutures are useful for applying traction to pull up and expose the trachea, and they can be lifesaving should accidental decannulation occur before the tract is established). A vertical cut is made in 2–3 rings in the midline, no part of the tracheal wall is removed. An appropriate size tracheostomy tube is inserted.

---

#### *Postoperative care*

The upper respiratory pathways are by-passed in tracheostomy and the humidification function of the nose is lost. The trachea quickly becomes dry, tends to crust, and thus obstructs the trachea or

tube. Patients with a tracheostomy must have humidification of the air they breathe; they should inhale and use the mucolytic agents. The regular suction several times a day and cleaning of tracheostomy daily are very important. Artificial nose (heat and moisture exchanger) might be attached to the tube. When a tracheostomy is no longer needed, it's allowed to heal shut or is surgically closed. For some people, a tracheostomy is permanent. **Complications** of tracheostomy can be immediate- bleeding, damage to the trachea, subcutaneous emphysema, damage to the trachea or esophagus, pneumothorax, hematoma, misplacement or displacement of the tracheostomy tube and long-term complications which are more likely the longer a tracheostomy is in place- displacement of the tracheostomy tube from the trachea, narrowing of the trachea, abnormal tissue formation in the trachea, obstruction of the tracheostomy tube, development of tracheo-oesophageal fistula or infection.

---

#### **Coniotomy (cricothyroidotomy)**

Coniotomy is an emergency procedure. The horizontal incision is made through the skin and cricothyroid membrane (between thyroid and cricoid cartilage) to establish a patent airway during certain urgent life-threatening situations, such as airway obstruction by a foreign body, angioedema, or massive facial trauma. It is nearly always performed as a last resort in cases where endotracheal intubation, emergency bronchoscopy or tracheotomy is impossible or contra-indicated.

---

### **Endotracheal intubation**

#### *Definition and indications*

Intubation is the placement of a tube into the trachea to maintain a patent airway in those who

are unconscious or unable to maintain their airway for other reasons. It is the first line treatment for acute airway obstruction. Intubation in some cases has replaced the tracheotomy for acute infectious airway obstruction. Also children after maxillofacial surgery are treated with intubation. Premature babies on artificial ventilation are often intubated for longer period; they tolerate intubation better than older infants and children, who should undergo tracheotomy in case intubation may last more than few weeks. It may be carried out without anesthesia in patients who are unconscious or a short intravenous anesthetic relaxant is used. Intubation is a technique that requires training, experience and regular updating to maintain competence. Alternative to intubation is laryngeal mask airway which is easier to insert, but it does not protect the airway from blood, saliva or vomit.

#### *Preprocedure considerations*

Patient should be aligned without deviation of head and neck, the head and neck should be mobile Pre-oxygenation with 100% oxygen for three minutes.

#### *Main procedure*

Intubation should not last for longer than 30 seconds. Hold the laryngoscope in left hand and introduce the laryngoscope over the right side of the tongue, sweeping the tongue to the mid-line. Position the tip of the blade in the vallecula and lift upwards and away from yourself until the glottis is visualized. Introduce the endotracheal tube through the vocal cords with the cuff positioned and inflated just beyond the cords. Ventilate and secure the tube.



## REFERENCES

- Bailey, B. J. – Johnson, J. T.: *Head and Neck Surgery – Otolaryngology*. Philadelphia: Lippincott Williams and Wilkins, 2006.
- Becker, W. – Naumann, H. H. – Pfaltz, C. R.: *Ear, Nose and Throat Diseases. A pocket reference*. Stuttgart: Thieme, 1994, 583 p.
- Behrbohm et al.: *Ear, Nose and Throat Diseases*. Stuttgart: Thieme, 2009.
- British Thyroid Association Guidelines for the Management of Thyroid Cancer. *Clinical Endocrinology*, vol. 81, Supplement 1 July 2014.
- Chole R. A. – McKenna M.: Pathophysiology of Otosclerosis. *Otol Neurotol* 2001; 22(2): 249-257.
- Conlin, A. E. – Parnes, L. S.: Treatment of Sudden Sensorineural Hearing Loss: A Systematic Review. In: *Arch Otolaryngol Head Neck Surg*. 2007; 133(6): 573-581.
- Cummings, C. W. – Flint, P. W. – Haughey, B. H. et al, eds. Cummings: *Otolaryngology: Head & Neck Surgery*. 4th ed. Philadelphia, PA: Elsevier, 2005.
- Dhingra, P. L.: *Diseases of ear, nose and throat*. Fourth edition. New Delhi: Elsevier, 2007, 426 p.
- Fokkens, W. – Lund, V. – Mullol, J. et al.: *Rhinology* 2012, vol 50 (Supl 23): 1-198.
- Gelfand, S. A.: *Essentials of Audiology*. 3rd ed. New York (USA): Thieme Medical Publishers Inc; 2009.
- Gleeson, M. – Browning, G. G. – Burton, M. J. – Clarke, R. – Hibbert, J. – Jones, N.S. – Lund, V.J. – Luxon, L. M. – Watkinson, J. C. editors. Scott-Brown's.: *Otorhinolaryngology and Head and Neck Surgery*. 7th ed. Vol. 3. Florida: CRC Press; 2013.
- Graham, J. M. – Scadding – G. K. – Bull, P. D.: *Pediatric ENT*. Berlin, Heidelberg: Springer Verlag, 2007.
- Hall, D. A. – Láinez, M. J. A. – Newman, C. W. – Sanchez, T. G. – Egler, M. – Tennigkeit, F. – Koch, M. – Langguth, B.: Treatment options for subjective tinnitus: Self reports from a sample of general practitioners and ENT physicians within Europe and the USA. *BMC Health Services Research* 2011, 11:302 doi:10.1186/1472-6963-11-302.
- Holland, N. J. – Weiner, G. M.: Recent developments in Bell's palsy. *BMJ* 2004; 329: 553.  
<http://emedicine.medscape.com/otolaryngology>
- Jakubíková, J.: *Vrozené anomálie hlavy a krku*. Praha: Grada Publishing, 2012.
- Kabátová, Z. – Profant, M. a kol.: *Audiológia*. Praha: Grada Publishing, 2012.
- Lejska, V.: *Kompendium ORL detského veku*. Praha: Grada Publishing, 1995.
- Ludman, H. – Bradley, P. J.: *ABC of Ear, Nose and Throat*. Singapore: Wiley-Blackwell, 2013, 151 p.
- Myers, E. N. et al.: *Operative otolaryngology Head and Neck Surgery*. Philadelphia: Saunders, 1997.
- Nixon, I. J. – Simo, R.: The neoplastic goitre. *Curr Opin Otolaryngol Head Neck Surg* 2013, 21: 143-149.
- Ohlrogge, M. – Francis, H. W.: Temporal bone fractures. *Otol Neurotol* 2004; 25(2): 195-196.
- Osma, U – Cureoglu, S. – Hosoglu, S.: The complications of chronic otitis media: report of 93 cases. *J Laryngol Otol*, 2000; 114(2): 97-100.
- Profant, M. et al: *Otolaryngológia* Bratislava: ARM 333, 2000.
- Sajjadi, H. – Paparella, M. M.: Meniere's disease. *Lancet* 2008; 372: 406-414.
- Snow, J. B. – Wackym, P. A. – Ballenger, J. J.: *Ballenger's otorhinolaryngology head and neck surgery*. Shelton, Conn: People's Medical Pub. House/B C Decker, 2009
- Warner, G. – Burgess, A. – Patel, S. – Martinez-Devesa, P. – Corbridge, R.: *Otolaryngology and Head and Neck Surgery*. Oxford: Oxford University, 2009.
- Witt, R. L. – Iro, H. – McGurk, M.: The Role of Extracapsular Dissection for Benign Parotid Tumors Current. *Otorhinolaryngology Reports*, June 2014, vol. 2, Issue 2, pp 55-63.

# LIST OF FIGURES

## THE EAR

Figure 1.1	Auricle-lateral surface.....	11
Figure 1.2	External auditory meatus .....	11
Figure 1.3a	Scheme of the middle ear – parts of the middle ear.....	12
Figure 1.3b	Scheme of the middle ear – ossicles .....	12
Figure 1.4	Levels of the tympanic cavity .....	12
Figure 1.5	Difference between the Eustachian tube in children and adults.....	13
Figure 1.6	Inner ear anatomy .....	14
Figure 1.7	Membranous labyrinth.....	14
Figure 1.8	Cross-section through the cochlea .....	15
Figure 1.9	Organ of Corti.....	16
Figure 1.10	Otoscopy.....	18
Figure 1.11	Tuning fork .....	19
Figure 1.12a	Tympanometer .....	20
Figure 1.12b	Patient interface .....	20
Figure 1.12c	Placement in the ear canal.....	20
Figure 1.13a	Tympanogram curves – Type A.....	20
Figure 1.13b	Tympanogram curves – Type B.....	20
Figure 1.13c	Tympanogram curves – Type C.....	20
Figure 1.14	Pure tone audiogram – normal hearing.....	21
Figure 1.15	Pure tone audiogram – conductive hearing loss.....	22
Figure 1.16	Pure tone audiogram – mixed hearing loss .....	22
Figure 1.17	Speech audiogram – normal (a), conductive loss (b), sensorineural loss (c), retrocochlear pathology (d).....	23
Figure 1.18	The ABR waveform.....	24
Figure 1.19	Apostasis auriculae before surgery (a), after surgery (b) .....	25
Figure 1.20	Microtia and atresia of the external auditory canal .....	25
Figure 1.21	Preauricular appendix .....	25
Figure 1.22a	Preauricular fistula ostium .....	26
Figure 1.22b	Perioperative picture – fistula leading under the branch of facial nerve.....	26
Figure 1.23a	Child with congenital anomaly of the external and middle ear.....	27
Figure 1.23b	Child with congenital anomaly of the external and middle ear; CT scan, axial plane .....	27
Figure 1.24	Auricular haematoma in child.....	29
Figure 1.25	Cauliflower ear .....	29
Figure 1.26	Ear canal syringing .....	30
Figure 1.27	Osteoma of the ear canal.....	31
Figure 1.28a	Squamous cell carcinoma of the external ear Clinical picture .....	32
Figure 1.28b	Primary closure .....	32
Figure 1.28c	Specimen.....	32
Figure 1.28d	Primary suture.....	32
Figure 1.29	Basal cell carcinoma of the auricle .....	33
Figure 1.30	Tympanic membrane with ventilation tube.....	34
Figure 1.31	Central tympanic membrane perforation .....	35
Figure 1.32	Retraction pocket in the epitympanum .....	36

Figure 1.33	Acute mastoiditis in child .....	38
Figure 1.34a	Gun shot with a bullet in the middle ear; plain radiograph, postero-anterior view .....	40
Figure 1.34b	Gun shot with a bullet in the middle ear; plain radiograph, lateral view .....	40
Figure 1.35	Transverse fracture of the temporal bone; CT scan, axial plane .....	41
Figure 1.36	Abnormalities of the cochlea – Mondini's malformation, CT scan.....	43
Figure 1.37	Otosclerosis – pure tone hearing test- Carhart's notch .....	44
Figure 1.38a	Principle of surgical treatment of otosclerosis. Sclerotic bone fixing footplate of stapes.....	45
Figure 1.38b	Principle of surgical treatment of otosclerosis. Piston as a part of ossicular chain .....	45
Figure 1.39a	Ménière's disease – Normal labyrinth.....	46
Figure 1.39b	Ménière's disease – Endolymphatic hydrops .....	46
Figure 1.40a	Symptoms of acoustic neuroma .....	49
Figure 1.40b	Acoustic neuroma; MRI scan, T2-weighted image, axial plane .....	49
Figure 1.40c	Acoustic neuroma; MRI scan, T2-weighted image, coronal plane .....	49
Figure 1.41	Pure tone hearing test – presbycusis .....	50
Figure 1.42	Epley manoeuvre .....	54
Figure 1.43	Facial nerve and the supranuclear connections.....	57
Figure 1.44	Facial nerve.....	59
Figure 1.45	Facial nerve palsy, right.....	60
Figure 1.46	Herpes zoster oticus .....	62

## NOSE AND PARANASAL SINUSES

Figure 2.1	External nose .....	64
Figure 2.2	Nasal septum.....	65
Figure 2.3	Nasal septum – blood supply .....	65
Figure 2.4	Lateral wall of nasal cavity, osteomeatal unit (red) .....	65
Figure 2.5	Paranasal sinuses – frontal view .....	66
Figure 2.6	Paranasal sinuses – right pansinusitis; plain radiograph, Waters' view .....	66
Figure 2.7	Anterior rhinoscopy .....	68
Figure 2.8	Posterior rhinoscopy .....	68
Figure 2.9a	Nasal endoscopy – nasal speculum, rigid and flexible endoscopes .....	69
Figure 2.9b	Nasal endoscopy –endoscopic view.....	69
Figure 2.10	Normal facial skelet; plain radiograph, postero-anterior view .....	69
Figure 2.11a	Normal paranasal sinuses; CT scan, axial plane .....	69
Figure 2.11b	Normal paranasal sinuses; CT scan, coronal plane.....	70
Figure 2.12a	Left sphenoid sinus cyst; MRI scan, axial plane .....	70
Figure 2.12b	Left sphenoid sinus cyst; MRI scan, coronal plane.....	70
Figure 2.12c	Left sphenoid sinus cyst; MRI scan, sagittal plane .....	70
Figure 2.13.	Visual analog pain scale.....	72
Figure 2.14	Chronic maxillary sinusitis; CT scan, axial plane.....	74
Figure 2.15	Nasal polyps – right nasal cavity .....	75
Figure 2.16	Unilateral nasal polyposis, left side; CT scan, coronal plane.....	75
Figure 2.17a	Frontal mucocele – anterior view.....	77
Figure 2.17b	Frontal mucocele – lateral view .....	77
Figure 2.18a	Orbital complications of sinusitis – normal .....	77
Figure 2.18b	Orbital complications of sinusitis – subperiosteal abscess .....	77
Figure 2.18c	Orbital complications of sinusitis – orbital abscess .....	77
Figure 2.19	Orbital cellulitis .....	78
Figure 2.20	Subperiosteal abscess in 8-year-old boy .....	78
Figure 2.21	Rhinophyma.....	80
Figure 2.22a	Osteoma of ethmoid sinuses; CT scan, axial plane .....	81
Figure 2.22b	Osteoma of ethmoid sinuses; CT scan, coronal plane.....	82
Figure 2.23	Fibrous dysplasia of right maxillar sinus; CT scan, axial plane.....	82
Figure 2.24a	Squamous cell carcinoma of external nose; Clinical picture .....	83

Figure 2.24b	Squamous cell carcinoma of external nose; CT scan, axial plane.....	83
Figure 2.25a	Öhngren's plane .....	84
Figure 2.25b	Sébileau levels .....	84
Figure 2.26	Nasal malignant melanoma.....	85
Figure 2.27a	Angiosarcoma .....	86
Figure 2.27b	Angiosarcoma; CT scan, axial plane.....	86
Figure 2.27c	Angiosarcoma; PET CT scan, axial plane.....	86
Figure 2.28	Nasal bone fracture; plain radiograph, lateral view .....	87
Figure 2.29	Right frontal sinus fracture; CT scan, axial plane .....	88
Figure 2.30a	Le Fort fractures – Typical fracture lines.....	88
Figure 2.30b	Patient with Le Fort II fracture .....	88
Figure 2.30c	Patient with Le Fort II fracture; CT scan, coronal plane.....	89
Figure 2.30d	Reconstruction with miniplates and titanium mesh .....	89
Figure 2.30e	One month after reconstruction .....	89
Figure 2.31	Blowout fracture; CT scan, coronal plane .....	90
Figure 2.32	Types of septal deviation .....	91
Figure 2.33	Septorhinoplasty – (a) before surgery, (b) after surgery .....	91
Figure 2.34	Septal perforation.....	92
Figure 2.35	Preformed silicone obturator.....	92
Figure 2.36	Anterior nasal packing .....	93
Figure 2.37a	Epistat Nasal Catheter – Epistat ready to be used.....	94
Figure 2.37b	Epistat Nasal Catheter – Epistat with inflated cuffs (10ml posterior, 20 ml anterior.....	94
Figure 2.38	Posterior nasal packing .....	94
Figure 2.39	Olfactory area .....	95
Figure 2.40	Choanal atresia; CT scan, axial plane .....	95

## ORAL CAVITY AND PHARYNX

Figure 3.1	Oral cavity and pharynx, lateral view .....	99
Figure 3.2	Faucial isthmus .....	99
Figure 3.3	Oropharynx, posterior view, posterior pharyngeal wall divided.....	100
Figure 3.4	Pharyngeal constrictors – posterior view .....	101
Figure 3.5	Nasopharynx – endoscopic view.....	101
Figure 3.6	Hypopharynx – endoscopic view.....	103
Figure 3.7a	Phases of swallowing – Oral preparatory and oral phase.....	104
Figure 3.7b	Phases of swallowing – Pharyngeal phase.....	104
Figure 3.7c	Phases of swallowing – Oesophageal phase .....	104
Figure 3.8	Tongue taste areas.....	105
Figure 3.9	Atrophy of the tongue and right-sided deviation, lesion of right hypoglossal nerve .....	106
Figure 3.10	Macroglossia.....	108
Figure 3.11	Adenoid hyperplasia .....	109
Figure 3.12	Adenoid face.....	109
Figure 3.13	Cheilitis.....	110
Figure 3.14	Pemphigus vulgaris.....	114
Figure 3.15	Acute tonsillitis .....	115
Figure 3.16a	Tonsillectomy; right tonsil partially removed .....	118
Figure 3.16b	Tonsillectomy.....	118
Figure 3.17a	Peritonsillar abscess right side; please note bulging of paratonsillar space, right side .....	120
Figure 3.17b	Peritonsillar abscess right side; CT scan, axial plane.....	120
Figure 3.18	Zenker’s diverticulum – pharyngeal pouch.....	123
Figure 3.19	Aspiration on videofluoroscopic examination .....	124
Figure 3.20	Oral fibroma.....	125
Figure 3.21a	Lower lip and floor of mouth haemangioma – skin.....	125
Figure 3.21b	Lower lip and floor of mouth haemangioma – intraoral portion.....	125

Figure 3.21c	Lower lip and floor of mouth haemangioma; CT scan, axial plane .....	125
Figure 3.22	SCC of the uvula.....	129
<b>OESOPHAGUS</b>		
Figure 4.1	Oesophagus.....	131
Figure 4.2	Oesophagogram; lateral view .....	132
Figure 4.3a	Surgical emphysema – pneumomediastinum; CT scan, axial plane .....	134
Figure 4.3b	Surgical emphysema, note air bubbles in the neck; CT scan, axial view.....	134
Figure 4.4	Ingested coin in the oesophagus; plain radiograph, postero-anterior view .....	135
Figure 4.5a	Postcorrosive stricture.....	136
Figure 4.5b	Dilatators.....	136
<b>LARYNX AND TRACHEA</b>		
Figure 5.1a	Larynx – anterior view.....	140
Figure 5.1b	Larynx – posterior view .....	140
Figure 5.2	Tracheobronchial tree .....	141
Figure 5.3	Intrinsic laryngeal muscles .....	142
Figure 5.4	Section of larynx in the coronal plane .....	142
Figure 5.5	Transverse section of the vocal fold .....	142
Figure 5.6	Trachea .....	143
Figure 5.7	Laryngeal nerves.....	144
Figure 5.8	Vocal cord vibrations.....	145
Figure 5.9	Respiratory and phonation positions of the vocal cords.....	145
Figure 5.10	Endoscopic view on flexible nasolaryngoscopy .....	146
Figure 5.11a	Bronchoscopy – flexible .....	147
Figure 5.11b	Bronchoscopy – rigid bronchoscopes .....	147
Figure 5.12	Indirect laryngoscopy .....	147
Figure 5.13	Acute laryngitis.....	151
Figure 5.14	Epiglottitis.....	153
Figure 5.15	Chronic laryngitis .....	154
Figure 5.16	Contact granuloma.....	155
Figure 5.17	Reinke’s oedema on the right side, partially retracted with instrument .....	156
Figure 5.18	Surgical treatment of Reinke’s oedema .....	156
Figure 5.19	Laryngeal papilloma .....	157
Figure 5.20	Retention cyst on the right vocal cord, polyp on the left vocal cord.....	157
Figure 5.21	Laryngeal cancer, T1b glottis .....	159
Figure 5.22	Types of endoscopic chordectomy.....	160
Figure 5.23	Hypopharyngeal cancer growing into right side of laryngeal inlet .....	161
Figure 5.24a	Adenoid cystic carcinoma of trachea – clinical picture .....	162
Figure 5.24b	Adenoid cystic carcinoma of the trachea – CT scan; axial scan.....	162
Figure 5.25	Foreign body in main bronchus .....	163
<b>NECK</b>		
Figure 6.1	Neck boundaries .....	165
Figure 6.2	Neck regions .....	166
Figure 6.3	Major blood vessels of the neck.....	167
Figure 6.4	Lymph nodes of the neck.....	168
Figure 6.5	Levels of the neck .....	168
Figure 6.6	Deep cervical fascia .....	169
Figure 6.7	Palpation of the neck.....	171
Figure 6.8a	Level VI recurrent lymph node; neck ultrasonography .....	172
Figure 6.8b	Doppler ultrasonography .....	172
Figure 6.9	CT with contrast of the neck in the axial plane at the level of the hyoid bone .....	172



Figure 6.10a	Esthesioneuroblastoma – preoperative (asterix marks the tumour); MRI scan, T1 – weighted image, sagittal plane .....	173
Figure 6.10b	Esthesioneuroblastoma – postoperative; MRI scan, T1 – weighted image, sagittal plane .....	173
Figure 6.11	Recurrent SCC in levels II-V right neck; PET CT, axial plane .....	173
Figure 6.12	Fine needle biopsy of submandibular gland lesion .....	173
Figure 6.13	Embryogenesis .....	174
Figure 6.14a	Branchial cyst .....	175
Figure 6.14b	Branchial cyst; CT scan, axial plane .....	175
Figure 6.14c	Branchial cyst; surgical specimen .....	175
Figure 6.15a	Neck abscess .....	177
Figure 6.15b	Neck abscess – Detail of pus draining from the ear .....	177
Figure 6.15c	Neck abscess; CT scan, axial plane .....	178
Figure 6.15d	Neck abscess; CT scan, sagittal plane .....	178
Figure 6.16	Haemangioma of the neck; CT scan, axial plane .....	181
Figure 6.17a	Lymphangioma of the neck .....	181
Figure 6.17b	Lymphangioma of the neck; MRI scan, coronal plane .....	181
Figure 6.18	Carotid body tumour, perioperative picture .....	182
Figure 6.19a	Madelung's disease – neck .....	183
Figure 6.19b	Madelung's disease – view of the back .....	183
Figure 6.19c	Madelung's disease – perioperative picture .....	184
Figure 6.19d	Madelung's disease – specimen .....	184
Figure 6.20	N3 metastasis .....	185
Figure 6.21a	Solitary metastasis to the neck (N2a); CT scan, axial plane .....	186
Figure 6.21b	Solitary metastasis to the neck (N2a); PET CT scan, axial plane .....	186
<b>THYROID AND PARATHYROID GLANDS</b>		
Figure 7.1	Thyroid gland – anterior view .....	188
Figure 7.2	Cross-section of the neck at the level of thyroid gland .....	188
Figure 7.3	Parathyroid glands in relation to the thyroid gland – posterior view .....	188
Figure 7.4a	Diffuse goitre – lateral view .....	189
Figure 7.4b	Diffuse goitre – anterior view .....	189
Figure 7.5	Recurrent laryngeal nerve during thyroidectomy – right side .....	190
Figure 7.6	Thyroid function regulation .....	190
Figure 7.7	Solitary 4.5cm well-defined relatively isoechoic nodule; USS thyroid .....	191
Figure 7.8	Fine needle aspiration biopsy – cytology specimen, Thy2 (Bethesda II), minimum six normal follicles visible, enlargement x60. Courtesy of Dr. Yen Yeo, Consultant Histopathologist, UHCW Coventry .....	192
Figure 7.9	Retrosternal goitre; CT scan, axial plane .....	192
Figure 7.10	Papillary thyroid cancer, neck recurrence; CT scan, axial plane .....	193
Figure 7.11	Hot nodule in the left lobe of thyroid; thyroid scintigraphy. Courtesy of Dr. Olu Adesanya, Consultant Radiologist, UHCW Coventry .....	193
Figure 7.12	Left lower parathyroid adenoma; MIBI scan, subtraction technique. Courtesy of Dr. Olu Adesanya, Consultant Radiologist, UHCW Coventry .....	193
Figure 7.13	Thyroglossal cyst .....	196
Figure 7.14	Anaplastic carcinoma of thyroid gland, involvement of trachea; CT scan, axial plane .....	199
Figure 7.15	Kocher incision .....	200
<b>SALIVARY GLANDS</b>		
Figure 8.1	Salivary glands .....	202
Figure 8.2	Facial nerve and its relation to the parotid gland .....	202
Figure 8.3	Salivary glands with the ducts .....	203
Figure 8.4	Pleomorphic adenoma of left superficial lobe of parotid gland; CT scan, axial plane .....	204
Figure 8.5	Pleomorphic adenoma in the left parotid gland; MRI scan, T2-weighted image, axial plane .....	204

---

Figure 8.6	Bimanual palpation of the submandibular gland .....	206
Figure 8.7a	Sialolith in the left submandibular gland; ultrasound scan .....	206
Figure 8.7b	Sialolith in the left submandibular gland CT .....	207
Figure 8.8	Tumour of the parotid gland .....	207
Figure 8.9	Malignant tumour of the left parotid gland; MRI scan, axial plane .....	208
Figure 8.10	Branches of facial nerve during superficial parotidectomy.....	208

**BASICS OF PHONiatrics**

Figure 9.1a	Hearing aid – With mould.....	214
Figure 9.1b	Hearing aid – “Open tip” hearing aid.....	215
Figure 9.2	Child with cochlear implant .....	215
Figure 9.3a	Artificial larynx – Electrolarynx .....	218
Figure 9.3b	Artificial larynx – Patient using the device .....	218
Figure 9.4	Tracheo-oesophageal shunt.....	219
Figure 9.5	Voice prosthesis .....	219
Figure 9.6	“Artificial nose” .....	219

# LIST OF TABLES

## THE EAR

Table 1.1	Degree of hearing loss .....	21
Table 1.2	Congenital anomalies of middle ear.....	33
Table 1.3	Complications of otitis media .....	37
Table 1.4	Differences between longitudinal and transverse temporal bone fractures .....	40
Table 1.5	Criteria for diagnosis of MD (American Academy of Otolaryngology and Head & Neck Surgery).....	47
Table 1.6	Common causes of SNHL .....	50
Table 1.7	Causes of sudden sensorineural hearing loss .....	52
Table 1.8	Causes of tinnitus.....	56
Table 1.9	Course of facial nerve .....	57
Table 1.10	House–Brackmann grading system of facial nerve paralysis (1985) .....	60
Table 1.11	Causes of facial nerve paralysis .....	61

## NOSE AND PARANASAL SINUSES

Table 2.1.	Complications of rhinosinusitis .....	76
Table 2.2.	Malignant melanoma .....	83
Table 2.3	Causes of epistaxis.....	93
Table 2.4	Aethiology of olfactory disorders .....	95

## ORAL CAVITY AND PHARYNX

Table 3.1	Other forms and types of acute tonsillitis .....	115
Table 3.2	Diseases associated with focal infection .....	117
Table 3.2	Surgical treatment options of peritonsillar abscess management.....	120

## LARYNX AND TRACHEA

Table 5.1	Grading of laryngeal dysplasia .....	158
-----------	--------------------------------------	-----

## NECK

Table 6.1	Division of neck nodes based on clinical grounds .....	168
-----------	--	-----

## THYROID AND PARATHYROID GLANDS

Table 7.1	Inflammation of the thyroid gland (according to Behrbohm et al., Ear, Nose, and Throat Diseases, Thieme, 2009).....	196
Table 7.2	U1 – U5 ultrasound classification of thyroid nodule .....	197
Table 7.3	Management of the thyroid nodule based on the FNA results .....	198
Table 7.4	Risk factors in assessment of the thyroid nodule .....	198

## SALIVARY GLANDS

Table 8.1	Differential diagnosis of diseases of salivary glands (according to Profant, 2000) .....	205
Table 8.2	Common primary epithelial salivary gland tumours .....	207

# LIST OF ABBREVIATIONS

ABR	auditory brainstem response	IAC	internal auditory canal
ACC	adenoid cystic carcinoma	IAM	internal auditory meatus
AIDS	acquired immunodeficiency syndrome	ICA	internal carotis artery
ANCAs	antineutrophil cytoplasmic antibodies	IHCs	inner hair cells
AOM	acute otitis media	ISSNHL	idiopathic sudden sensorineural hearing loss
ASSR	auditory steady state response	LOS	lower oesophageal sphincter
BAEP	brainstem auditory evoked potential	LPR	laryngopharyngeal reflux
BAER	brainstem auditory evoked response	MALT	mucosa-associated lymphoid tissue
BAHA	bone anchored hearing aid	MBS	modified barium swallow
BERA	brainstem evoked response audiometry	MD	Ménière's disease
BPPV	benign paroxysmal positional vertigo	MRI	magnetic resonance imaging
CPA	cerebellopontine angle	NARES	nonallergic rhinitis with eosinophilia syndrome
CRP C-	reactive protein	NBI	narrow band imaging
CRS	chronic rhinosinusitis	NG	naso-gastric
CSF	cerebrospinal fluid	NIHL	noise-induced hearing loss
CT	computed tomography	NPC	nasopharyngeal carcinoma
CUP	cancer of unknown primary	OA	oesophageal atresia
daPa	dekapascal	OAEs	otoacoustic emissions
dB	decibel	OHCs	outer hair cells
dB HL	decibel hearing level	OM	otitis media
EAC	external auditory canal	OME	otitis media with effusion
ECA	external carotid artery	OSA	obstructive sleep apnoea
ECochG	electrocochleography	OSAS	obstructive sleep apnoea syndrome
EGFR	epidermal growth factor receptor	PET	positron emission tomography
ENB	esthesioneuroblastoma	RNA	ribonucleic acid
ENT	ear, nose, throat	SCC	squamous cell carcinoma
EBV	Epstein-Barr virus	SNHL	sensorineural hearing loss
EEG	electroencephalogram	SNM	sinusal malignancies
ESR	erythrocyte sedimentation rate	SSNHL	sudden sensorineural hearing loss
EXIT	ex utero intrapartum treatment	TEP	tracheoesophageal puncture
FBC	full blood count	TM	tympanic membrane
FDG	fluorodeoxyglucose	TOF	tracheoesophageal fistula
FEES	flexible endoscopic evaluation of swallowing	UOS	upper oesophageal sphincter
FESS	functional endoscopic sinus surgery	US, USS	ultrasonography
FNA	fine needle aspiration	VAS	visual analog scale
GPA	granulomatosis with polyangiitis	VEMP	vestibular evoked myogenic potential
HAART	highly active anti-retroviral therapy	VFSS	videofluoroscopy
HIV	human immunodeficiency virus	VRA	visual reinforcement audiometry
HPV	human papilloma virus	VRT	vestibular rehabilitation therapy
HRCT	high resolution computed tomography		

# INDEX

## A

Abscess  
~ Bezold's 37, 39  
~ brain 37  
~ Citelli's 37, 39  
~ deep neck space 37  
~ epidural 79  
~ extradural 37  
~ intracerebral 80  
~ Luc's 37, 39  
~ mediastinal 121  
~ neck 177  
~ orbital 79  
~ parapharyngeal 121  
~ paratonsillar (peritonsillar) 119, 222  
~ post-aural 9  
~ retropharyngeal 121, 177  
~ septal 92  
~ subperiosteal 78  
~ subdural 37, 79  
Accessory nerve 168, 169  
Acoustic neuroma 48  
Actinomycosis 180  
Adam's Apple 165  
Additus ad antrum 13  
Adenoidectomy 107, 222  
Adenoids 102, 103, 109  
Agranulocytosis 116  
Achalasia 138  
AIDS 112  
Air conduction 19, 21  
Ansa cervicalis 168  
Antrum 13  
Aphasia 212  
Aphonia 217  
Apraxia 212  
Arytenoid cartilage 141  
Audiogram 21  
Audiometry 21  
~ conditioned play 23  
~ pure tone 21  
~ speech 23  
~ visual reinforcement 22

Auditory brainstem response 23  
Auricle 11, 28  
Aqueduct  
~ vestibular 14  
~ cochlear 14

## B

Basilar membrane 15  
Bell's palsy 61  
Benign paroxysmal positional vertigo 54  
Biopsy 173, 176  
Blowout fracture 90  
Bonebridge 216  
Bone anchored hearing aid 27, 216  
Bone conduction 19, 21  
Bony labyrinth 13  
Branchial apparatus 174  
Bronchi 141, 143

## C

Cancer of unknown primary 186  
Carbuncle 176  
Carina 143  
Carcinoma  
~ adenocarcinoma 85  
~ adenoid cystic 85  
~ basal cell 32, 82  
~ squamous cell 32, 41, 83, 84, 126, 158  
Carhart's notch 44  
Carotid artery 166  
~ common 166, 167  
~ external 100, 102, 166  
~ internal 167  
~ sheath 170  
Cat scratch disease 179  
Cerumen 11, 30  
Cervical fascia 169  
~ deep 169  
~ superficial 169  
Cleft lip and palate 107  
Cochlea 12, 15

Cochlear implant 215  
Common cold 72  
Congenital anomalies  
~ external ear 25  
~ inner ear 43  
~ larynx 147  
~ middle ear 33  
~ neck 174  
~ nose 95  
~ oesophagus 133  
~ oral cavity 107  
~ pharynx 107  
~ trachea 147  
Concha (inferior, middle, superior) 65  
Coniotomy 141, 231  
Cordecomy 159  
Cough 145  
Cranial nerves 168  
Cranial sympathetic nervous system 169  
Cricoid cartilage 101, 140, 141, 143  
Croup 152  
Cyst  
~ dermoid 96, 171, 174  
~ lateral neck 174  
~ retention 157  
~ thyroglossal duct 171, 175, 195

## D

Deafness 43  
Deep neck spaces 170  
Delphian node 144  
Dermoid cyst 96, 171  
Diphtheria 116  
Diplopia 78  
Dix-Hallpike test 54  
Dysarthria 212  
Dysphonia 217

## E

Ear 11  
~ anatomy 11



- ~ evaluation 18
- ~ external 11
- ~ middle 11
- ~ inner 11
- Endocrine orbitopathy 194
- Endolymph 14
- Endoscopy
  - ~ flexible 68, 106, 146
  - ~ rigid 68, 106, 146
- Epiglottis 100, 102, 140, 141
- Epiglottitis 152
- Epistat 94
- Epistaxis 64, 93, 125
- Epitympanum 12
- Epley manoeuvre 55
- Erysipelas 71
- Esthesioneuroblastoma 88
- Eustachian tube 12, 13, 34, 68, 73, 102
  - ~ orifice 101
- External auditory meatus (canal) 11
  - ~ exostoses 31
  - ~ foreign bodies 31
  - ~ atresia 26
- External ear 11
  - ~ congenital anomalies 25
  - ~ diseases 25
  - ~ foreign bodies 31
  - ~ trauma 29
  - ~ tumors 31
- External otitis 27
- External nose 64
  - ~ inflammatory diseases 71
- F**
- Facial nerve 57, 101, 208
  - ~ paralysis 28, 37, 60, 208
- Fallopian canal 58
- Fascia 169
  - ~ fascial planes 169
  - ~ fascial spaces 177
- Faucial isthmus 99, 102
- FESS 74, 224
- Fibrous dysplasia 82
- Fine needle aspiration 173, 191, 197, 204, 208
- Fistula
  - ~ branchial (lateral neck) 175
  - ~ thyroglossal duct 175
- Floor of the mouth 99, 100
- Focal infection 117
- Foramen caecum 100, 103
- Foreign bodies
  - ~ external ear 31
  - ~ nose 97
  - ~ oesophagus 135
  - ~ pharynx 122
  - ~ upper airway 163
- Fossa of Rosenmüller 102
- Free field testing 22
- Furuncle 71, 176
- G**
- Gelle test 19
- Glomus tumours 41, 182
- Glossitis 114
- Glossopharyngeal nerve 101, 103, 169
- Glottis 142
- Goitre 189
- Granulomatosis with polyangiitis 97
- Grommet insertion 225
- H**
- Haemangioma 81, 96, 125, 180
  - ~ subglottic 149
- Haematoma of the auricle 29
- Hair cells
  - ~ inner 16
  - ~ outer 16, 24
- Hearing aid 214
- Hearing tests 19
- Hearing loss 19, 21, 45, 48, 211, 212
  - ~ acquired 213
  - ~ bilateral 50
  - ~ conductive 34, 213
  - ~ congenital 49
  - ~ degrees 21, 213
  - ~ fluctuating 45, 48
  - ~ hereditary 213
  - ~ mixed 213
  - ~ noise-induced 51
  - ~ presbycusis 50
  - ~ rehabilitation 214
  - ~ sensorineural 22, 38, 49, 213
  - ~ sudden sensorineural 48, 52
  - ~ treatment 214
  - ~ type 21
  - ~ unilateral 48, 50
- Hearing screening 25, 211
- Hemithyroidectomy 200
- Herpes zoster oticus 62
- HIV 180
- Hoarseness 145
- House–Brackmann grading system 60
- Human papilloma virus 156
- Hypoglossal nerve 101, 168
- Hypopharyngeal carcinoma 161
- Hypopharynx 99, 102, 106
- Hyperthyroidism 194
- Hypothyroidism 194
- Hypotympanum 12
- CH**
- Choana 64, 68, 101
- Choanal atresia 95
- Cholestatoma 18, 36
- Chondroma 157
- Chorda tympani 58
- I**
- Impedance audiometry 19
- Incus 12
- Infectious mononucleosis 116, 179
- Inner ear 11
  - ~ anomalies 43
  - ~ tumors 48
- J**
- Jugular foramen 167, 169
- Jugular vein 166
  - ~ external 167
  - ~ internal 166
- Juvenile angiofibroma 107, 125
- K**
- Kaposi sarcoma 112
- Kiesselbach's plexus 64, 91
- Killian's dehiscence 101, 102
- L**
- Labyrinth
  - ~ bony 13
  - ~ membranous 14
- Labyrinthitis 38, 55
- Language 211
  - ~ disorder 212
- Laryngeal nerve
  - ~ recurrent 140, 143, 188, 189
  - ~ superior 140, 143, 189
- Laryngectomy 160, 218
- Laryngitis
  - ~ acute 151

- ~ chronic 153
- ~ subglottic 152
- Laryngocele 149
- Laryngomalacia 148
- Laryngoscopy 146, 223
  - ~ indirect 147
- Larynx
  - ~ anatomy 140
  - ~ carcinoma 158
  - ~ congenital anomalies 147
  - ~ evaluation 146
  - ~ foreign bodies 163
  - ~ inflammatory disease 151
  - ~ physiology 144
  - ~ trauma 150
  - ~ tumors 155
- Le Fort fractures 88
- Leukoplakia 113, 158
- Light reflex 18
- Lingual nerve 101
- Lingual tonsil 100, 103
- Lipoma 183
- Little's area 64, 91
- Lymphadenitis
  - ~ acute 176
  - ~ chronic 177
- Lymphadenopathy 177
  - ~ specific 179
- Lymphangioma 125, 181
- Lyme disease 179
- Lymph nodes 127, 144, 161, 67, 176, 185
  - ~ retropharyngeal 121
- Lymphoma 177
  
- M**
- Madelung's disease 183
- Malignant melanoma 83, 85
- Malleus 12
- Mastoid 13
- Mastoidectomy 227
- Mastoiditis 37
- Mediastinitis 177, 178
- Meningitis 39, 79
- Mesotympanum 12
- Ménière's disease 45, 55
- Microlaryngoscopy 146
- Miculicz disease 206
- Middle ear 11
  - ~ anomalies 33
  - ~ carcinoma 43
  - ~ diseases 33
- ~ trauma 39
- ~ tumors 41
- ~ inflammation 33
- Mucocele 76
- Mucociliary transport 12, 13
- Mumps 204
- Muteness 212
- Myringitis 29
- Myringoplasty 226
- Myringotomy 225
  
- N**
- Narrow band imaging 107
- Nasal
  - ~ bone fracture 87
  - ~ cavity 64, 100, 101
  - ~ endoscopy 68
  - ~ packing 94
  - ~ polyp 74
  - ~ septum 64, 68, 91
  - ~ septum deviation 89
  - ~ septal haemangioma 90
  - ~ spetal perforation 90
- Nasolacrimal duct 65
- Nasopharynx 99, 101, 106, 125, 126
- Nasopharyngeal carcinoma 126
- Neck
  - ~ anatomy 165
  - ~ diseases 174
  - ~ dissection 127, 129, 160, 185, 230
  - ~ evaluation 170
  - ~ inflammatory diseases 176
  - ~ levels 168
  - ~ lymph nodes 168
  - ~ physiology 165
  - ~ regions 165, 168
  - ~ spaces 170
  - ~ trauma 180
  - ~ vascular malformations 180
- Necrotising fasciitis 178
- Neurinoma 48, 184
- Neurofibromatosis 48
- Nose
  - ~ anatomy 64
  - ~ congenital anomalies 95
  - ~ diseases 71
  - ~ evaluation 68
  - ~ foreign bodies 97
  - ~ physiology 67
  - ~ trauma 87
- ~ tumors 80
- Nystagmus 17, 38, 54
  
- O**
- Obstructive sleep apnoea 109
- Oesophagography 132
- Oesophagoscopy 133, 223
- Oesophageal atresia 133
- Oesophagus
  - ~ anatomy 131
  - ~ congenital anomalies 133
  - ~ diseases 133
  - ~ evaluation 132
  - ~ inflammatory diseases 133
  - ~ motility disorders 138
  - ~ physiology 132
  - ~ trauma 134
  - ~ tumors 137
- Öhngren's plane 84
- Olfactory disorders 95
- Oral cavity
  - ~ anatomy 99
  - ~ carcinomas 127
  - ~ congenital anomalies 107
  - ~ diseases 107
  - ~ evaluation 106
  - ~ inflammatory diseases 110
  - ~ physiology 103
  - ~ tumors 124
- Orbit 65
- Orbital
  - ~ abscess 79
  - ~ cellulitis 78
- Organ of Corti 15
- Oropharynx 99, 100, 102, 106
- OSAS 109
- Ossicles 12
- Osteoma 31, 81
- Osteomeatal complex 67
- Osteomyelitis 77
- Otitis externa 27
  - ~ malignant 28
- Otitis media 33, 73
  - ~ acute 34
  - ~ chronic 35
  - ~ complications 37
  - ~ with effusion 34
- Otoacoustic emissions 24
- Otomycosis 28
- Otosclerosis 43
- Otoscopy 18
- Ototoxicity 51
- Oval window 13

- P**  
 Palate  
 ~ hard 99  
 ~ soft 99, 102  
 Papilloma 81  
 ~ inverted (Schneiderian) 81  
 ~ squamous 31  
 Papillomatosis 156, 162  
 Paracusis Willisii 44  
 Paraganglioma 41, 182  
 Paranasal sinuses  
 ~ anatomy 66  
 ~ diseases 71  
 ~ evaluation 68  
 ~ physiology 67  
 Parathyroid gland 188  
 ~ adenoma 195  
 Parathyroidectomy 229  
 Parotidectomy 229  
 Perichondritis 29  
 Perilymph 13, 14  
 Peritonsillar abscess 119  
 Petrositis 38  
 Pharyngeal  
 ~ pouch 122  
 ~ recess 102  
 ~ tonsil 102  
 Pharyngitis 118  
 Pharyngoscopy 223  
 Pharynx  
 ~ anatomy 101  
 ~ carcinoma 128, 161  
 ~ congenital anomalies 107  
 ~ diseases 107  
 ~ evaluation 106  
 ~ hypopharynx 99, 102, 106  
 ~ nasopharynx 99, 101, 106, 125, 126  
 ~ oropharynx 99, 100, 106  
 ~ physiology 103  
 ~ tumors 124  
 Phlegmona 177  
 Phoniatics 211  
 Pleomorphic adenoma 207  
 Phonation 144  
 Phrenic nerve 168  
 Piriform sinus 102, 142  
 Platysma 165  
 Plaut-Vincent angina 116  
 Preauricular fistula 26  
 Preseptal cellulitis 78  
 Presbycusis 48  
 Prominentia mallearis 18  
 Promontory 13  
 Pure tone audiometry 21  
 Pyrifrom sinus 100
- R**  
 Recurrent laryngeal nerve 143  
 Reinke's space 142  
 Reinke's oedema 155, 163  
 Respiration 145  
 Rhinoscopy  
 ~ anterior 68  
 ~ posterior 68  
 Rhinitis  
 ~ allergic 73  
 ~ drug induced 76  
 ~ hormonal 75  
 ~ medicamentosa 76  
 ~ occupational 75  
 ~ vasomotor 75  
 Rhinosinusitis 71  
 ~ acute 72  
 ~ chronic 74  
 ~ complications 76  
 ~ intracranial complications 79  
 ~ orbital complications 77  
 Rhinophyma 80  
 Rinne test 19
- S**  
 Sacculle 14  
 Salivary glands 97, 202  
 ~ anatomy 202  
 ~ diseases 204  
 ~ evaluation 203  
 ~ parotid 202  
 ~ physiology 203  
 ~ sublingual 100, 203  
 ~ submandibular 100, 202  
 ~ tumors 207  
 Sarcoidosis 179  
 Scintigraphy 193, 195  
 Semicircular canal 14, 15, 17  
 Septal  
 ~ abscess 92  
 ~ haematoma 92  
 ~ perforation 92  
 Septoplasty 91, 224  
 Septorhinoplasty 91  
 Schwabach test 19  
 Schwartze sign 44  
 Sialendoscopy 207  
 Sialolithiasis 206  
 Sialosis 205  
 Sinonasal malignancies 84  
 Sinuse (paranasal)  
 ~ ethmoid 66  
 ~ frontal 66  
 ~ maxillary 66  
 ~ sphenoid 67  
 Sinusitis 71  
 Sistrunk procedure 196, 227  
 Sjögren's syndrome 205  
 Sleep apnoea (OSA, OSAS) 109  
 Suttering 212  
 Soft palate 99, 102  
 Sound waves 16  
 Speech 100, 105, 160, 211  
 ~ disorder 212  
 Stapedotomy 45  
 Stapedius (stapedial) reflex 19, 21, 58  
 Stapes 12  
 ~ footplate 13  
 Stensen's duct 99  
 Sternocleidomastoid muscle 166  
 Stomatitis 110  
 Stridor 147  
 Stroboscopy 146  
 Syringing of EAC 30  
 Stria mallearis 18  
 Subglottic haemangioma 149  
 Subglottic stenosis 148  
 Swallowing 98, 104, 141  
 ~ disorders 107, 124  
 Syphilis 116, 179
- T**  
 Taste 100, 105  
 Temporal bone fractures 39  
 Thoracic duct 168  
 Thrombosis  
 ~ cavernous sinus 76, 80  
 ~ internal jugular vein 121  
 ~ sigmoid sinus 38  
 ~ venous sinus 80  
 Thyroid cartilage 140  
 Thyroid gland 188  
 ~ anatomy 188  
 ~ cancer 198  
 ~ congenital anomalies 195  
 ~ diseases 194  
 ~ evaluation 190  
 ~ nodules 197  
 ~ physiology 189  
 ~ surgery 200

- Thyroidectomy 228  
Thyroiditis 196  
Thyroglossal duct 100  
Thyrotoxicosis 194  
Tinnitus 19, 45, 48, 55  
Tongue 100  
  ~ base of the tongue 100, 102  
  ~ carcinoma 127, 128  
  ~ inflammatory diseases 114  
Tonsil  
  ~ carcinoma 128  
  ~ lingual 100, 103  
  ~ palatine 99, 102, 103  
  ~ pharyngeal (adenoid tissue) 102, 103  
  ~ tubarius 103  
Tonsillar hyperplasia 109  
Tonsillectomy 109, 117, 221  
Tonsillitis  
  ~ acute 115  
  ~ chronic 117  
Tonsillogenic sepsis 121  
Tonsillotomy 109, 118  
Torticollis 121, 182  
Torus tubarius 101, 102  
Total thyroidectomy 200  
Toxoplasmosis 179  
Tuberculosis 179  
Tularaemia 179  
Trachea 140, 141  
  anatomy 143  
  congenital anomalies 149  
    ~ foreign bodies 163  
    ~ physiology 145  
    ~ trauma 151  
    ~ tumors 162  
  Tracheal stenosis 149  
  Tracheobronchial tree 141  
  Tracheoesophageal fistula 133, 149  
  Tracheobronchoscopy 146  
  Tracheomalacia 149  
  Tracheostomy 147, 149, 152, 160, 231  
  Trigeminal nerve 101  
  Trismus 119, 177  
  Truncus lymphaticus dexter 168  
  Tubotympanic inflammation 34  
  Tuning forks 19  
  Turbinate (inferior, middle, superior) 65, 68  
  Tympanic cavity 12  
  Tympanic membrane 12, 13  
    ~ pars flaccida 18  
    ~ pars tensa 18  
    ~ perforation 35  
    ~ retraction pocket 36  
  Tympanogram 20  
  Tympanometry 20
- U**  
Utricle 14  
Uvula 102
- V**  
Vagus nerve 103, 140, 143, 166, 169, 190  
Ventilation tube 34  
Vertigo 17, 38, 45, 53  
Vestibular neuronitis 55  
Vestibular schwannoma 48  
Vestibular system 14, 17  
Vestibule 14  
Vestibulocochlear nerve 14, 15  
Vibrant soundbridge 216  
Visual reinforcement audiometry 22  
Vocal cord (fold) 140, 142, 145  
  ~ paralysis (palsy) 144, 148, 163, 190  
  ~ polyp 155  
Voice disorders 216
- W**  
Waldeyer`s ring 103, 105  
Weber test 19  
Whartin`s tumor 207  
Wharton`s duct 100
- Z**  
Zenker`s diverticulum 102, 122

# APPENDIX

## TNM Classification for Head and Neck Cancer (American Joint Committee on Cancer: the 7th edition, 2010)

The TNM classifications for cancers of the head and neck along with anatomic staging and histological grading are provided below. World Health Organization (WHO) criteria are supplied for the nasopharynx.

### Oral cavity and larynx TNM classification

<b>Primary tumor (T)</b>	
TX	Primary tumor cannot be assessed
T0	No evidence of primary tumor
Tis	Carcinoma in situ
T1	Tumor 2 cm or less in greatest dimension
T2	Tumor > 2 cm but not more than 4 cm in greatest dimension
T3	Tumor > 4 cm in greatest dimension
T4a	Moderately advanced local disease Lip – Tumor invades through cortical bone, inferior alveolar nerve, floor of mouth, or skin of face Oral cavity – Tumor invades adjacent structures (eg, through cortical bone into deep extrinsic muscle of the tongue, maxillary sinus, or skin of face)
T4b	Very advanced local disease Tumor invades masticator space, pterygoid plates, or skull base and/or encases internal carotid artery
<i>Glottis:</i>	
TX	Primary tumor cannot be assessed
T0	No evidence of primary tumor
Tis	Carcinoma in situ
T1	Tumor limited to the vocal cord(s) (may involve anterior or posterior commissure) with normal mobility
T1a	Tumor limited to 1 vocal cord
T1b	Tumor involves both vocal cords
T2	Tumor extends to the supraglottis and/or subglottis, and/or with impaired vocal cord mobility



T3	Tumor limited to the larynx with vocal cord fixation and/or invasion of the paraglottic space, and/or inner cortex of the thyroid cartilage
T4a	Moderately advanced local disease Tumor invades through the outer cortex of the thyroid cartilage and/or invades tissues beyond the larynx (eg, trachea, soft tissues of the neck, including deep extrinsic muscle of the tongue, strap muscles, thyroid, or esophagus)
T4b	Very advanced local disease Tumor invades prevertebral space, encases carotid artery, or invades mediastinal structures
<i>Supraglottis:</i>	
TX	Primary tumor cannot be assessed
T0	No evidence of primary tumor
Tis	Carcinoma in situ
T1	Tumor limited to 1 subsite of the supraglottis with normal vocal cord mobility
T2	Tumor invades mucosa of more than 1 adjacent subsite of the supraglottis or glottis or region outside the supraglottis (eg, mucosa of base of the tongue, vallecula, medial wall of piriform sinus) without fixation of the larynx
T3	Tumor limited to the larynx with vocal cord fixation and/or invades any of the following: postcricoid area, pre-epiglottic space, paraglottic space, and/or inner cortex of the thyroid cartilage
T4a	Moderately advanced local disease Tumor invades through the thyroid cartilage and/or invades tissues beyond the larynx (eg, trachea, soft tissues of the neck, including deep extrinsic muscle of the tongue, strap muscles, thyroid, or esophagus)
T4b	Very advanced local disease Tumor invades prevertebral space, encases carotid artery, or invades mediastinal structures
<i>Subglottis:</i>	
TX	Primary tumor cannot be assessed
T0	No evidence of primary tumor
Tis	Carcinoma in situ
T1	Tumor limited to the subglottis
T2	Tumor extends to vocal cord(s) with normal or impaired mobility
T3	Tumor limited to the larynx with vocal cord fixation
T4a	Moderately advanced local disease Tumor invades cricoids or thyroid cartilage and/or invades tissues beyond the larynx (eg, trachea, soft tissues of the neck, including deep extrinsic muscle of the tongue, strap muscles, thyroid, or esophagus)
T4b	Very advanced local disease Tumor invades prevertebral space, encases carotid artery, or invades mediastinal structures
<b>Regional lymph nodes (N)</b>	
NX	Regional nodes cannot be assessed
N0	No regional lymph node metastasis

N1	Metastasis in a single ipsilateral lymph node 3 cm or less in greatest dimension
N2	Metastasis in a single ipsilateral lymph node > 3 cm but not more than 6 cm in greatest dimension; or in multiple ipsilateral lymph nodes, none > 6 cm in greatest dimension; or in bilateral or contralateral lymph nodes, none > 6 cm in greatest dimension
N2a	Metastasis in a single ipsilateral lymph node > 3 cm but not more than 6 cm in greatest dimension
N2b	Metastasis in multiple ipsilateral lymph nodes, none > 6 cm in greatest dimension
N2c	Metastasis in bilateral or contralateral lymph nodes, none > 6 cm in greatest dimension
N3	Metastasis in a lymph node > 6 cm in greatest dimension
<b>Distant metastasis (M)</b>	
M0	No distant metastasis
M1	Distant metastasis

**Histologic grade**

<b>Histologic grade (G)</b>	
GX	Grade cannot be assessed
G1	Well differentiated
G2	Moderately differentiated
G3	Poorly differentiated
G4	Undifferentiated

**Nasopharynx  
WHO criteria**

Type 1	Differentiated squamous cell carcinoma
Type 2	Nonkeratinizing carcinoma
Type 3	Undifferentiated carcinoma

**Anatomic stage/prognostic groups**

<b>Stage</b>	<b>T</b>	<b>N</b>	<b>M</b>
0	Tis	N0	M0
I	T1	N0	M0
II	T2	N0	M0
III	T3	N0	M0
	T1	N1	M0
	T2	N1	M0
	T3	N1	M0
IVA	T4a	N0	M0
	T4a	N1	M0
	T1	N2	M0
	T2	N2	M0
	T3	N2	M0
	T4a	N2	M0
IVB	T Any	N3	M0
	T4b	N Any	M0
IVC	T Any	N Any	M1

**TNM classification**

<b>Primary tumor (T)</b>	
TX	Primary tumor cannot be assessed
T0	No evidence of primary tumor
Tis	Carcinoma in situ
T1	Tumor confined to the nasopharynx, or tumor extends to oropharynx and/or nasal cavity without parapharyngeal extension (eg, without posterolateral infiltration of tumor)
T2	Tumor with parapharyngeal extension (posterolateral infiltration of tumor)
T3	Tumor involves bony structures of skull base and/or paranasal sinuses
T4	Tumor with intracranial extension and/or involvement of cranial nerves, hypopharynx, or orbit, or with extension to the infratemporal fossa/masticator space
<b>Regional lymph nodes (N)</b>	
NX	Regional nodes cannot be assessed
N0	No regional lymph node metastasis
N1	Unilateral metastasis in cervical lymph nodes = 6 cm in greatest dimension, above the supraclavicular fossa, and/or unilateral or bilateral retropharyngeal lymph nodes = 6 cm in greatest dimension (midline nodes are considered ipsilateral nodes)
N2	Bilateral metastasis in cervical lymph nodes = 6 cm in greatest dimension, above the supraclavicular fossa (midline nodes are considered ipsilateral nodes)
N3	Metastasis in a lymph node > 6 cm and/or to the supraclavicular fossa (midline nodes are considered ipsilateral nodes)
N3a	> 6 cm in dimension
N3b	Extension to the supraclavicular fossa
<b>Distant metastasis (M)</b>	
M0	No distant metastasis
M1	Distant metastasis

**Histologic grade**

<b>Histologic grade (G)</b>	
GX	Grade cannot be assessed
G1	Well differentiated
G2	Moderately differentiated
G3	Poorly differentiated
G4	Undifferentiated

**Anatomic stage/prognostic groups**

<b>Stage</b>	<b>T</b>	<b>N</b>	<b>M</b>
0	Tis	N0	M0
I	T1	N0	M0
II	T1	N1	M0
	T2	N0	M0
	T2	N1	M0
III	T1	N2	M0
	T2	N2	M0
	T3	N0	M0
	T3	N1	M0
	T3	N2	M0
IVA	T4	N0	M0
	T4	N1	M0
	T4	N2	M0
IVB	T Any	N3	M0
IVC	T Any	N Any	M1

**Oropharynx and hypopharynx  
TNM classification**

<b>Primary tumor (T)</b>	
<i>Oropharynx:</i>	
TX	Primary tumor cannot be assessed
T0	No evidence of primary tumor
Tis	Carcinoma in situ
T1	Tumor = 2 cm in greatest dimension
T2	Tumor > 2 cm but not more than 4 cm in greatest dimension
T3	Tumor > 4 cm in greatest dimension or extension to lingual surface of the epiglottis
T4a	Moderately advanced local disease Tumor invades the larynx, deep/extrinsic muscle of the tongue, medial pterygoid, hard palate, or mandible
T4b	Very advanced local disease Tumor invades lateral pterygoid muscle, pterygoid plates, lateral nasopharynx, or skull base or encases the carotid artery
<i>Hypopharynx:</i>	
TX	Primary tumor cannot be assessed
T0	No evidence of primary tumor
Tis	Carcinoma in situ
T1	Tumor limited to 1 subsite of the hypopharynx and/or = 2 cm in greatest dimension
T2	Tumor invades more than 1 subsite of the hypopharynx or an adjacent site or measures > 2 cm but not more than 4 cm in greatest dimension without fixation of the hemilarynx
T3	Tumor > 4 cm in greatest dimension or with fixation of the hemilarynx or extension to the esophagus
T4a	Moderately advanced local disease Tumor invades thyroid/cricoid cartilage, hyoid bone, thyroid gland, or central compartment soft tissue (including prelaryngeal strap muscles and subcutaneous fat)
T4b	Very advanced local disease Tumor invades prevertebral fascia, encases carotid artery, or involves mediastinal structures
<b>Regional lymph nodes (N)</b>	
NX	Regional nodes cannot be assessed
N0	No regional lymph node metastasis
N1	Metastasis in a single ipsilateral lymph node = 3 cm in greatest dimension
N2	Metastasis in a single ipsilateral lymph node > 3 cm but not more than 6 cm in greatest dimension; or in multiple ipsilateral lymph nodes, none > 6 cm in greatest dimension; or in bilateral or contralateral lymph nodes, none > 6 cm in greatest dimension
N2a	Metastasis in a single ipsilateral lymph node > 3 cm but not more than 6 cm in greatest dimension



N2b	Metastasis in multiple ipsilateral lymph nodes, none > 6 cm in greatest dimension
N2c	Metastasis in bilateral or contralateral lymph nodes, none > 6 cm in greatest dimension
N3	Metastasis in a lymph node > 6 cm in greatest dimension
<b>Distant metastasis (M)</b>	
M0	No distant metastasis
M1	Distant metastasis

**Histologic grade**

<b>Histologic grade (G)</b>	
GX	Grade cannot be assessed
G1	Well differentiated
G2	Moderately differentiated
G3	Poorly differentiated
G4	Undifferentiated

**Anatomic stage/prognostic groups**

<b>Stage</b>	<b>T</b>	<b>N</b>	<b>M</b>
0	Tis	N0	M0
I	T1	N0	M0
II	T2	N0	M0
III	T3	N0	M0
	T1	N1	M0
	T2	N1	M0
	T3	N1	M0
IVA	T4a	N0	M0
	T4a	N1	M0
	T1	N2	M0
	T2	N2	M0
	T3 T4a	N2 N2	M0 M0
IVB	T Any	N3	M0
	T4b	N Any	M0
IVC	T Any	N Any	M1

**Nasal cavity and paranasal sinuses  
TNM classification**

<b>Primary tumor (T)</b>	
<i>Maxillary sinus:</i>	
TX	Primary tumor cannot be assessed
T0	No evidence of primary tumor
Tis	Carcinoma in situ
T1	Tumor limited to maxillary sinus mucosa with no erosion or destruction of bone
T2	Tumor causing bone erosion or destruction, including extension into the hard palate and/or middle nasal meatus, except extension to posterior wall of the maxillary sinus and pterygoid plates
T3	Tumor invades any of the following: bone of the posterior wall of the maxillary sinus, subcutaneous tissues, floor or medial wall of the orbit, pterygoid fossa, ethmoid sinuses
T4a	Moderately advanced local disease Tumor invades the anterior orbital contents, skin of the cheek, pterygoid plates, infratemporal fossa, cribriform plate, sphenoid or frontal sinuses
T4b	Very advanced local disease Tumor invades any of the following: orbital apex, dura, brain, middle cranial fossa, cranial nerves other than maxillary division of trigeminal nerve (V2), nasopharynx, or clivus
<i>Nasal cavity and ethmoid sinus:</i>	
TX	Primary tumor cannot be assessed
T0	No evidence of primary tumor
Tis	Carcinoma in situ
T1	Tumor restricted to any 1 subsite, with or without bony invasion
T2	Tumor invading 2 subsites in a single region or extending to involve an adjacent region within the nasoethmoidal complex, with or without bony invasion
T3	Tumor extends to invade the medial wall or floor of the orbit, maxillary sinus, palate, or cribriform plate
T4a	Moderately advanced local disease Tumor invades any of the following: anterior orbital contents, skin of the nose or cheek, minimal extension to the anterior cranial fossa, pterygoid plates, sphenoid or frontal sinuses
T4b	Very advanced local disease Tumor invades any of the following: orbital apex, dura, brain, middle cranial fossa, cranial nerves other than maxillary division of trigeminal nerve (V2), nasopharynx, or clivus
<b>Regional lymph nodes (N)</b>	
NX	Regional nodes cannot be assessed
N0	No regional lymph node metastasis
N1	Metastasis in a single ipsilateral lymph node = 3 cm in greatest dimension

N2	Metastasis in a single ipsilateral lymph node > 3 cm but not more than 6 cm in greatest dimension; or in multiple ipsilateral lymph nodes, none > 6 cm in greatest dimension; or in bilateral or contralateral lymph nodes, none > 6 cm in greatest dimension
N2a	Metastasis in a single ipsilateral lymph node > 3 cm but not more than 6 cm in greatest dimension
N2b	Metastasis in multiple ipsilateral lymph nodes, none > 6 cm in greatest dimension
N2c	Metastasis in bilateral or contralateral lymph nodes, none > 6 cm in greatest dimension
N3	Metastasis in a lymph node > 6 cm in greatest dimension
<b>Distant metastasis (M)</b>	
M0	No distant metastasis
M1	Distant metastasis

**Histologic grade**

<b>Histologic grade (G)</b>	
GX	Grade cannot be assessed
G1	Well differentiated
G2	Moderately differentiated
G3	Poorly differentiated
G4	Undifferentiated

**Anatomic stage/prognostic groups**

<b>Stage</b>	<b>T</b>	<b>N</b>	<b>M</b>
0	Tis	N0	M0
I	T1	N0	M0
II	T2	N0	M0
III	T3	N0	M0
	T1	N1	M0
	T2	N1	M0
	T3	N1	M0
IVA	T4a	N0	M0
	T4a	N1	M0
	T1	N2	M0
	T2	N2	M0
	T3	N2	M0
	T4a	N2	M0
IVB	T Any	N3	M0
	T4b	N Any	M0
IVC	T Any	N Any	M1

**Major salivary glands  
TNM classification**

<b>Primary tumor (T)</b>	
TX	Primary tumor cannot be assessed
T0	No evidence of primary tumor
Tis	Carcinoma in situ
T1	Tumor = 2 cm in greatest dimension without extraparenchymal extension (clinical or macroscopic evidence of invasion of the soft tissues, not microscopic evidence)
T2	Tumor > 2 cm but not more than 4 cm in greatest dimension without extraparenchymal extension
T3	Tumor > 4 cm and/or tumor having extraparenchymal extension
T4a	Moderately advanced disease Tumor invades the skin, mandible, ear canal, and/or facial nerve
T4b	Very advanced disease Tumor invades skull base and/or pterygoid plates and/or encases carotid artery
<b>Regional lymph nodes (N)</b>	
NX	Regional nodes cannot be assessed
N0	No regional lymph node metastasis
N1	Metastasis in a single ipsilateral lymph node = 3 cm in greatest dimension
N2	Metastasis in a single ipsilateral lymph node > 3 cm but not more than 6 cm in greatest dimension; or in multiple ipsilateral lymph nodes, none > 6 cm in greatest dimension; or in bilateral or contralateral lymph nodes, none > 6 cm in greatest dimension
N2a	Metastasis in a single ipsilateral lymph node > 3 cm but not more than 6 cm in greatest dimension
N2b	Metastasis in multiple ipsilateral lymph nodes, none > 6 cm in greatest dimension
N2c	Metastasis in bilateral or contralateral lymph nodes, none > 6 cm in greatest dimension
N3	Metastasis in a lymph node > 6 cm in greatest dimension
<b>Distant metastasis (M)</b>	
M0	No distant metastasis
M1	Distant metastasis

**Anatomic stage/prognostic groups**

<b>Stage</b>	<b>T</b>	<b>N</b>	<b>M</b>
0	Tis	N0	M0
I	T1	N0	M0
II	T2	N0	M0
III	T3	N0	M0
	T1	N1	M0
	T2	N1	M0
	T3	N1	M0
IVA	T4a	N0	M0
	T4a	N1	M0
	T1	N2	M0
	T2	N2	M0
	T3	N2	M0
	T4a	N2	M0
IVB	T Any	N3	M0
	T4b	N Any	M0
IVC	T Any	N Any	M1



**Mucosal melanoma  
TNM classification**

<b>Primary tumor (T)</b>	
TX	Primary tumor cannot be assessed
T3	Mucosal disease
T4a	Moderately advanced disease Tumor involving deep soft tissue, cartilage, bone, or overlying skin
T4b	Very advanced disease Tumor involving brain, dura, skull base, lower cranial nerves (IX, X, XI, XII), masticator space, carotid artery, prevertebral space, or mediastinal structures
<b>Regional lymph nodes (N)</b>	
NX	Regional lymph nodes cannot be assessed
N0	No regional lymph node metastases
N1	Regional lymph node metastases present
<b>Distant metastasis (M)</b>	
M0	No distant metastasis
M1	Distant metastasis

**Anatomic stage/prognostic groups**

<b>Stage</b>	<b>T</b>	<b>N</b>	<b>M</b>
III	T3	N0	M0
IVA	T4a	N0	M0
	T3	N1	M0
	T4a	N1	M0
IVB	T4b	N Any	M0
IVC	T Any	N Any	M1

**Thyroid gland  
TNM classification**

<b>Primary tumor (T)</b>	
TX	Primary tumor cannot be assessed
T0	No evidence of primary tumor is found
T1	Tumor size $\leq 2$ cm in greatest dimension and is limited to the thyroid
T1a	Tumor $\leq 1$ cm, limited to the thyroid
T1b	Tumor $> 1$ cm but $\leq 2$ cm in greatest dimension, limited to the thyroid
T2	Tumor size $> 2$ cm but $\leq 4$ cm, limited to the thyroid.
T3	Tumor size $>4$ cm, limited to the thyroid or any tumor with minimal extrathyroidal extension (eg, extension to sternothyroid muscle or perithyroid soft tissues)
T4a	Moderately advanced disease; tumor of any size extending beyond the thyroid capsule to invade subcutaneous soft tissues, larynx, trachea, esophagus, or recurrent laryngeal nerve
T4b	Very advanced disease; tumor invades prevertebral fascia or encases carotid artery or mediastinal vessel
<i>All anaplastic carcinomas are considered stage IV:</i>	
T4a	Intrathyroidal anaplastic carcinoma
T4b	Anaplastic carcinoma with gross extrathyroid extension
<b>Regional lymph nodes (N)</b>	
<i>Regional lymph nodes are the central compartment, lateral cervical, and upper mediastinal lymph nodes:</i>	
NX	Regional nodes cannot be assessed
N0	No regional lymph node metastasis
N1	Regional lymph node metastasis
N1a	Metastases to level VI (pretracheal, paratracheal, and prelaryngeal/Delphian lymph nodes)
N1b	Metastases to unilateral, bilateral, or contralateral cervical (levels I, II, III, IV, or V) or retropharyngeal or superior mediastinal lymph nodes (level VII)
<b>Distant metastasis (M)</b>	
M0	No distant metastasis is found
M1	Distant metastasis is present

### Stage grouping

Separate stage groupings are recommended for differentiated, medullary, and anaplastic carcinoma			
<i>Papillary and follicular thyroid cancer (age &lt; 45y):</i>			
Stage	T	N	M
I	Any T	Any N	M0
II	Any T	Any N	M1
<i>Papillary and follicular; differentiated (age ≥ 45y):</i>			
Stage	T	N	M
I	T1	N0	M0
II	T2	N0	M0
III	T3	N0	M0
IVA	T1-3	N1a	M0
	T4a	N1b	M0
IVB	T4b	Any N	M0
IVC	Any T	Any N	M1
<i>Anaplastic carcinoma (all anaplastic carcinomas are considered stage IV):</i>			
Stage	T	N	M
IVA	T4a	Any N	M0
IVB	T4b	Any N	M0
IVC	Any T	Any N	M1
<i>Medullary carcinoma (all age groups):</i>			
Stage	T	N	M
I	T1	N0	M0
II	T2, T3	N0	M0
III	T1-T3	N1a	M0
IVA	T4a	N0	M0
	T4a	N1a	M0
	T1	N1b	M0
	T2	N1b	M0
	T3	N1b	M0
	T4a	N1b	M0
	T4a	N0, N1b	M0
	T1-T4a	N1b	M0
IVB	T4b	Any N	M0
IVC	Any T	Any N	M1

Miroslav Tedla  
Gabriela Pavlovčinová  
Sabyasachi Chakrabarti

# Basic OTO rhino laryngology

Vydala Univerzita Komenského v Bratislave vo Vydavateľstve UK  
Technická redaktorka: Andrea Jahnátková  
Korigovali autori

Rozsah 262 strán, 26,34 AH, 26,87 VH, náklad 200, prvé vydanie  
Vytlačilo Polygrafické stredisko UK v Bratislave

ISBN 978-80-223-3963-6

