

IFOS
Dubai
29/03/2019

Vertigo in the emergency department

**P Bertholon,
ENT / Neuro department
Saint Etienne, France**



Introduction

- **Vertigo/dizziness is a common complaint that accounts for 3,3 to 3,6 % of emergency department visits.**

Newman-Toker DE et al.

Spectrum of dizziness visits to US Emergency Departments : cross-sectional analysis from a nationally representative sample
Mayo Clin Proc 2008 July; 83(7):765-775

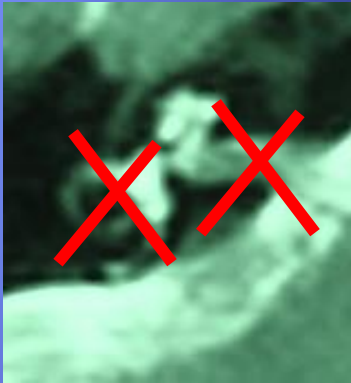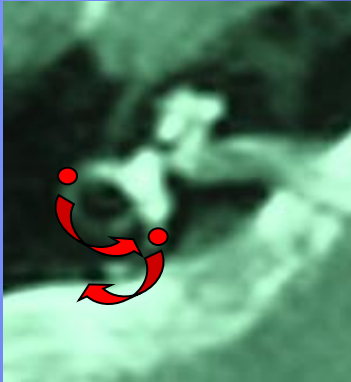
Cheung CS et al.

Predictors of important neurological causes of dizziness among patients presenting to the emergency department.
Emerg Med 2010 July,27(7):517-521

- **Diagnosis of a patient suffering from vertigo is challenging as it may be due to various disorders in the fields of Otolaryngology, Neurology, Psychiatry and Internal Medicine...**
- **However, in emergency, it is easier to make an accurate diagnosis as vertigo should be associated with objective signs, in particular oculomotor abnormalities.**

➤ It is essential to remind that **vertigo due to a peripheral (ENT) disorder has mainly 2 different presentations :**

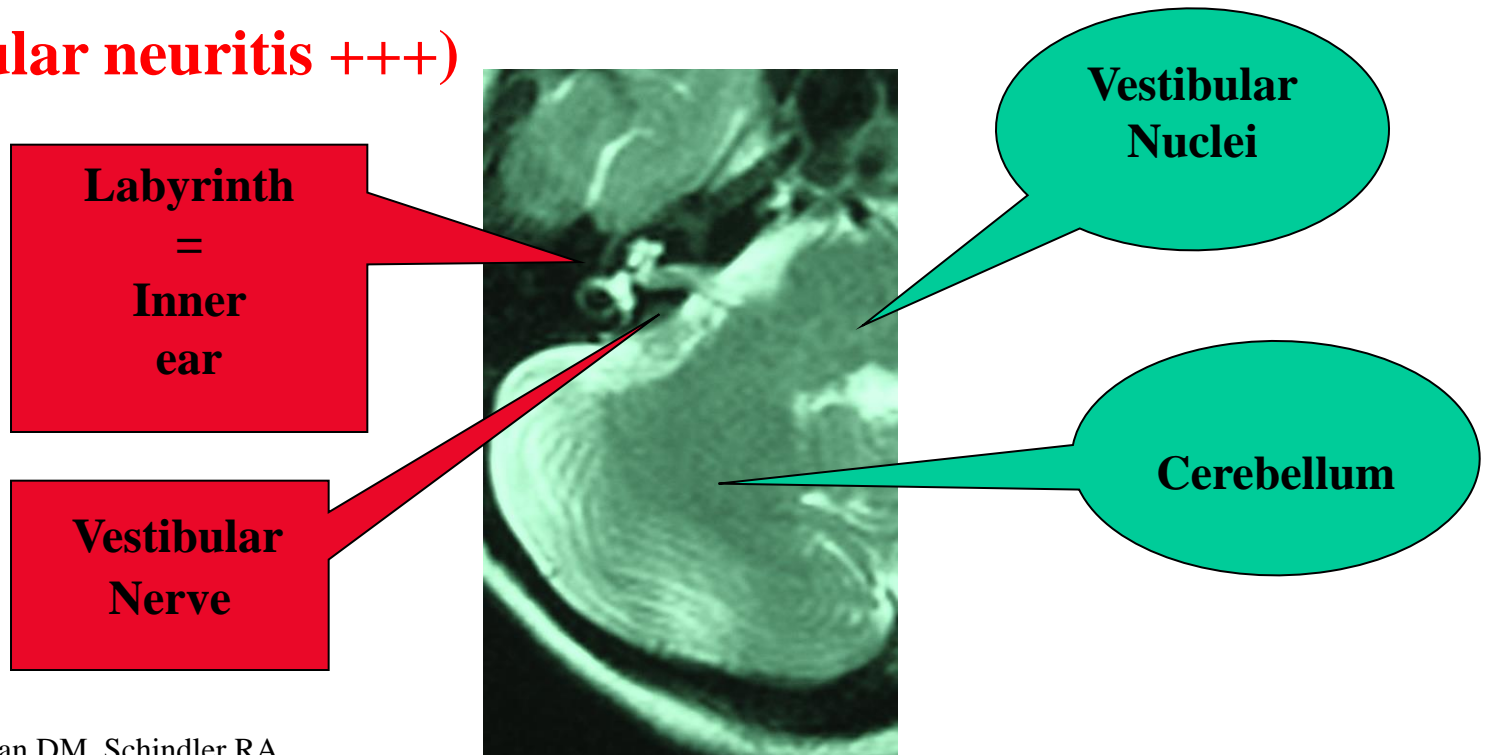
- either a **dysfunction of a canal** as observed in BPPV : the patient complain of **brief (less than 1 minute) positional vertigo** and positional manoeuvres should trigger a typical positional nystagmus (according to the canal involved)
- or a **dysfunction of the inner ear and/or vestibular nerve**, with a spontaneous **vertigo during a least 20 minutes** as can be observed in a crisis of Meniere's disease, labyrinthitis, vestibular neuritis... Then, the patient should have a typical peripheral vestibular deficit with a spontaneous horizontal-torsional nystagmus and a contralateral body deviation.



- However, one of the most difficult diagnostic challenge is to differentiate a benign vestibular neuritis from a dangerous stroke in the posterior fossa that can present with isolated vertigo.

Peripheral vestibular disease

(vestibular neuritis +++)



Rubenstein RL, Norman DM, Schindler RA, Kaseff L. Cerebellar infarction : a presentation of vertigo.
Laryngoscope 1980;90;505-514.

Huang CY, Yu YL. Small cerebellar strokes may mimic labyrinthine lesions.
J Neurol Neurosurg Psych 1985; 48:263-265.

Central vestibular or cerebellar disease
(cerebellar stroke +++)

The diagnosis relies on **history taking** (symptoms)

There is accumulating evidence that trying to clarify the type of vestibular symptoms (dizziness / vertigo / unsteadiness /lightheadedness...) is of limited clinical utility.

On the contrary, it is useful to focalize on :

TIming (onset, duration, evolution) and

TRiggers (action, movements or situations that provoke the onset of dizziness in patient with intermittent symptoms)

For example : - Vestibular symptoms only on arising is an argument for orthostatic hypotension, whereas symptoms both on arising and on lying back or when rolling in bed is typically observed in BPPV.

- Head trauma induces BPPV, labyrinthine concussion and/or fracture.

(TITRATE is the acronym for TIming, TRiggers And Targeted Exams)

Newman-Toker DE, Edlow JA.

TiTrATE: A Novel Approach to Diagnosing Acute Dizziness and Vertigo

Neurol Clin. 2015 August ; 33(3): 577–599.

A few simple questions should be systematically asked in order to search for a neurological disorder (clumsiness, paresthesia, dysarthria...)

SYMPTOMS

Isolated Vertigo

Vertigo with hearing loss
Fullness, tinnitus

Vertigo with neurological symptoms :
double vision,
paresthesia
clumsiness (hand)
dysarthria
dysphagia, dysphonia

Brief (< 1 mn)
and Positional
(bed +++)

Spontaneous
Vertigo

Spontaneous
Vertigo

Post traumatic
Vertigo

Unique
episode
(days)

Recurrent
episodes

Unique
episode
(days)

Recurrent
Episodes
(> 20 mn)

Usually
PERIPHERAL
(BPPV)

Usually
PERIPHERAL
(vestibular
neuritis ?)

Vestibular
Migraine ?

Usually
PERIPHERAL
(labyrinthitis ?
(Vestibular schwannoma ?)

Usually
PERIPHERAL
(Meniere ?)

Usually
PERIPHERAL
(labyrinthine
concussion
and/or fracture)

CENTRAL
(stroke...)

The diagnosis relies on **bedside examination** (signs)

At least 2 recent series show the importance and sensitivity of clinical examination compare to imaging tests in acute vertigo patients :

- **Series from a Neurological Department using a 3-step bedside oculomotor examination**

No device

Kattah JC et al. HINTS to diagnose stroke in the Acute Vestibular syndrome. Three-step bedside oculomotor examination more sensitive than early MRI diffusion-weighted Imaging.

Stroke 2009;40:3504-3510

- **Series from an ENT Department using a 4-step bedside examination including oculomotor and body examination**

Frenzel glasses are needed

Vanni S et al. STANDING, a four-step bedside algorithm for differential diagnosis of acute vertigo in the emergency department

Acta Otorhinolaryngologica italica 2014;34:419-426

Kattah JC et al. HINTS to diagnose stroke in the Acute Vestibular syndrome. Three-step bedside oculomotor examination more sensitive than early MRI diffusion-weighted Imaging. Stroke 2009;40:3504-3510.

Prospective study of 101 consecutive patients with an acute vestibular syndrome and at least 1 stroke risk factor underwent :

A 3-step bedside examination including :

- Observation of Nystagmus in different positions of gaze.**
- prism cross-cover test of ocular alignment (search for a skew deviation)**
- horizontal head impulse test (Halmagyi test)**

Bedside examination was compared to Neuroimaging (MRI or CT)

Among the 101 consecutive patients :

- 25 patients had a peripheral lesion**
- 76 had a central lesion (69 ischemic strokes)**

The presence of normal horizontal head impulse test, direction changing nystagmus in eccentric gaze, or skew deviation was 100% sensitive and 96% specific for stroke.

Initial MRI diffusion-weighted imaging was falsely negative in 12 % (all < 48 hours after symptoms onset)

A 3-step bedside oculomotor examination appears more sensitive for stroke than early MRI in Acute vestibular syndrome.

Vanni S et al. **STANDING**, a four-step bedside algorithm for differential diagnosis of acute vertigo in the emergency department

Acta Otorhinolaryngologica italica 2014;34:419-426

Prospective study of 292 consecutive patients with an acute vestibular syndrome randomized in a **STANDING** group and a **CONTROL** group

A **4-step bedside** examination including :

- Observation of **Spontaneous nystagmus** (Frenzel glasses)
- Observation of **Positional nystagmus** (supine roll test, Dix Hallpike)
- **horizontal head impulse test** (Halmagyi test)
- Analysis of **body stability** (the inability to stand alone with eyes opened is considered a central sign)

The **STANDING** algorithm shows good reliability and very high accuracy in excluding dangerous disease in the hands of emergency physicians.

Based on the 2 previous studies we regularly use a simple algorithm using a set of **5 basic bedside test :**

- 1. Analysis of eyes movements in different position of gaze as well as ocular pursuit**
- 2. Analysis of nystagmus under videonystagmoscopy (portable device).**
- 3. Head Impulse Test / Halmagyi test**
- 4. Positional manoeuvres**
- 5. Analysis of postural stability by Romberg and/or Fukuda testing.**

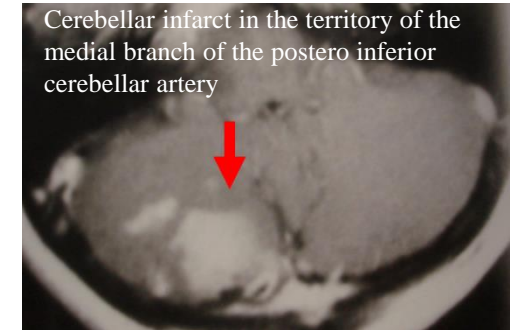
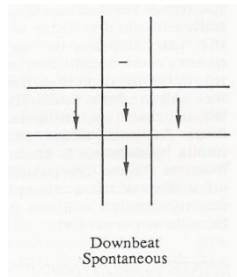
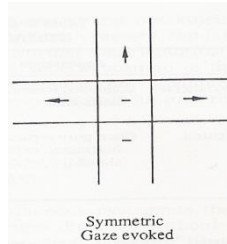
SIGNS

Nystagmus (fixation)

Spontaneous Nystagmus is absent

Spontaneous Nystagmus is present

**Nystagmus is obviously Central
(Gaze evoked Nystagmus,
Nystagmus is purely vertical
or purely torsional)**



CENTRAL

Nystagmus (fixation, VNS)

Spontaneous Nystagmus is absent

Spontaneous Nystagmus is present

**Nystagmus is possibly
Peripheral
= horizontal-torsional**

Head impulse test

Saccade -

Saccade +

**Standing
Position -**

**Standing
Position +**

CENTRAL

PERIPHERAL

Nystagmus (fixation, VNS)

Spontaneous Nystagmus is absent

Spontaneous Nystagmus is present

Positional Manœuvres

Supine roll test

**Dix
Hallpike**

**Horizontal
Nystagmus**

**Rotatory
Upbeating
Nystagmus**

Hor BPPV

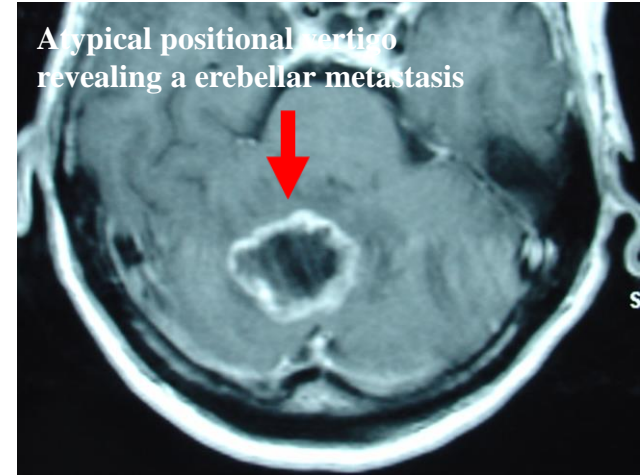
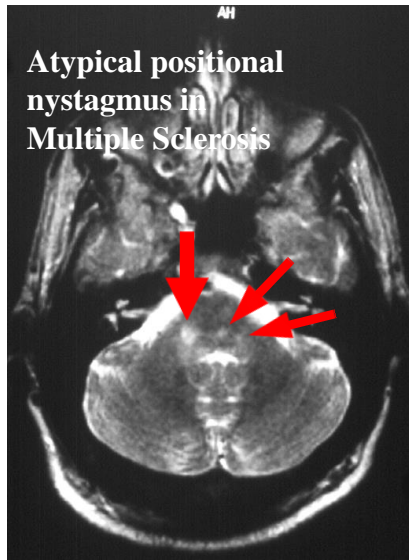
Post BPPV

Nystagmus (fixation, VNS)

Spontaneous Nystagmus is absent

Spontaneous Nystagmus is present

Positional Manœuvres



Nystagmus is absent or atypical

Standing Position - or other neurological Signs +

CENTRAL

Summary of a simple algorithm

Spontaneous Nystagmus is absent

Spontaneous Nystagmus is present

Positional Manœuvres

Supine roll test

Dix
Hallpike

Horizontal
Nystagmus

Rotatory
Upbeating
Nystagmus

Nystagmus
is absent
or atypical

Nystagmus is
obviously Central
(Gaze evoked Nystagmus,
Nystagmus is purely vertical
or purely torsional)

Nystagmus is possibly
Peripheral
= horizontal-torsional

Head impulse test

Saccade -

Saccade +

Standing Position -
or other neurological
Signs +

Standing
Position -

Standing
Position +

Hor BPPV

Post BPPV

CENTRAL

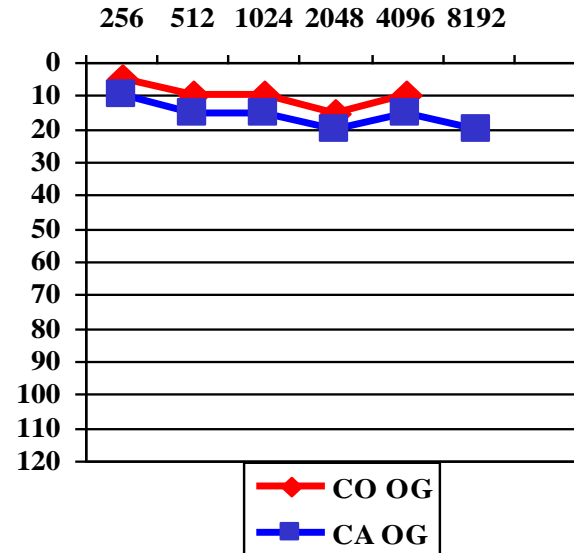
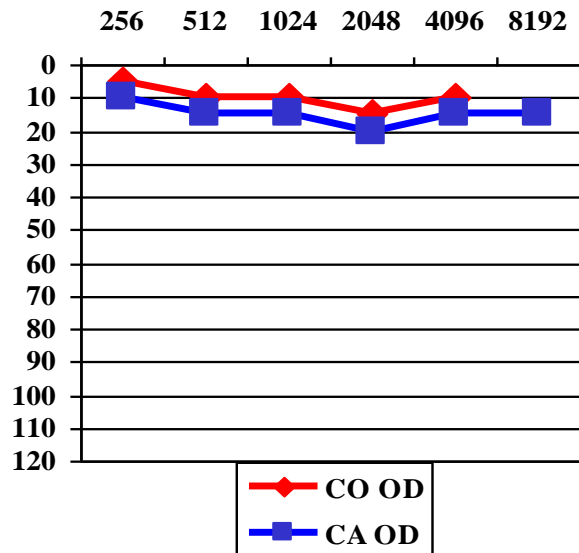
PERIPHERAL

➤ This set of **5 basic bedside tests** is usually able to differentiate a peripheral vestibular disorder from a central lesion and often to approach the underlying etiology.

➤ This set of **5 basic bedside tests can be completed by many others clinical tests** (cover test, head shaking, vibratory test, fistula test...search for cerebellar dysmetria...).

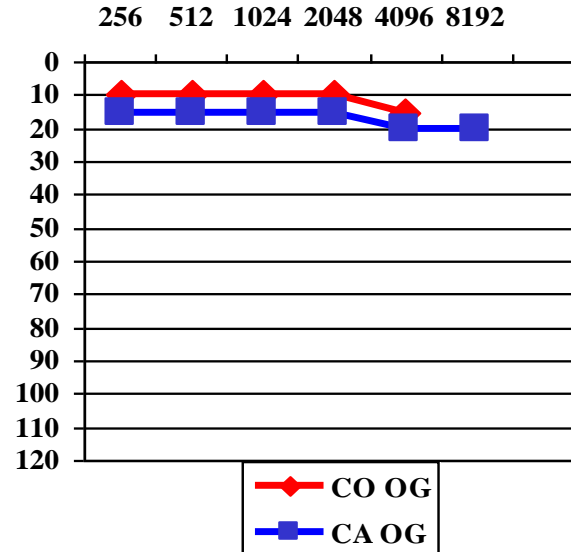
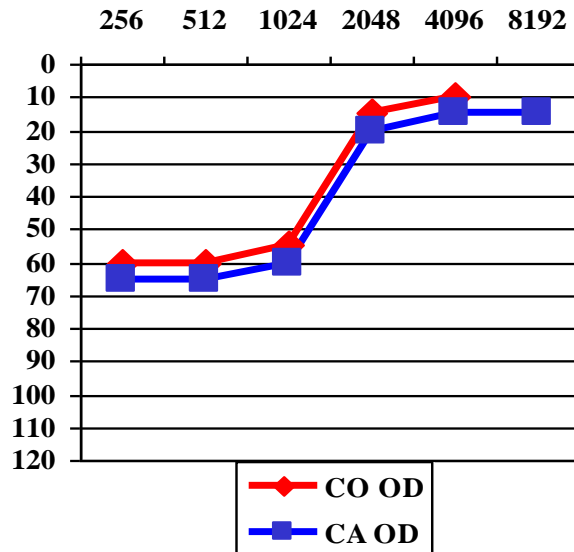
➤ This **clinical evaluation should be completed by audiological testing** (which can be performed with a portable device) as **audiological testing often immediately orientates the diagnosis.**

Normal pure tone Audiometry



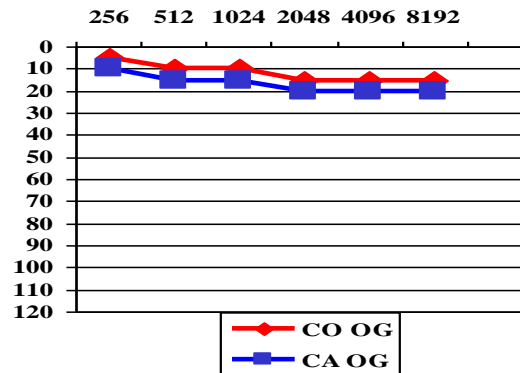
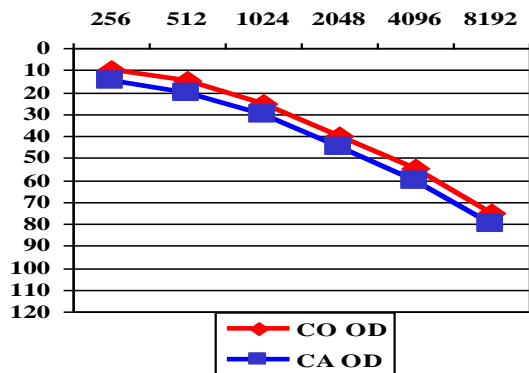
Normal Audiometry is compatible with BPPV, vestibular neuritis, vestibular migraine, cerebellar stroke (in the territory of the postero-inferior cerebellar artery), Wallenberg syndrome...

Audiometry showing a sensorineural hearing loss on the low-middle frequencies

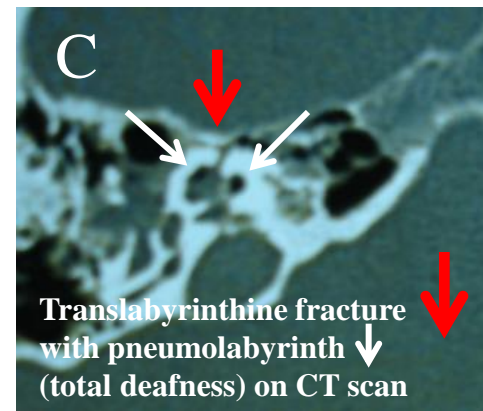
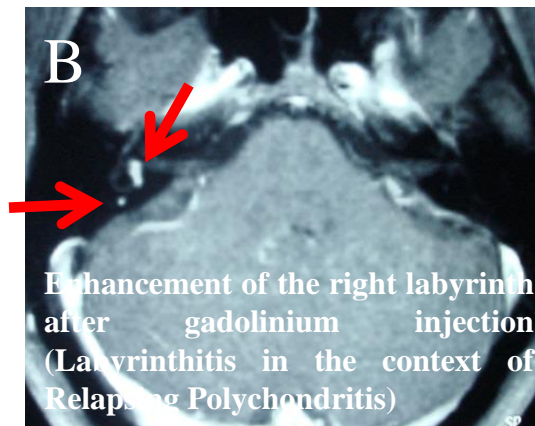
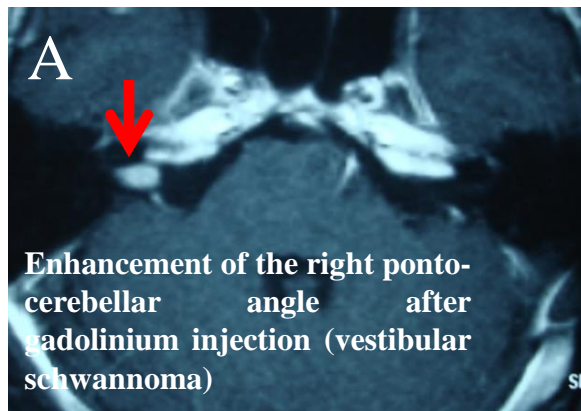


This audiometry is typical of a Meniere's disease (right Meniere's disease at an early stage)

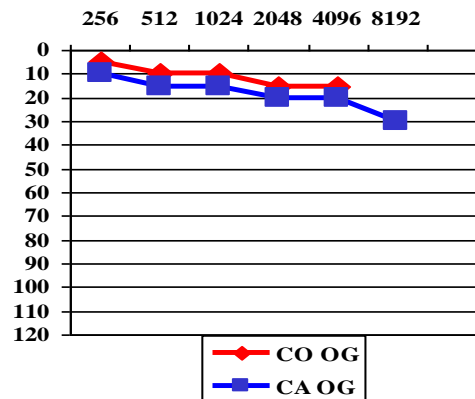
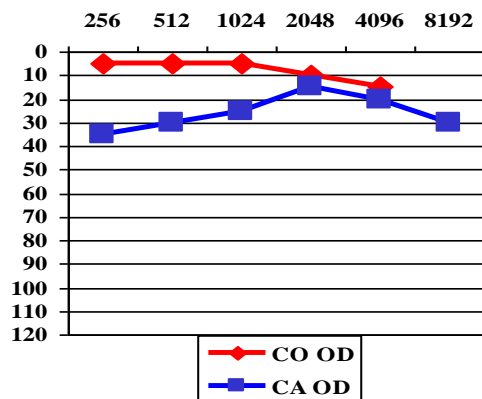
Audiometry showing a sensorineural hearing loss on the middle-high frequencies or total deafness



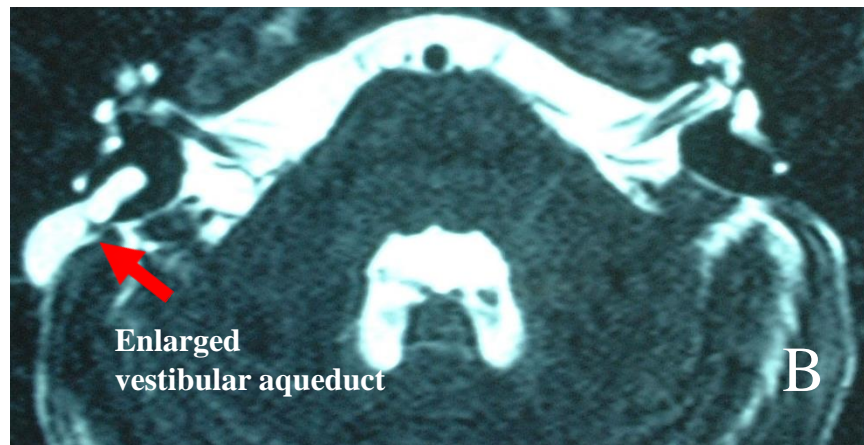
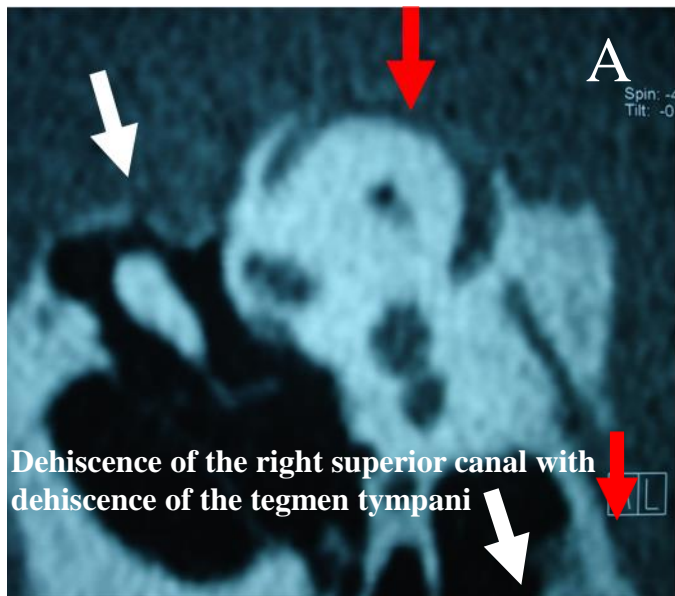
This audiometry is compatible with a vestibular schwannoma (A) (including an intralabyrinthine form), labyrinthitis (B), temporal bone fracture (C), intralabyrinthine haemorrhage (total deafness), cerebellar stroke (rare) in the territory of the antero-inferior cerebellar artery (which also supply the inner ear)



Audiometry showing a mixed hearing loss



This audiometry in the context of vertigo is an argument for a third window mechanism as can be observed in dehiscence of the superior canal (A), enlarged vestibular aqueduct (B)...



CONCLUSION

Based on **history taking** and a set of **basic bedside tests** (together with pure tone audiometry), clinician should be able to decide :

- whether the patient is possibly suffering from a stroke
- whether the patient is affected by a non-threatening disorder for which treatment can be started (Benign paroxysmal positional vertigo, vestibular neuritis, Meniere's disease, vestibular migraine...)
- whether the diagnosis is still unclear and additional oto-neurological examination is required to guide for other appropriate audiovestibular (electrophysiological), imaging (brain MRI and/or inner CT) and/or laboratory testing.