



# Sinus & Skull Base Surgery

Sheng-Po Hao MD, FACS, FICS

Taiwan

**Anatomy**

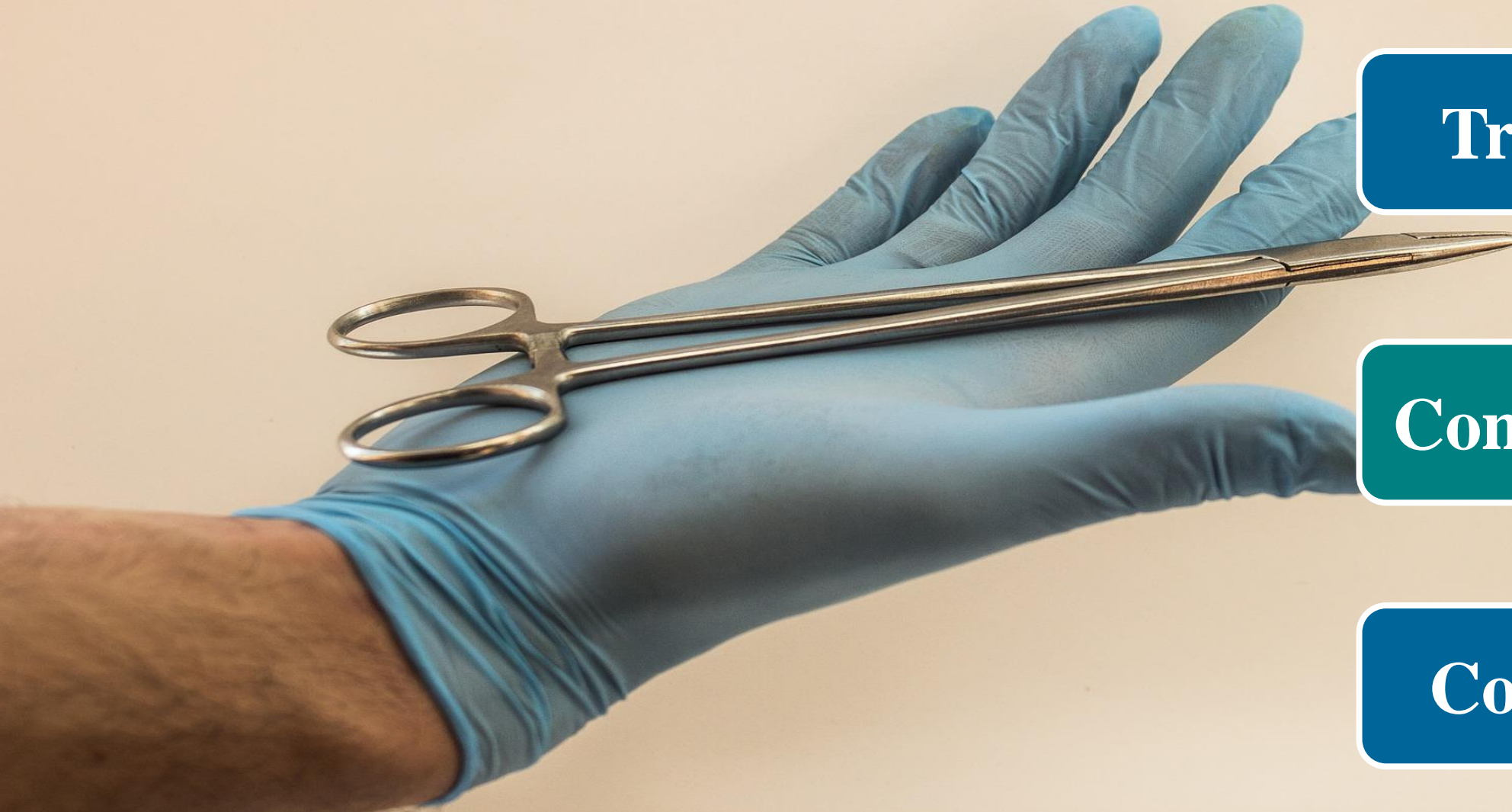**Clinical case**

**Diagnosis**

**Treatment**

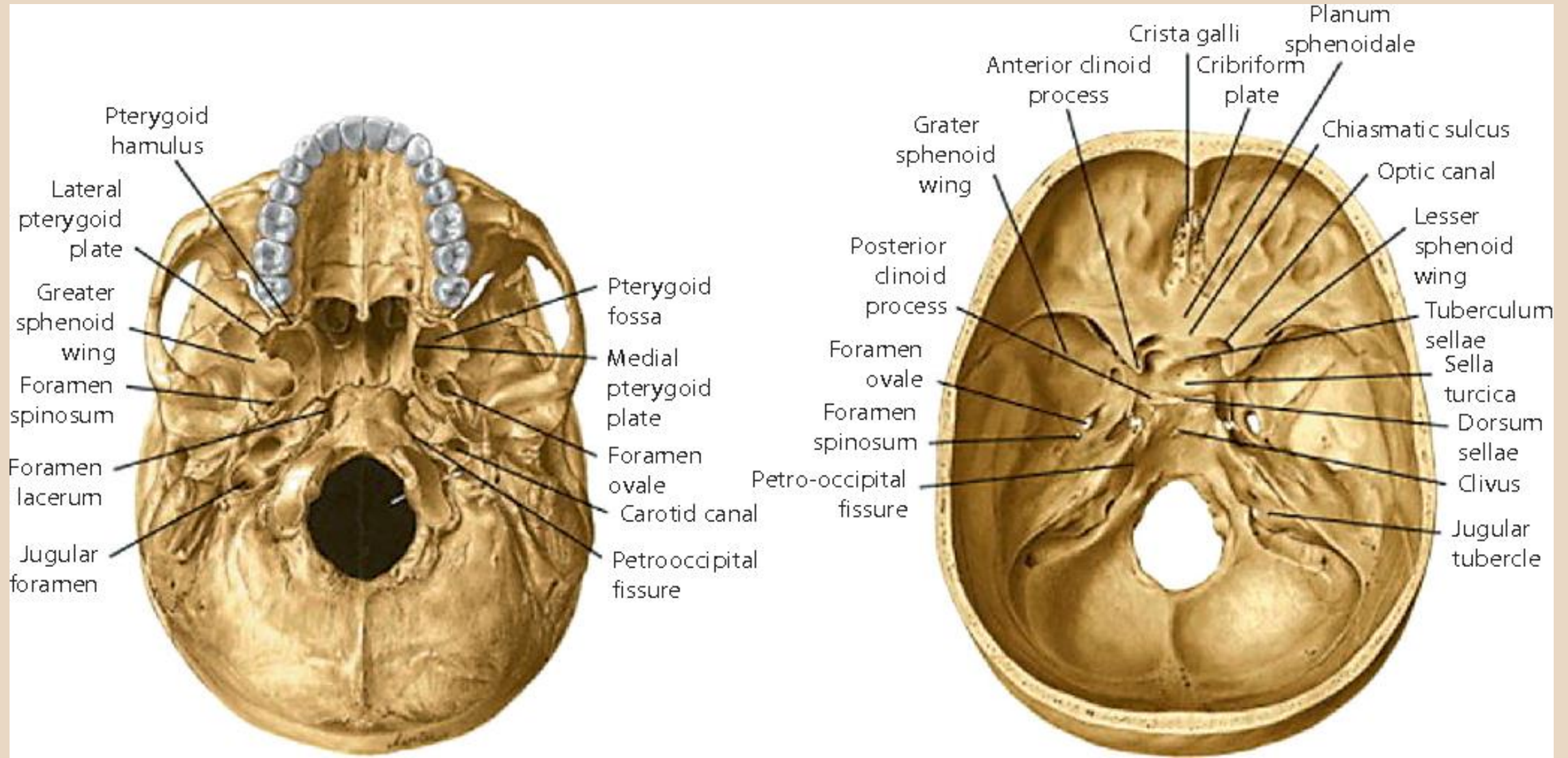
**Complication**

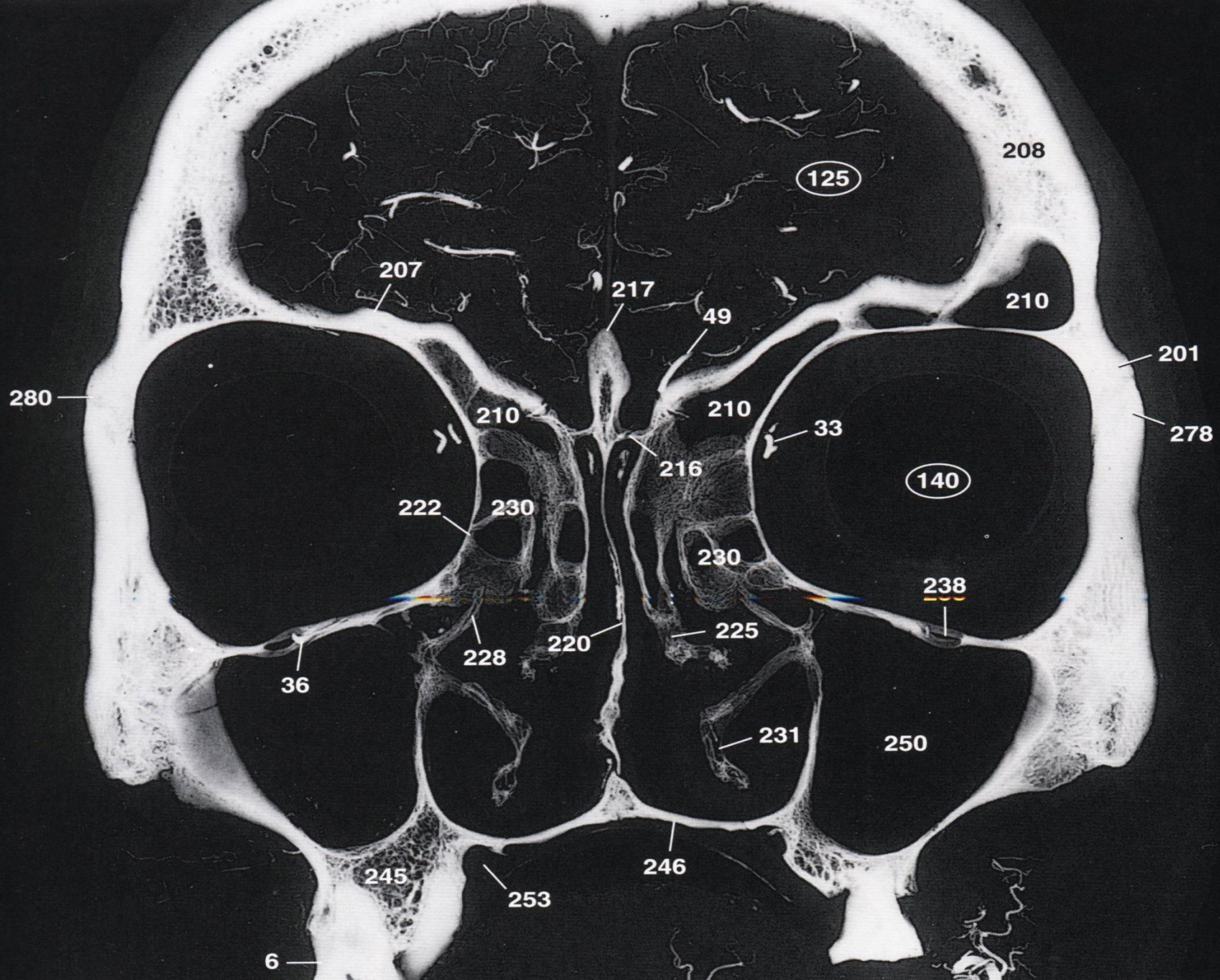
**Conclusion**



**Anatomy**

# Anatomy





# **Clinical Case**

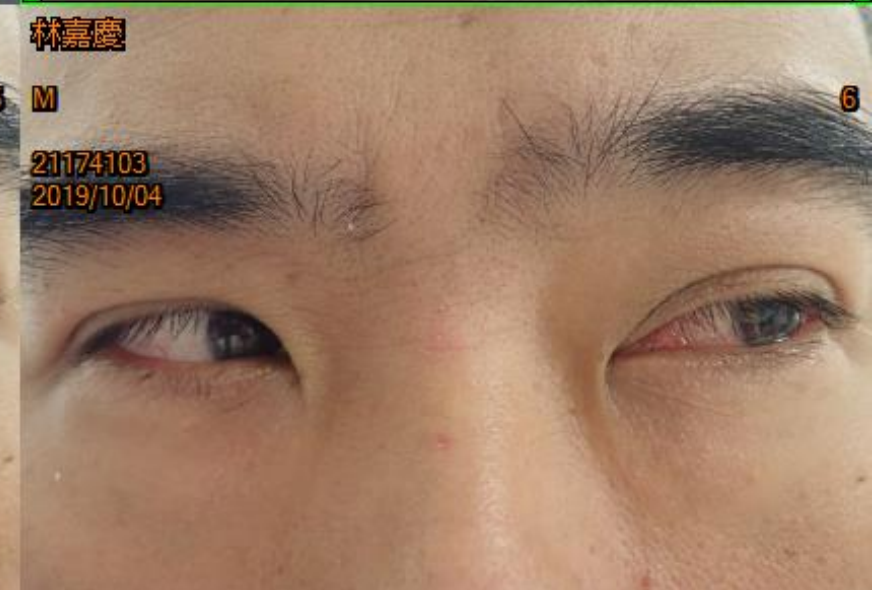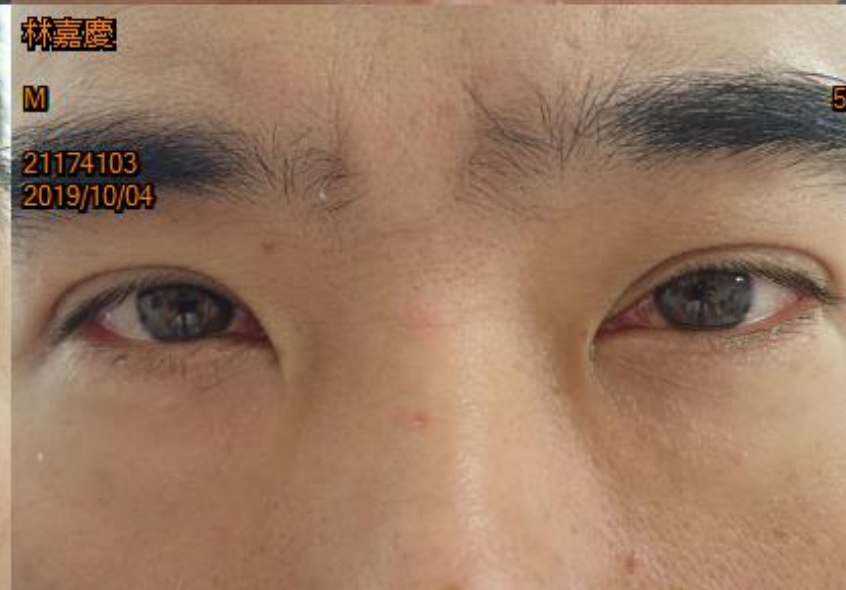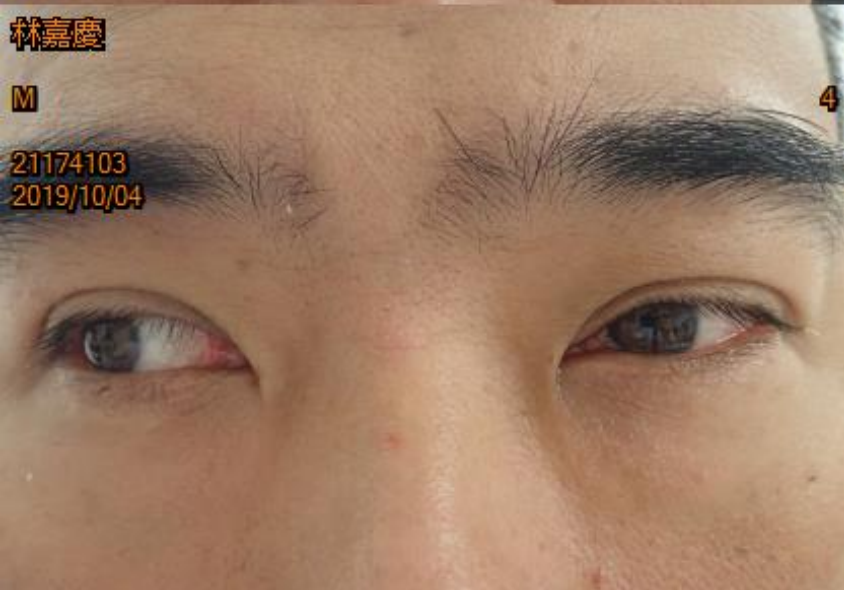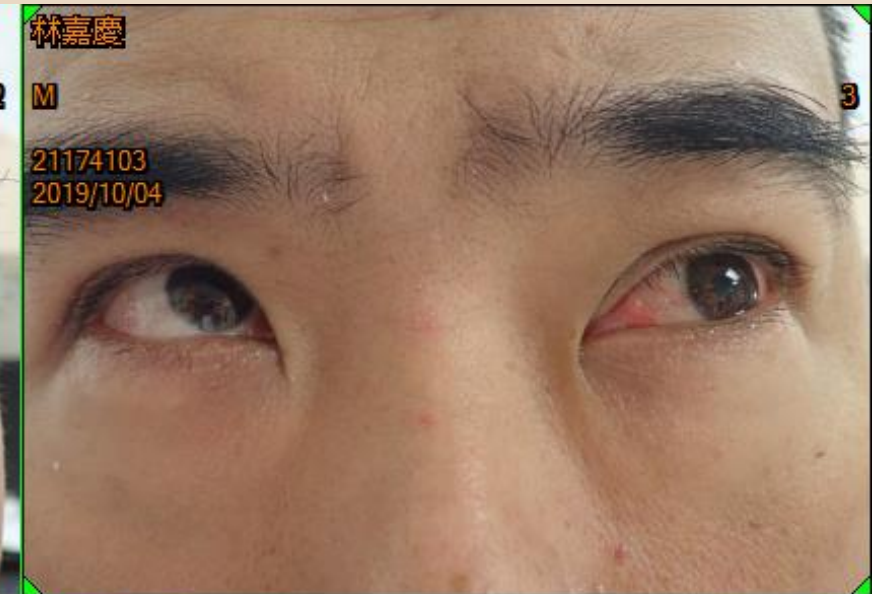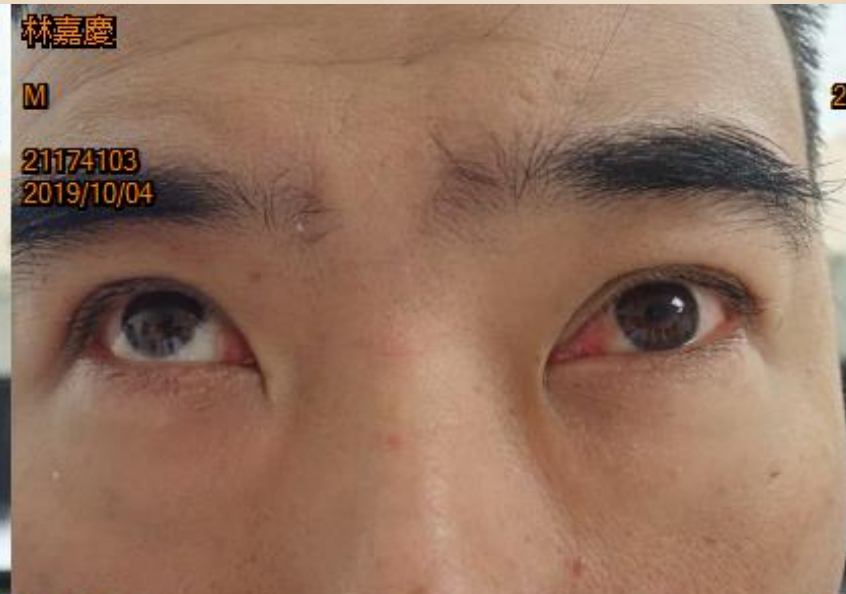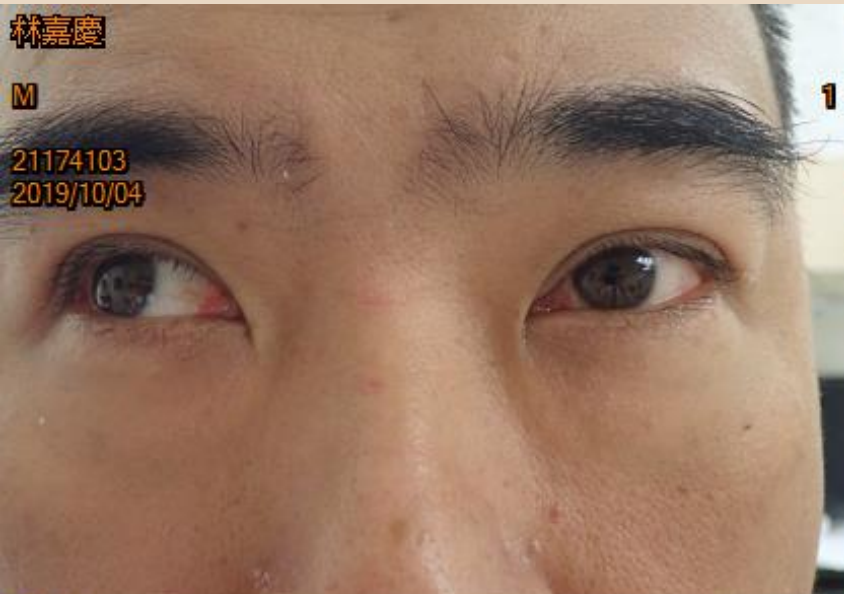# Craniofacial Resection

2019.09

36 Y/O male

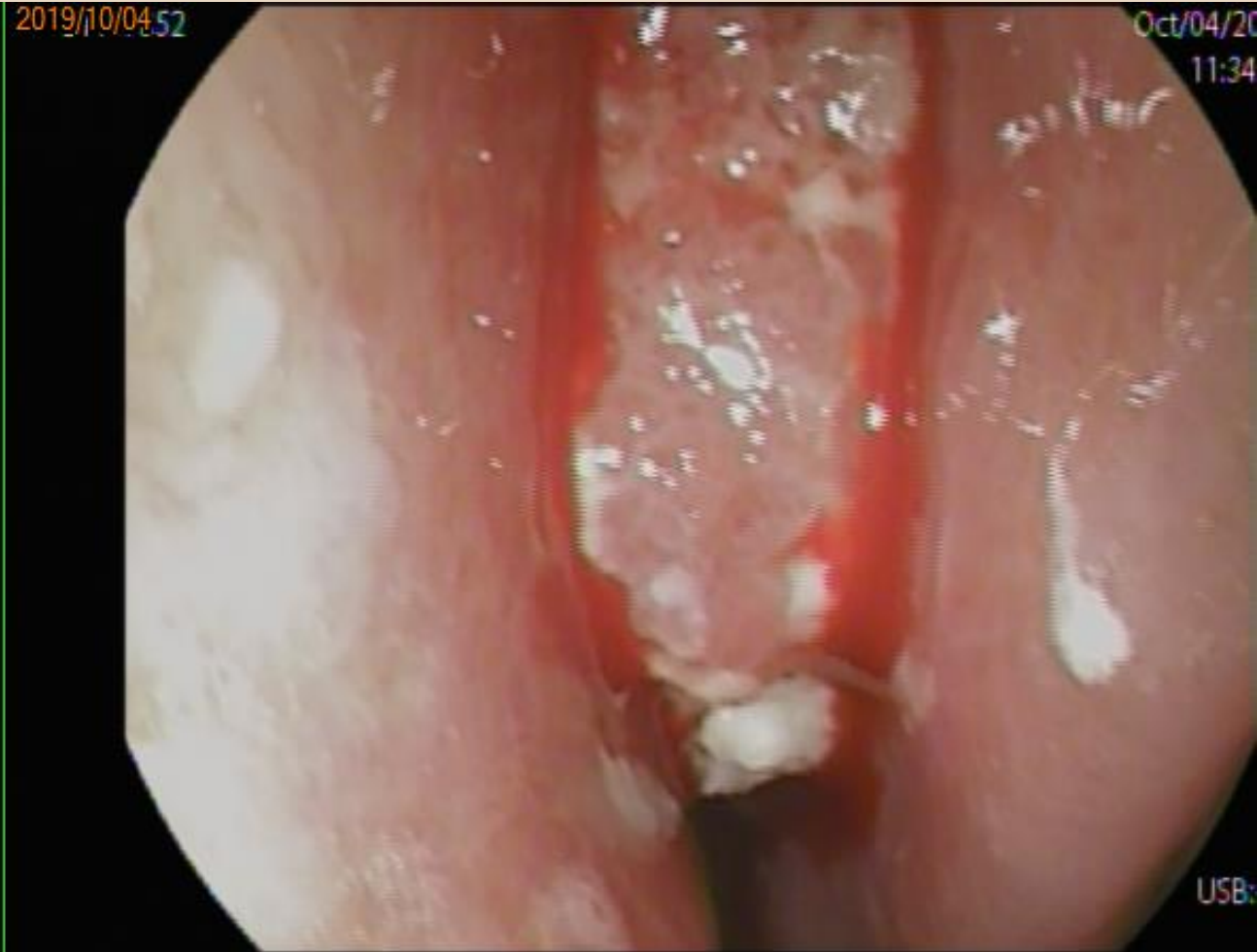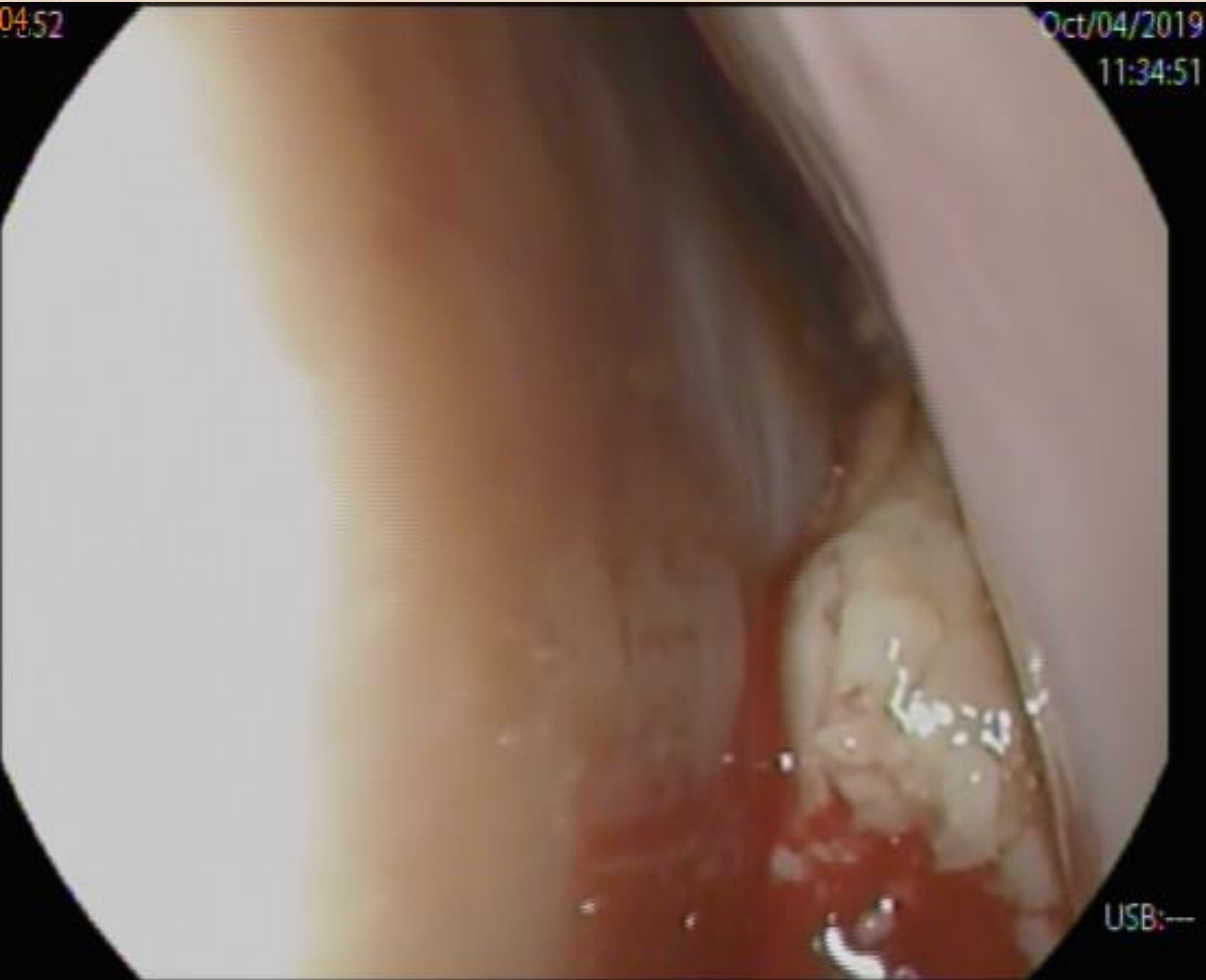Presented with

- Diplopia
- Headache
- Epistaxis intermittently
- Hyposmia





# Sinoscopy



# Clinical Case of Craniofacial Resection

2019.10

- First biopsy in OPD

- **Pathology: sinonasal papilloma**

Section shows polypoid tissue fragments with mature collagenous fibers covered by hyperkeratotic and hyperplastic stratified squamous epithelium. The surface is ulcerated. No obvious evidence of stromal invasion is found.

- Arrange image study

# Inverted papilloma

- Commonest nasal tumor
- **Malignant transformation: 10-30 %**  
occurs in a variety of histologies
- CT features
  - CT features are mostly nonspecific, demonstrating a soft tissue density mass with some enhancement.
  - As the mass enlarges, bony resorption and destruction may be present, with a similar pattern to that seen in patients with squamous cell carcinoma.
  - The presence of a focal, often cone-shaped, hyperostosis has been reported to correlate with the point of origin of the lesions.

# Inverted Papilloma

- MRI

MRI often demonstrates a distinctive appearance, referred to as convoluted cerebriform pattern, seen on both T2 and contrast-enhanced T1 weighted images.

- Signal characteristics

**T1:** isointense to muscle

**T2:** generally hyperintense to muscle

**T1 C+ (Gd):** heterogeneous enhancement

# Differential Diagnosis

- Sinonasal carcinoma:
  - unfortunately imaging is unable to confidently distinguish between inverted papillomas, inverted papilloma with malignancy and pure malignancy
- Antrochoanal polyp
  - non-enhancing, peripheral mucosal enhancement may be present
- Inflammatory polyp:
  - non-enhancing, peripheral mucosal enhancement may be present
- Juvenile nasopharyngeal angiofibroma (JNA)
- Olfactory neuroblastoma
- Paranasal sinus mucocoele

# Histopathology

## Epithelial

### *Benign*

Exophytic papilloma  
Inverted papilloma  
Columnar papilloma  
Adenoma

### *Malignant*

Squamous cell carcinoma  
Transitional cell carcinoma  
Adenocarcinoma  
Adenoid cystic carcinoma  
Melanoma  
Olfactory neuroblastoma  
Undifferentiated carcinoma

## Lymphoreticular tumors

Lymphoma  
Plasmacytoma  
Giant cell tumor

## Metastatic carcinoma

## Nonepithelial

### *Benign*

Fibroma  
Chondroma  
Osteoma  
Neurilemmoma  
Neurofibroma  
Hemangioma

### *Malignant*

Soft-tissue sarcoma  
Rhabdomyosarcoma  
Leiomyosarcoma  
Fibrosarcoma  
Liposarcoma  
Angiosarcoma  
Myxosarcoma  
Hemangiopericytoma  
Connective tissue sarcoma  
Chondrosarcoma  
Osteosarcoma

# Histopathology

**Table 1.** Pathology among patients undergoing anterior craniofacial resection

Malignant		Benign	
Olfactory neuroblastoma	7	Aggressive polyposis	1
Recurrent nasopharyngeal carcinoma	4	Mucocele	1
Malignant fibrous histiocytoma	4		
Adenocystic carcinoma	3		
Squamous cell carcinoma	3		
Osteogenic sarcoma	2		
Adenocarcinoma	1		
Undifferentiated carcinoma	1		
Malignant mixed tumor	1		
Malignant melanoma	1		
Chordoma	1		
Total	28	Total	2

**Diagnosis – Image / Histology**



# CT & MRI

- **Bony involvement** is best demonstrated on **CT scan** with bone windows.
- **MRI** with gadolinium can demonstrate **intracranial and soft tissue extension**.
- The main role of imaging is **to determine the extent of the neoplasm**, whether there is
  - intracranial disease
  - cranial nerve involvement
  - tumor around the vertebral or basilar artery
  - circumferential tumor around the ICA

# CT & MRI

- Imaging findings that best correlate with **dural invasion** by the tumor are both **dural enhancement** and **focal nodularity of the enhancing intracranial tumor**.  
sensitivity of 88%, specificity of 100%, accuracy of 95%
- Dural enhancement of greater than 5 mm was 91% sensitive in predicting invasion.
- Sinonasal tumors can **gain intracranial access** via direct invasion through the nasal cavity, sinuses, or orbit.
- Another common pattern for HN tumors to access the intracranial compartment is via the **cranial nerves**

# Sinonasal Inverted Papilloma

- **CT findings**

  - 40% show “**entrapped bone**”

  - Focal hyperostosis of adjacent bone may indicate point of tumor attachment

- **MR findings**

  - T2: Predominantly **hyperintense** to skeletal muscle

  - T2 & T1 C+ FS MR:

    - Curvilinear striations or “**convoluted, cerebriform pattern**” is distinctive

- **MRI: differentiating tumor from obstructed secretions**

# Sinonasal SCC

- CT finding:

**Bone destruction** is characteristic  
irregular margins

Enhancement tends to be heterogeneous

- MRI finding:

T1WI

Intermediate signal mass, **similar to muscle signal**

T2WI

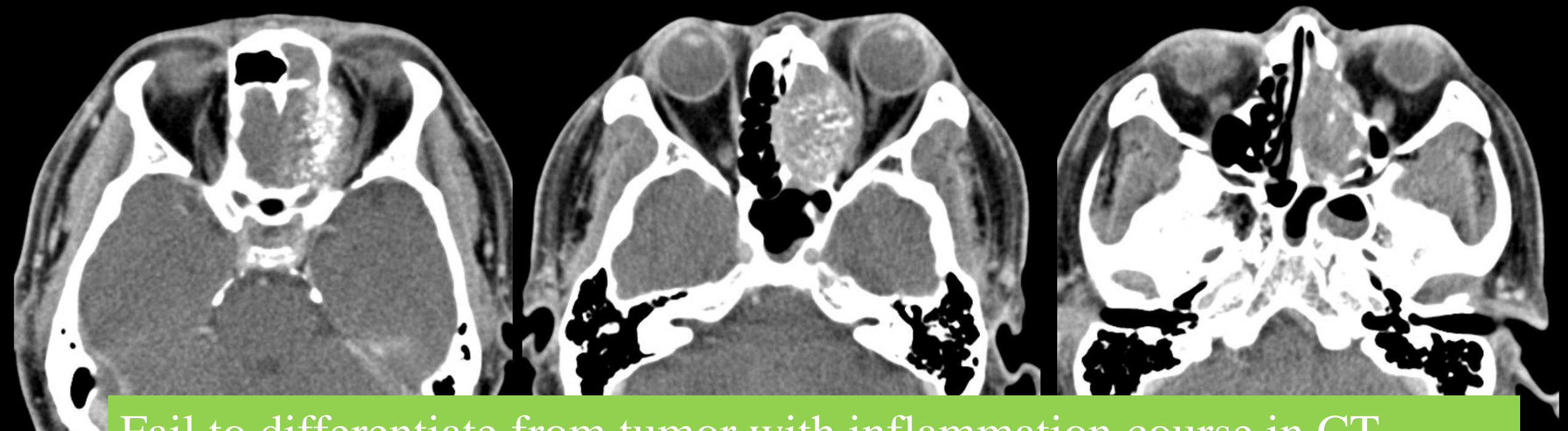**Intermediate to high signal** compared to musculature, but lower than other sinonasal malignancies

**T2 differentiates high signal obstructed sinus secretions from tumor**

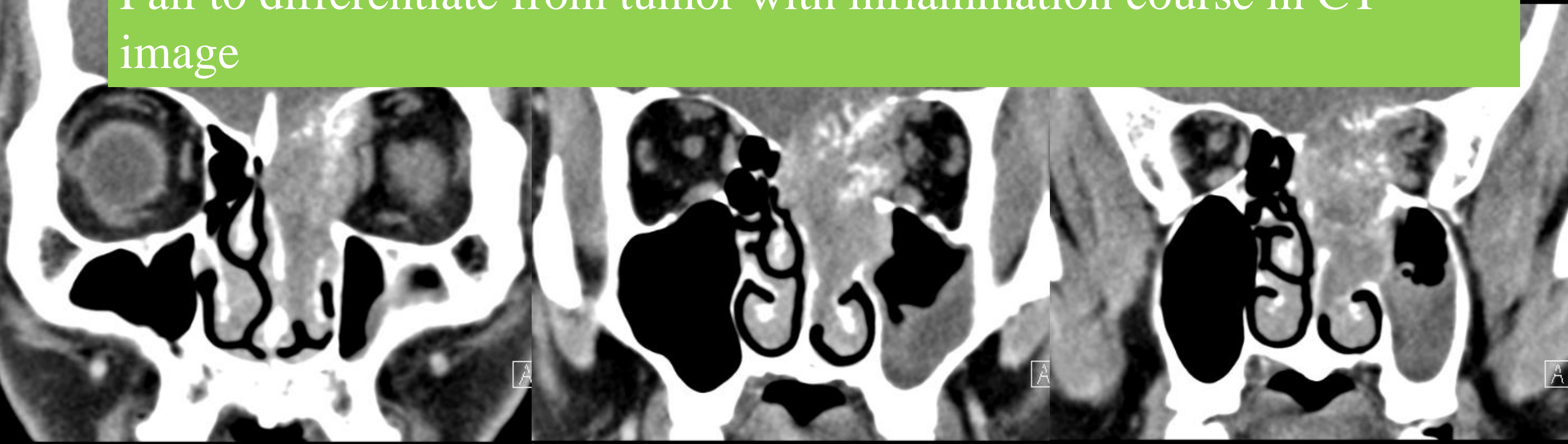- T1WI C+

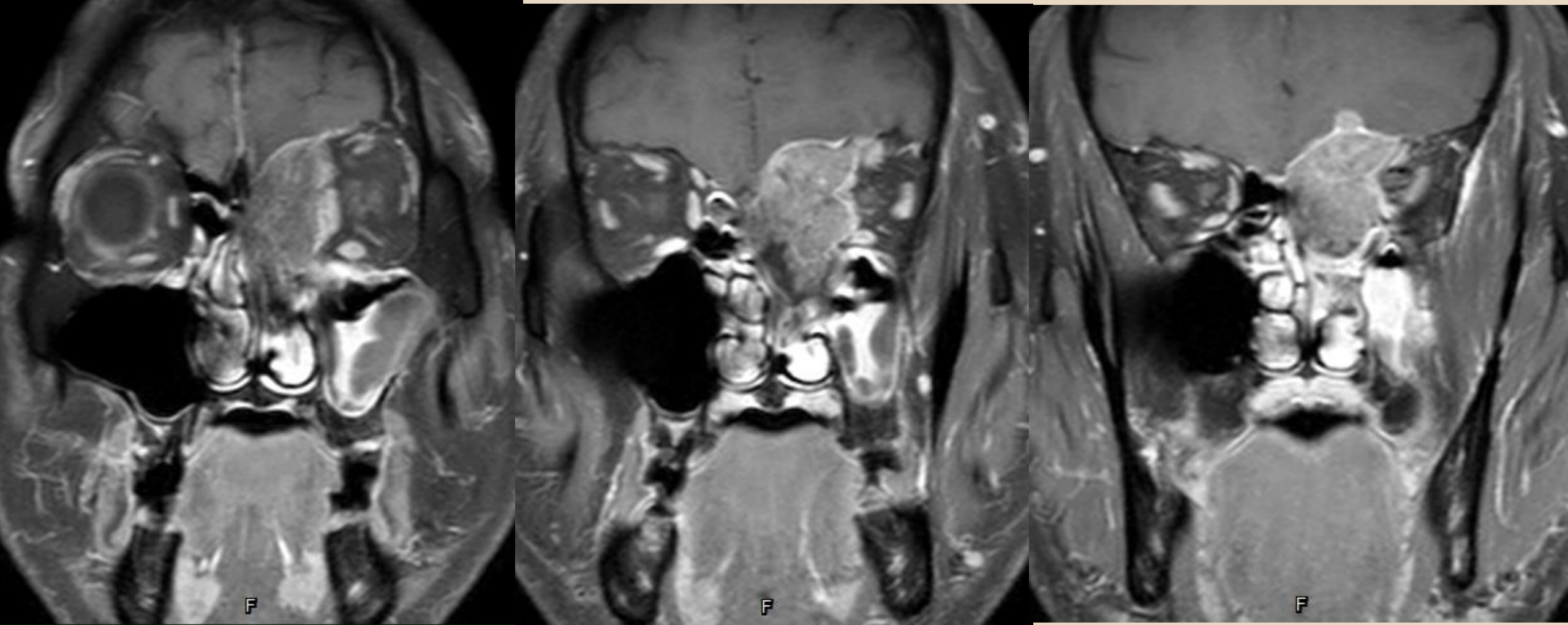
Enhancement typically mild to moderate; diffuse, but heterogeneous

Enhances to **lesser degree than adenocarcinoma, esthesioneuroblastoma, melanoma**

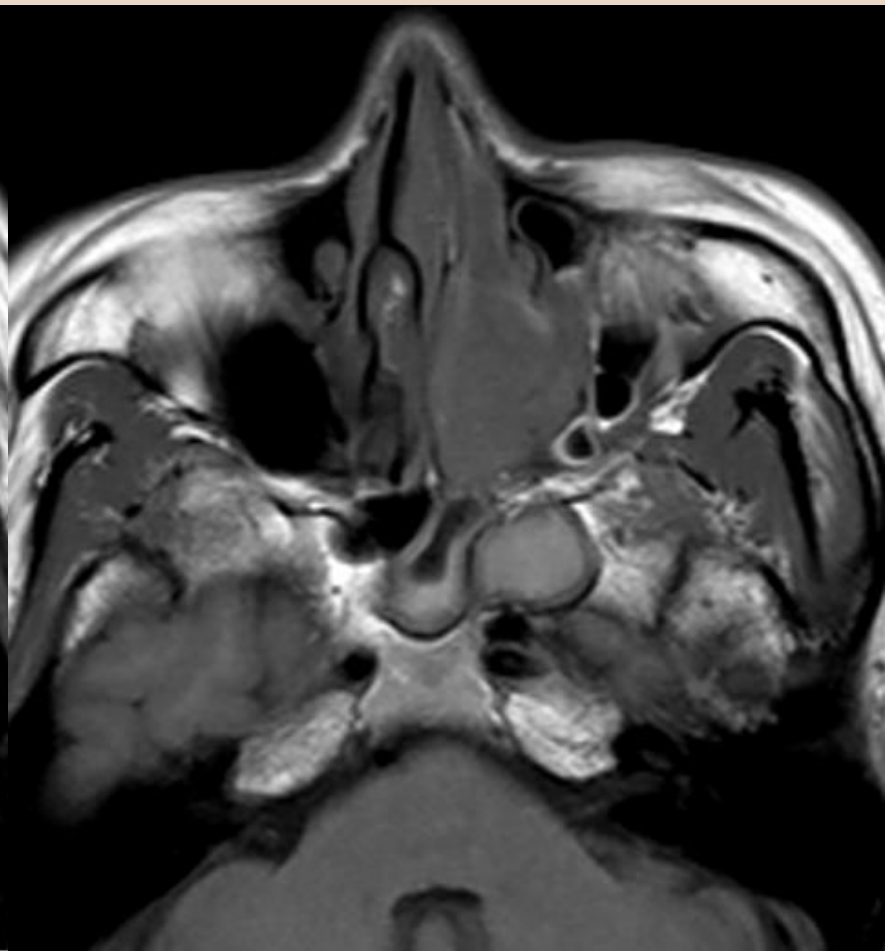
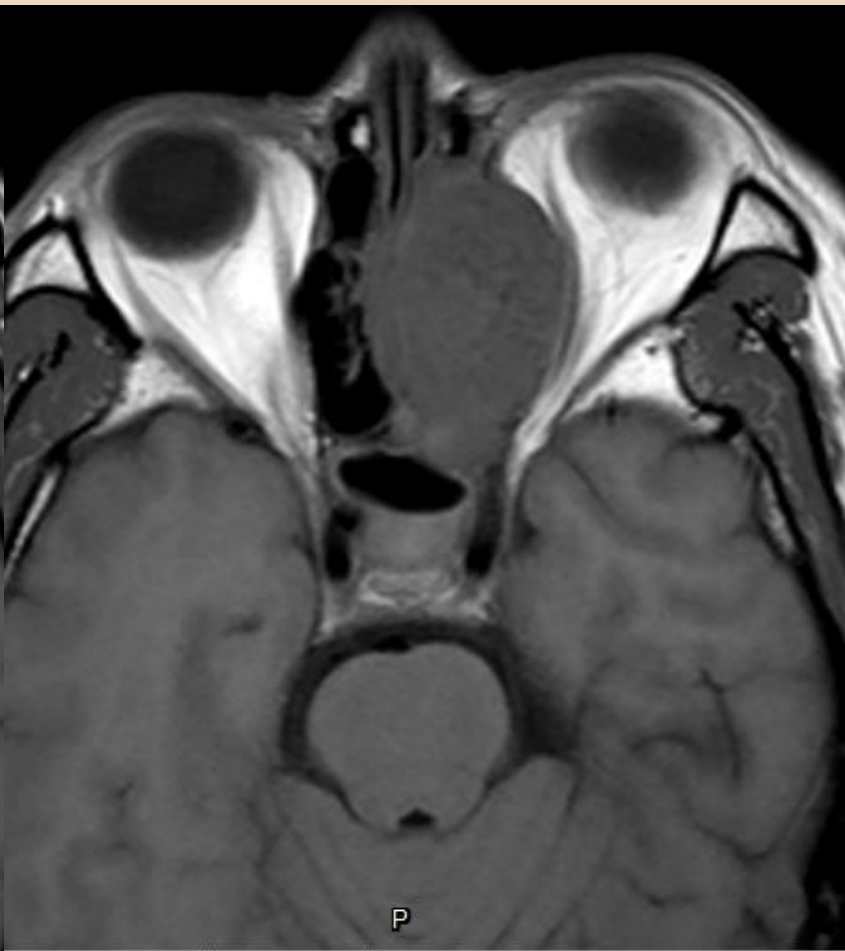
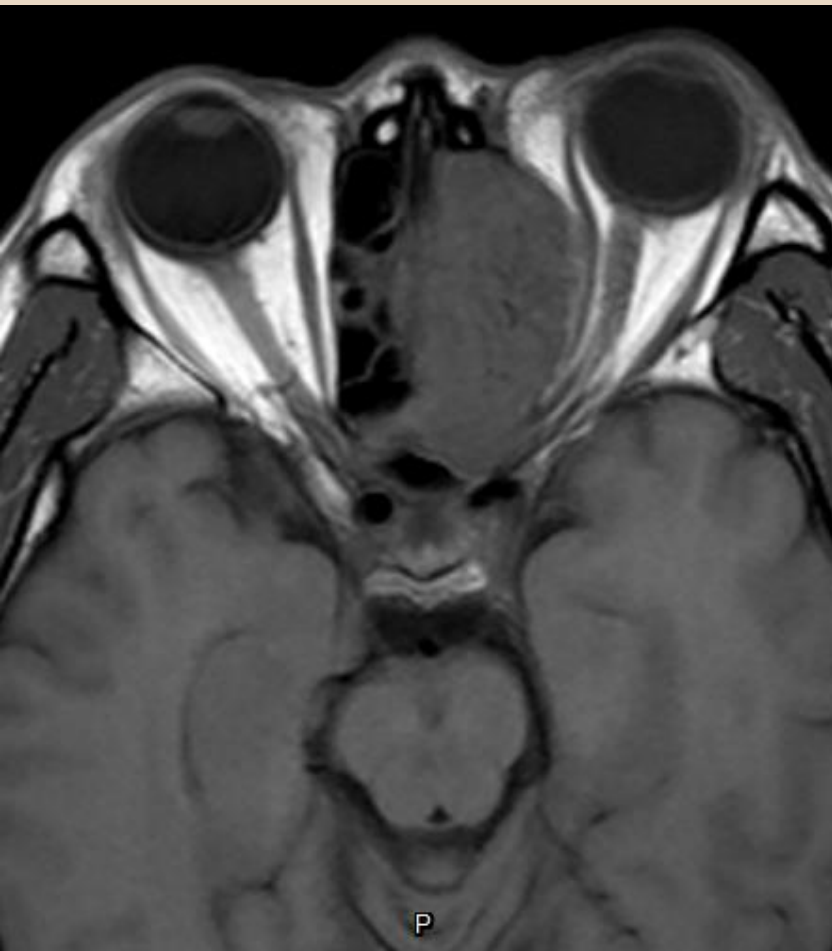


Fail to differentiate from tumor with inflammation course in CT image





- Intracranial extension
- Intradural invasion
- Intraorbital invasion



# PET/CT

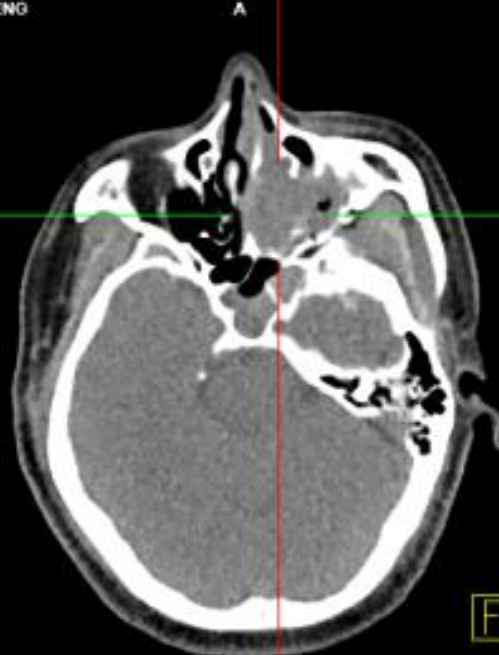
- PET-CT is a combination of cross-sectional anatomic information provided by CT and the metabolic information provided by **positron emission tomography (PET)**.
- PET is most commonly performed with 2-[F-18]fluoro-2-deoxy-D-glucose (FDG).

Fluorine-18 (F-18) is an unstable radioisotope and has a half-life of approximately 110 minutes.



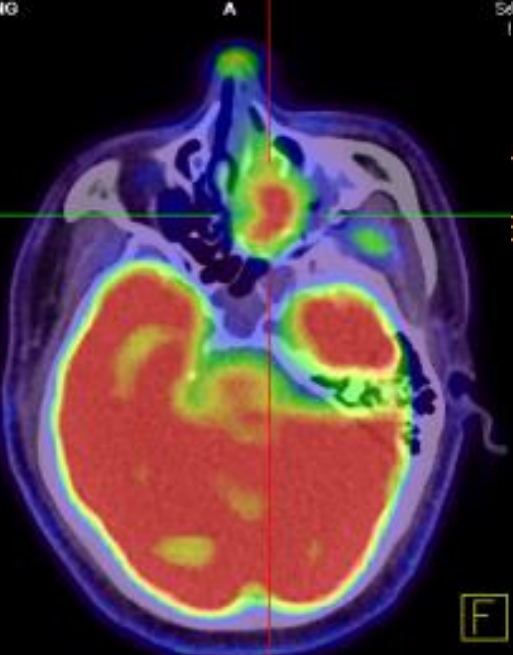
# Indications for FDG PET-CT Imaging

- Staging of patients where **staging** is difficult clinically.
- Staging or **restaging** of patients with a high risk of disseminated disease such as advanced loco-regional disease and primary sites with a high propensity for disseminated disease such as nasopharyngeal cancer. □
- To **identify the primary site** in patients presenting with metastatic squamous cell carcinoma in cervical lymph nodes, with no primary site identified on other imaging.
- **Response assessment** 3–6 months' post chemo-radiotherapy. □
- To **differentiate relapse from treatment effects** in patients suspected to have tumor recurrence where magnetic resonance imaging (MRI) is uncertain or equivocal.



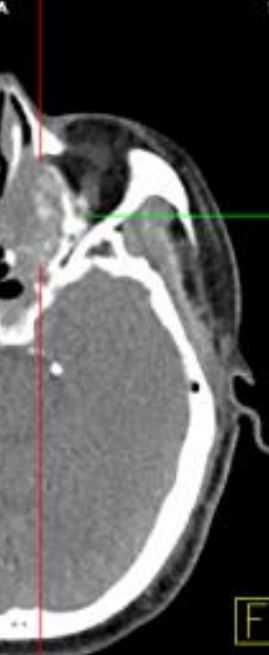
Ser.Nr.71173  
Biograph64  
VG51C

LIN CHIA CHIENG  
21174103  
\*10/10/1972  
18/10/2019  
10:00:10



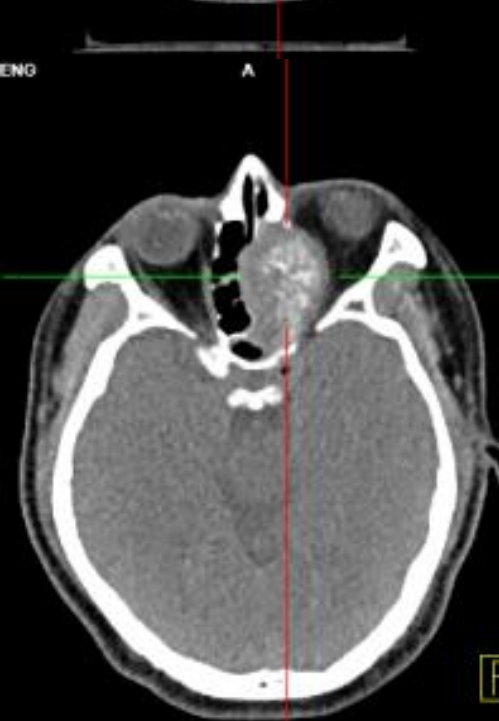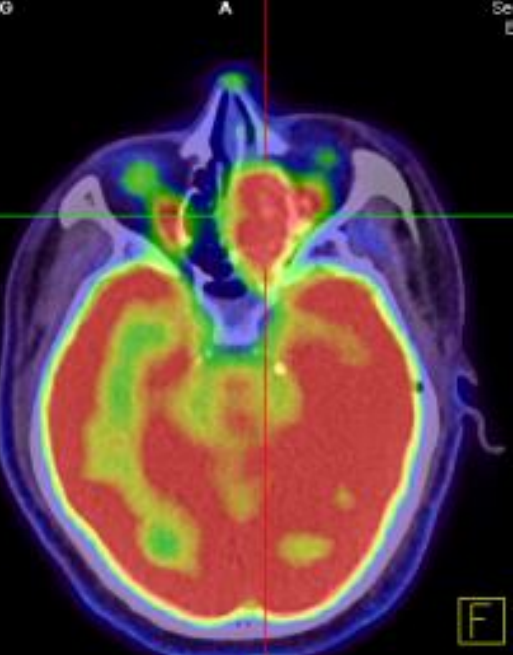
Ser.Nr.71173  
Biograph64  
VG51C

LIN CHIA CHIENG  
21174103  
\*10/10/1972  
18/10/2019  
10:00:10



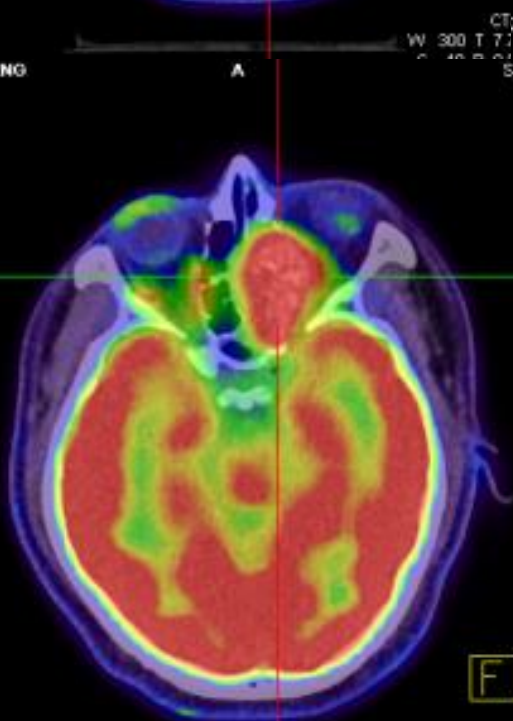
Ser.Nr.71173  
Biograph64  
VG51C

LIN CHIA CHIENG  
21174103  
\*10/10/1972  
18/10/2019  
10:00:10



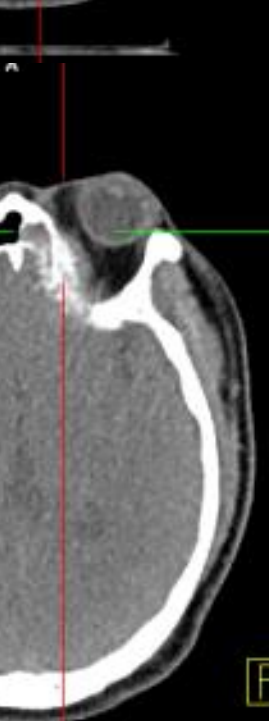
W 300 SP F910.7  
Ser.Nr.71173  
Biograph64  
VG51C

LIN CHIA CHIENG  
21174103  
\*10/10/1972  
18/10/2019  
10:00:10



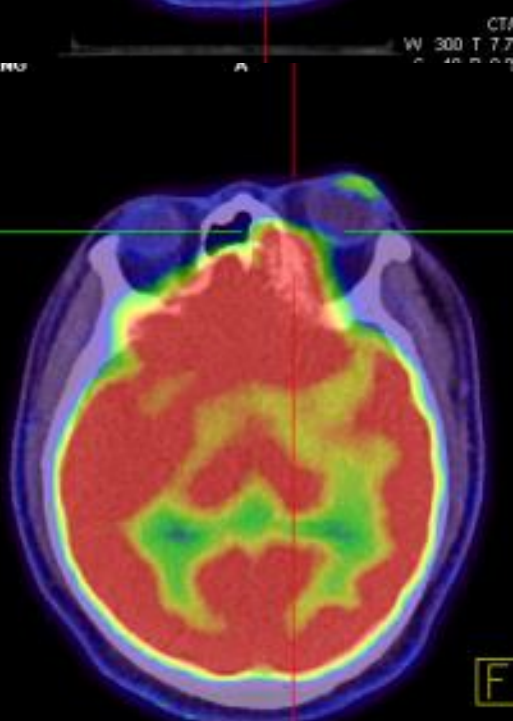
Ser.Nr.71173  
Biograph64  
VG51C

LIN CHIA CHIENG  
21174103  
\*10/10/1972  
18/10/2019  
10:00:10



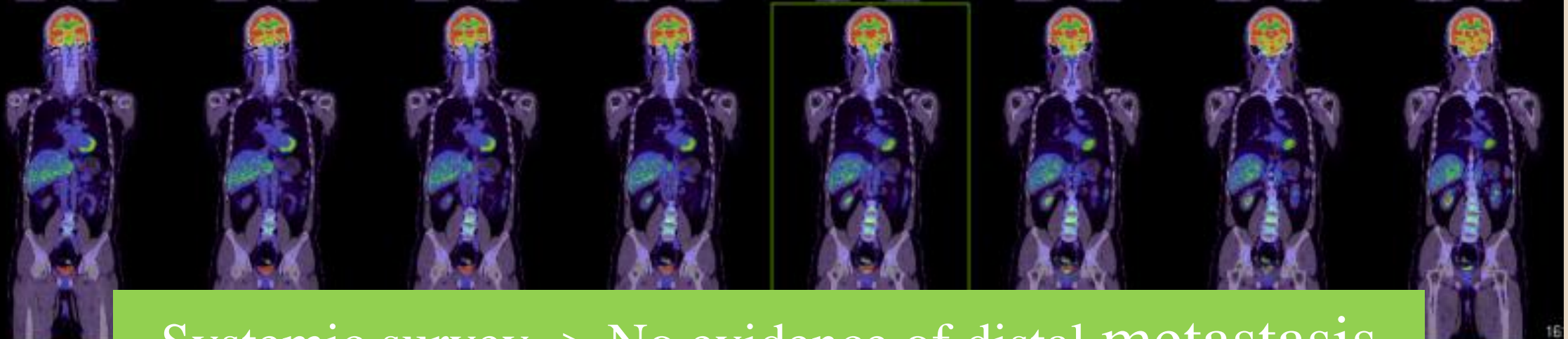
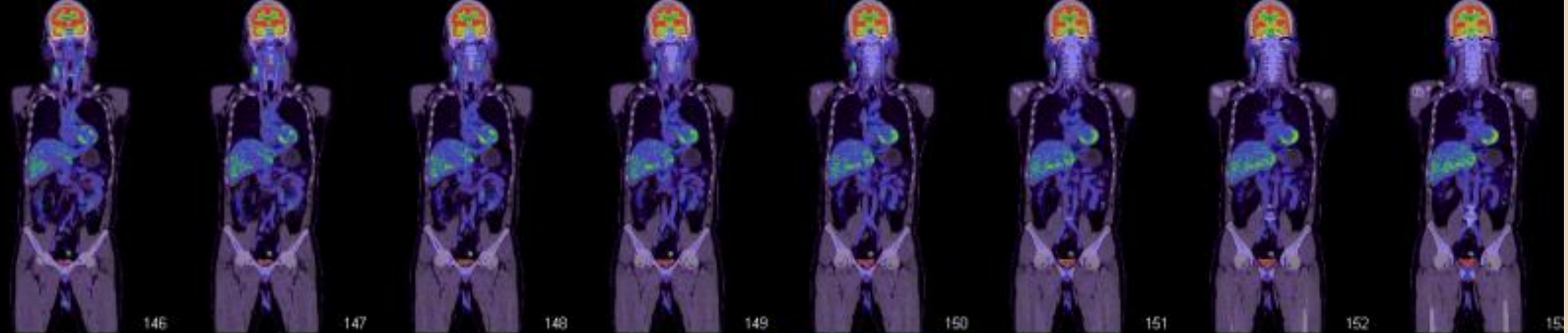
W 300 SP F904.7  
Ser.Nr.71173  
Biograph64  
VG51C

LIN CHIA CHIENG  
21174103  
\*10/10/1972  
18/10/2019  
10:00:10

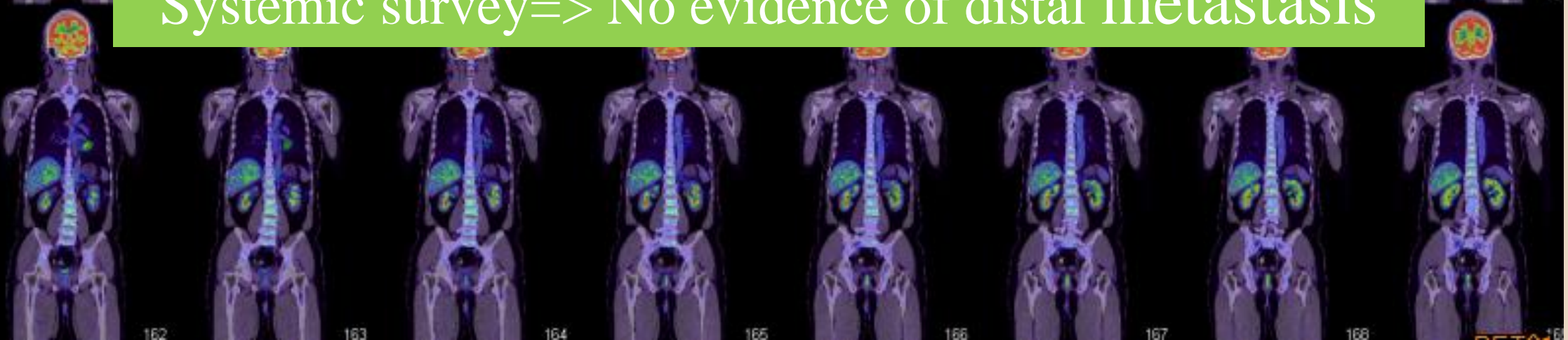


Ser.Nr.71173  
Biograph64  
VG51C

LIN CHIA CHIENG  
21174103  
\*10/10/1972  
18/10/2019  
10:00:10



Systemic survey=> No evidence of distal metastasis



# Staging

## Nasal cavity/ethmoid

T1	Restricted to any 1 subsite, with or without bony invasion
T2	Invades 2 subsites in a single region or extends to involve an adjacent region within the nasoethmoid complex, with or without bony invasion
T3	Extends to invade the medial wall or floor of the orbit, maxillary sinus, palate, or cribriform plate
T4a	Invades any of the following: anterior orbital contents, skin of the nose or cheek, minimal extension to anterior cranial fossa, pterygoid plates, sphenoid, or frontal sinuses
T4b	Invades any of the following: orbital apex, dura mater, brain, middle cranial fossa, cranial nerves other than V2, nasopharynx, or clivus

## Dulguerov modified TNM staging (T only)

T1	Nasal cavity/ paranasal sinuses (not sphenoid or superior most ethmoid)
T2	Includes sphenoid with extension to/erosion of cribriform plate
T3	Extends into orbit or anterior cranial fossa without dural invasion
T4	Tumor involving brain

# Kadish stage

## Kadish staging

Stage A	Tumor confined to the nasal cavity
Stage B	Tumor involves the nasal cavity + one or more paranasal sinuses
Stage C	Extension of the tumor beyond the sinonasal cavities and into the paranasal sinuses. Involvement of the cribriform lamina, orbit, skull-base, and intracranial
Stage D	Cervical lymph node involvement or distant metastasis

# Clinical Case of Craniofacial resection

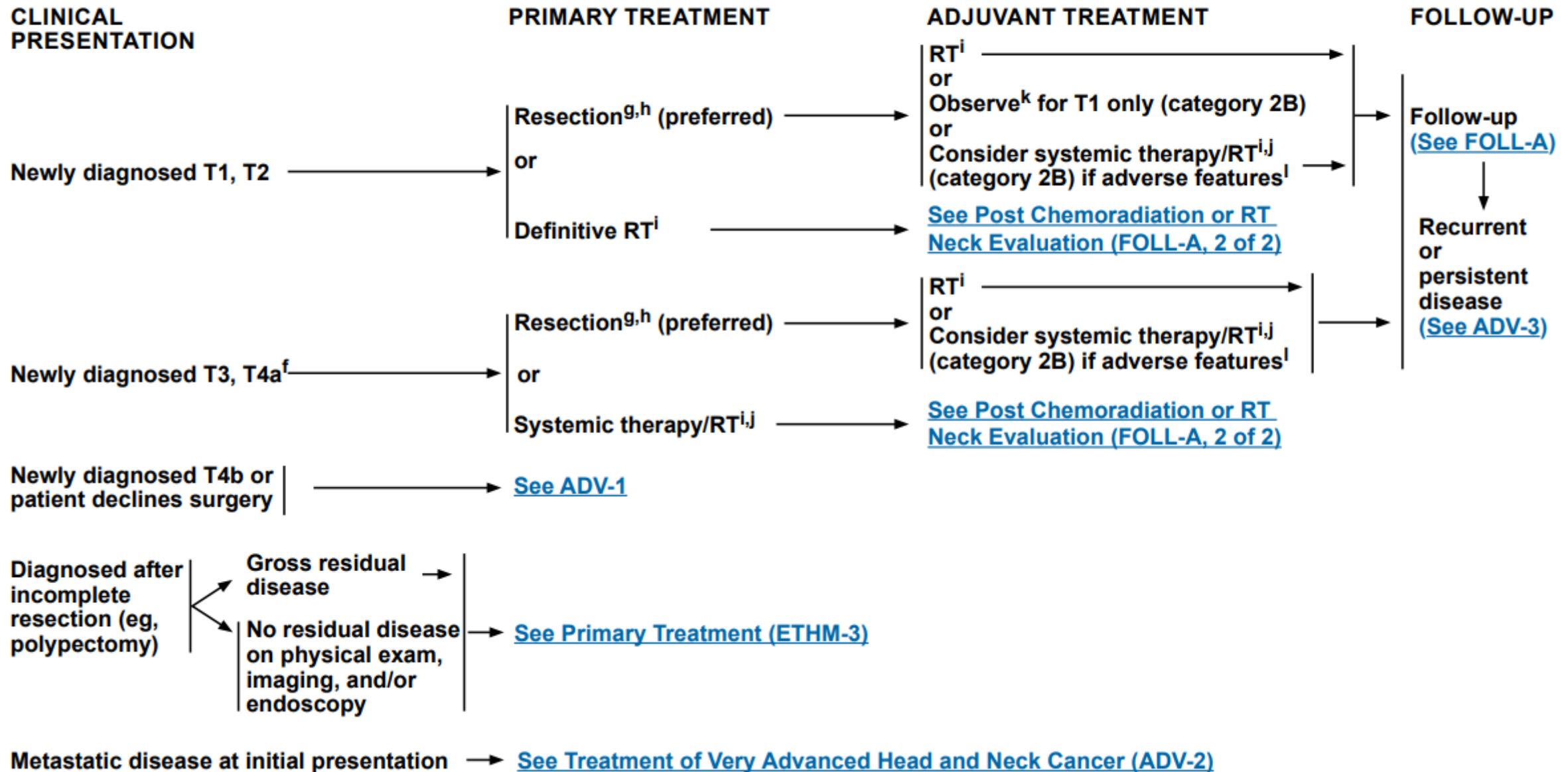
2019.10

- Second time biopsy done in OPD due to image findings
- Pathology:

## **Inverted papilloma with focal malignant change**

### MICROSCOPIC DESCRIPTION

- Section shows inverted papillomatous hyperplasia of squamous epithelium with some neutrophil infiltration. Focal tumor cells show moderate to marked nuclear hyperchromatism and pleomorphism, increased N/C ratio and mitoses involving full thickness of mucosa. Focal suspicious of tumor cell necrosis and stromal invasion is noted.
- Staging: **Kadish stage C** 、 **TNM stage 4b**



**Treatment**



# Treatment

Radiation therapy

Concurrent chemoradiotherapy

Operation

# Surgical Approach to Anterior Cranial Base

- Conventional approach
  - a) Subfrontal (Transcranial)
  - b) Transfacial
  - c) Craniofacial
- Endoscopic approach

# Oncology Concept

- En bloc vs Piecemeal resection

Open approaches are required when attempted **en bloc resection**, and resection of large and highly invasive tumors.

- "central debulking"- modified en bloc resection

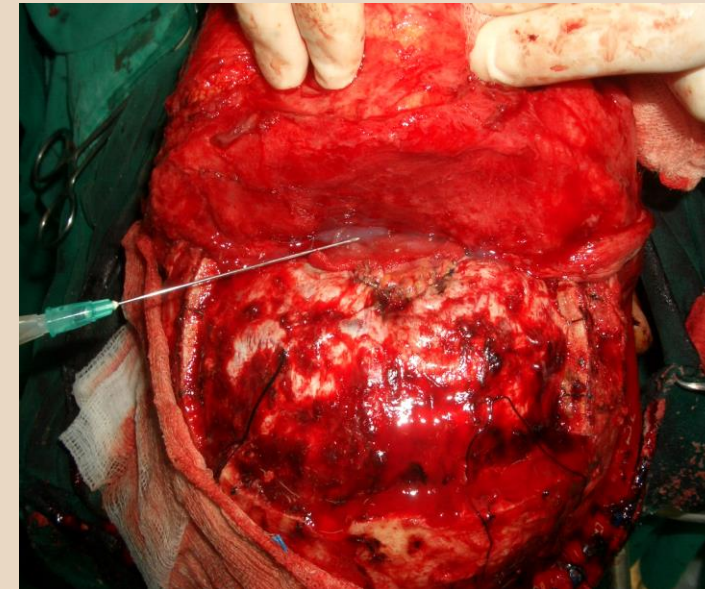
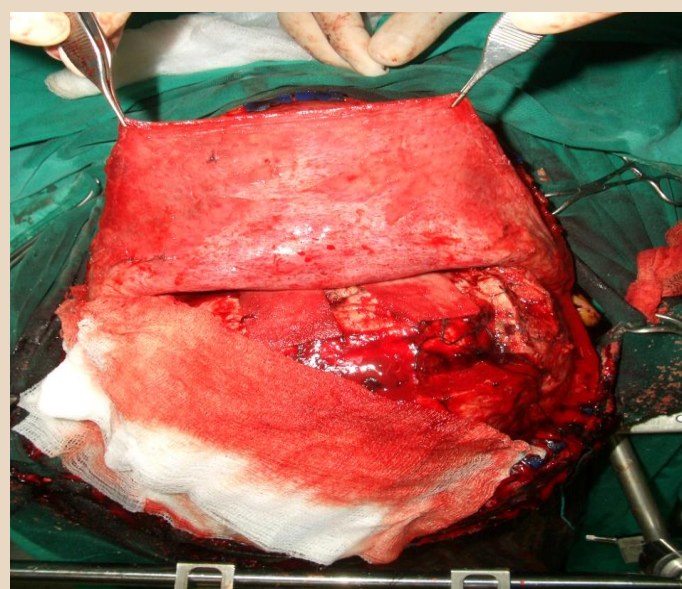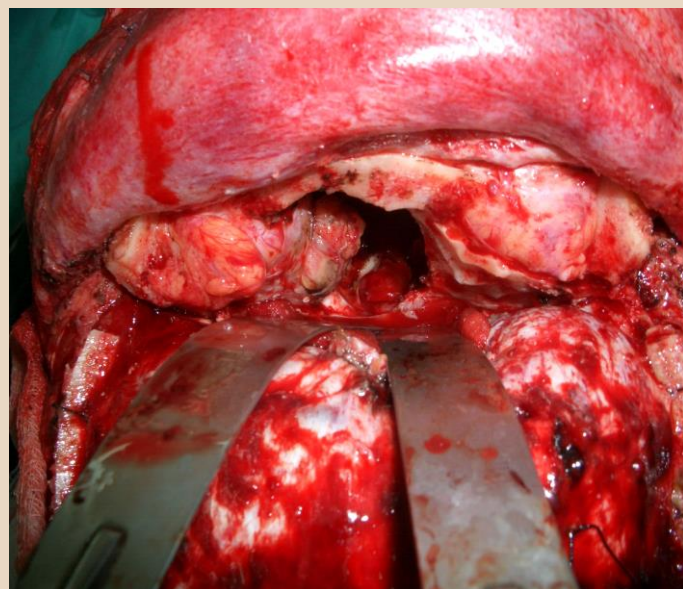
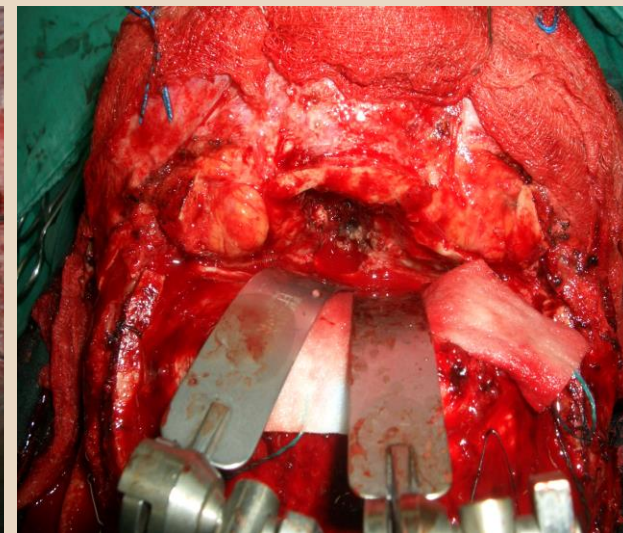
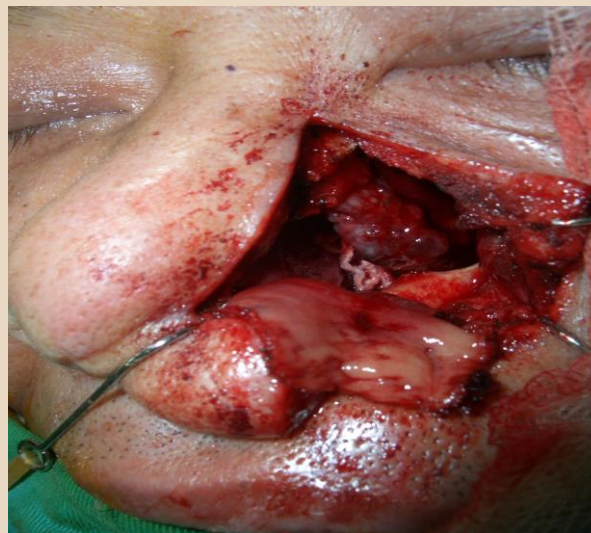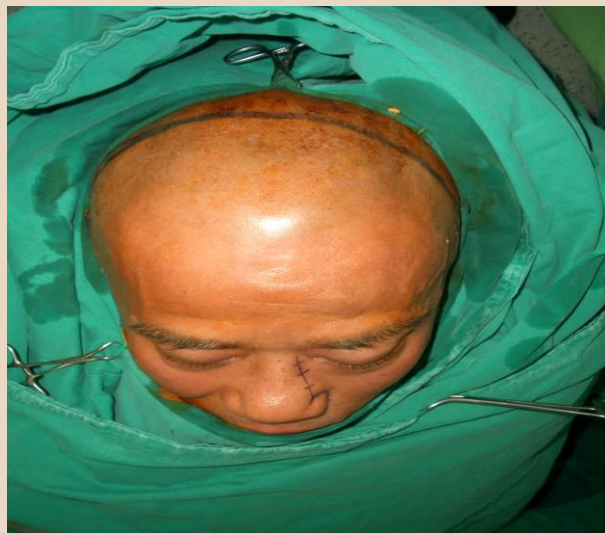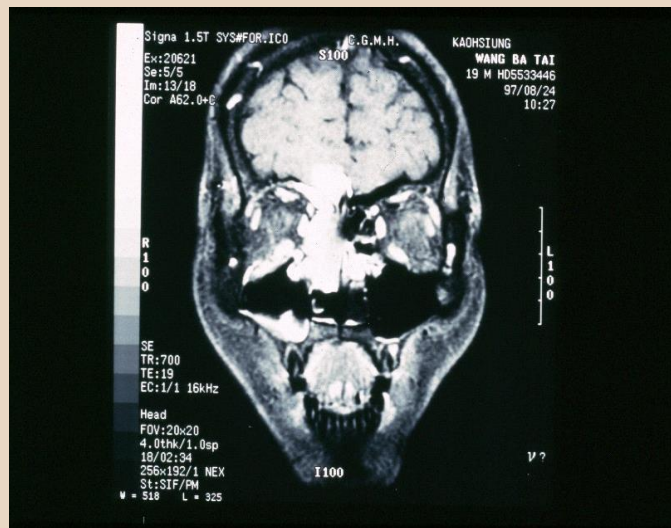# **Surgical Approach to Anterior Cranial Base**

- Craniofacial resection
- Transfacial
- Extended subfrontal
- Endoscopic

# Craniofacial Resection

- Bidirectional approach
- Wide field exposure
- Oncologically sound resection
- Standard approach

# Craniofacial Resection

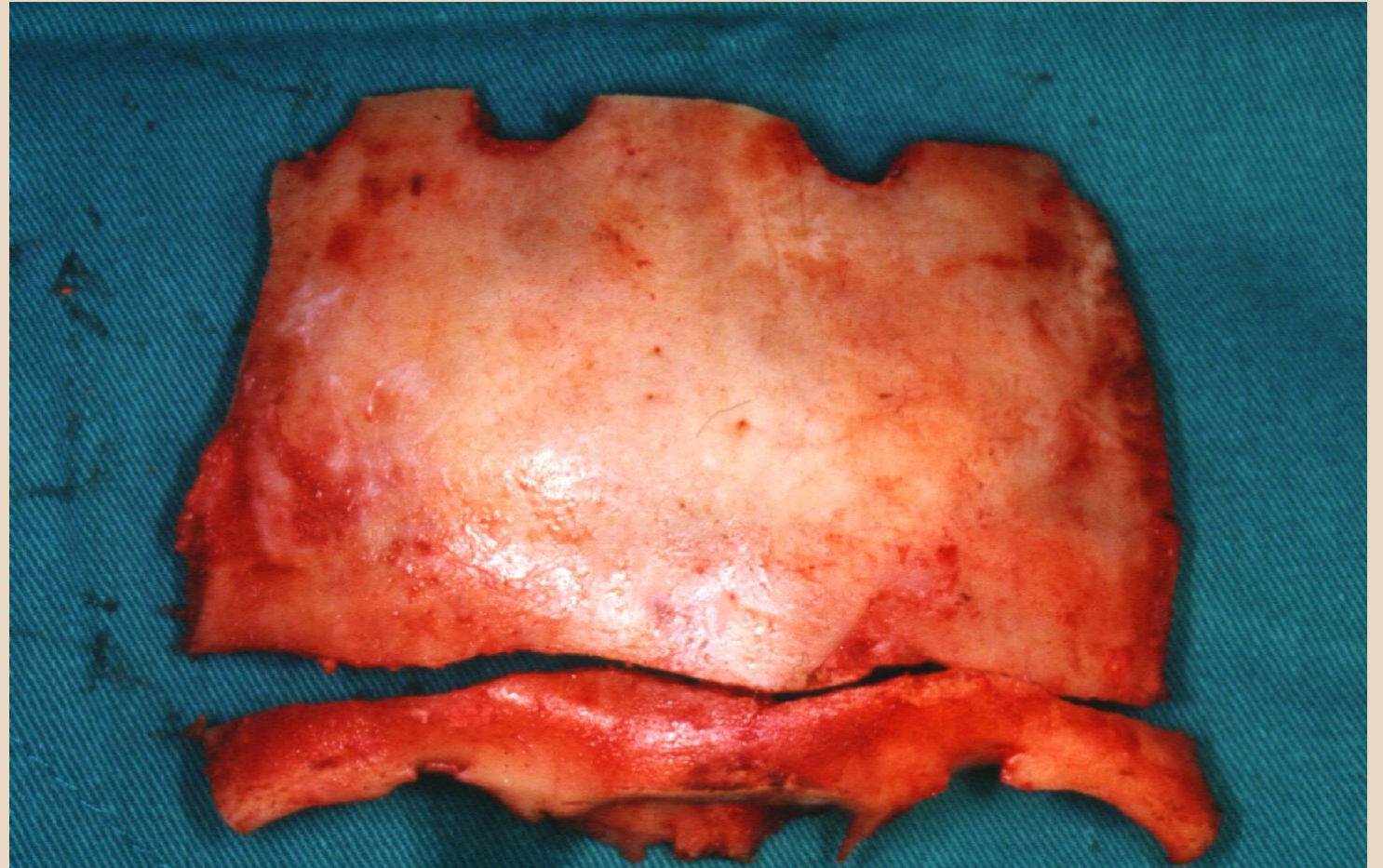


# Subfrontal (Transcranial)

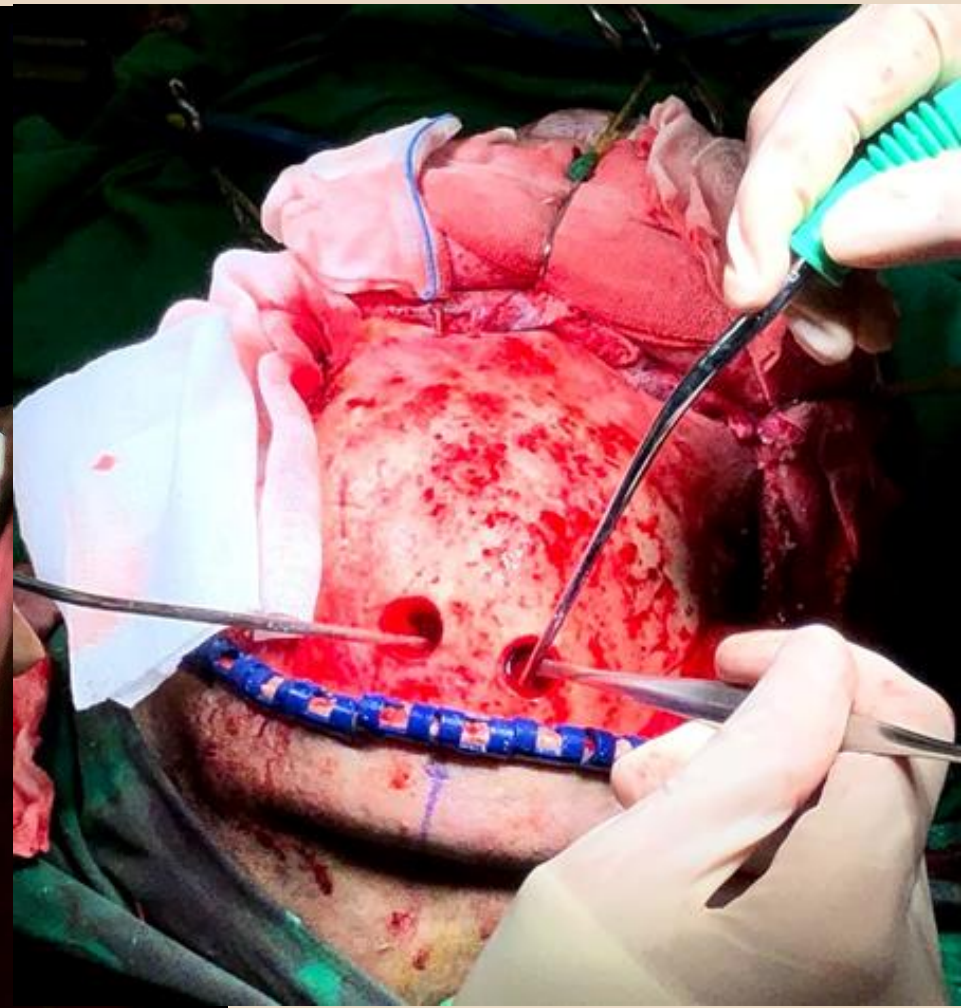
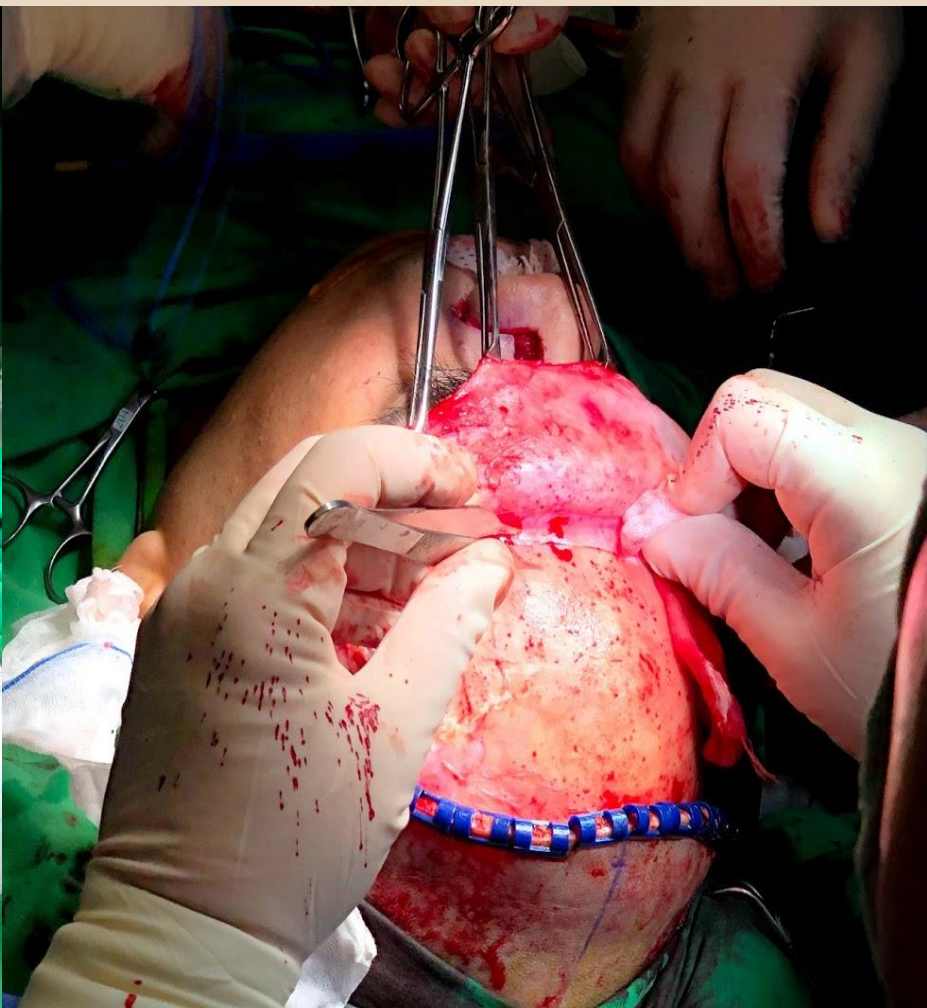
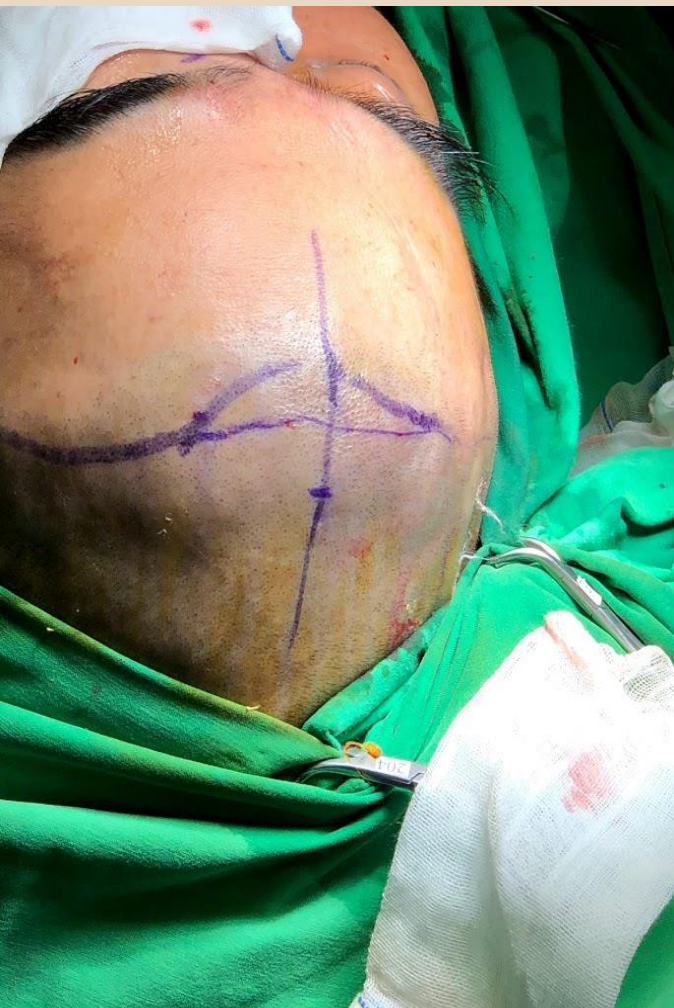- Traditional approaches to anterior skull base lesions involve a **frontal craniotomy** and an incision behind the hair line.
- The **frontal, bifrontal, pterional approaches** and their variations with extension along the skull base including the expanded bifrontal, frontotemporal orbitozygomatic and transbasal.


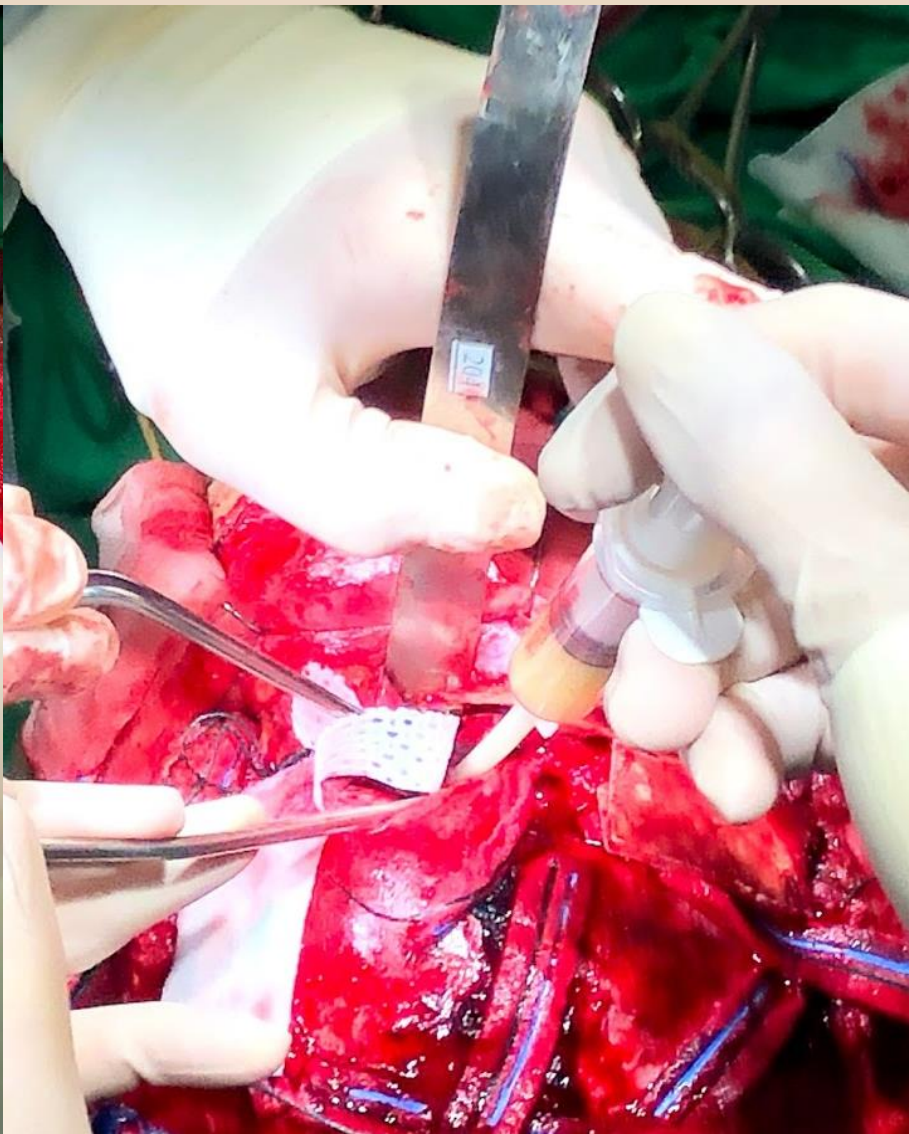
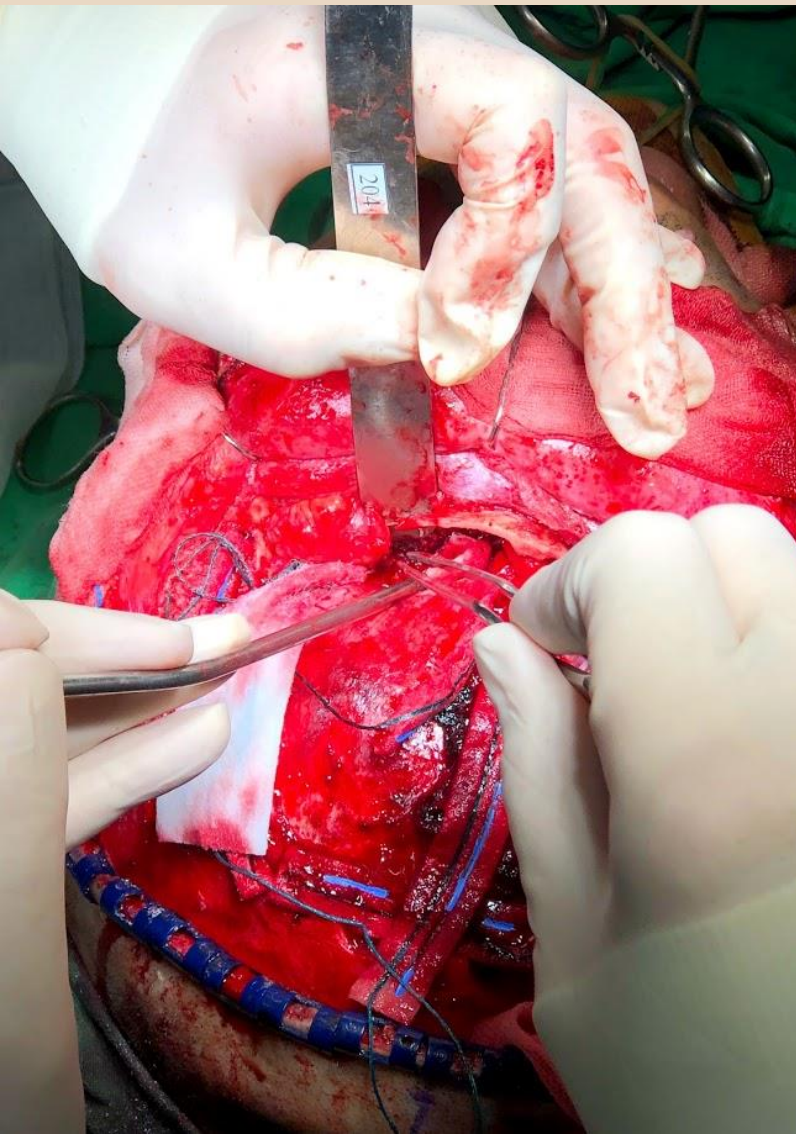
# Transcranial (transbasal) Approach

- Frontal craniotomy
- Orbital bar
- Supra-orbital









# Conventional Tranfacial Approach

- The **Le Fort I osteotomy**

to gain full exposure of a tumor from the cribriform plate to the lower clivus.

- The **lateral rhinotomy incision with or without osteotomy**

to gain access to the lateral nasal cavity and maxillary sinus

- The **Weber-Fergusson incision**

to reach the lateral maxillary cavity and palate

- The **Lynch incision**

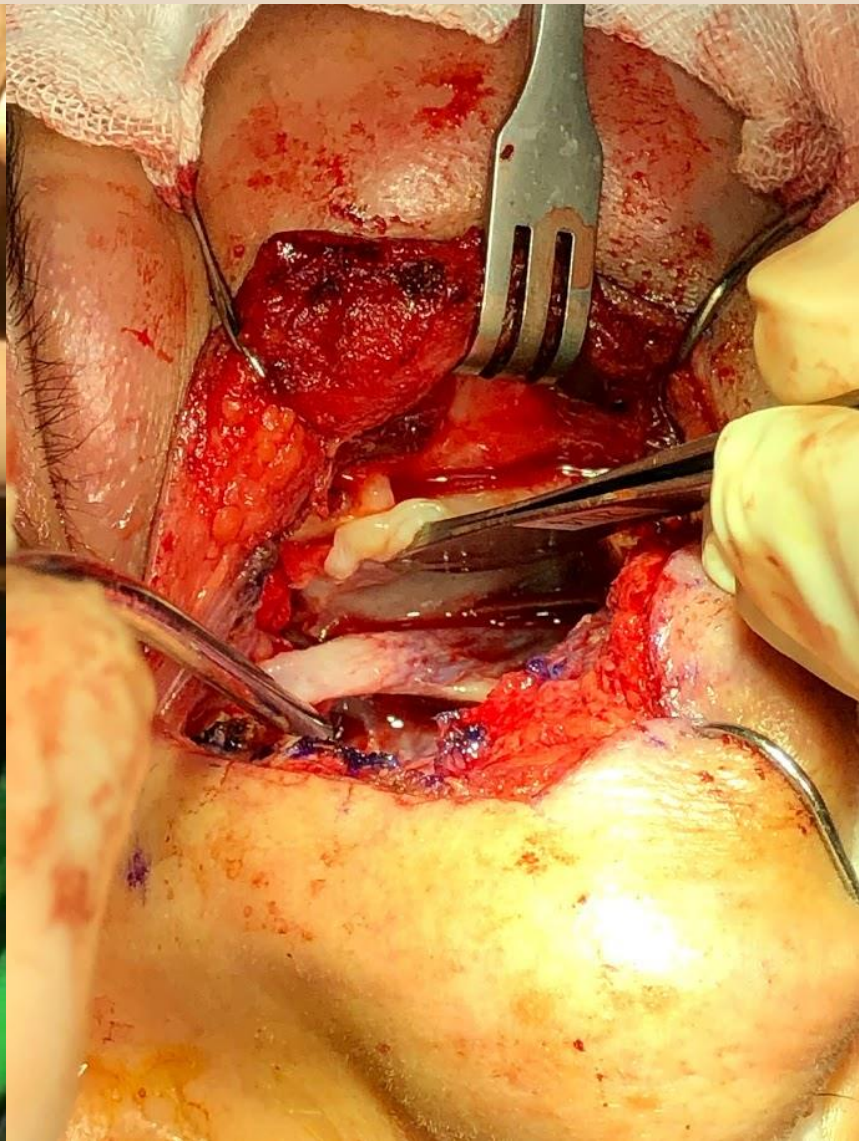
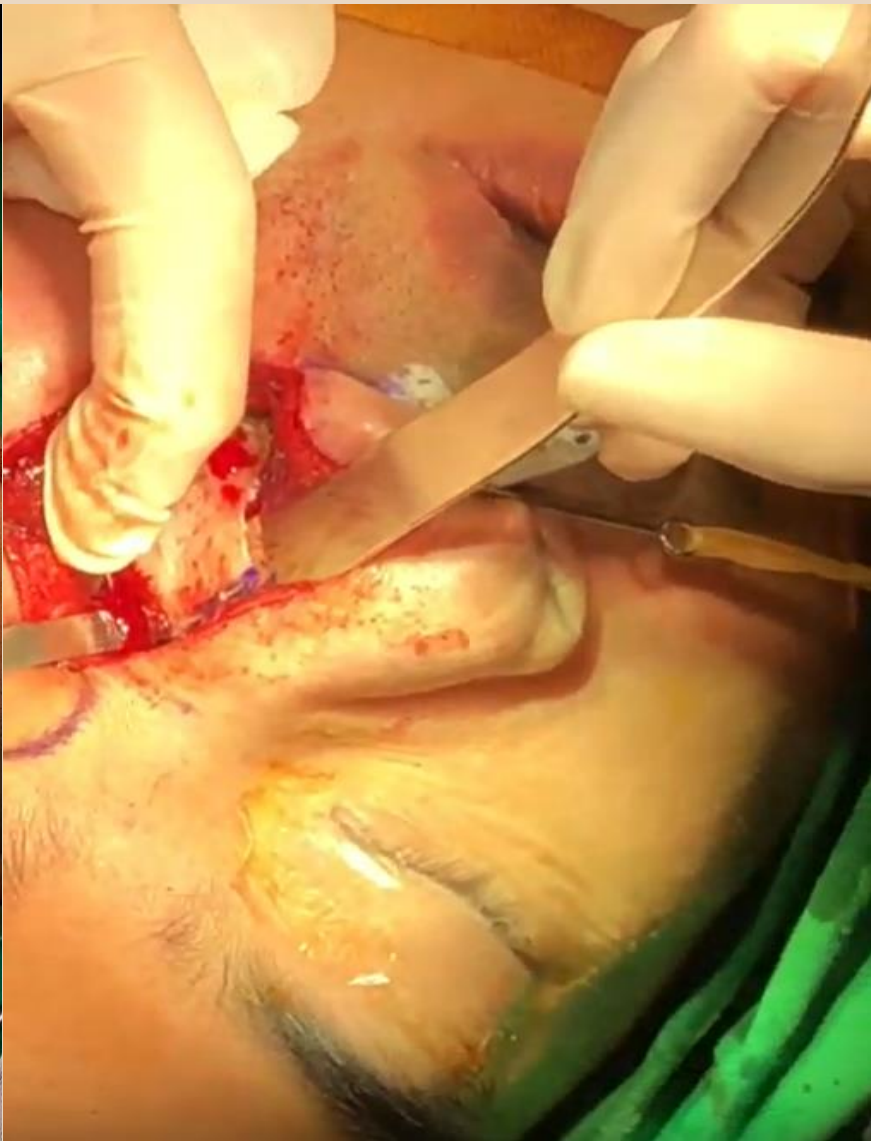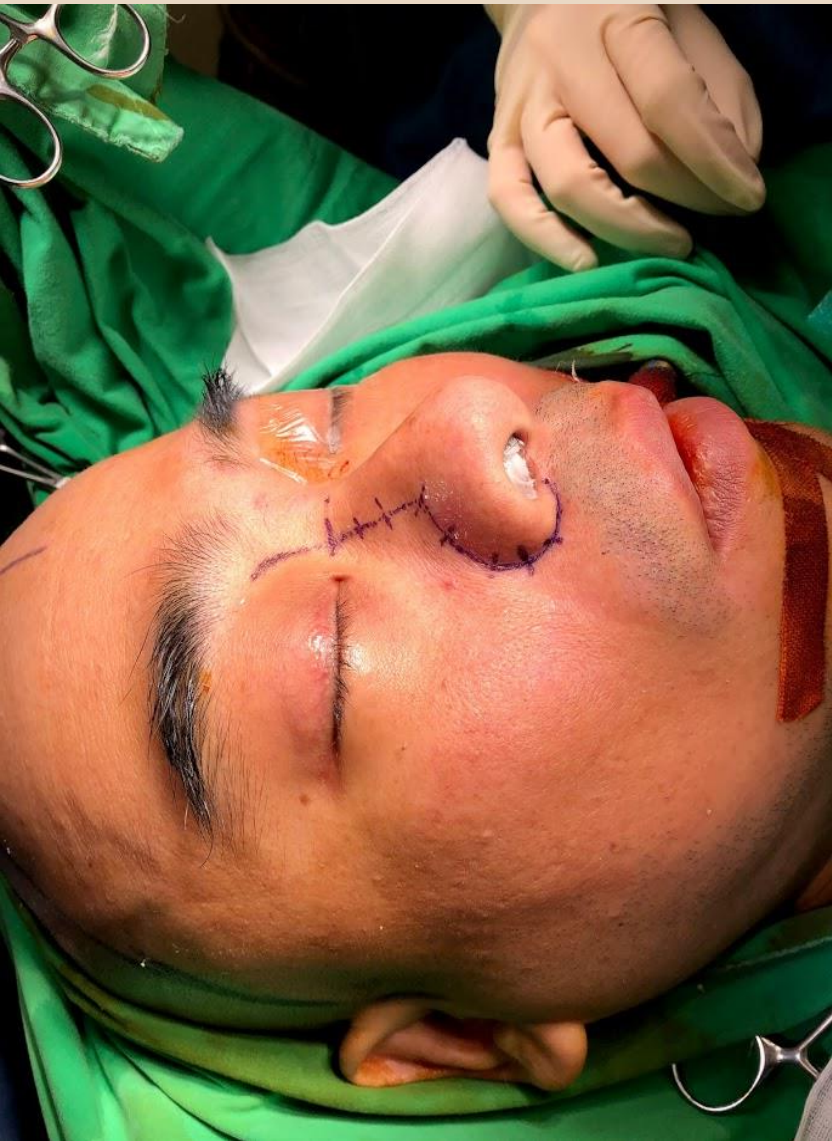extends the Weber-Fergusson to include the lateral orbit

- The **Dieffenbach incision**

for tumors in the infra-orbital rim and zygomatic root as well as the maxilla

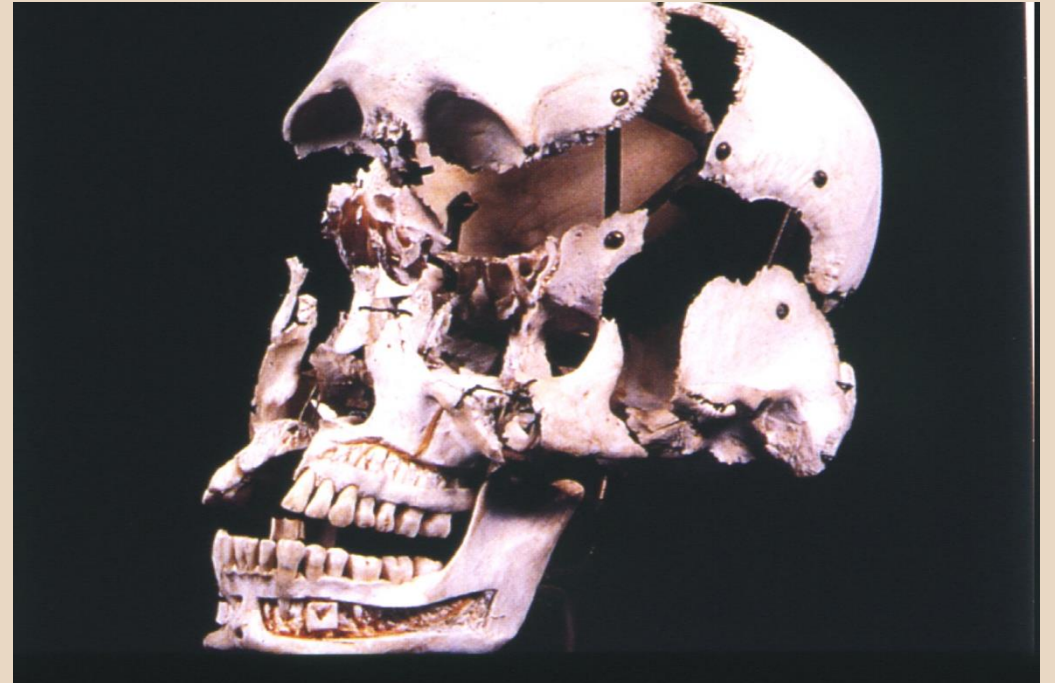
- The **Midfacial degloving procedure**

avoids a facial incision by using a sublabial incision, yet allows similar access to the lateral rhinotomy incision and the Weber-Fergusson incision

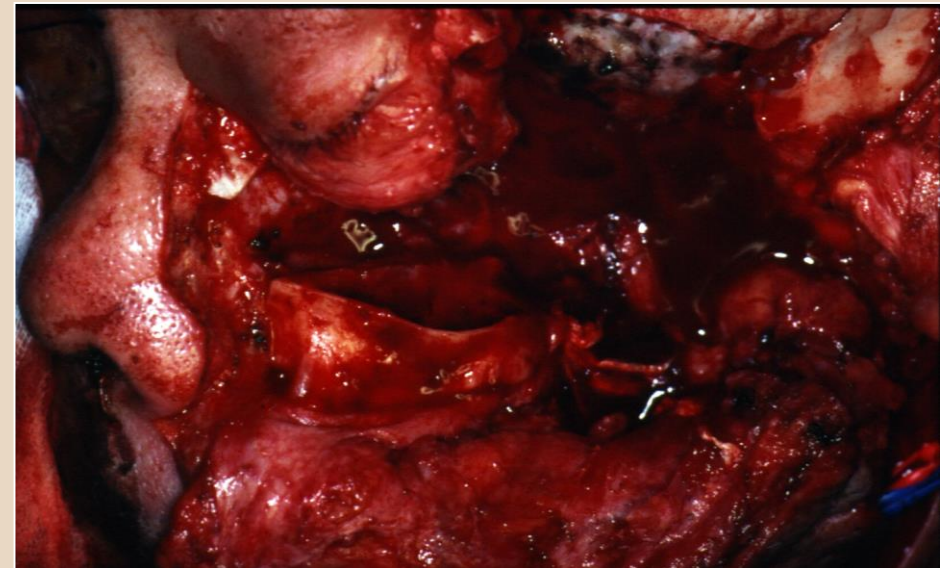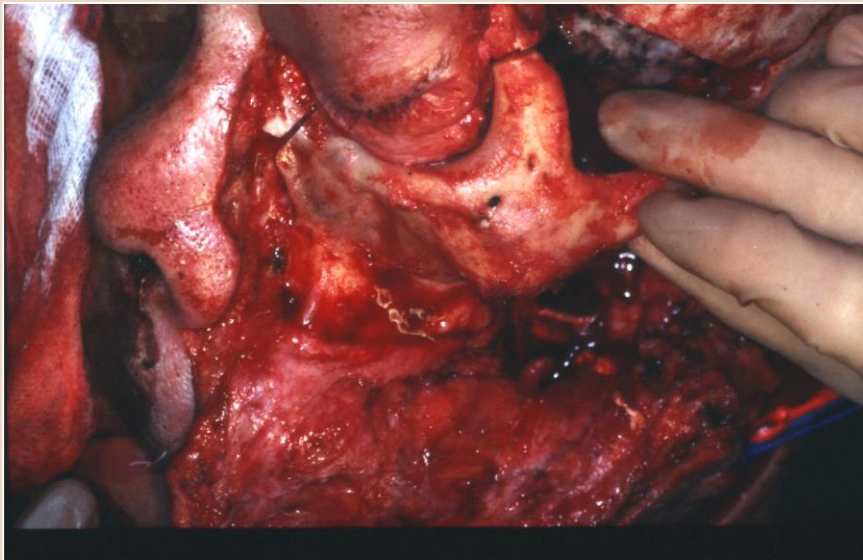
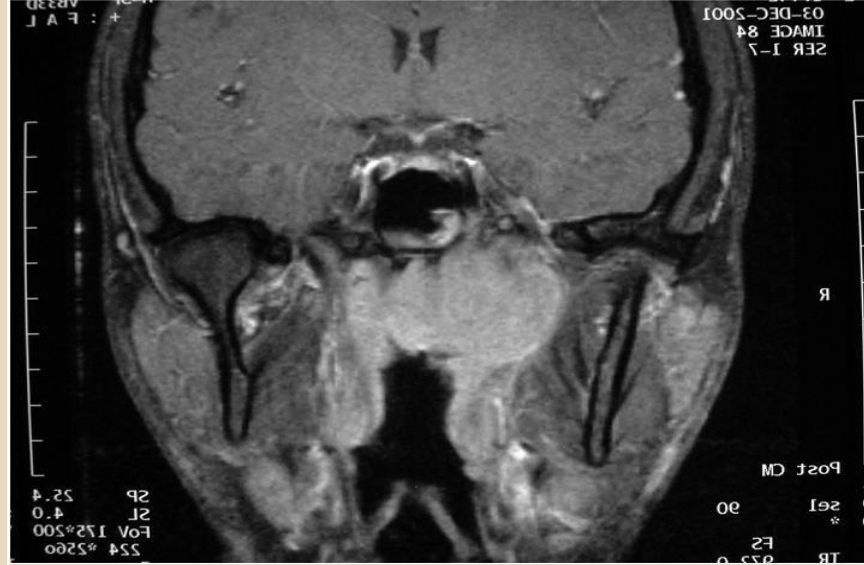


# Tranfacial Resection– *Facial Translocation*

- Janecka IP , 1989
- Anterior & central skull base
- Modular craniofacial disassembly
- Excellent surgical field
- Extensive tumor resection, reconstruction

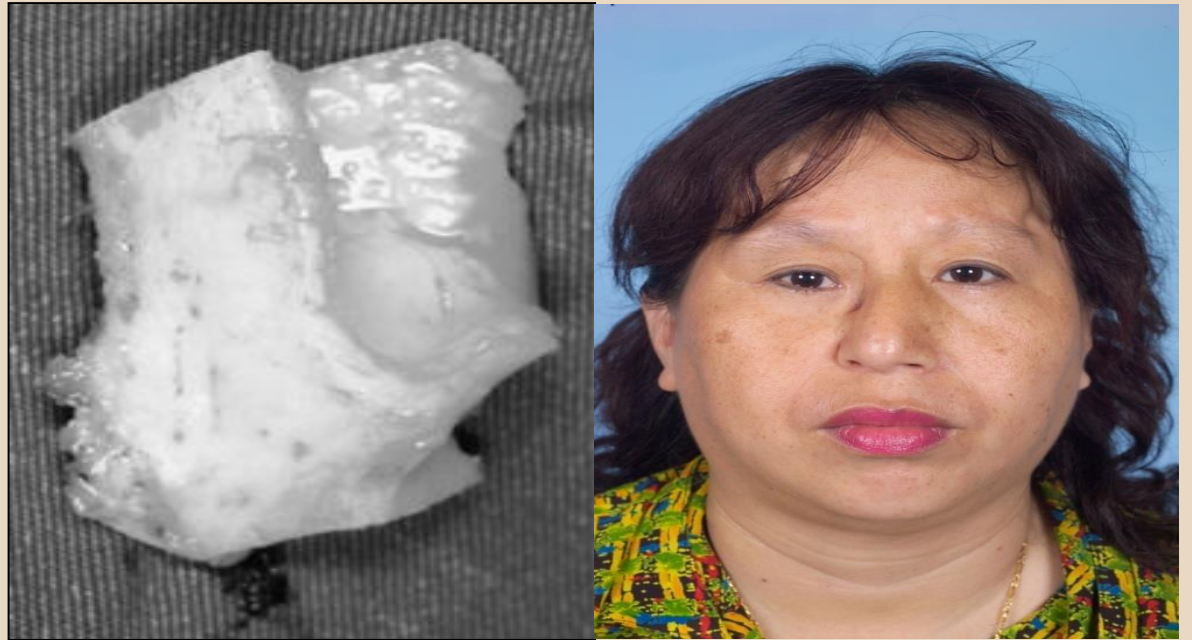

# Facial Translocation Approach



# Pitfall of Facial Translocation

- bone graft viability
- facial scar, psychiatric impact



free bone graft

## **Facial translocation approach to the skull base:**

### *The viability of translocated facial bone graft*

**SP Hao MD, FACS, FICS**

**Otolaryngol Head Neck Surg**

**2001; 124: 292-6**

- Bone graft necrosis: RT, without reconstruction
- Viability increase with reconstruction esp after RT



# **Lateral Nasal Wall Mucoperiosteal Flap**

**A Versatile New Reconstruction of the Inner Defect of Translocated Facial Bone Segments**

**Annal Plast Surg 2004; 52, 343-8**

**Sheng-Po Hao MD**

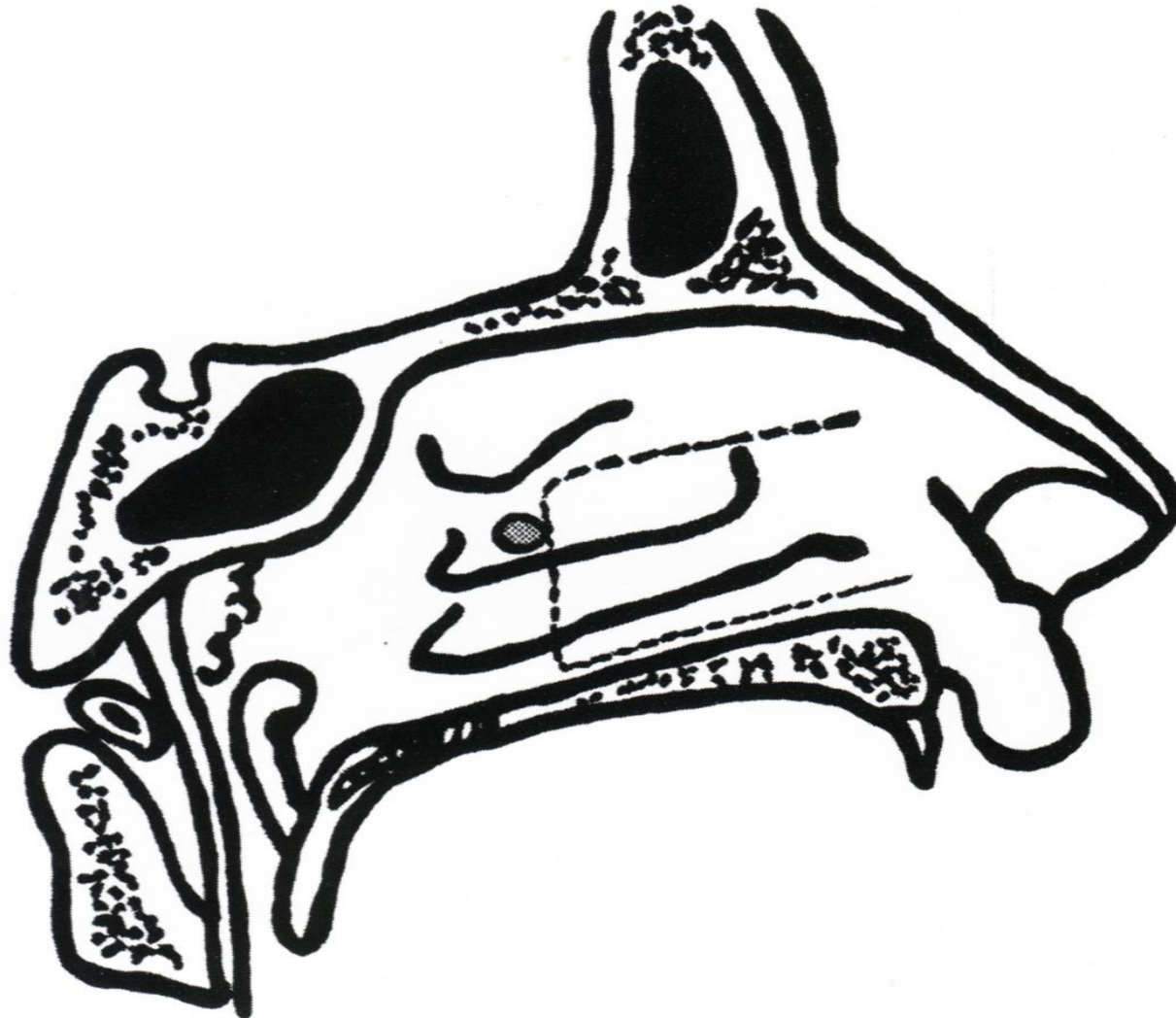
Lateral nasal wall mucoperiosteal flap

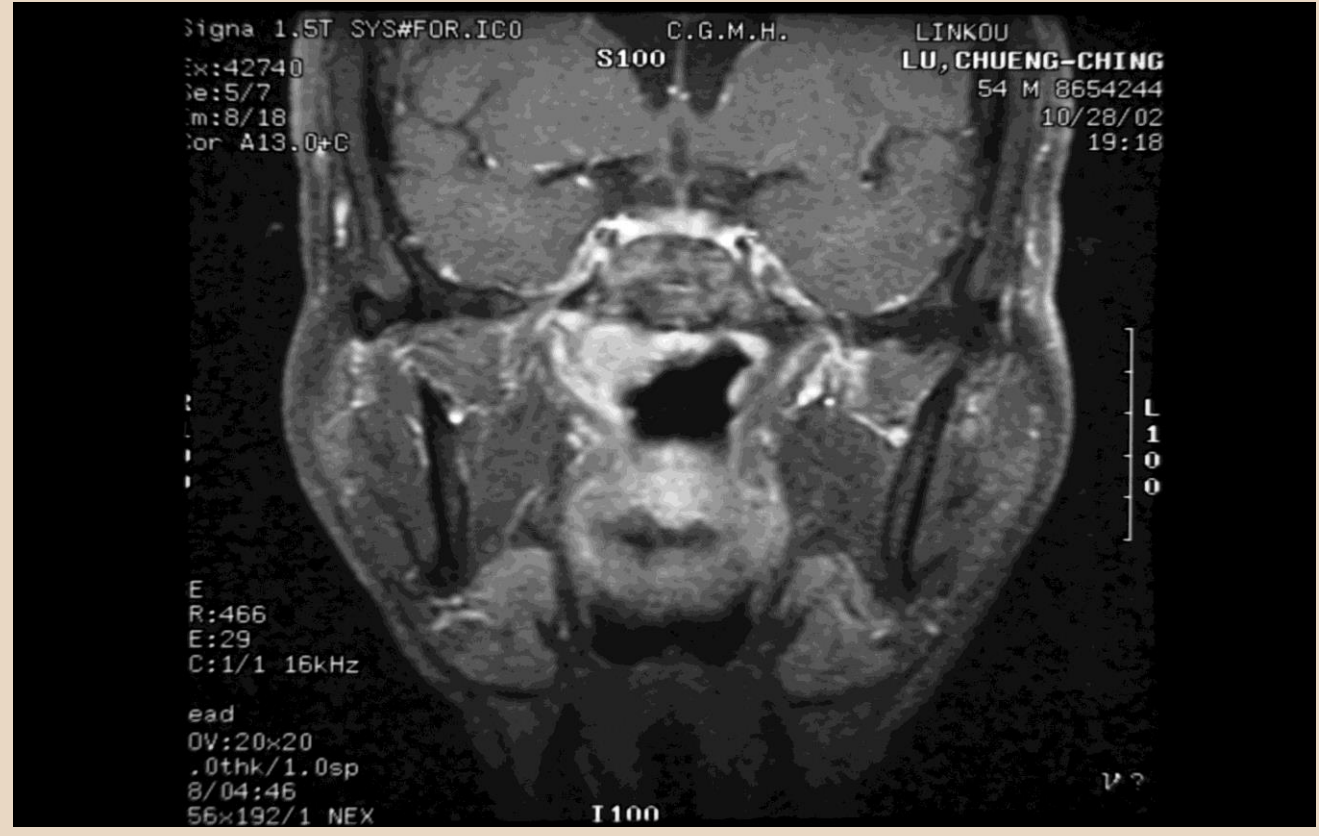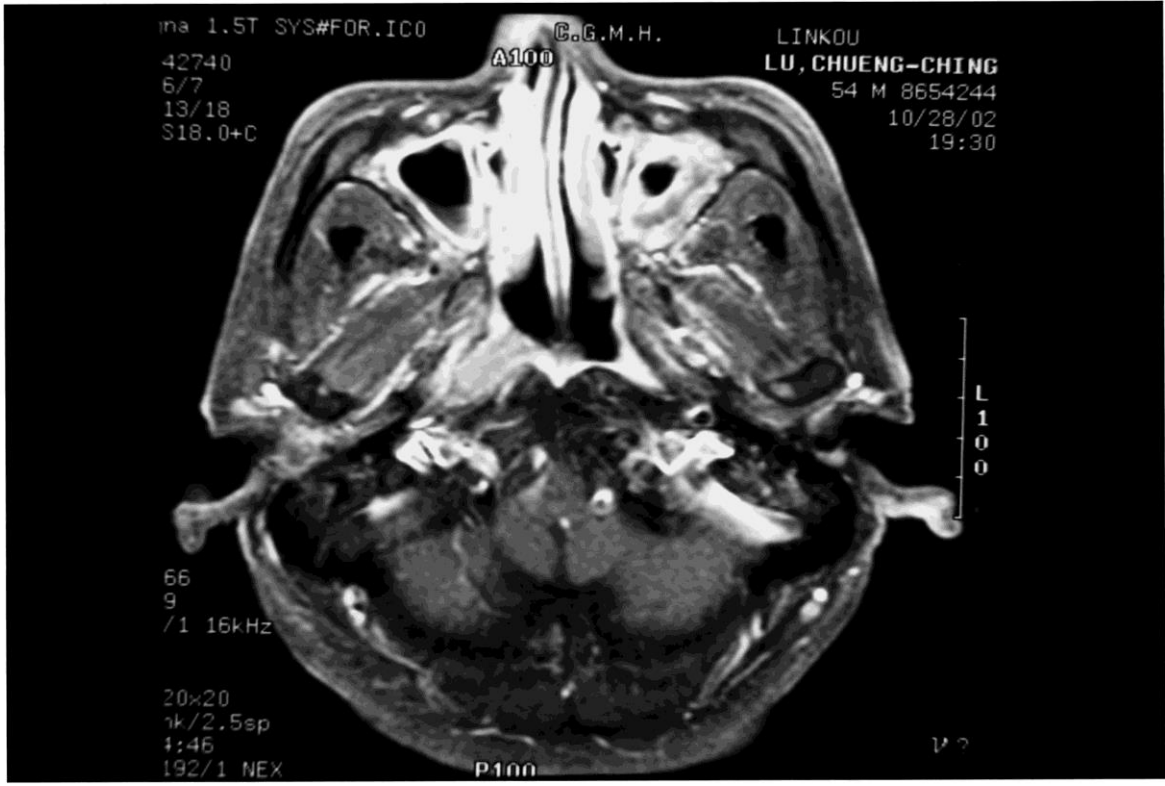- Significantly increase the viability of FBG, especially RT
- *Not* hinder the detection of early recurrence
- Easy develop and transfer

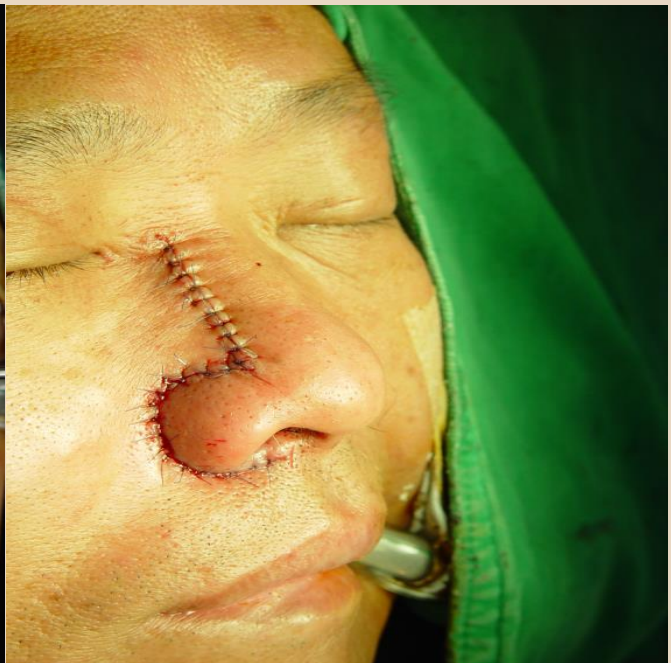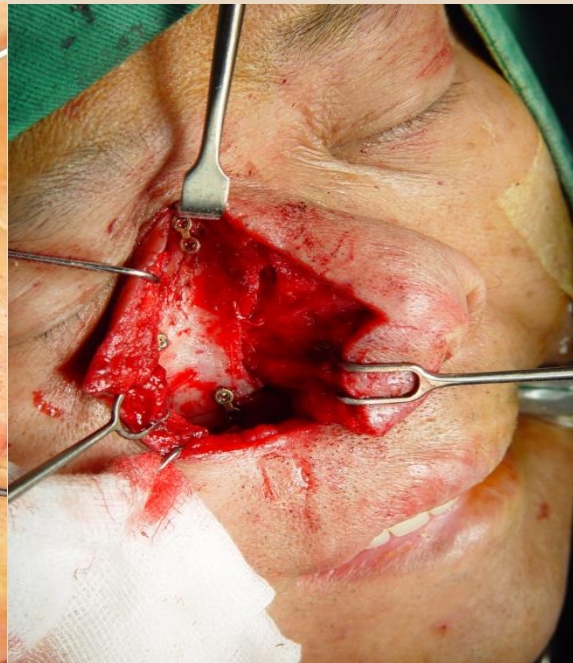
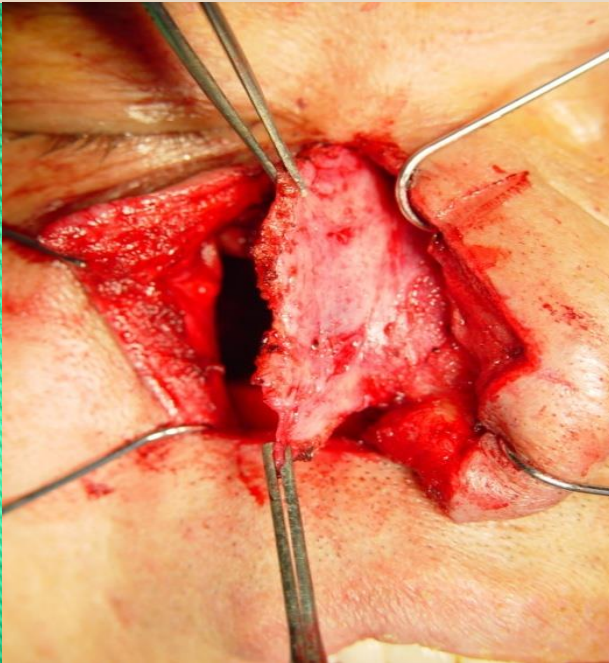
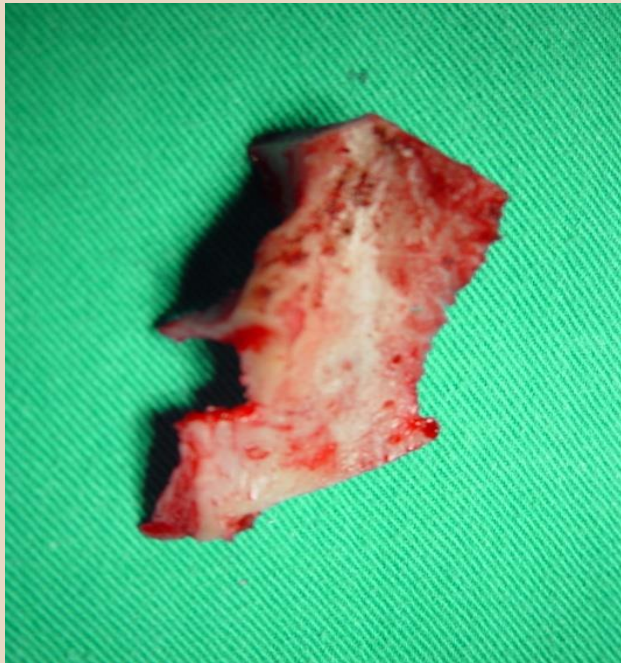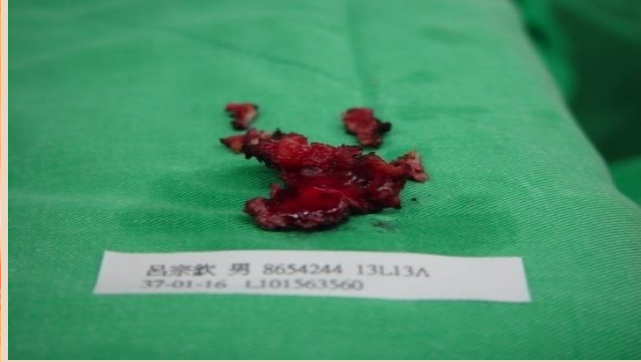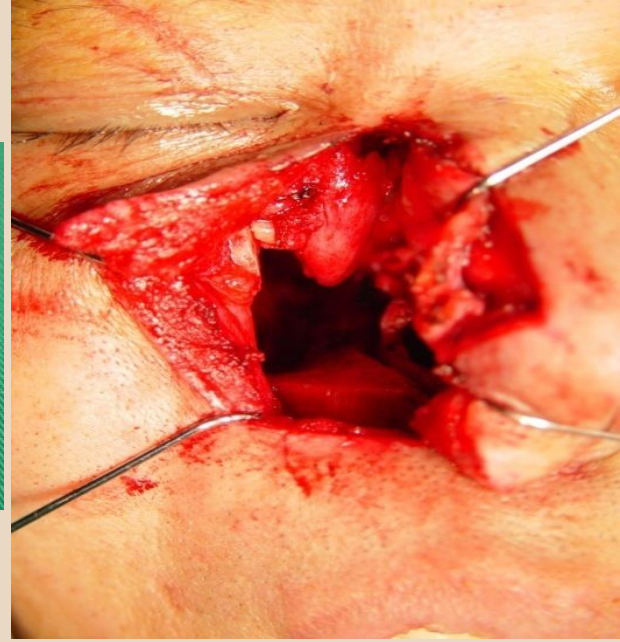
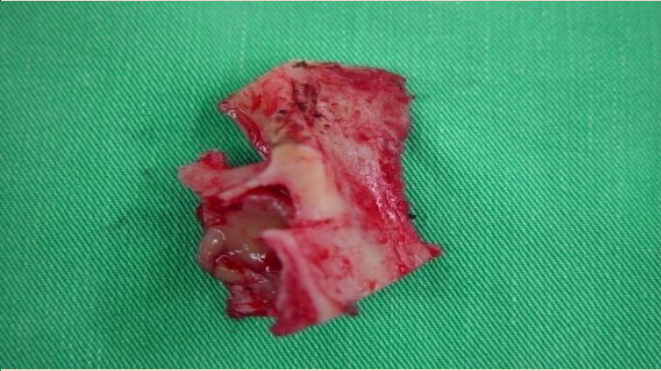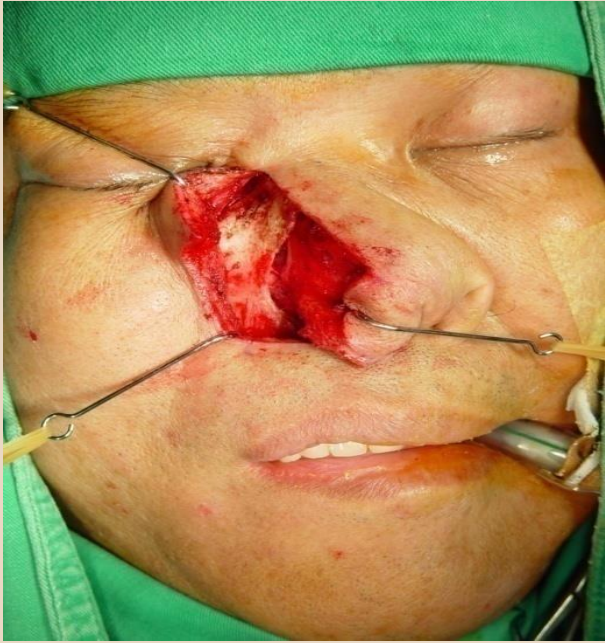
## Modified Facial Translocation Technique to Prevent Necrosis of Bone Graft

---

Sheng-Po Hao, MD





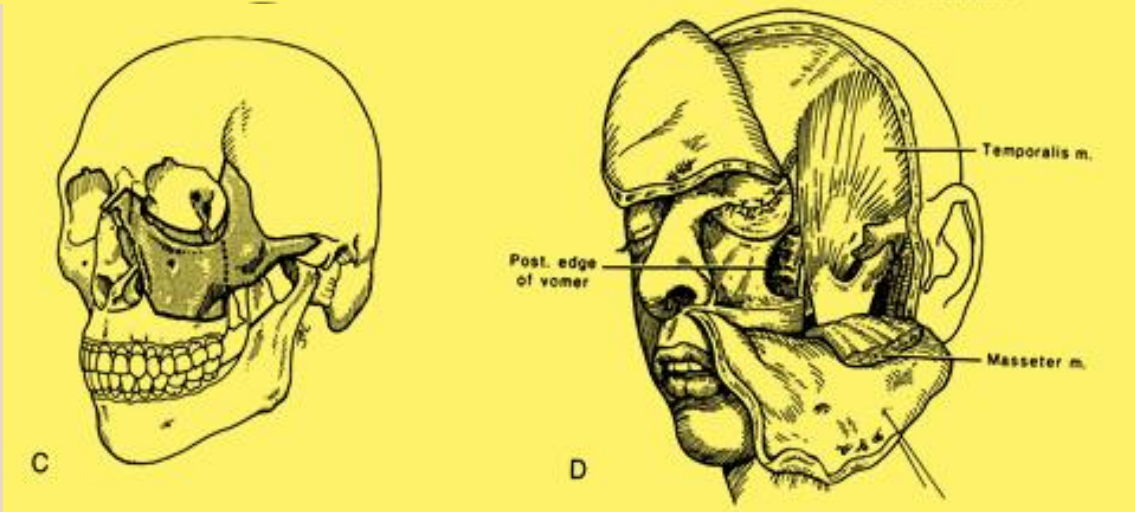
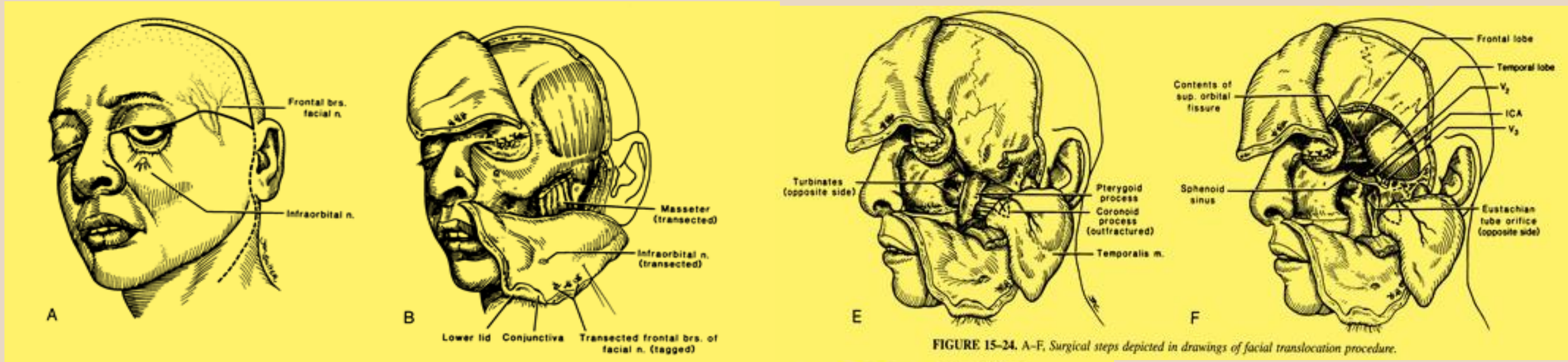




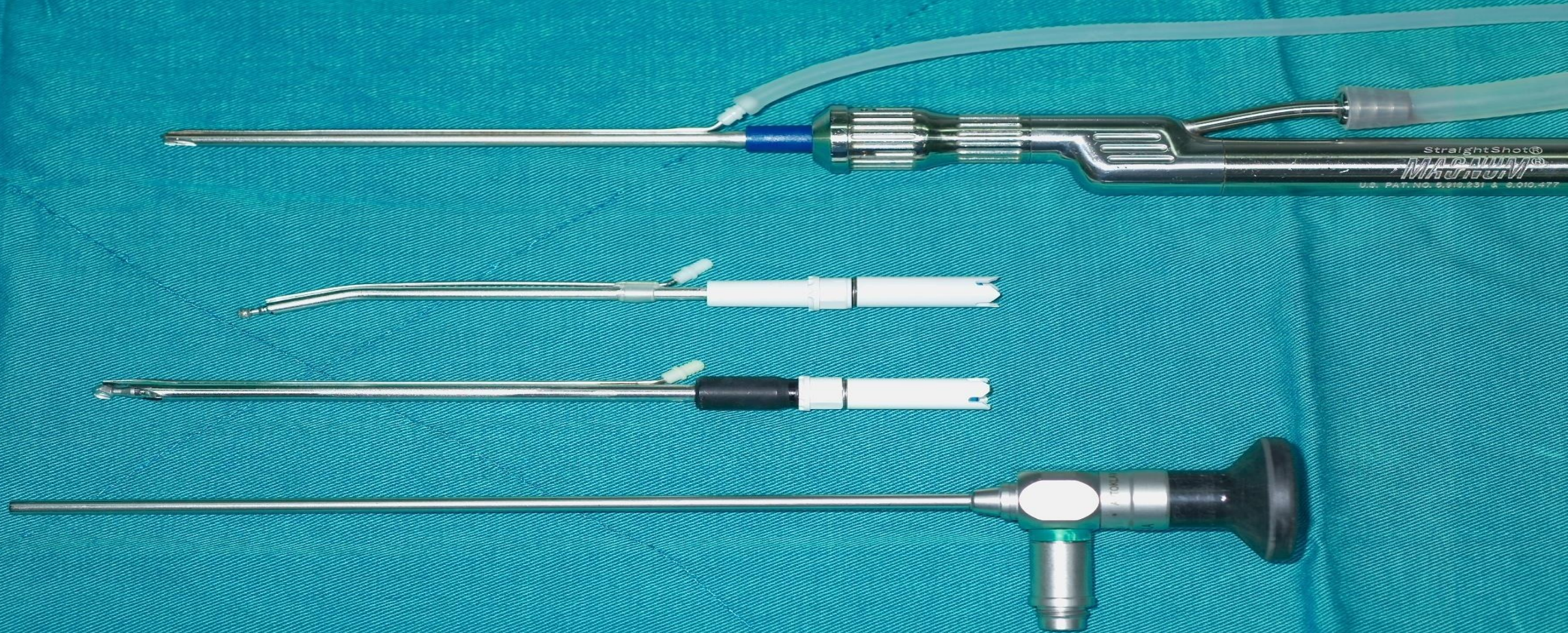
# Modified Facial Translocation

VEDIO

# CranioFacial Resection –

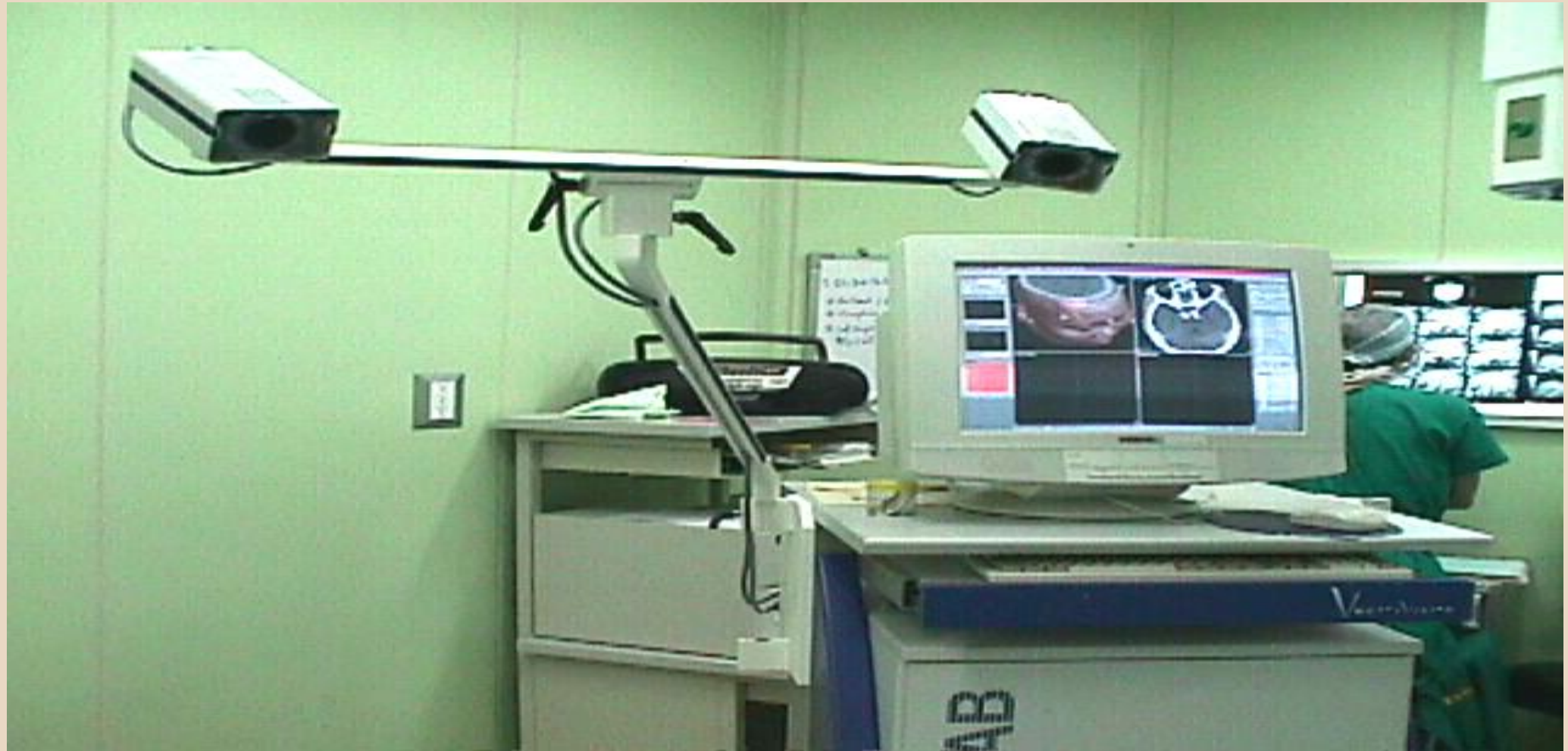

# Powerful Instrument

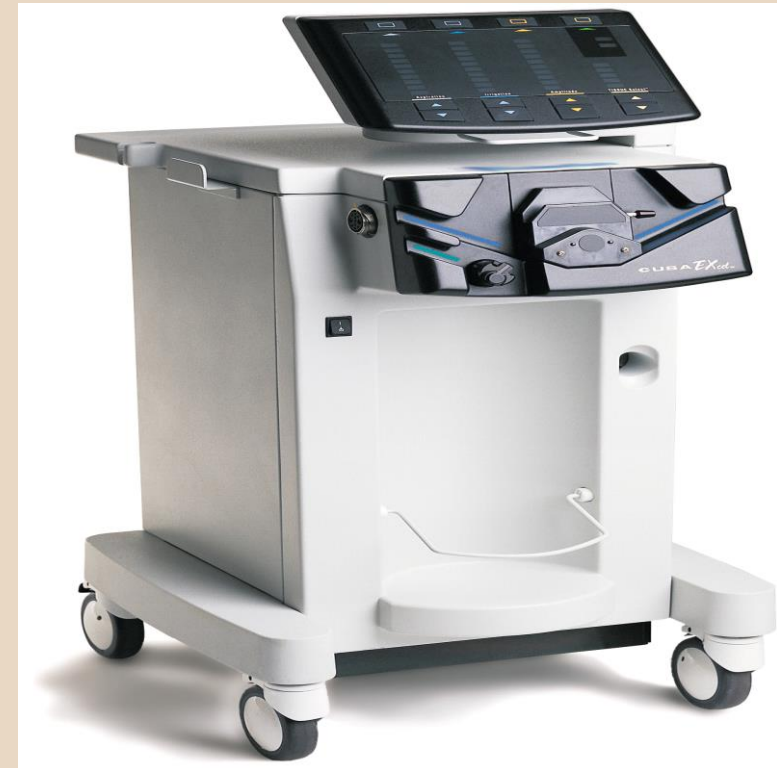
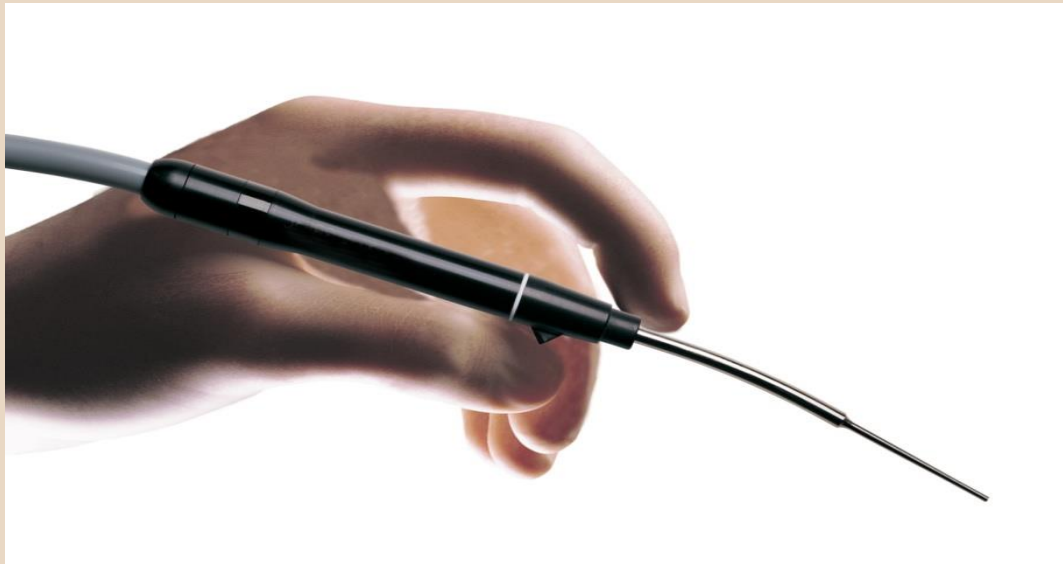


# Navigation



# CUSA Excel



# Cavitron Ultrasonic Surgical Aspirator (CUSA)

- Cavitation is defined as the process of formation of the **vapour phase of a liquid** when it is subjected to reduced pressures at constant ambient temperature.
- The cavitron ultrasonic surgical aspirator (CUSA) device generates ultrasonic waves in the range of 23 kHz to produce **tissue cavitations**.
- When the vibrating tip contactstissue, it breaks cells apart (fragmentation).

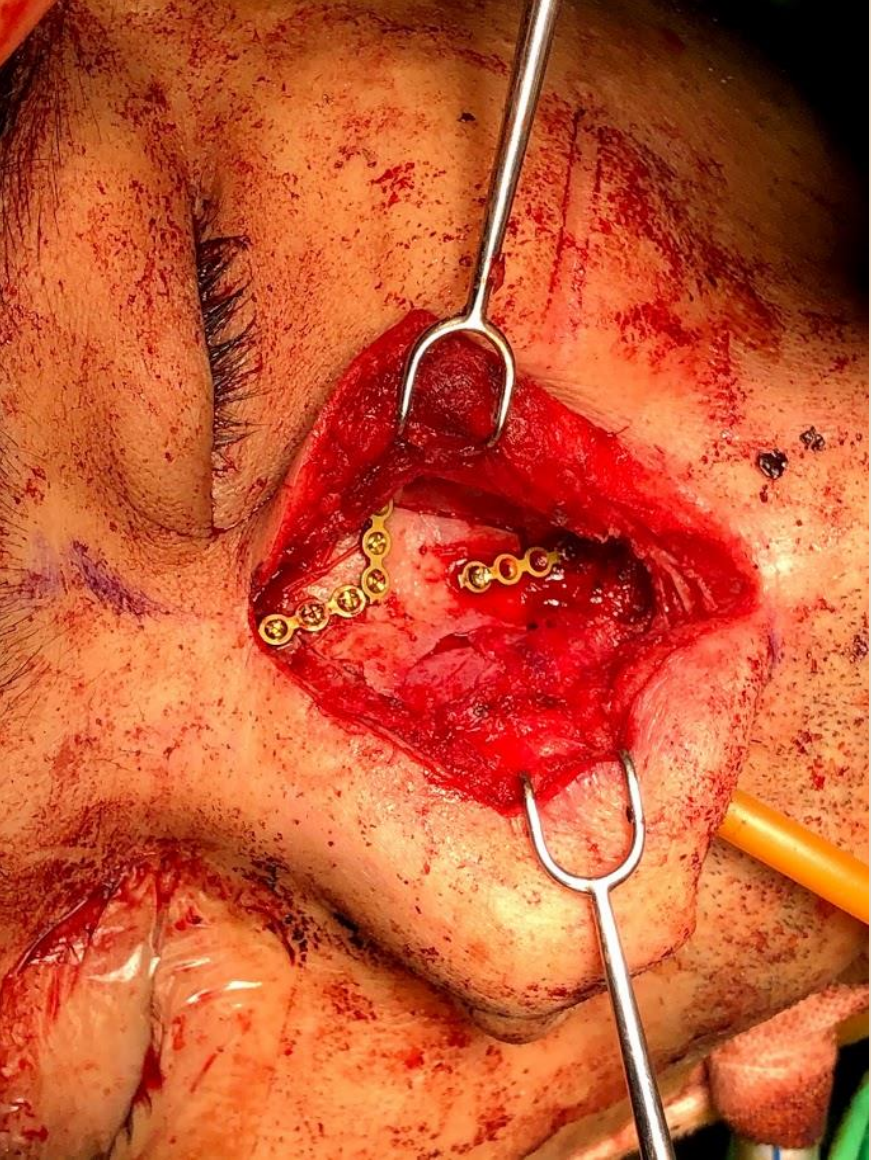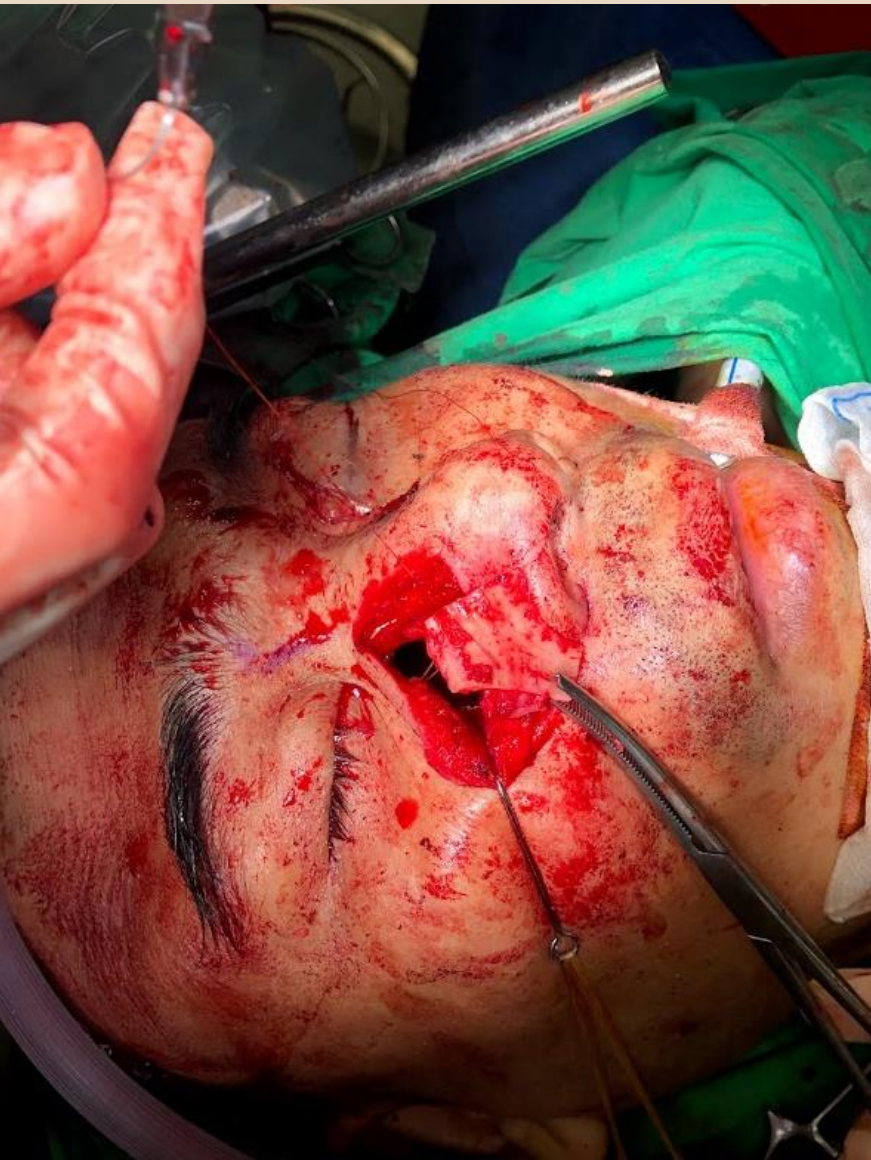# Oncology Principles

Negative surgical margins

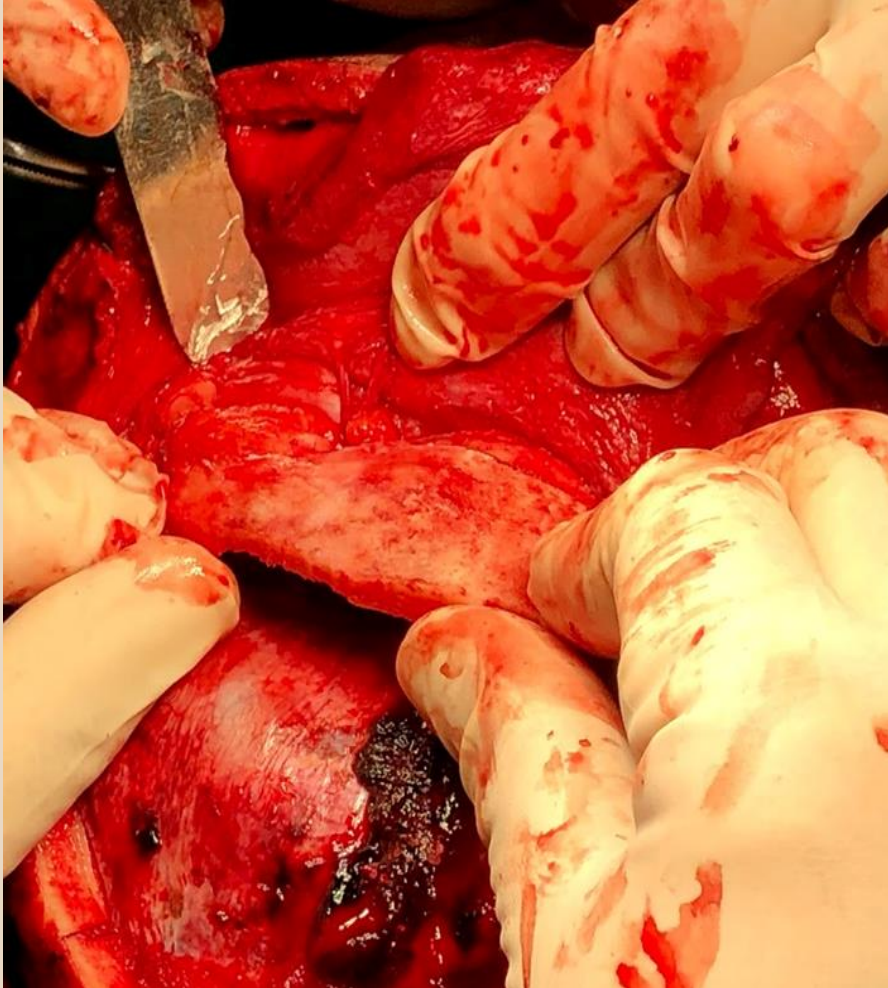
# Reconstruction

- Complete elimination of free communication by flaps or grafts
- Avoid CSF leak: watertight dura closure
- Rigid bony fixation: plate better than wire

# Reconstruction – modified facial translocation



# Reconstruction: Galeopericranial Flap



- Preserved **supraorbital** and **supratrochlear** arteries and veins
- 10 cm from eyebrow: long enough
- **Galeopericranial flap** was turned inwards above the supraorbital ridge, below and fixed to the exposed dura
- Leave enough room for the flap to pass through, to ensure a proper blood supply

# Galeopericranial Flap

- Advantage:

The galeopericranial flap is strong enough to support the intracranial content and is **a reliable barrier for a skull base defect**, even if postoperative radiotherapy is used

- Disadvantage:

- too large of a defect that includes the bilateral orbits or which extends beyond the posterior wall of the sphenoid sinus
- those who have received previous radiotherapy or surgery
- cases in which a great bulk is needed



# Pericranial flaps vs Galeopericranial flap

Authors	Pericranial flap	Galeopericranial flap
Noone et al. <sup>(2)</sup>	Less risk of hair loss, forehead paralysis, or paresthesia; bony irregularities	Thicker; superior vascular supply
Tse et al. <sup>(11)</sup>	Thinner and more suitable while larger arc of rotation required	Difficult dissection in adhesions between subcutaneous tissue and the galea
Georantopoulou et al. <sup>(20)</sup>	Thinner	Thicker but still pliable; visible forehead irregularities
Har-Shai et al. <sup>(22)</sup>	Easy separation between the galea and periosteum due to the absence of fibrotic vertical bands in the subgaleal layer	Technical difficulty in finding a subfollicular dissection

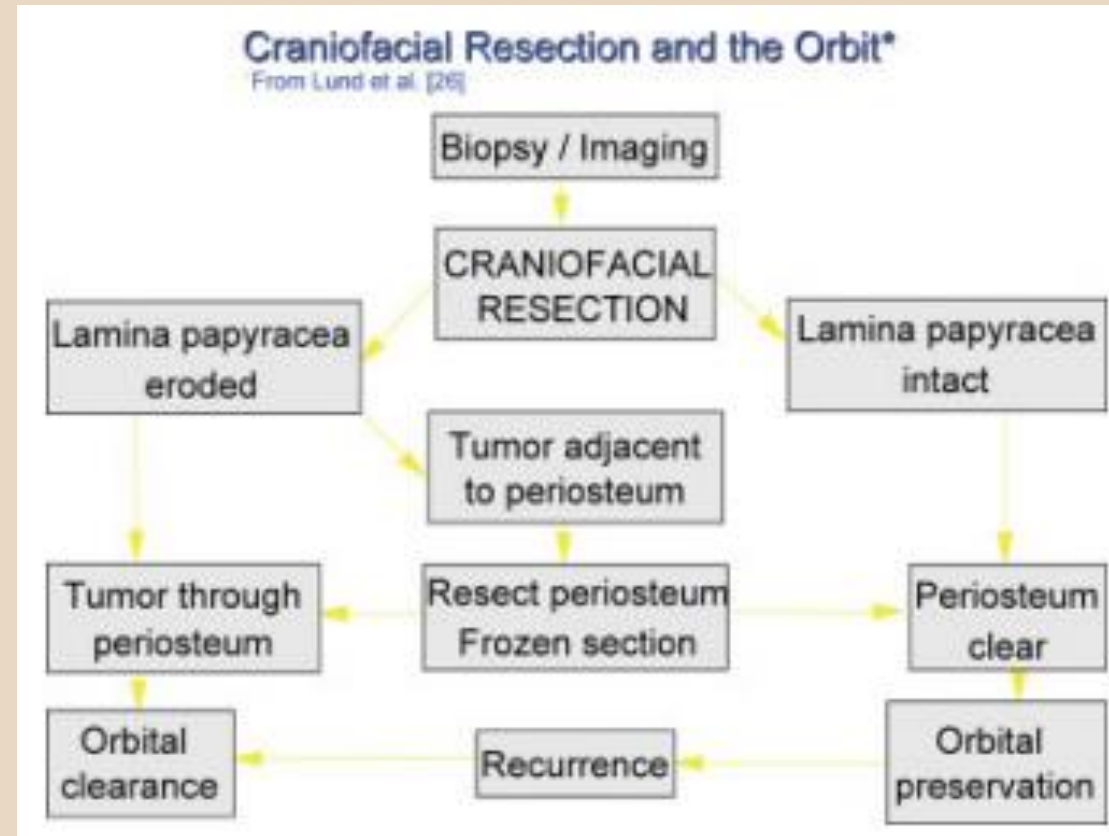
# Skull-base Tumors Invading the Orbit

- **Orbital invasion** can be defined in different ways.
  - Some include tumors adjacent to the orbit without bone erosion
  - others take erosion of the bone as proof of invasion
- **Surgery** alone or combined with either **postoperative or preoperative radiation therapy** is the mainstay of treatment of tumors with orbital invasion
- The choice of therapy depends on the aggressiveness, grade of invasion and pathology of the tumor

# Skull-base Tumors Invading the Orbit

## *Surgery*

- Different indications for **orbital exenteration** have been proposed in the literature.
- Most authors agree on resection of the mass without orbital exenteration when invasion is limited to the bone or periosteum.
- When invasion includes **periorbital tissue, orbital fat, extraocular muscles, or orbital apex**, most authors agree on **orbital exenteration**



# Skull-base Tumors Invading the Orbit

## *Radiation therapy*

- Radiation therapy is more commonly used in the treatment of **epithelial malignancies and neuroendocrine tumors** than in the treatment of bone and cartilage malignancies
- The doses have varied from **50 to 70 Gy** given over a period of five to six weeks
- **Conventional radiation therapy** may lead to **blindness** via **retinopathy** or **optic neuropathy**
- The use of **IMRT (Intensity-modulated radiotherapy)** reduces the incidence of radiation-induced blindness, severe dry eye syndromes, and increases survival compared to conventional radiation

# Skull-base Tumors Invading the Orbit

## *Chemotherapy*

- Chemotherapy is **not a first line treatment** in most sinonasal or skull-based tumors
- Chemotherapy is used in the treatment of **aggressive tumors or in palliation therapy**
- Among the most common regimes in the treatment of sinonasal tumors included **etoposide** and **cisplatin**.
  - Other regimes included vincristine, ifosfamide, doxorubicin or 5-fluorouracil

# **Craniofacial Resection** *surgical procedure*

- Transbasal resection- frontal craniotomy & orbital bar
- Orbital capsule removal
- Optic nerve decompression- CUSA
- Dura & brain resection
- Main tumor resection: Modified en-bloc resection, Piecemeal
- Dura repair- pericranium
- Galeopericranial flap reconstruction
- Bone graft fixation

# Clinical Case of Craniofacial resection

2019.10

- **Final Pathology:**

- **Carcinoma with bony invasion**

- Left frontal sinus", multiple sinusectomy

- Left **orbital wall**", resection

- **Inverted papilloma with malignant transformation**

(invasive squamous cell carcinoma)

- **Dura**, excisional biopsy

- Tumor in left frontal sinus", tumor excision and sinusectomy

# Prognosis

- According to a International Collaborative study of 334 patients / 17 institutions
  - CFR for malignant paranasal sinus tumors is a safe surgical treatment with an overall **mortality of 4.5%** and **complication rate of 33%**
  - The **5-year overall, disease-specific, and recurrence-free survival rates** were 48.3%, 53.3%, and 45.8% respectively
- The status of **surgical margins**, **histologic findings** of the primary tumor, and **intracranial extent** were independent predictors of overall, disease-specific, and recurrence-free survival on multivariate analysis.



# Complication

- The reported incidence of complications from anterior skull base surgery ranges from 6.5% to 23.5%.
- The **most-common one is CSF leakage**, which may increase the risk of **ascending meningitis**
- Key point:
  - to avoid direct communication between the sterile neurocranium and underlying dirty upper aerodigestive tract**
  - Dura **watertight** repair
  - Selection of a **strong, reliable barrier** for isolating the sterile cavity is critical

# Complication

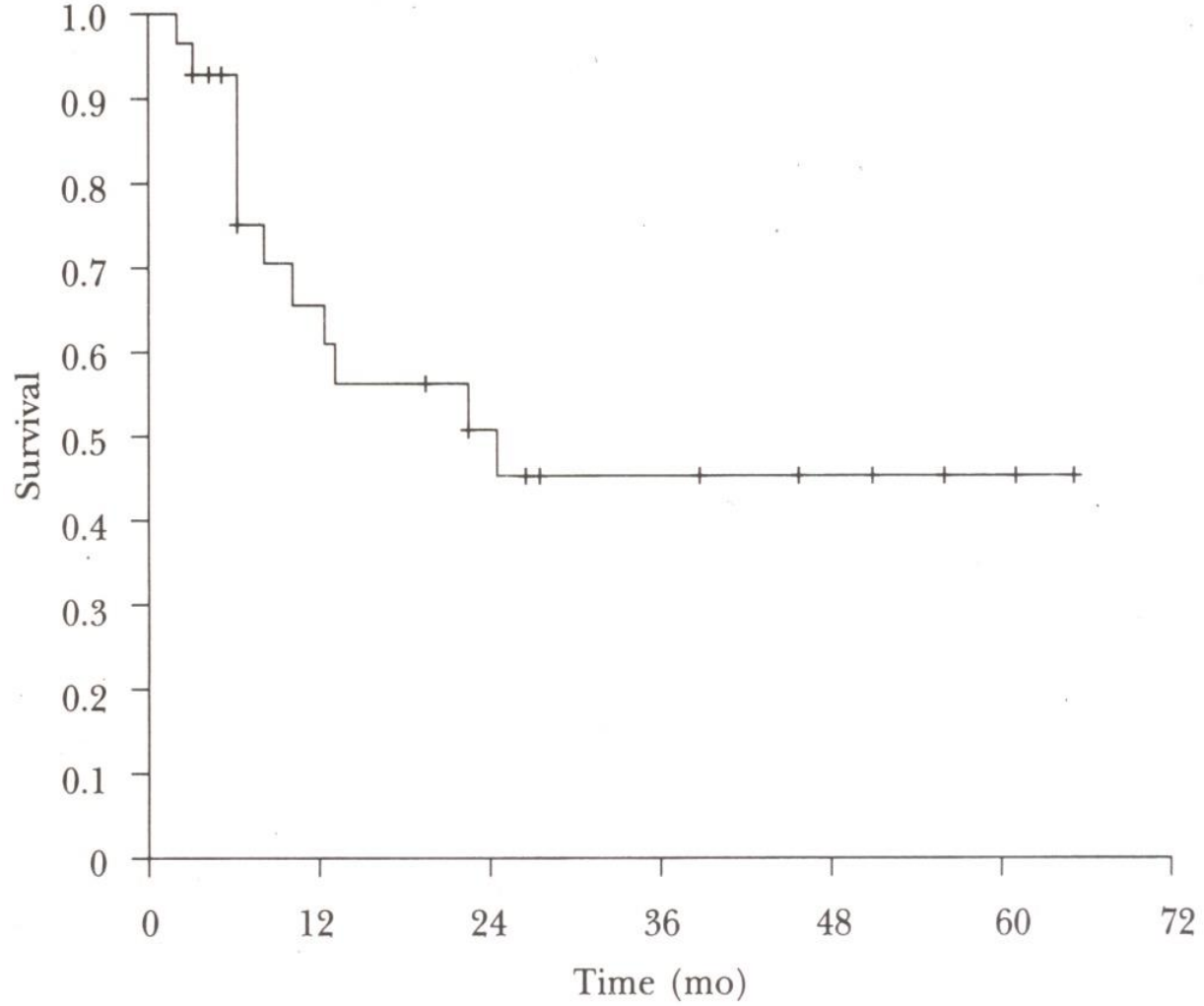
- Common complications of **anterior cranial base surgery** mainly occur due to **direct communication between the cranial cavity and the underlying respiratory tract**, and may result in
  - cerebrospinal fluid (CSF) leakage
  - meningitis
  - encephalitis
  - an epidural or subdural abscess
  - osteomyelitis of the skull
  - a hematoma
  - pneumocephalus
  - meningoencephalocele

# Complication

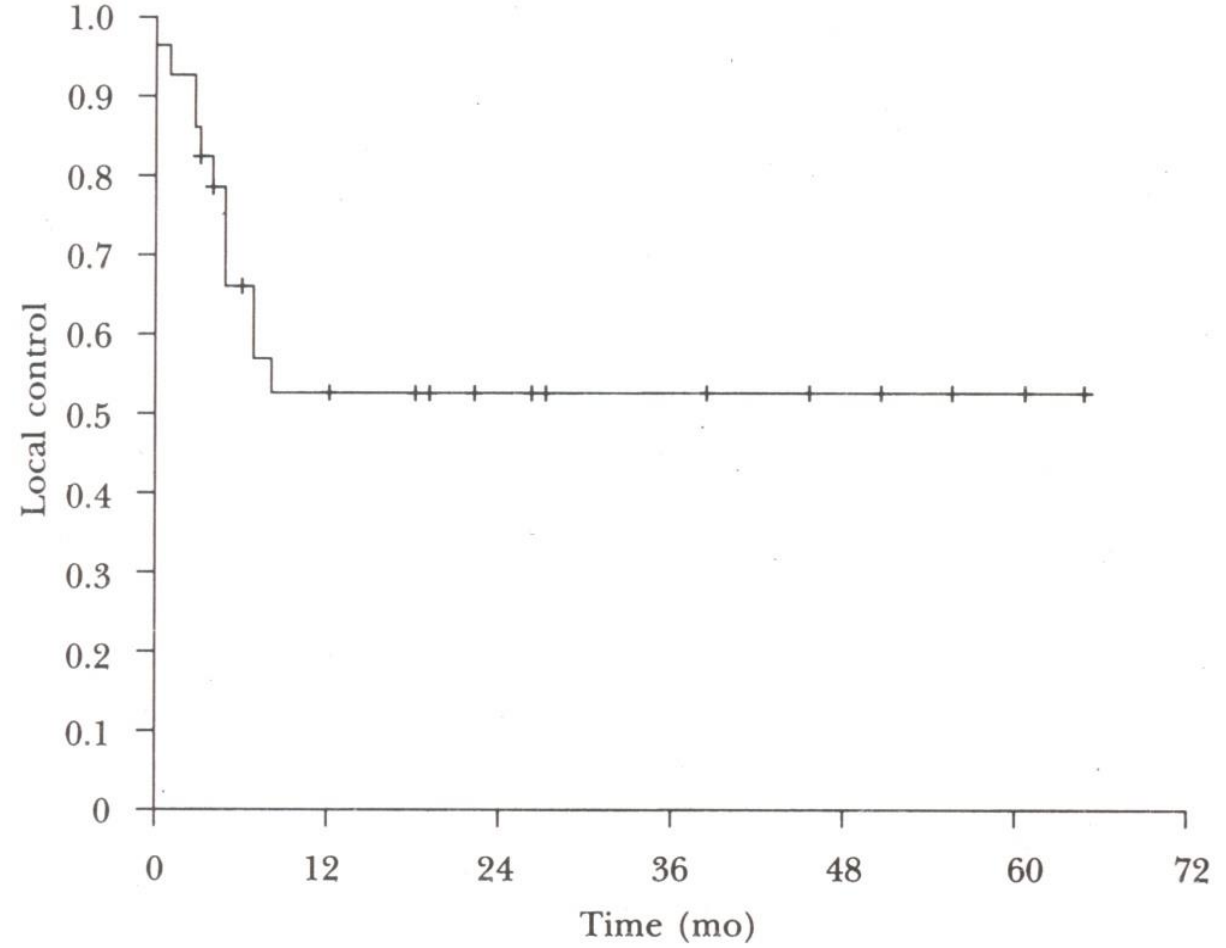
- According to a International Collaborative study of 1193 patients from 17 institutions .
  - Postoperative complications occurred in 433 patients (36.3%).
  - Wound complications occurred in 237 (19.8%)
  - CNS-related complications in 193 (16.2%)
  - orbital complications in 20 (1.7%)
  - systemic complications in 57 (4.8%) patients
- **Medical comorbidity, prior radiation therapy, and the extent of intracranial tumour involvement** were independent predictors of postoperative complications.

# Lumbar drain

- Patients who suffer from coughing or gagging during emergence from anesthesia, obstructive sleep apnea, morbid obesity, excessive nose blowing cause elevated CSF pressure that also **increase the risk of CSF leak**
- One helpful adjunct in patients who are at risk for CSF leak it to place a **subarachnoid lumbar drain** to allow CSF diversion, lower intracranial pressures and allow healing of the nasal flap
  - **Overdrainage should be avoided** because this creates a negative intracranial pressure that may result in pneumocephalus and promote bacterial contamination of the CSF with resultant meningitis



**Fig. 1.** *Survival among 28 patients with malignant tumors.*



**Fig. 2.** *Local control among 28 patients with malignant tumors.*

**Endoscopic approach**

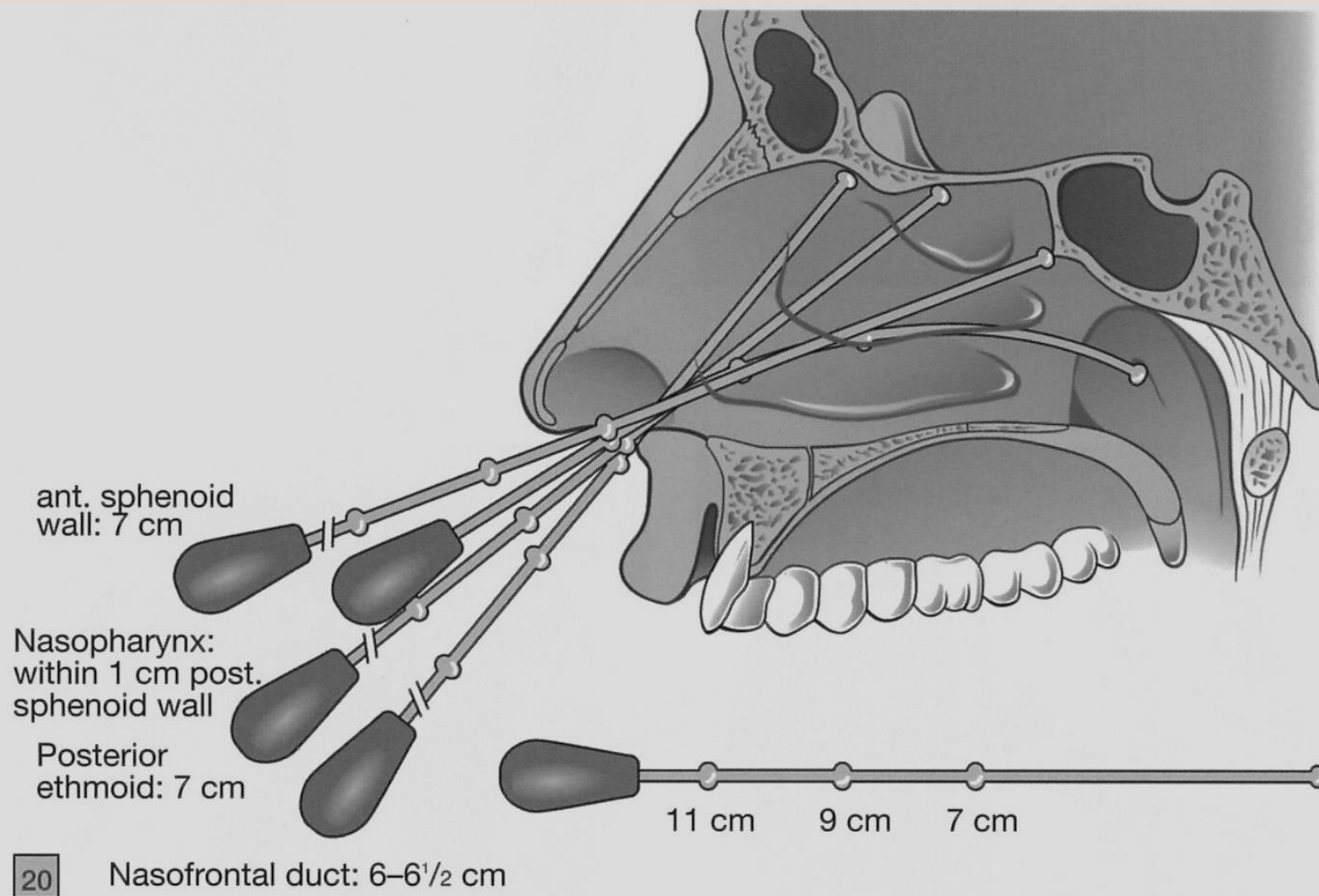
# **Changing Paradigm in Skull Base Surgery**

*from Open to Endoscopic*

Open approaches, including craniotomy, facial translocation, etc, are always a much more involved approach which often carries more morbidity and psychological stress than the endoscopic approach.



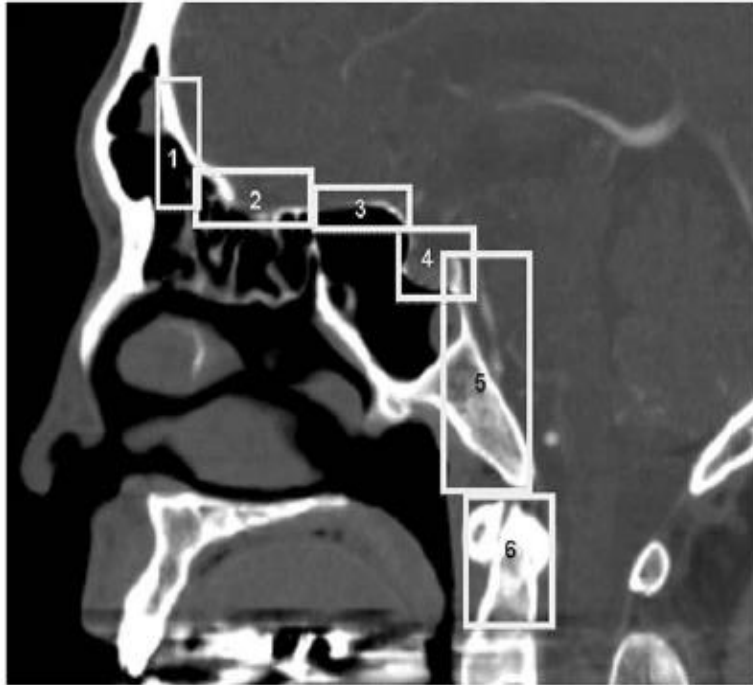
# Endoscopic approach



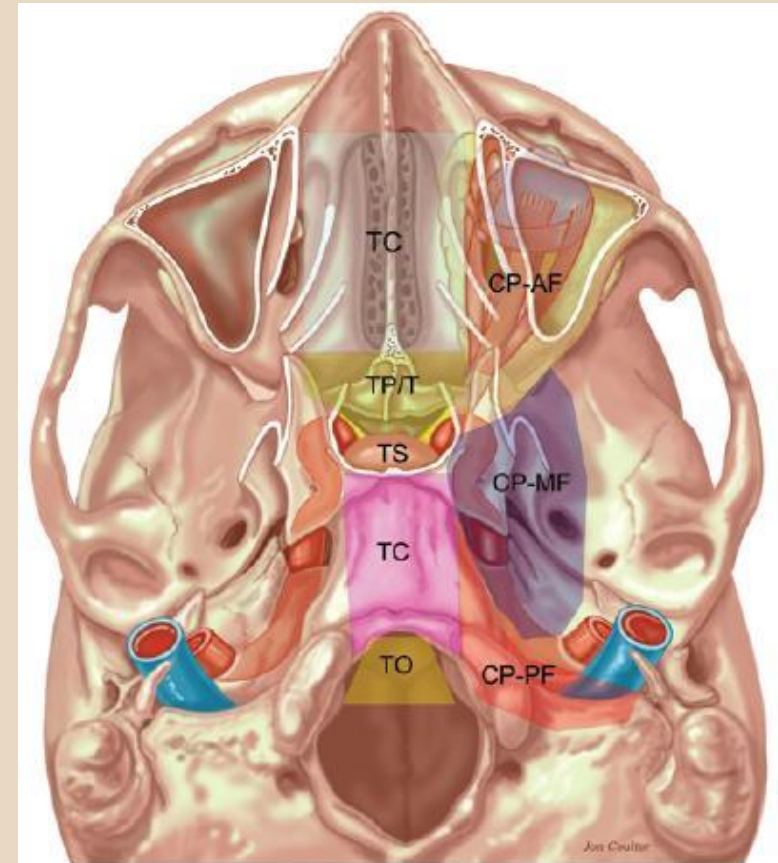
Checking the depth of the surgical field.

Open approaches are always a much more involved approach which often carries more morbidity and psychological stress than the endoscopic approach.

# Anatomy



**Fig. 1** Schematic depiction of the sagittal plane module on a computed-tomography (CT) scan of the skull base. The various endonasal surgical approaches are numbered as follows; (1) transfrontal (2) transcribriform, (3) transplanum, (4) transsphenoid, (5) transclival and (6) transodontoid.



**FIG. 1.** Illustration showing the skull base in an inferior view. Each colored area represents a module of expanded endonasal approach at the skull base. CP-AF = coronal plane anterior fossa; CP-MF = coronal plane middle fossa; CP-PF = coronal plane posterior fossa; TC = transclival (pink area); TC = transcribriform (white area); TO = transodontoid; TP/T = transplanum/transsterculum; TS = transsellar.

# Endoscopic

- Mini-invasive
- Powerful instrument
- Navigation
- Bioglue

# Endoscopic Skull Base Surgery

- Approach
- Resection
- Reconstruction

# Endoscopic Approach

- Limited skull base invasion
- Endoscopic duroplasty
- En bloc resection?
- Repair large dural defect?
- Manage intracranial or intradural complications?
- **Learning curve**

# Conceptual Change

- Resection:  
En bloc vs Piecemeal
- ”central debulking”

# Concept

The only thing changed in endoscopic resection is the way to remove the tumor, nevertheless, the extent of resection and the control of surgical margin remain exactly the same with the open method.

# Endoscopic approach - Navigation





# Endoscopic approach - Navigation

- Indication

- Revision procedures
- Massive polyposis
- Endoscopic tumor resection
- Endoscopic skull base surgery

# Image – guided Systems (Indication)

- Revision procedures
- Massive polyposis
- Endoscopic tumor resection
- Endoscopic skull base surgery

Although it is a useful adjunct, image guided navigation is not a substitute for good anatomic knowledge or surgical skill.

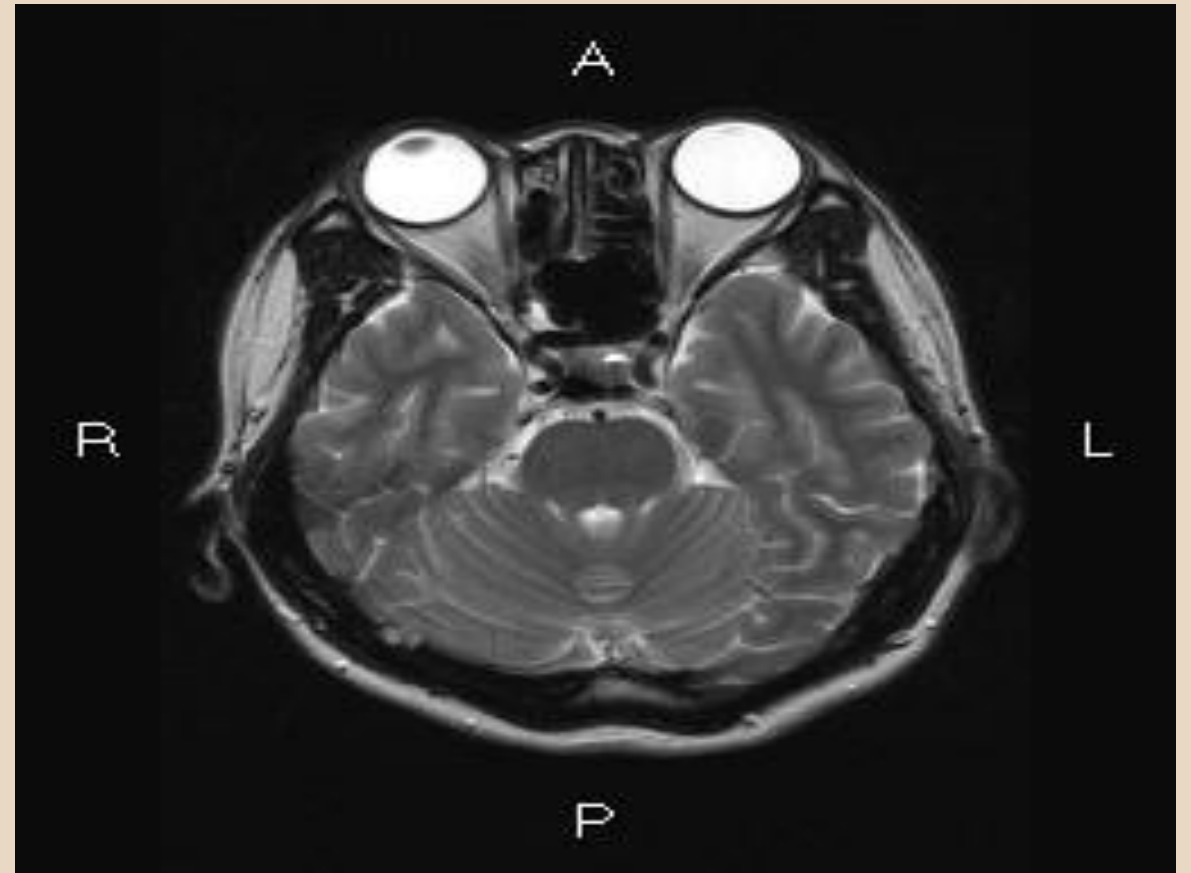
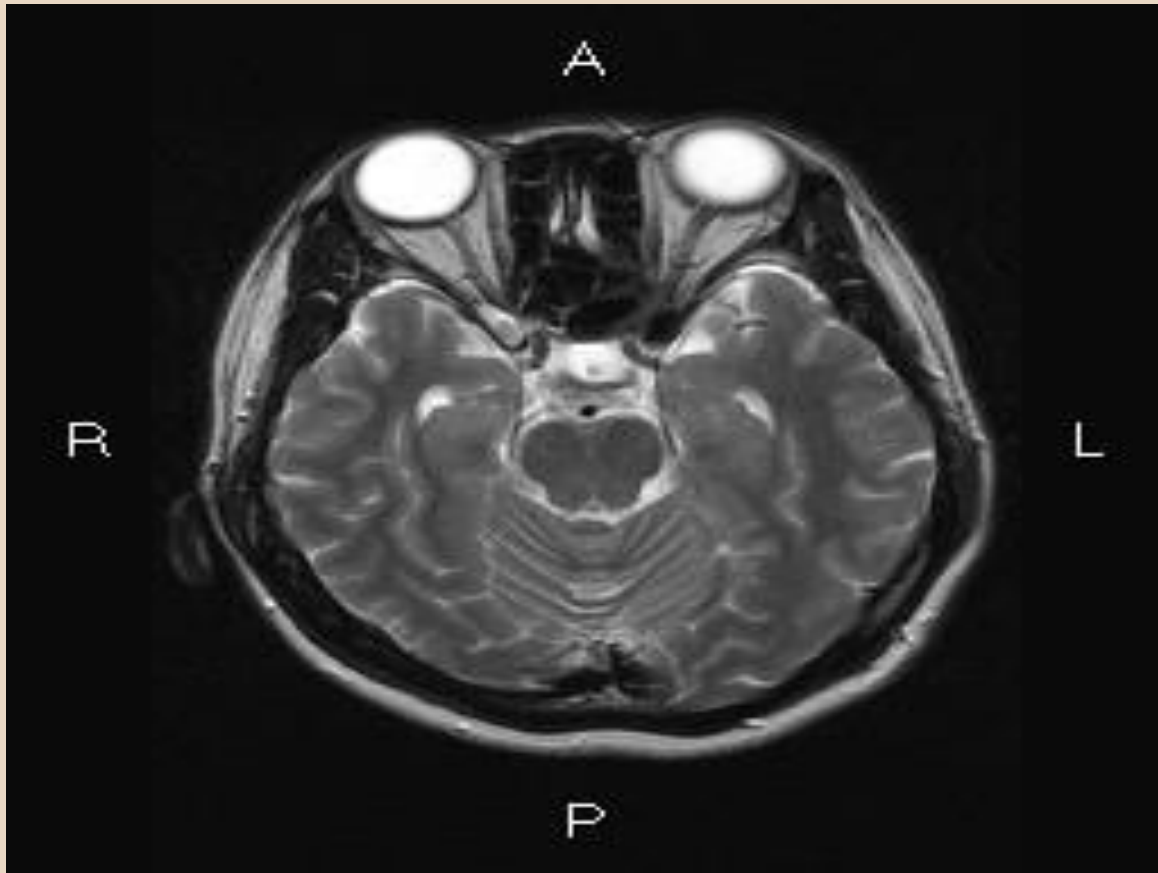
# Oncology Principles

The only thing changed in endoscopic resection is the way to remove the tumor, nevertheless, the extent of resection and the control of surgical margin remain exactly the same with the open method.

# Case Presentation

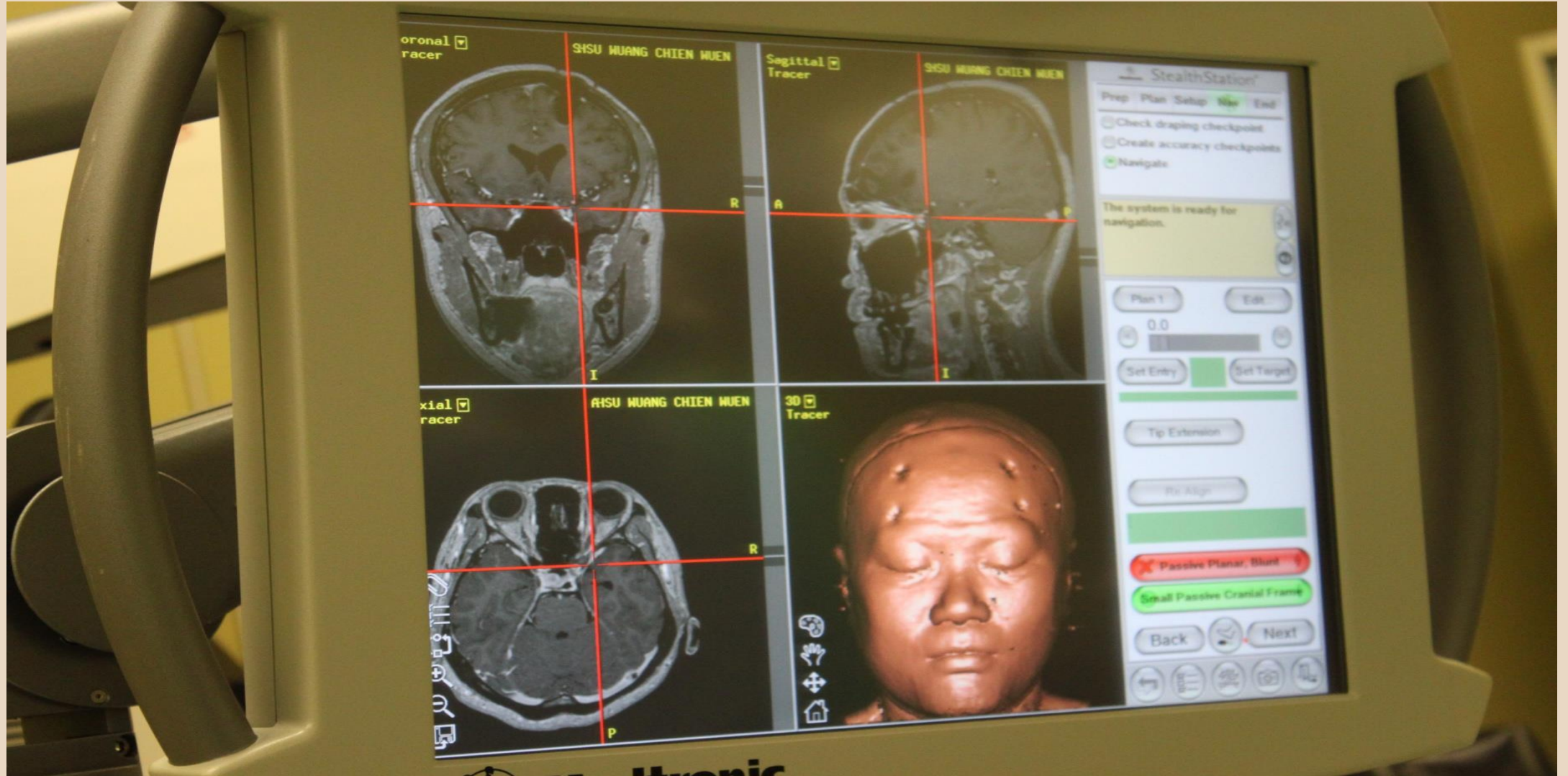- 許王x文 30 Y/O F (16539731)
- Chief complaint
  - right visual field defect noted for 3 months
- Diagnosis
  - orbital meningioma s/p outside 2006
  - s/p endoscopic duroplasty in CGMH 2009
  - orbital cone mucocele 2011.6

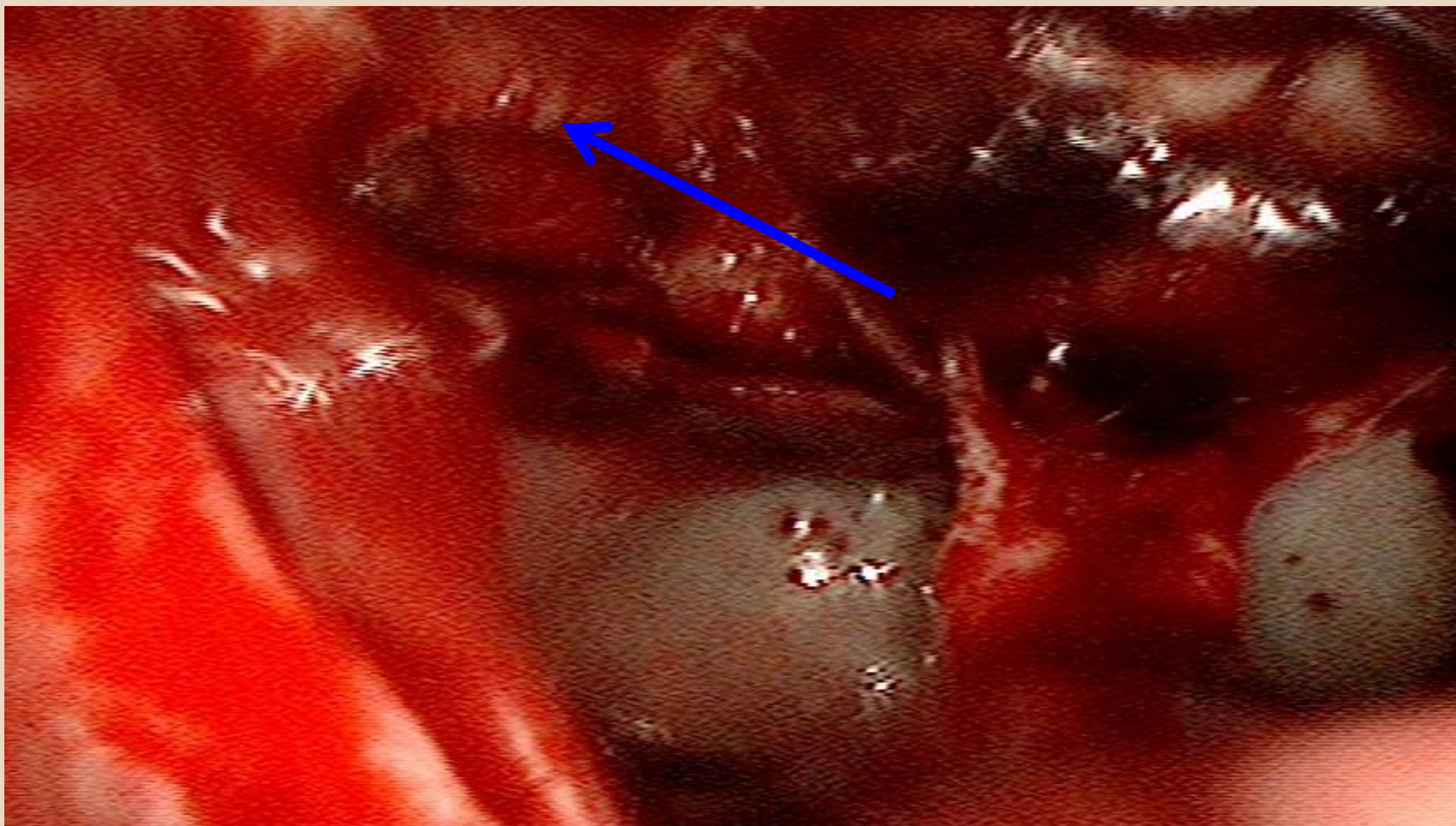
# 6/15 Head Neck MRI



r/o right orbital cone lesion

# Navigation-guided Endoscopic Decompression

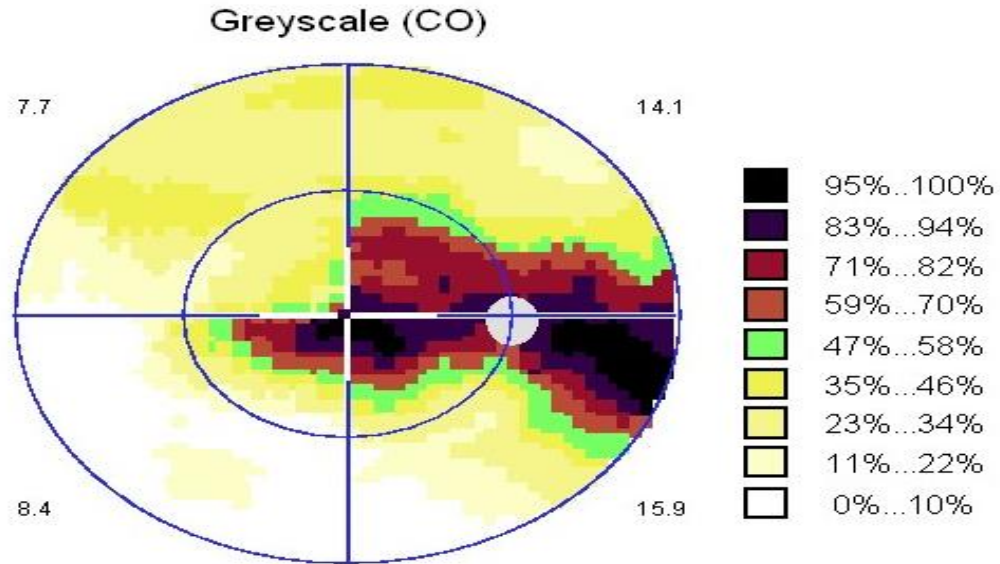




Optic n. Decompressed

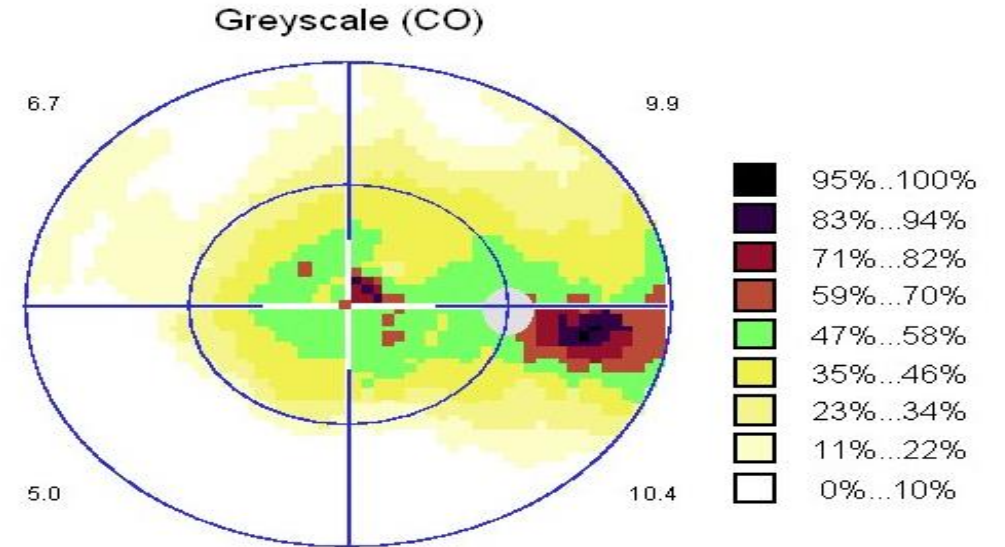
# Visual Field Examination

OD / 04/01/2011 / 14:36:49  
Seven-in-One



Pre-Op: Central to temporal side  
scotoma

OD / 06/16/2011 / 15:14:52  
Seven-in-One



Post-Op: Scotoma improved, Zone of  
absolute defect ↓↓



# Challenges, Endoscopic Approach

- Two surgeons, four hands technique
- Justified for malignancy?
- CSF leak management?
- Still evolving, indication, technique, instrument

# CSF leak management

- Interposition technique
- Tuck & tempon
- Rotational flap

# Interposition Technique~ *above skull Base*

Transnasal Endoscopic Repair of Cerebrospinal Fluid Rhinorrhea: An Interposition Technique

Laryngoscope 1996;106:501-503 Sheng-Po Hao MD, FACS, FICS

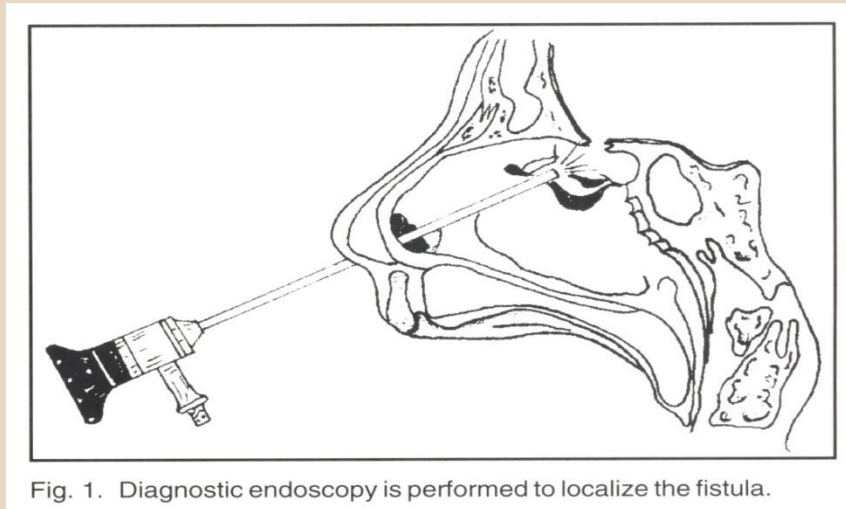


Fig. 1. Diagnostic endoscopy is performed to localize the fistula.

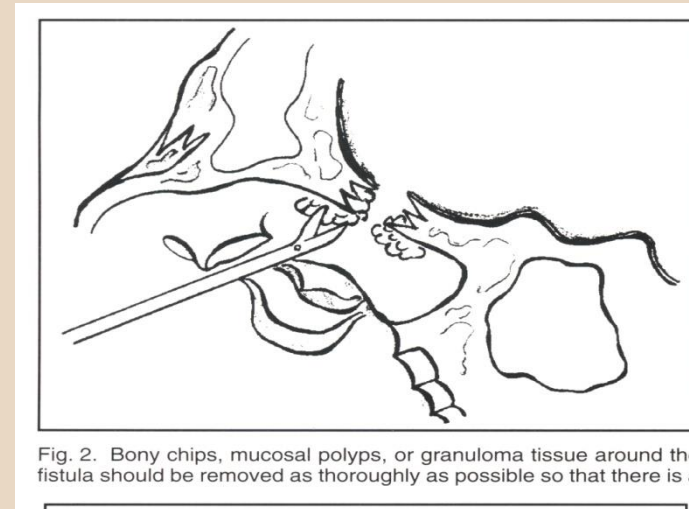


Fig. 2. Bony chips, mucosal polyps, or granuloma tissue around the fistula should be removed as thoroughly as possible so that there is a

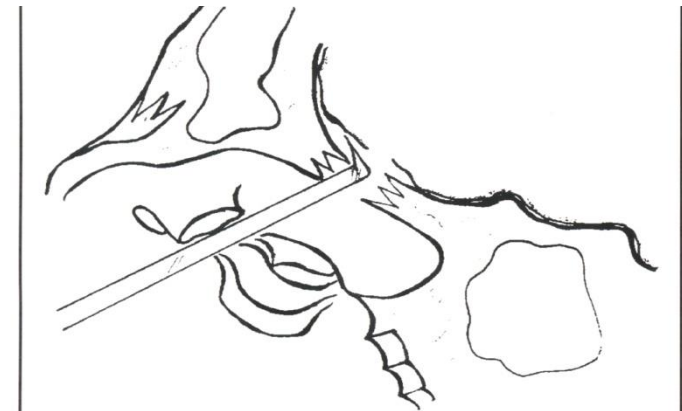


Fig. 3. The dura surrounding the bony defect is elevated off the skull with a neuro-otologic elevator, thus creating an epidural space.


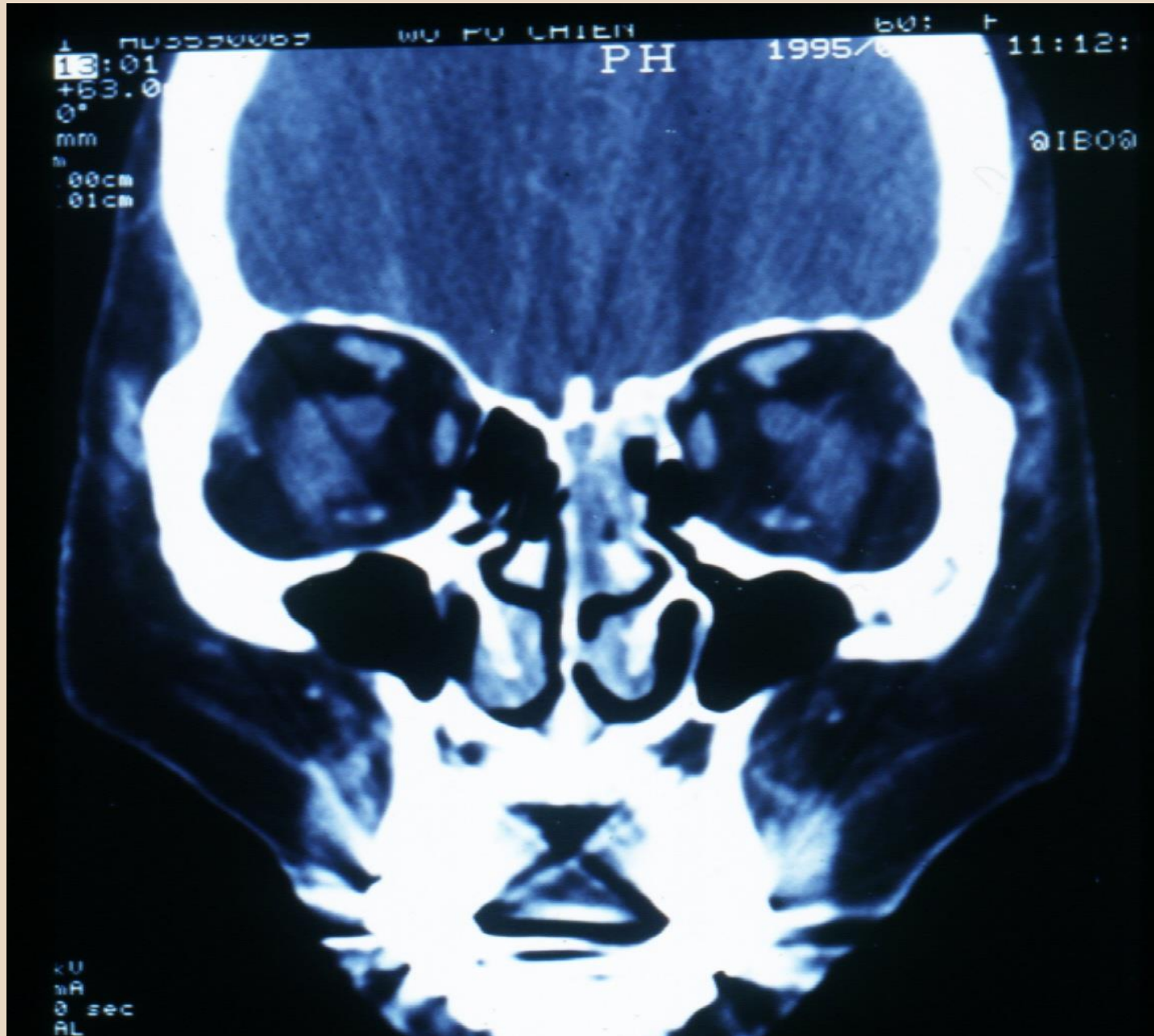
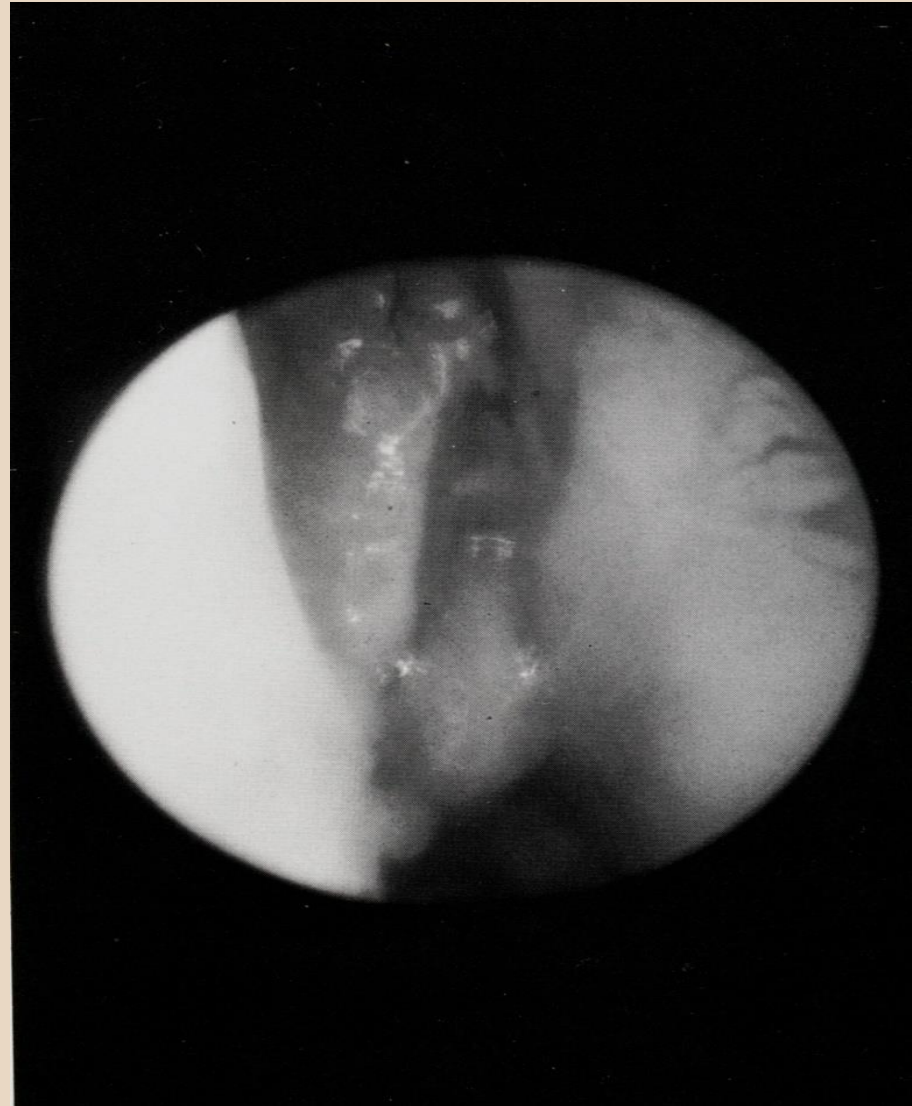
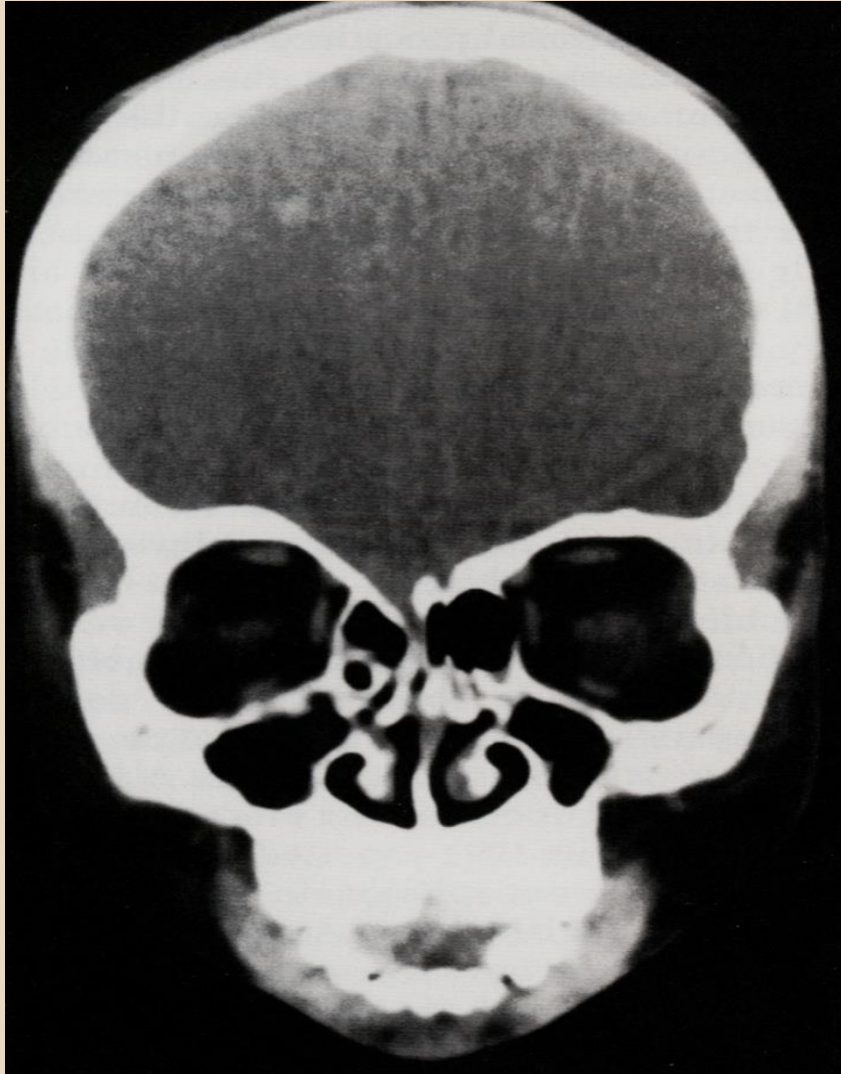


Fig. 4. The Lyodura graft is inserted through the skull defect to lie in the epidural space and is interposed between the torn dura and bony skull. The arrows indicate that intracranial pressure will compress the injured dura and the interposed Lyodura graft to the basal skull, thereby aiding adherence.

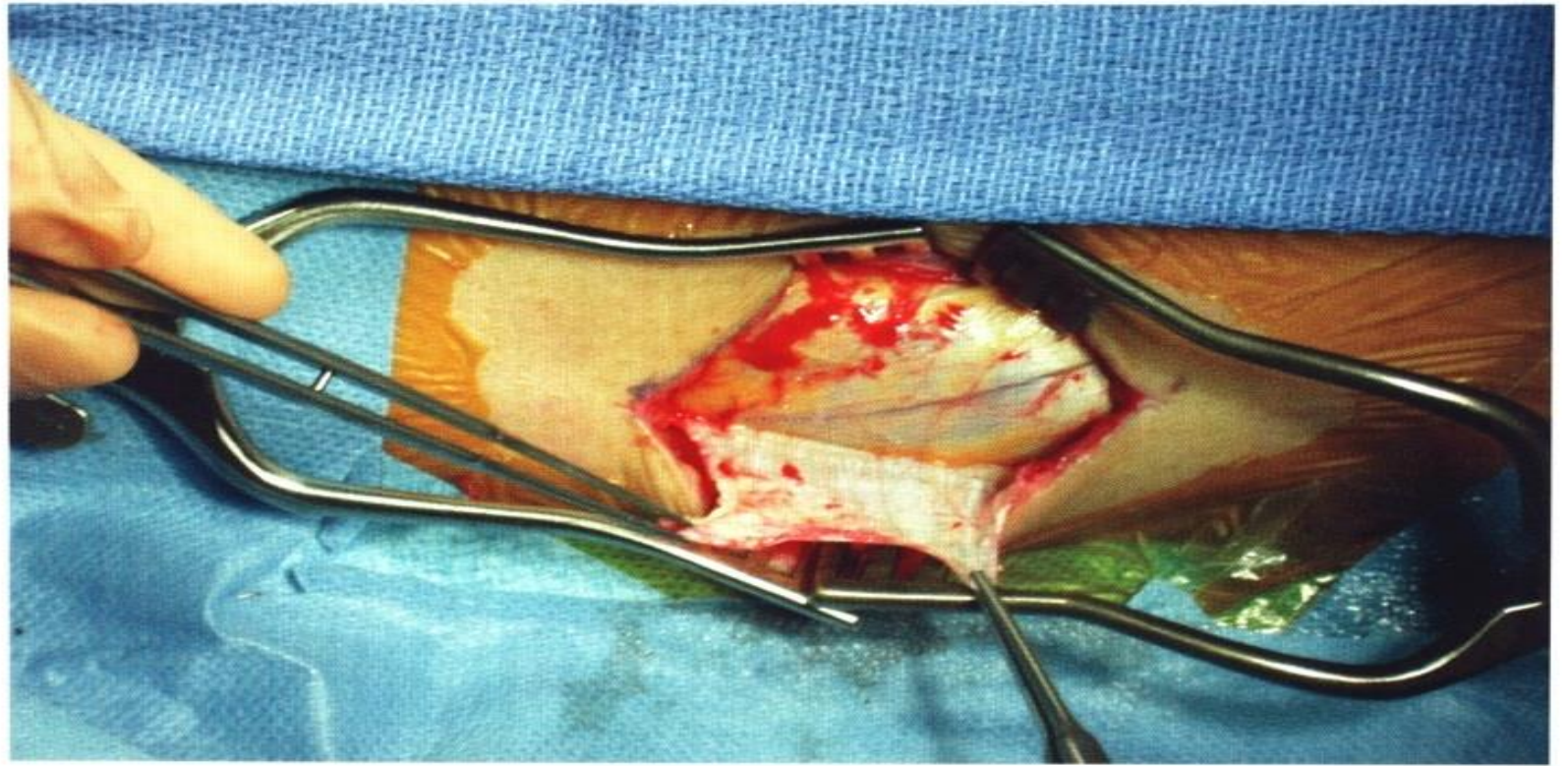
# Small ONF



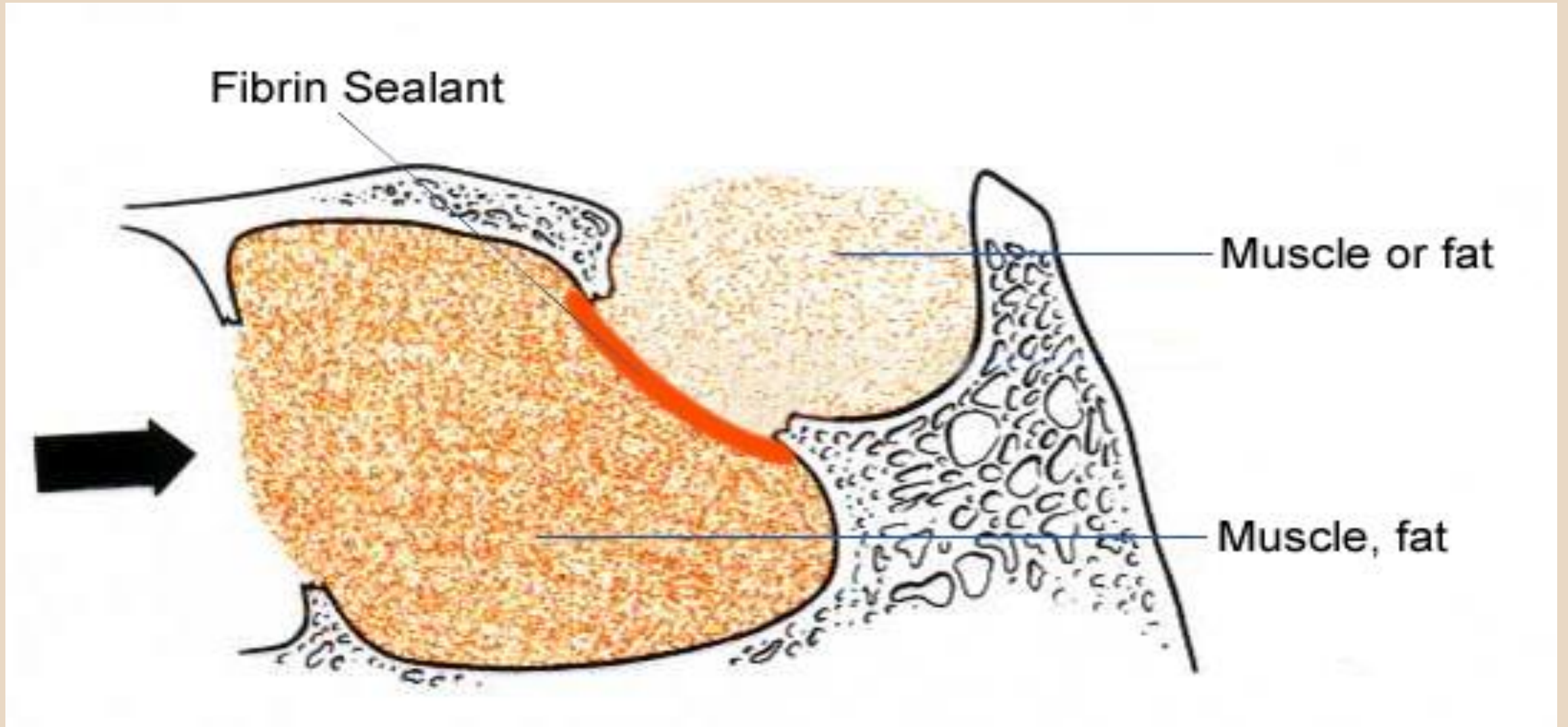
# Meningocele



**Fig 14–3.** The lateral thigh provides an abundant source of autologous fat and fascia for multi-layered endoscopic reconstruction of a skull base defect. The location away from the site of tumor resection allows for simultaneous graft harvest.

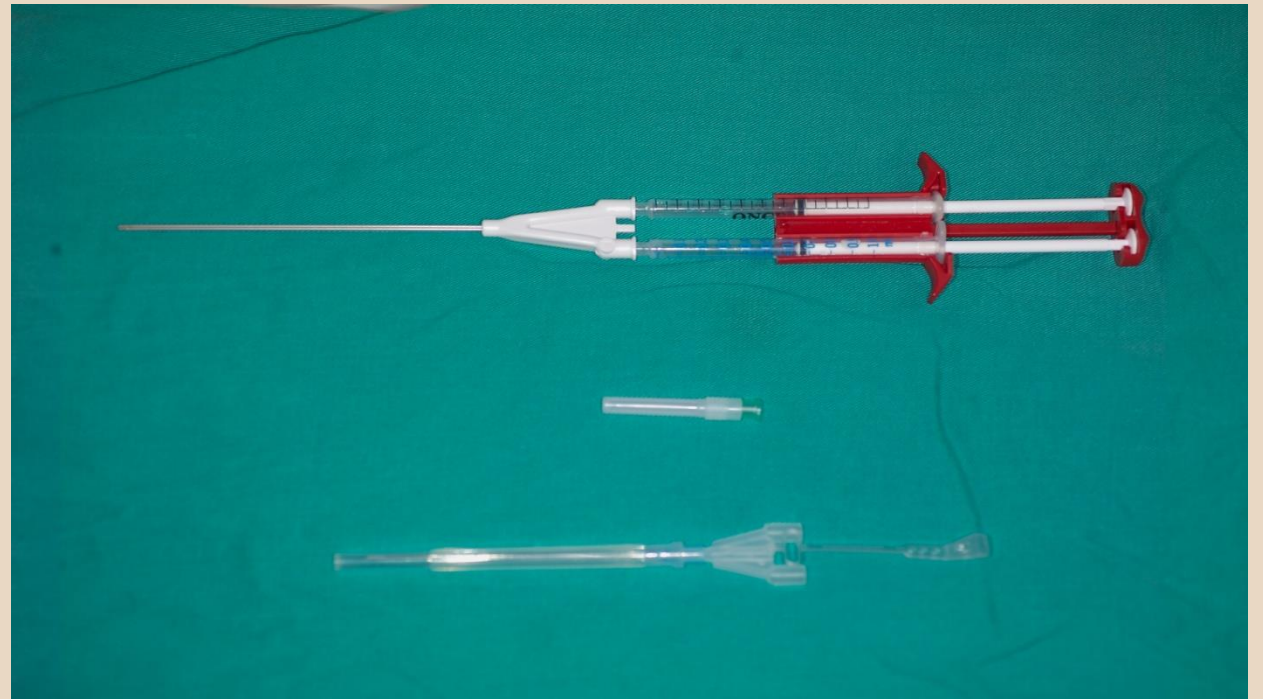


# Tuck & Tempnade



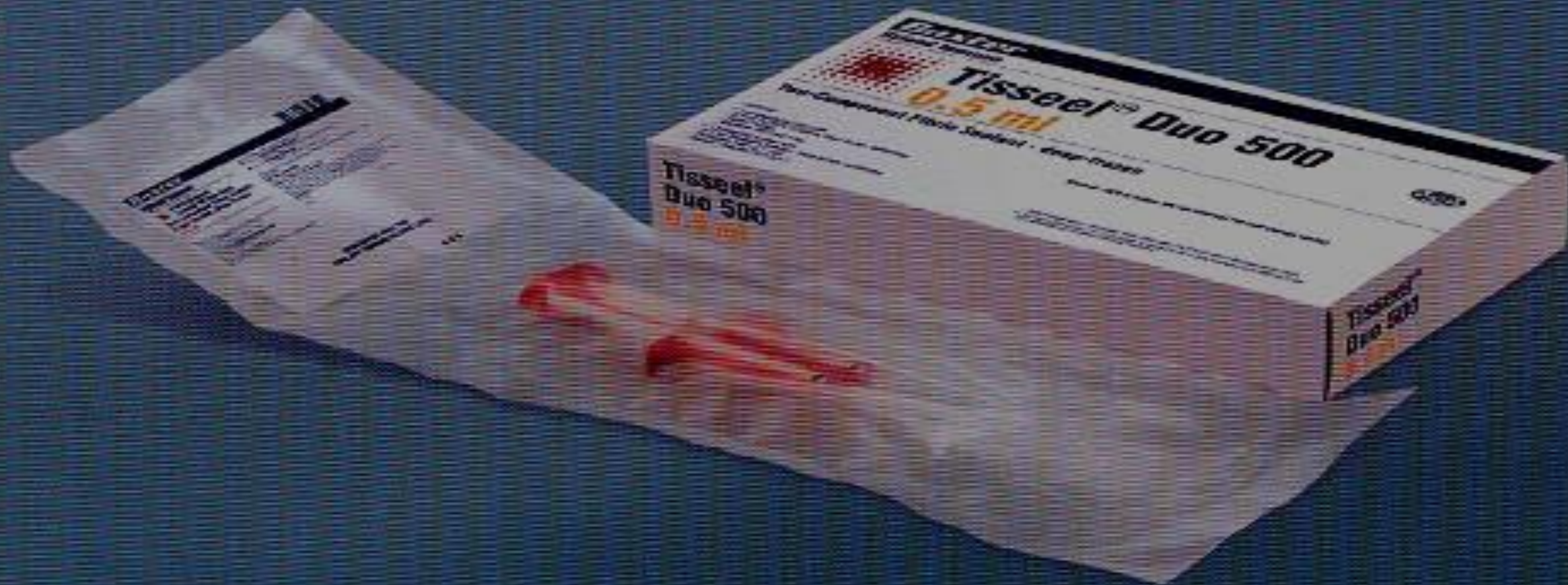# Tuck & Tempon

- Sphenoid sinus, esp. lateral wall
- Diffuse leak
- Fat or fasciae graft
- Bioglue

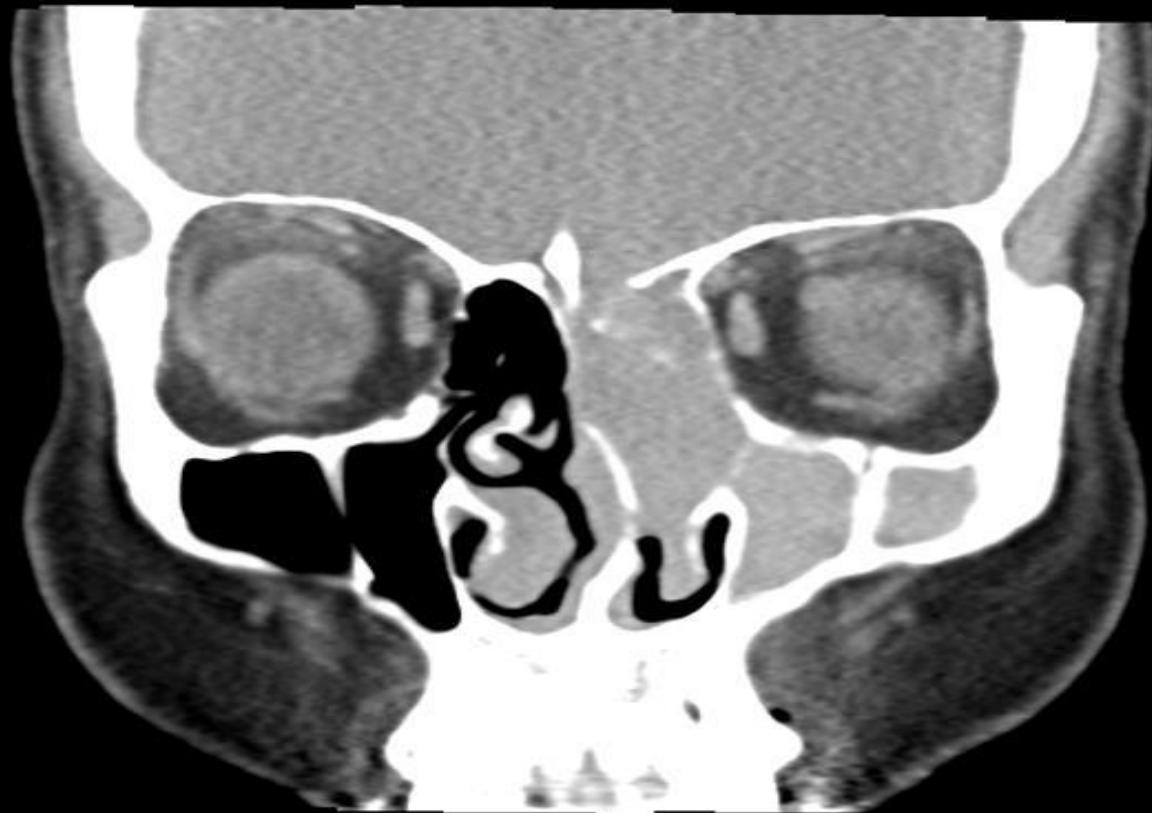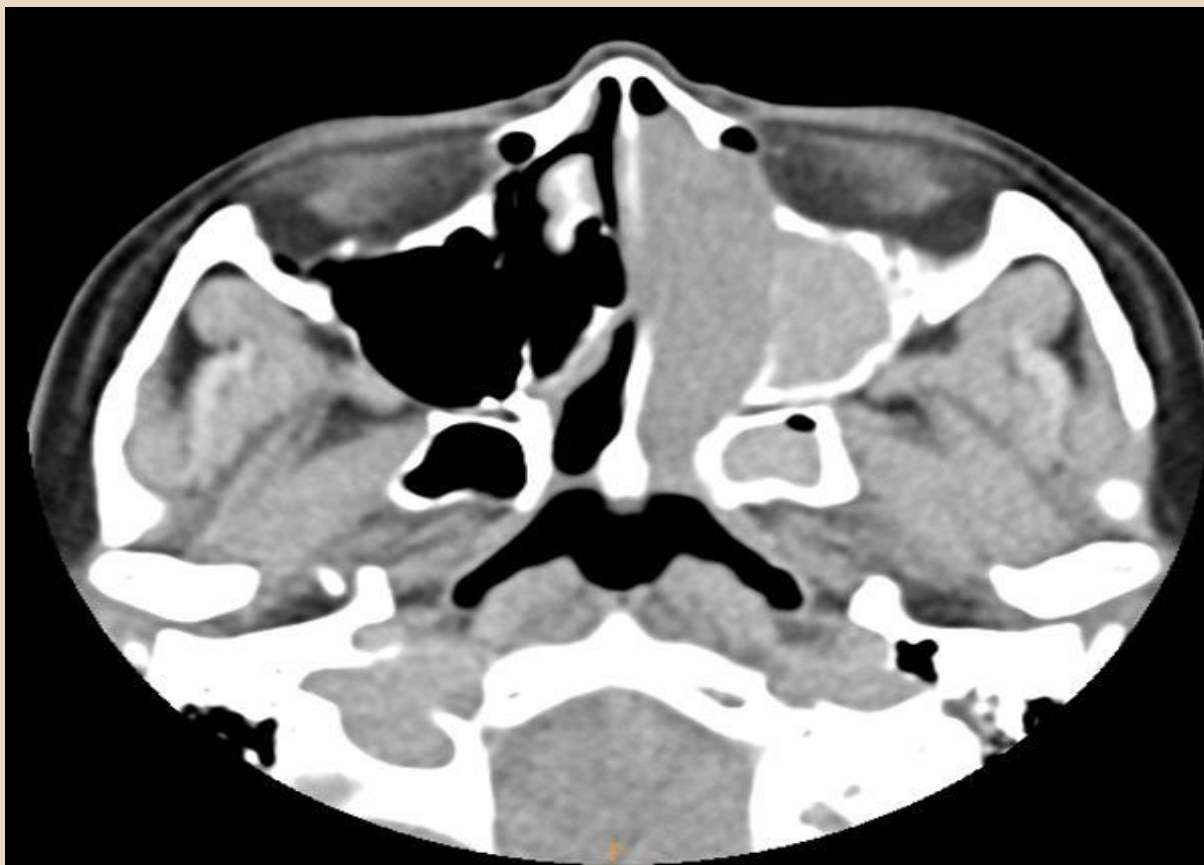




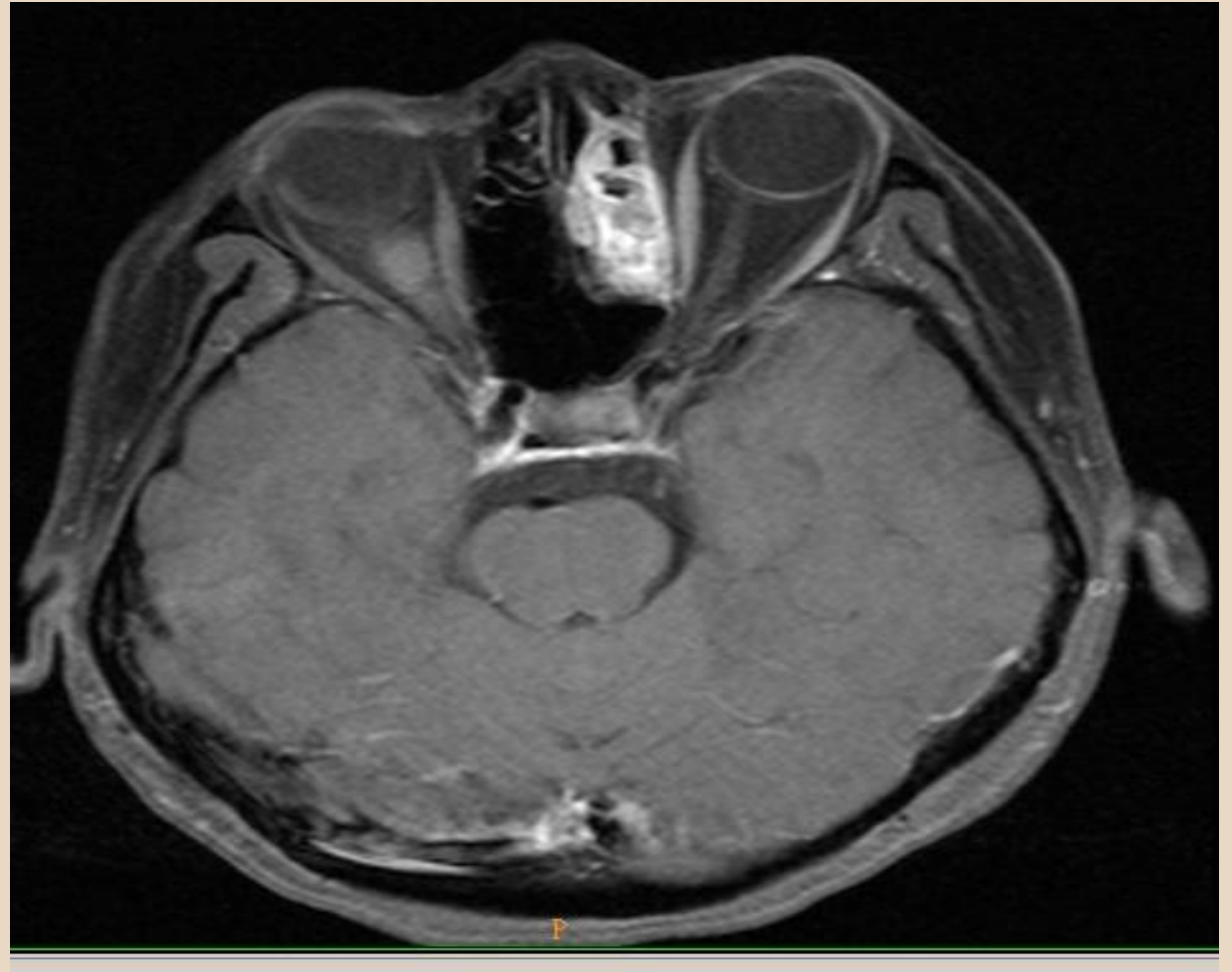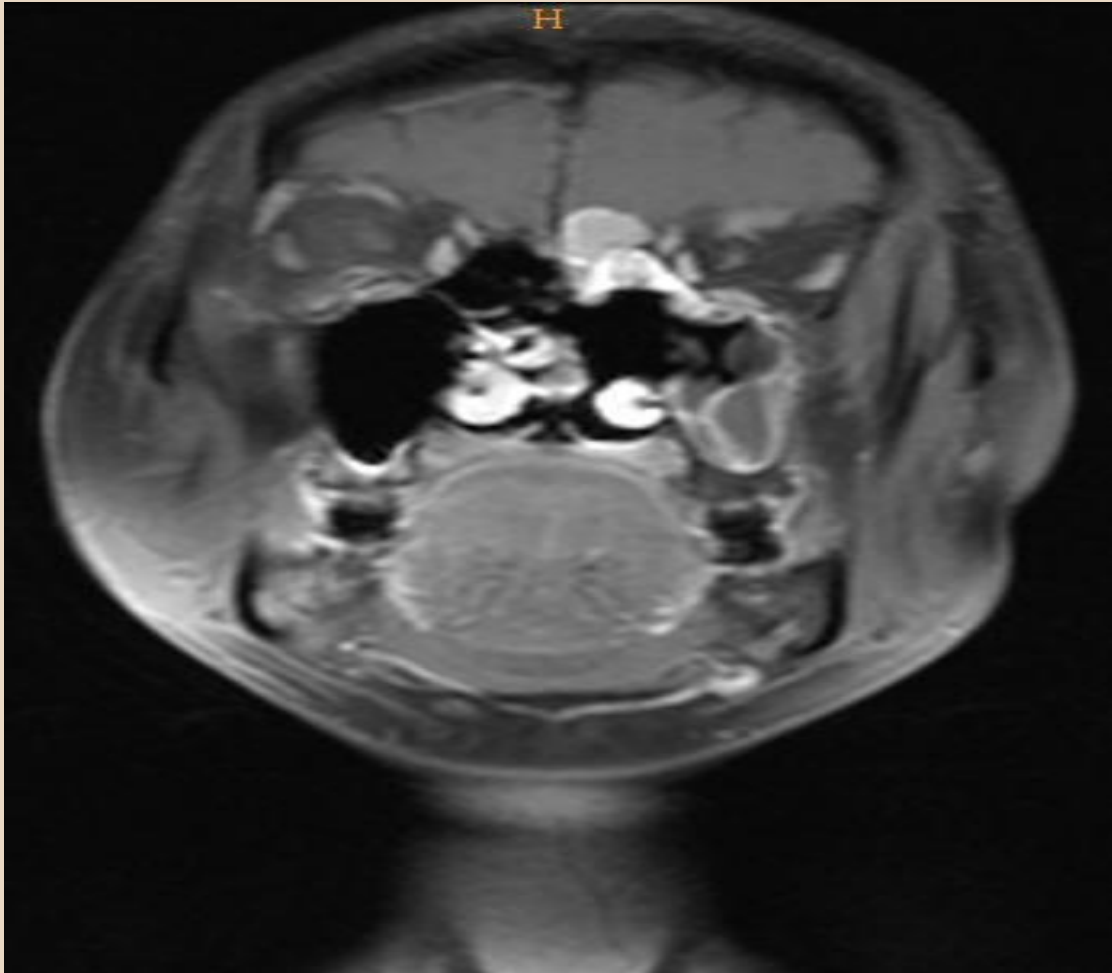Tisseel Duo 500  
fibrin sealant




**41 Y/O F, Professor, Lawyer**  
**Olfactory neuroblastoma**



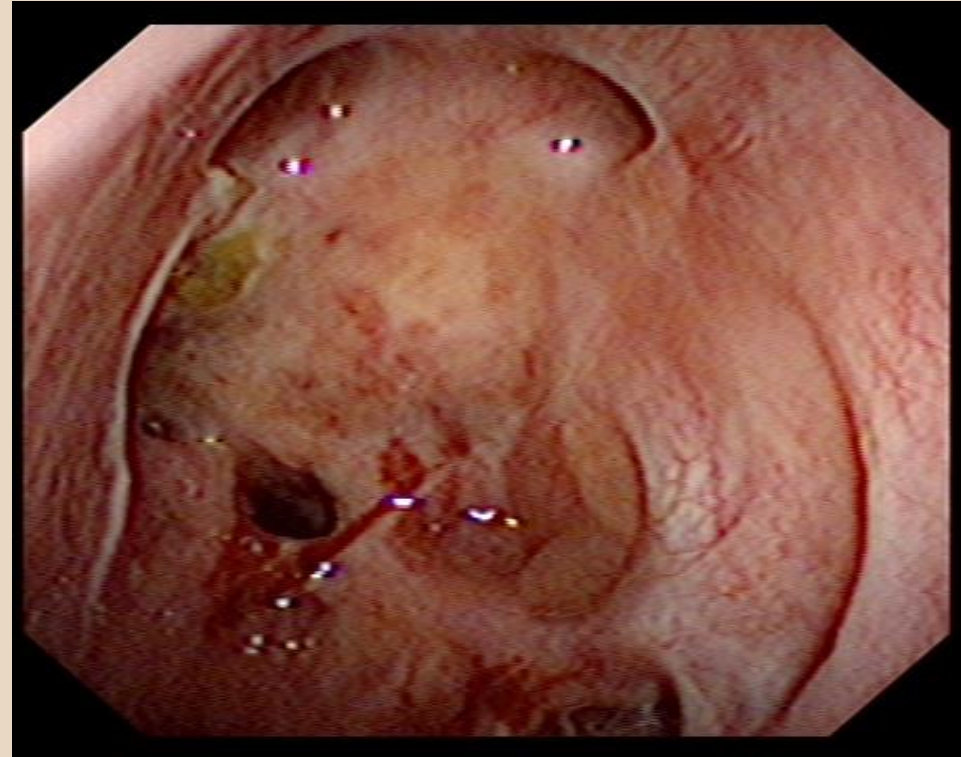
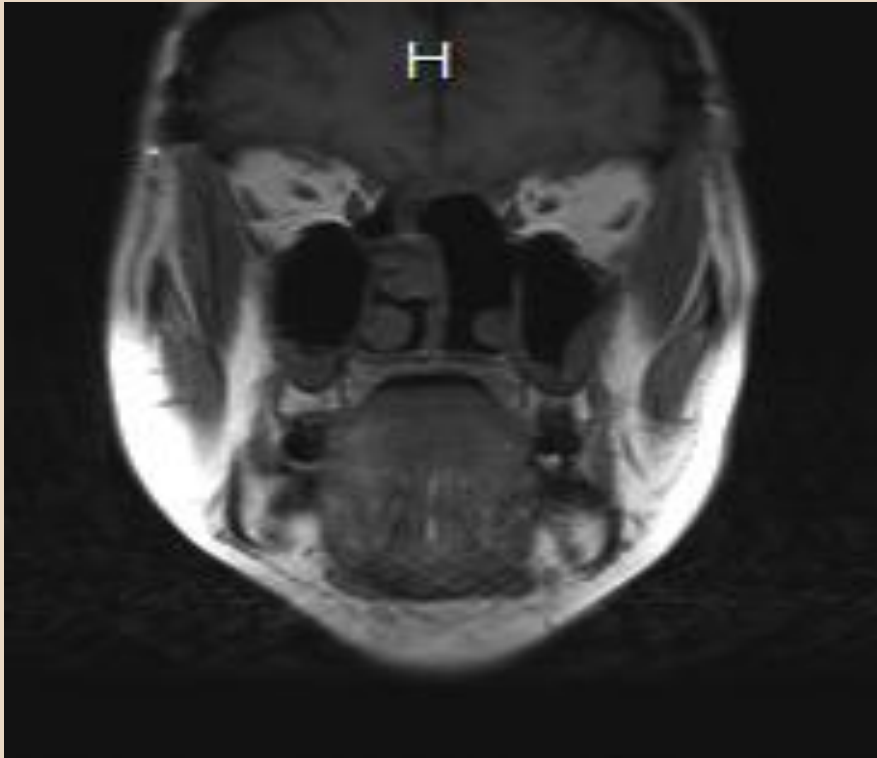
# Endoscopic resection outside with residual tumor



# En Bloc Resection

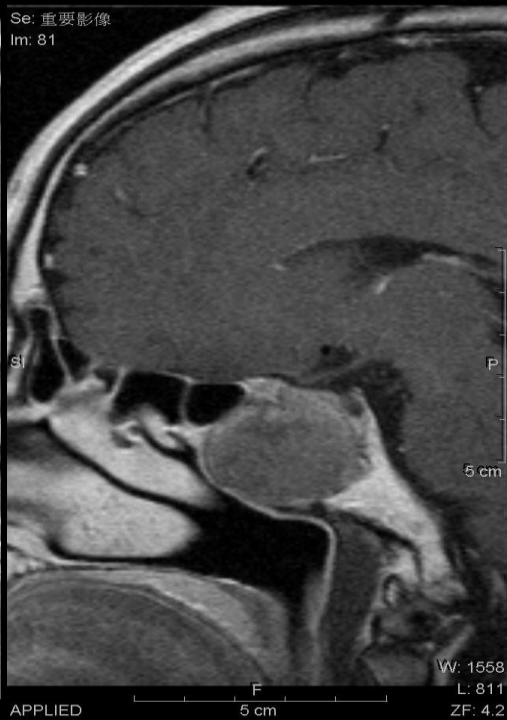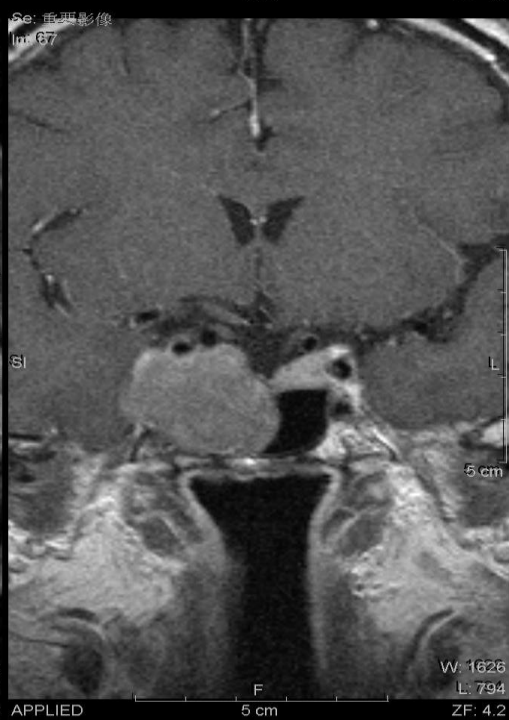
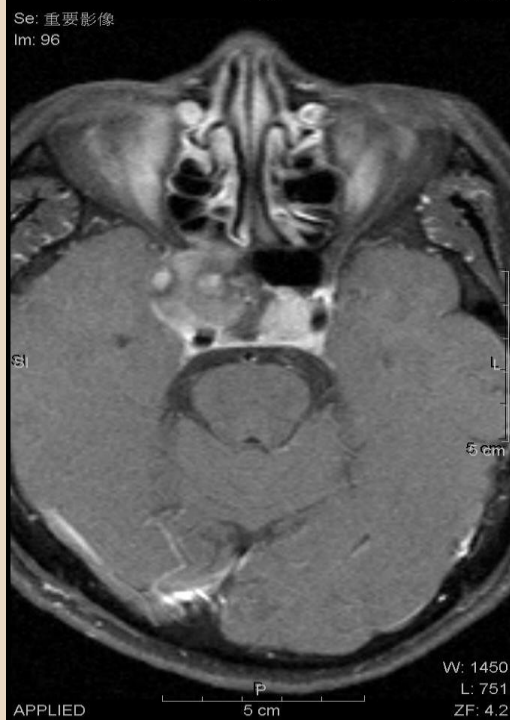

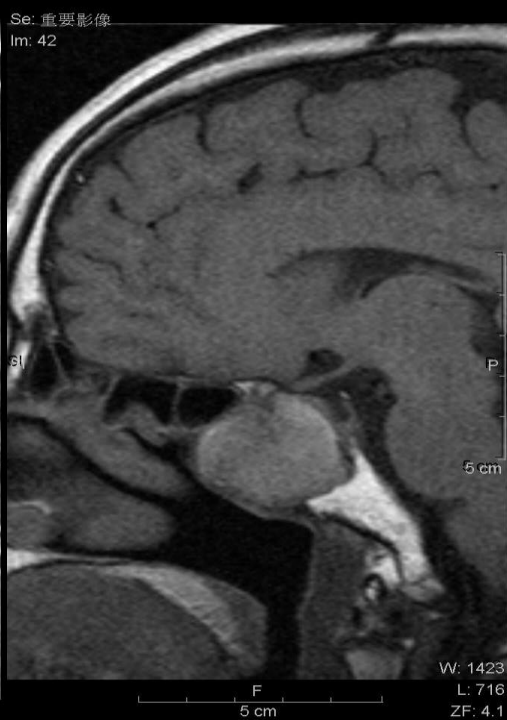
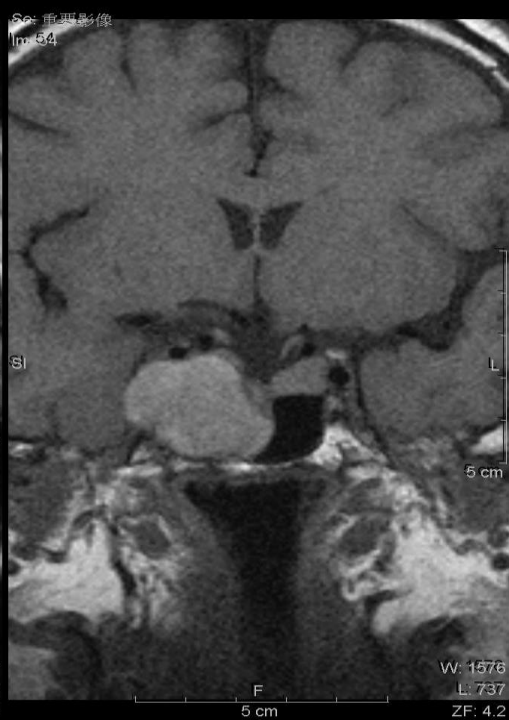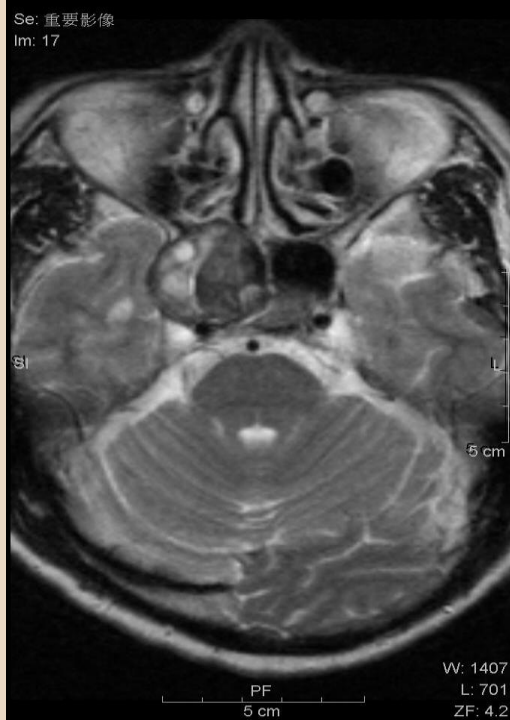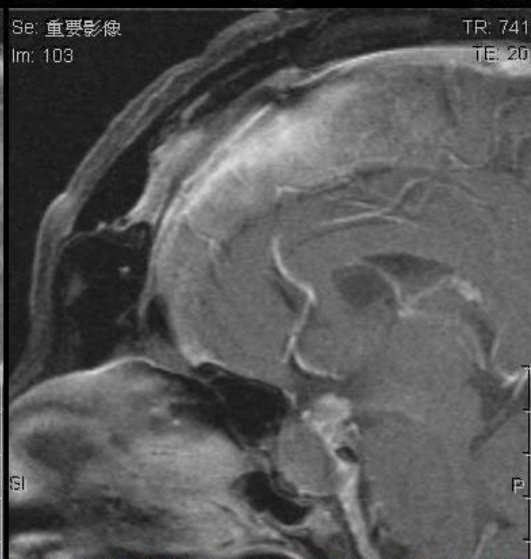
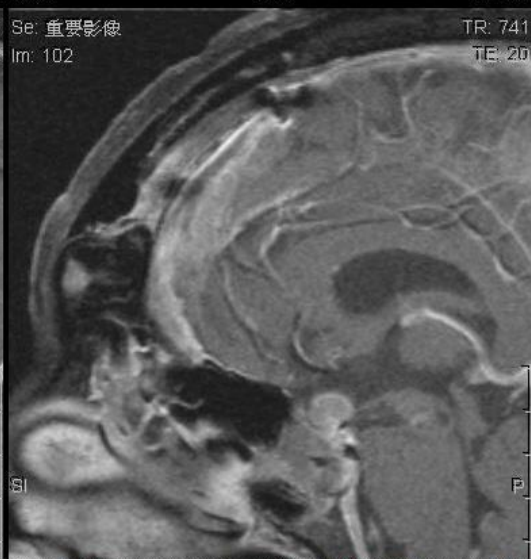
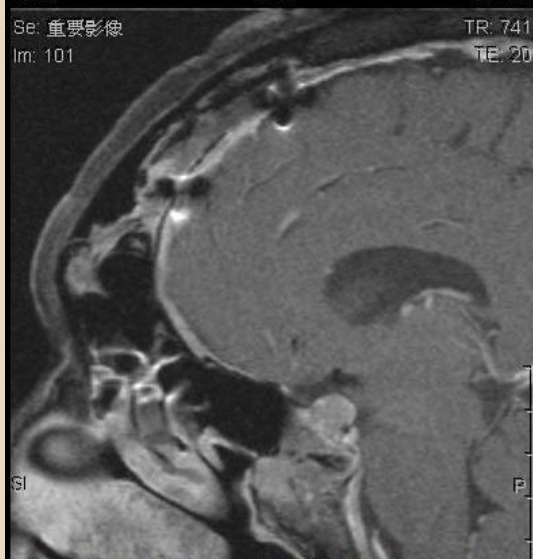
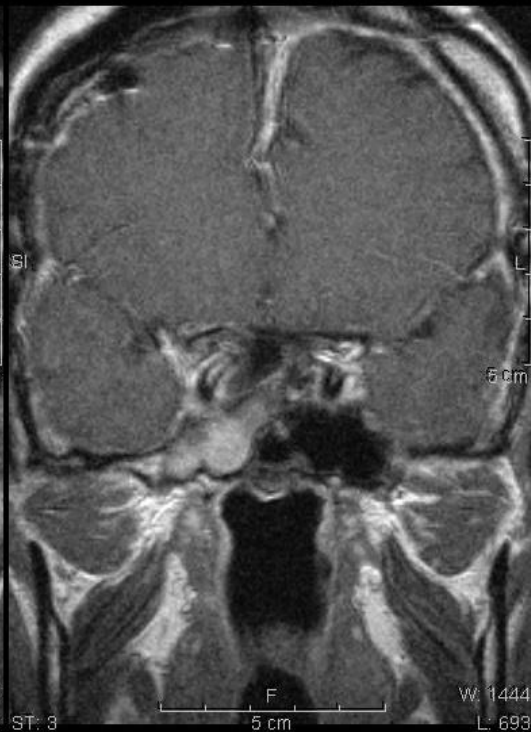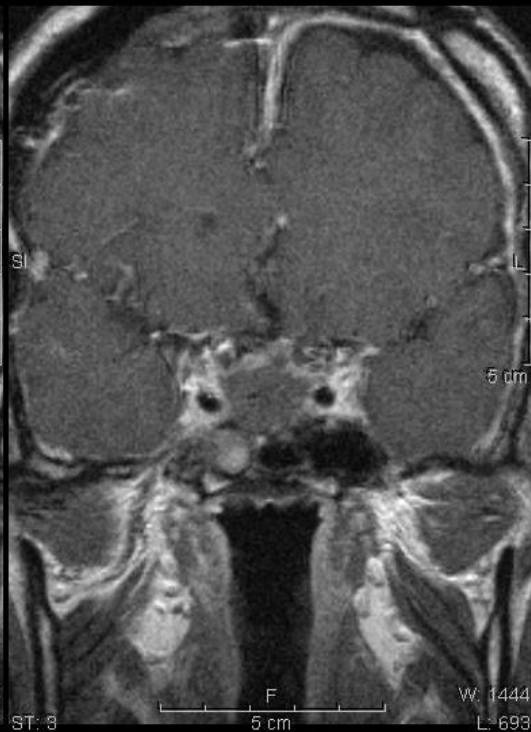
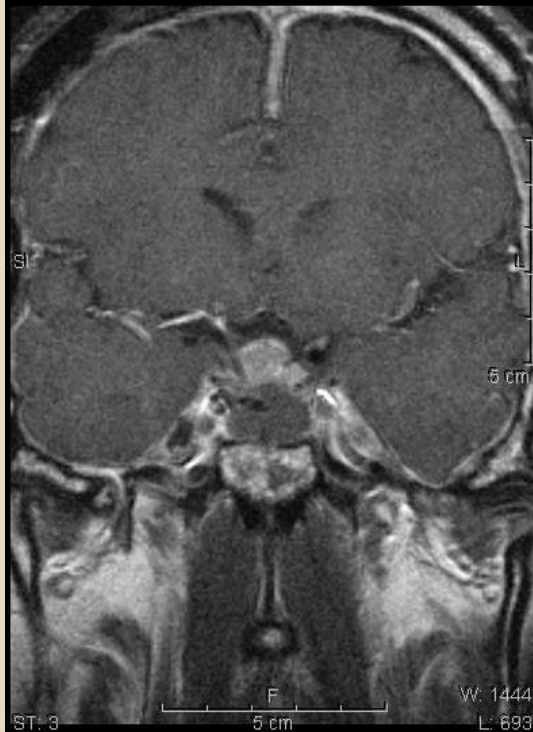
**Post-op 28 months : No residual tumor**



# Rotational Flap

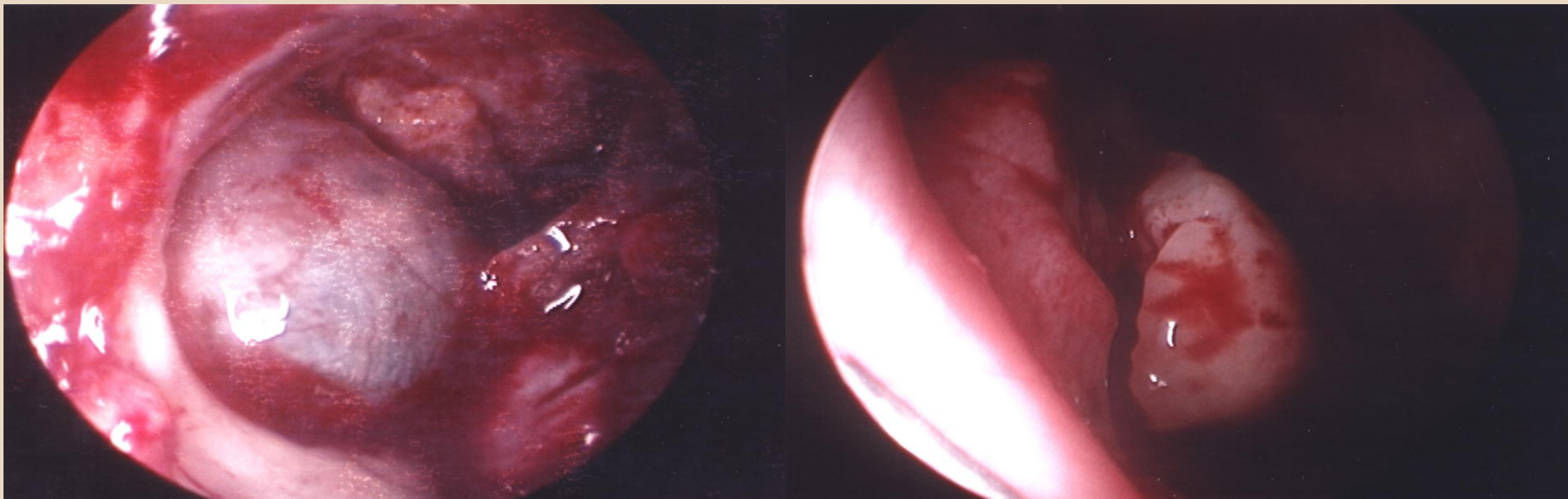
- Infected case
- Turbinate flap
- Nasal septal flap
- Bioglue



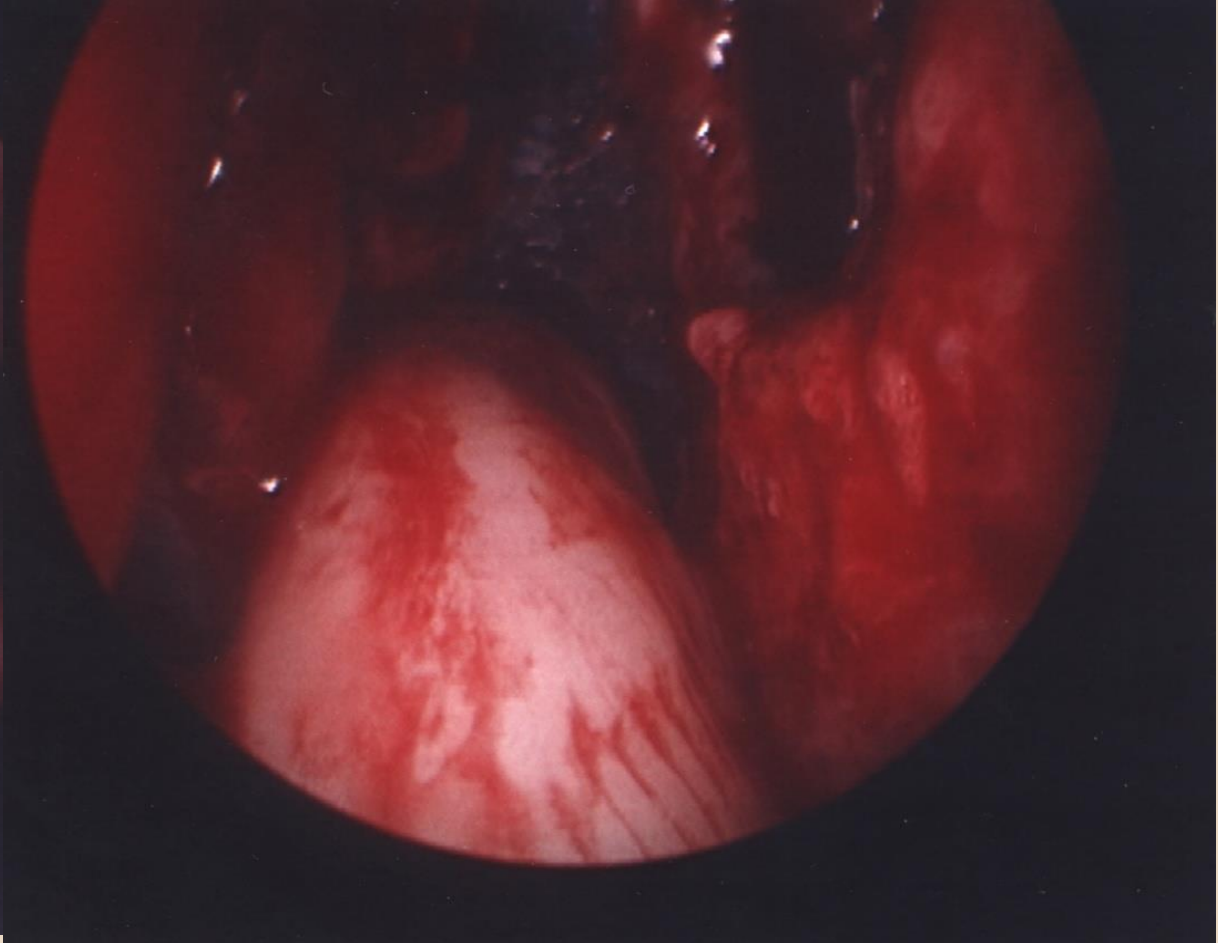
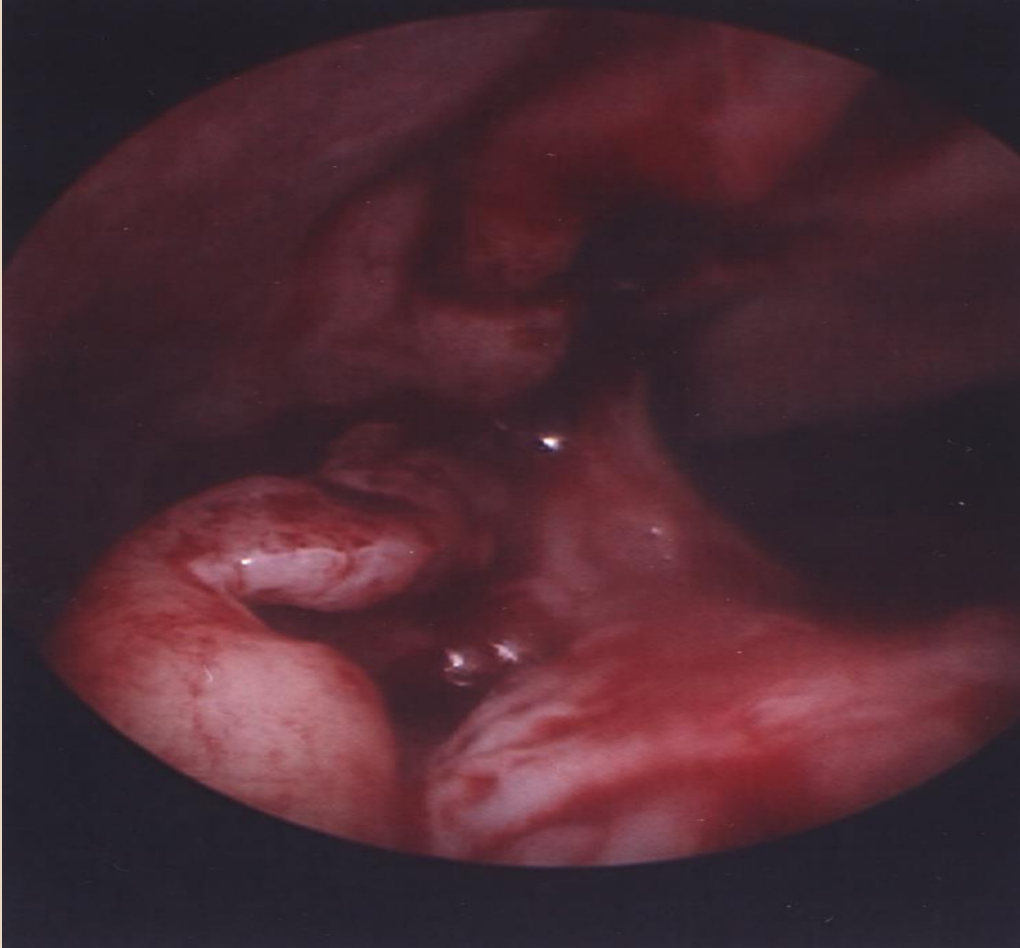




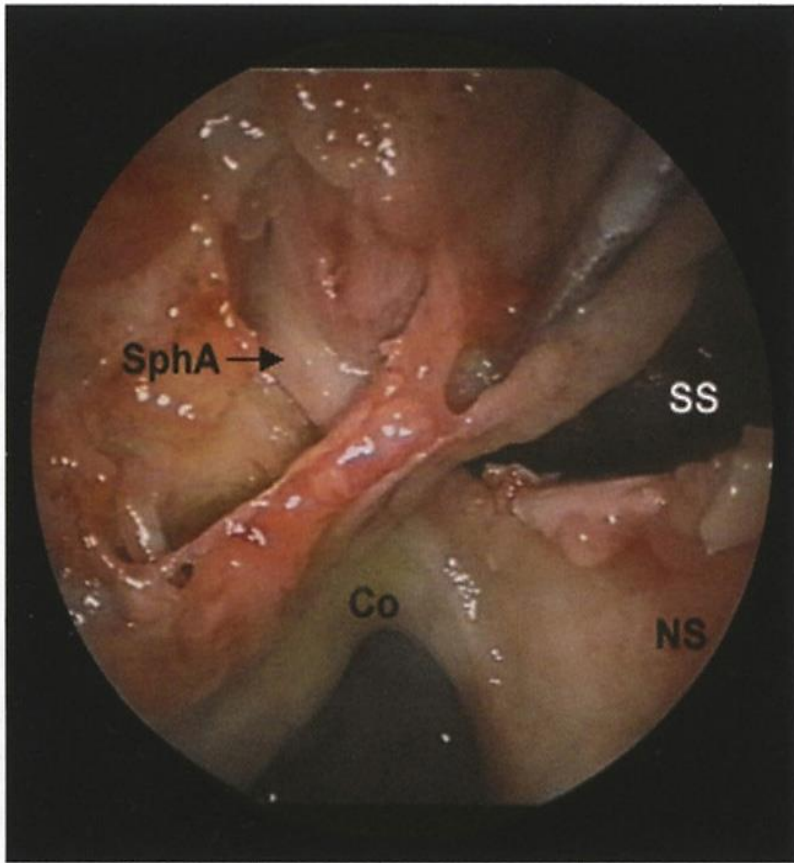
# Acquired Meningocele



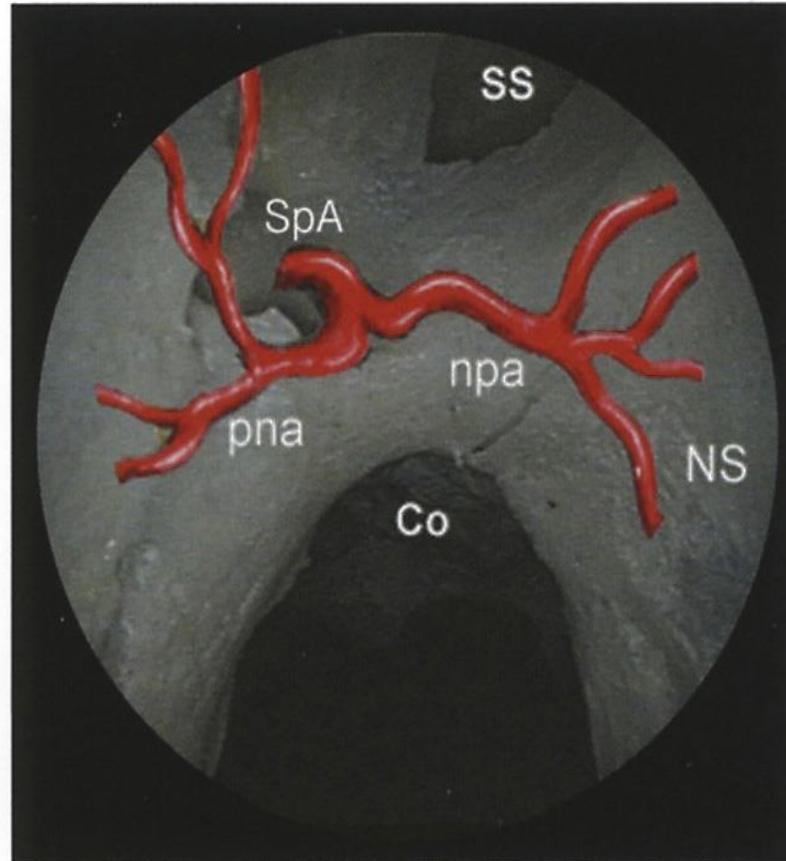
# Inferior Turbinate Flap



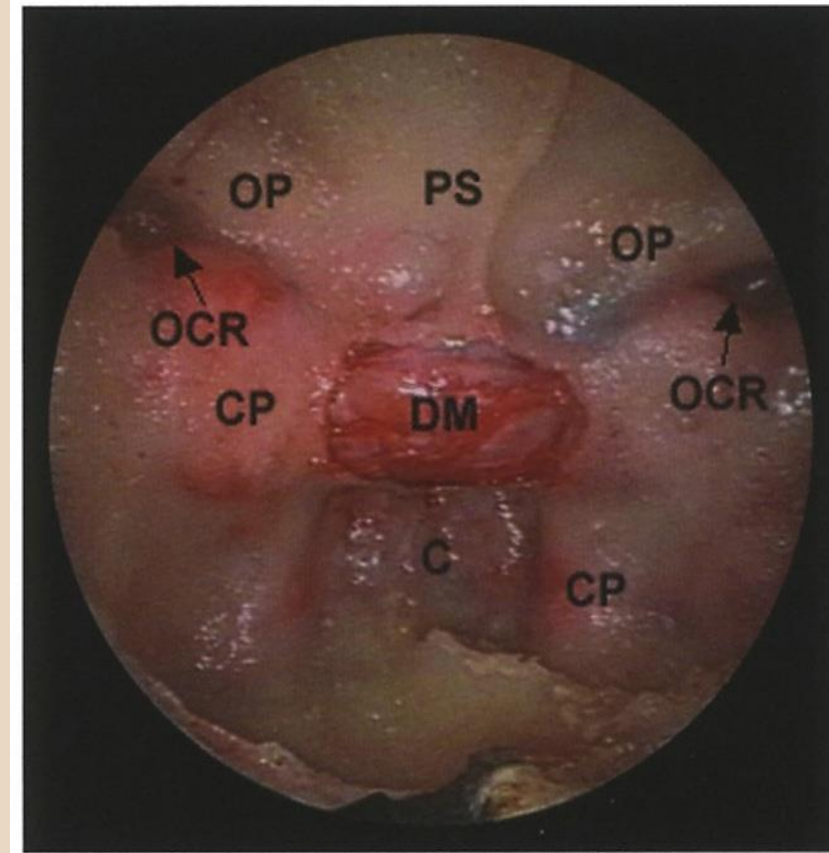
# Septal Flap



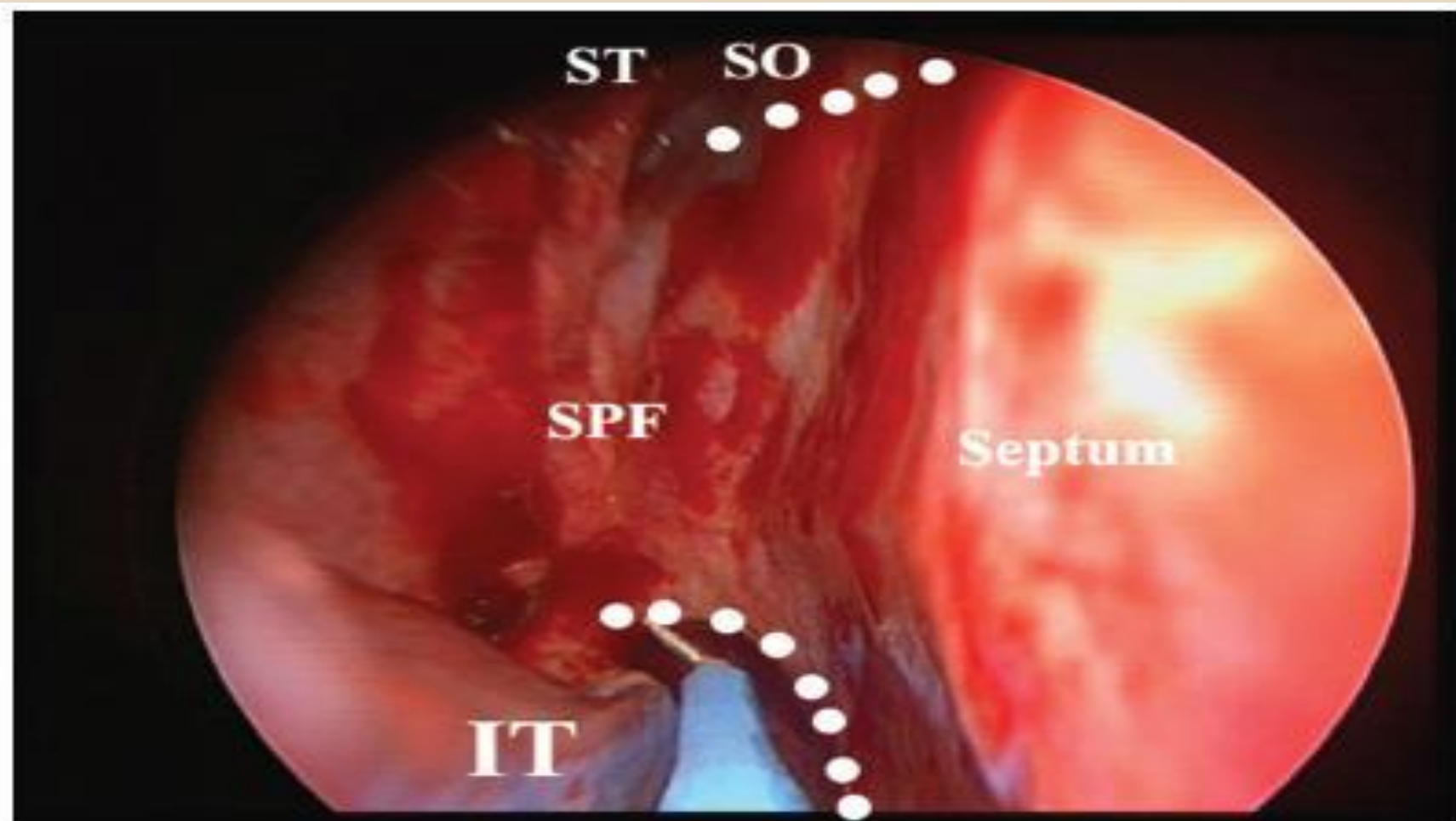
**Fig. 20**  
Right nasal cavity. Exposure of the sphenopalatine artery



**Fig. 21**  
Right nasal cavity. Course of the main branches of the sphenopalatine artery.



**Fig. 22**  
Sphenoid stage: Main landmarks of the posterior intracavitary sphenoid sinus.



*Figure 1. Planned incisions around pedicle of the nasoseptal flap. IT, inferior turbinate; ST, superior turbinate; SO, sphenoid ostium; SPF, mucosa over the sphenopalatine foramen.*

# Ideal Flap for Pituitary Surgery

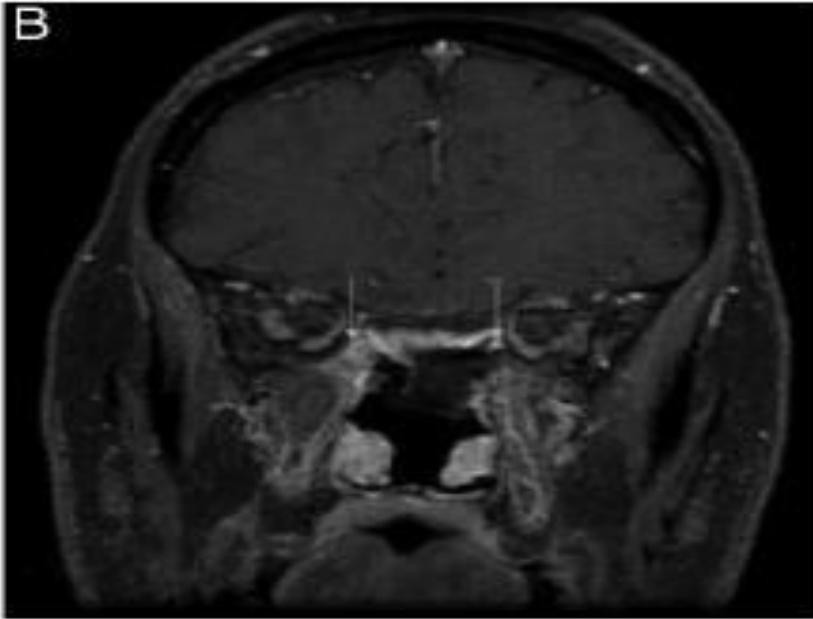
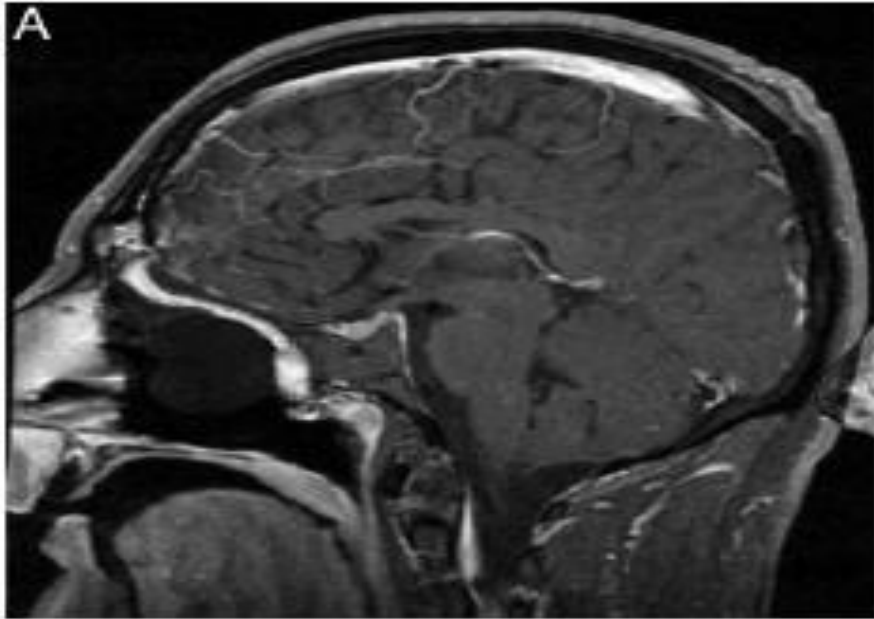
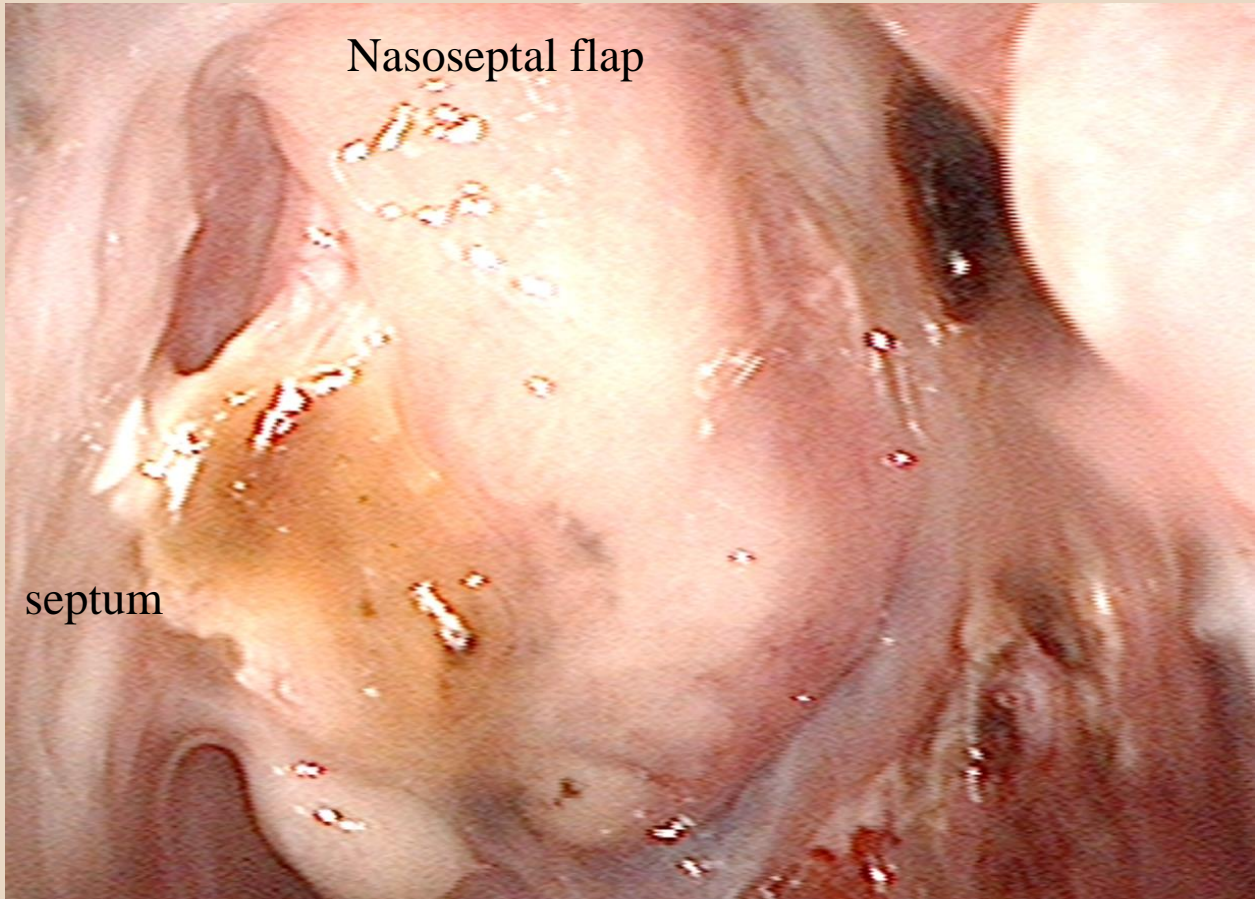
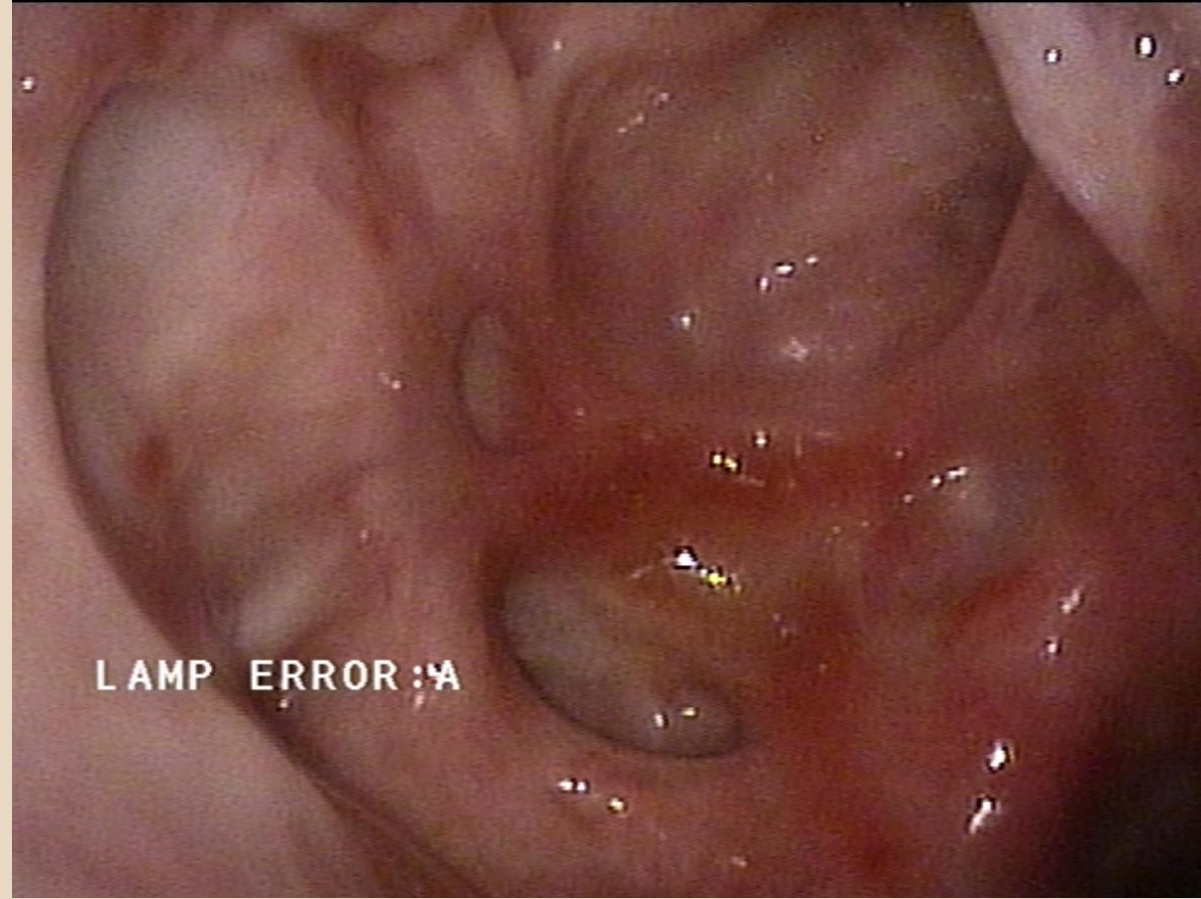


Fig. 3. (A) Sagittal magnetic resonance image of a patient after resection of the anterior skull base. The flap is covering the entire skull base from the inferior palate of the posterior wall of the frontal sinus to the planum sphenoidale. (B) Coronal magnetic resonance image of the same patient. The flap covers the anterior skull base from orbit to orbit.

# Result

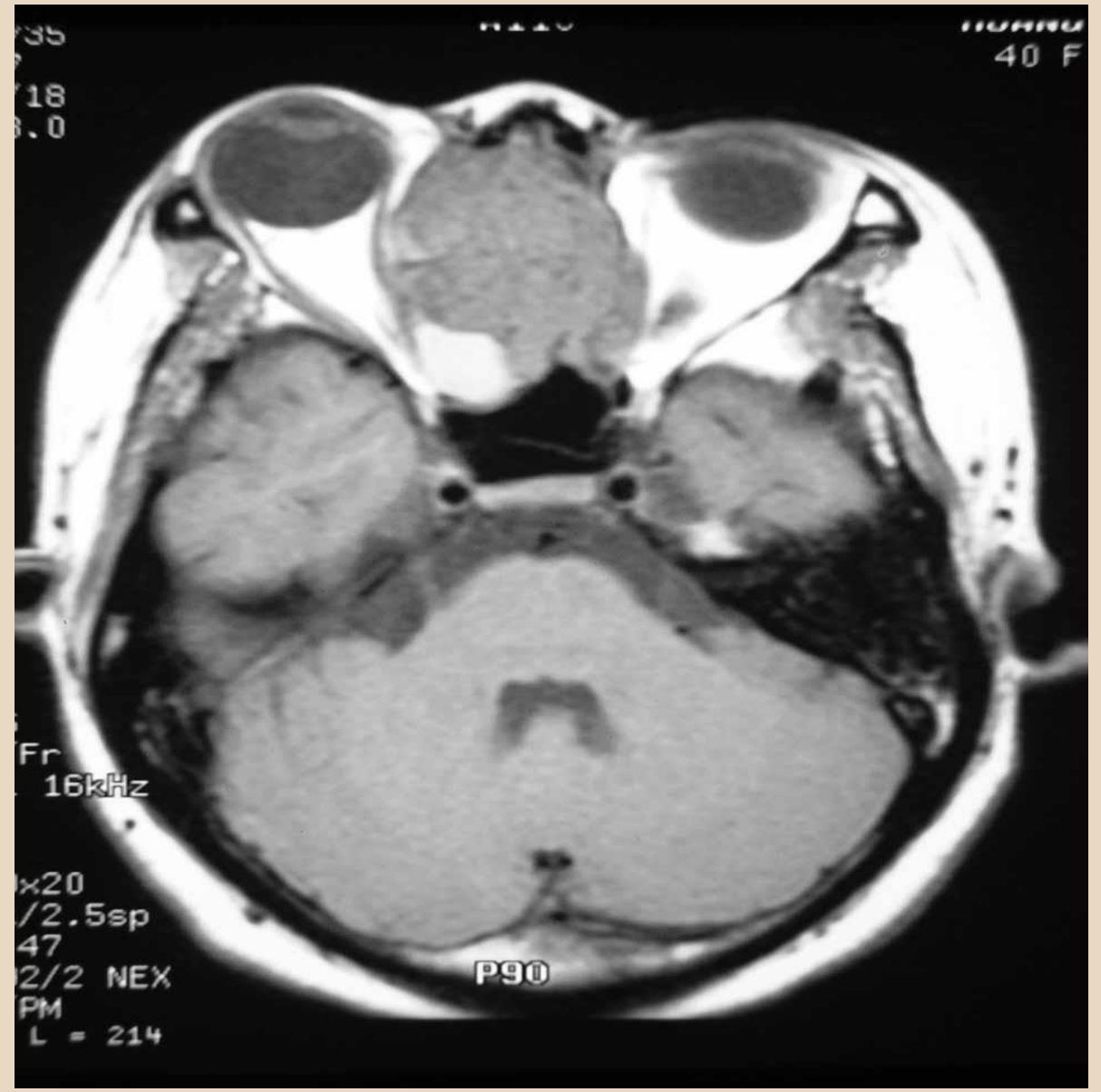
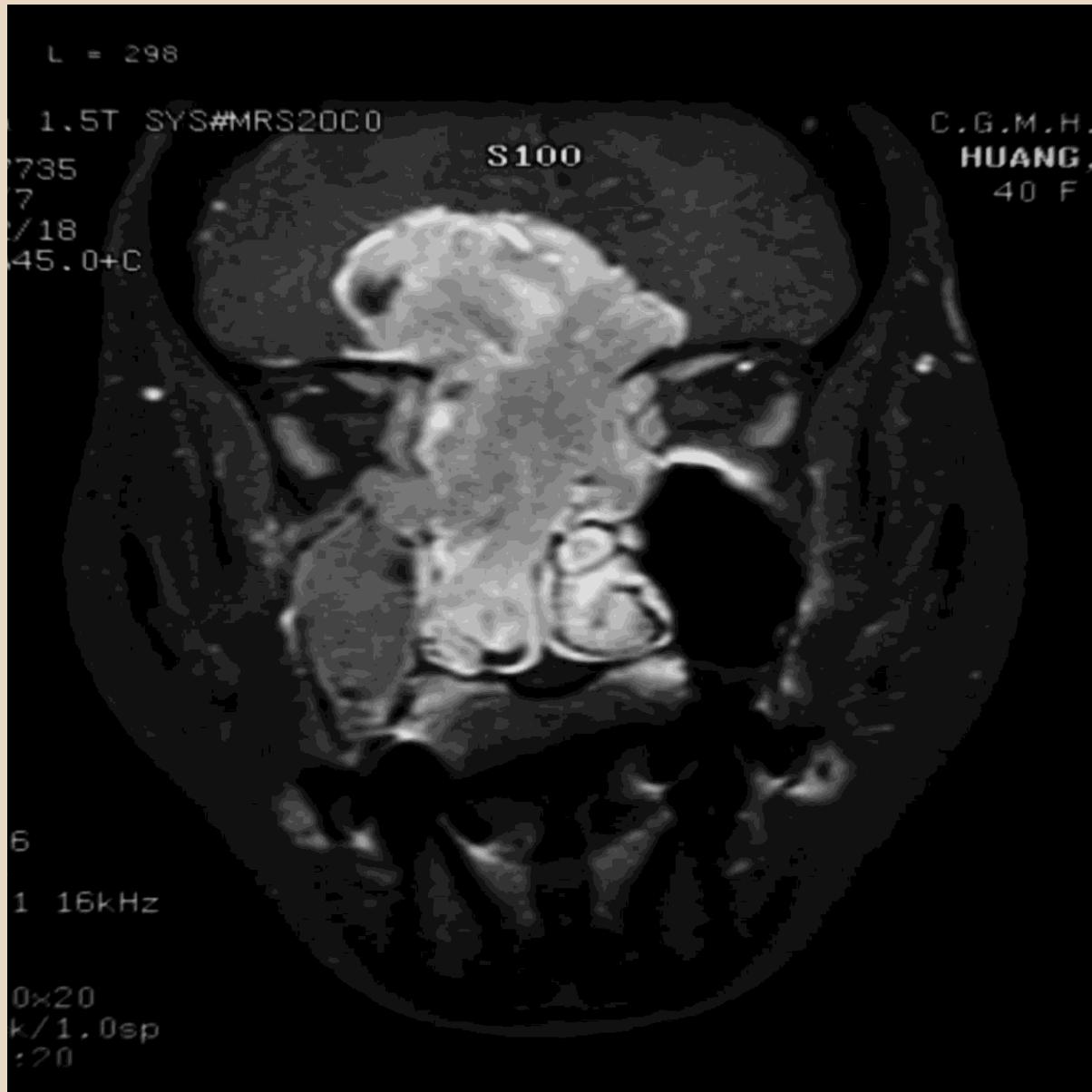

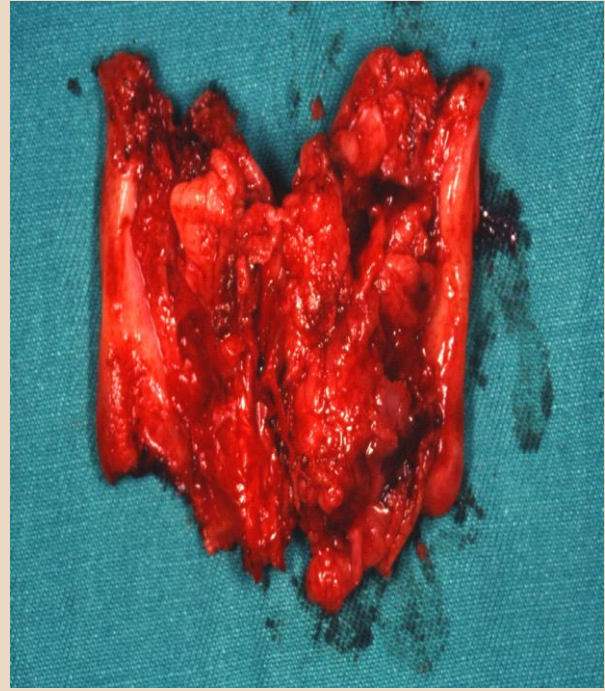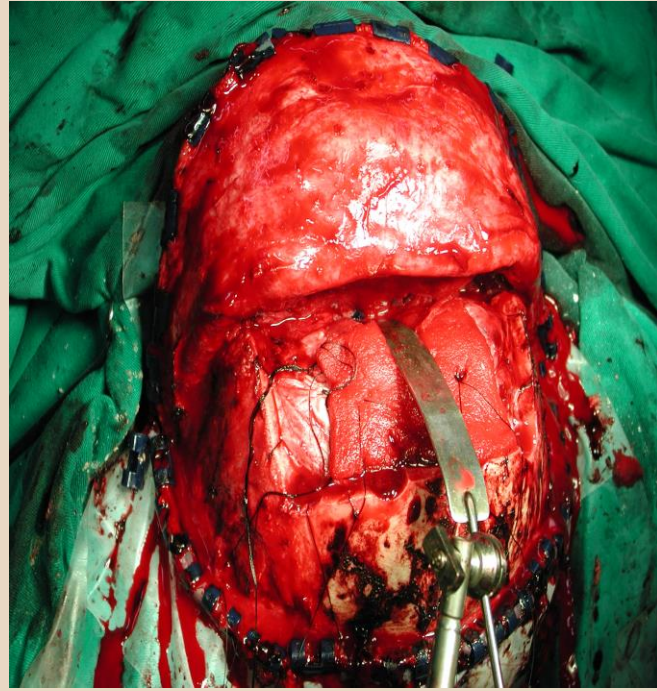
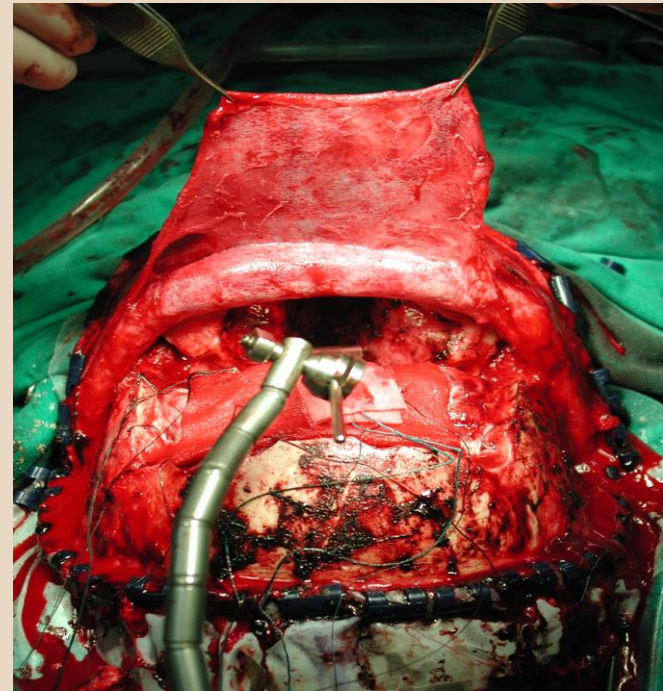
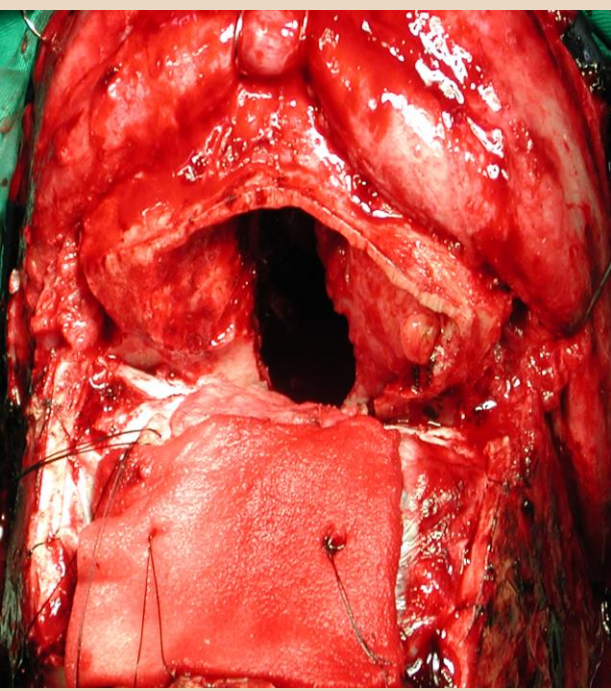
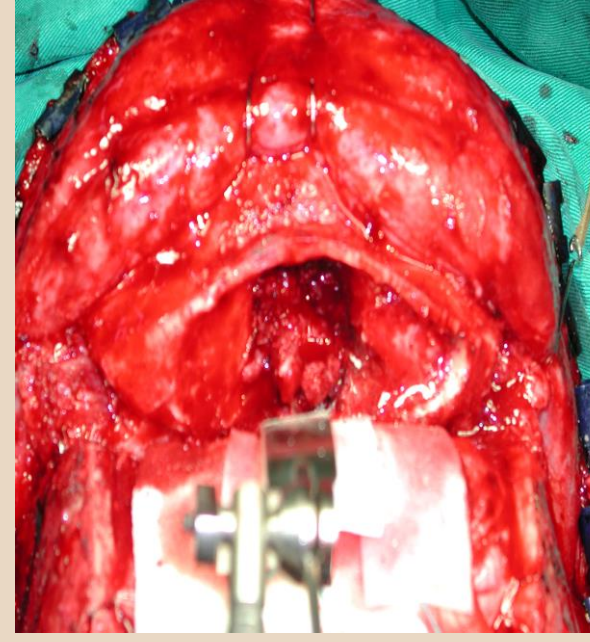
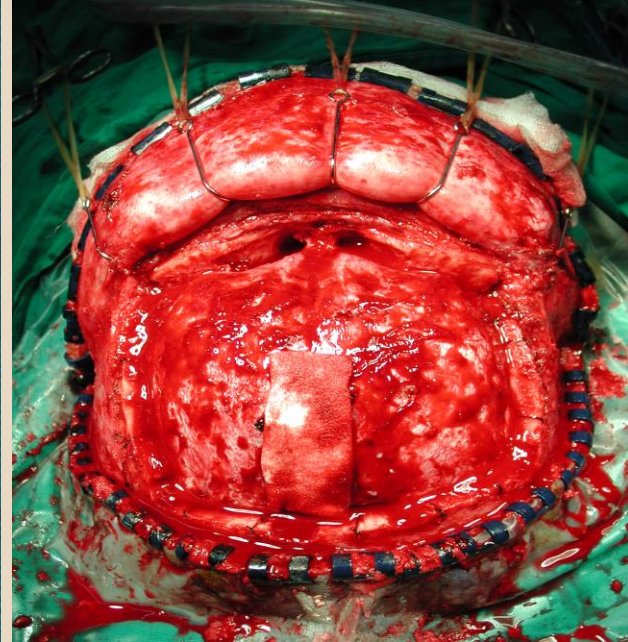
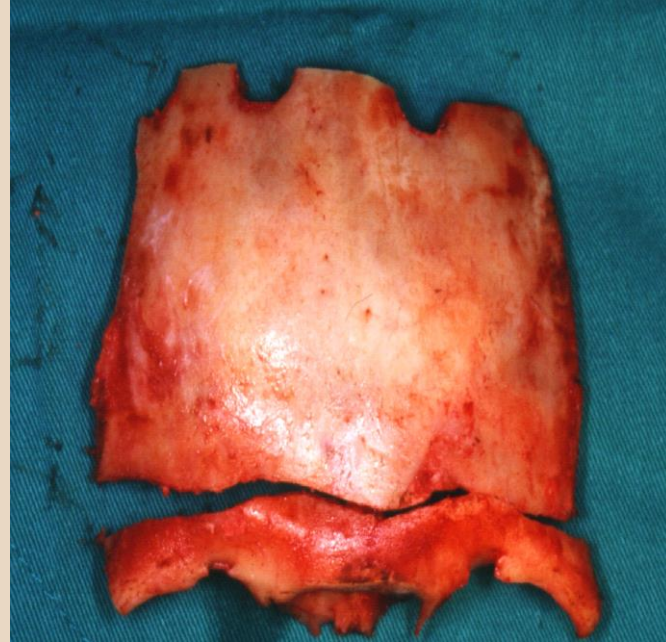
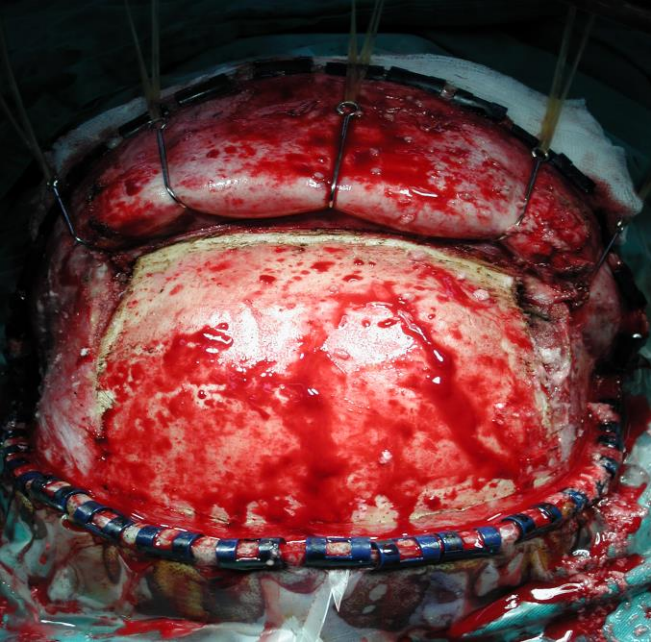
Chronic paranasal sinusitis s/p endoscopic sinus surgery with CSF leak  
*Nasoseptal pedicled flap, post op 35 days*



Pituitary tumor  
*Nasoseptal pedicled flap, post op 3 months*

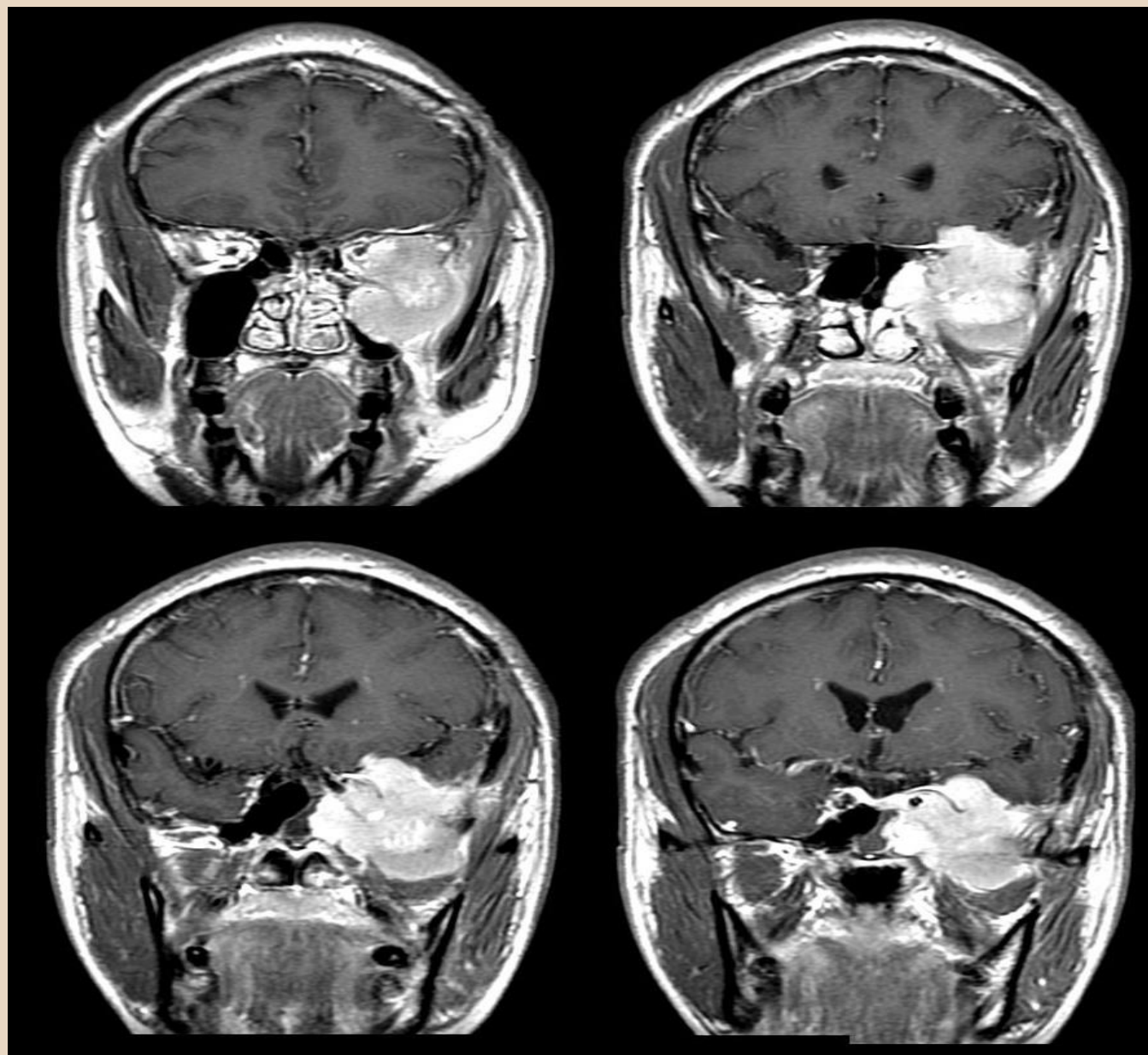
# Olfactory Neuroblastoma

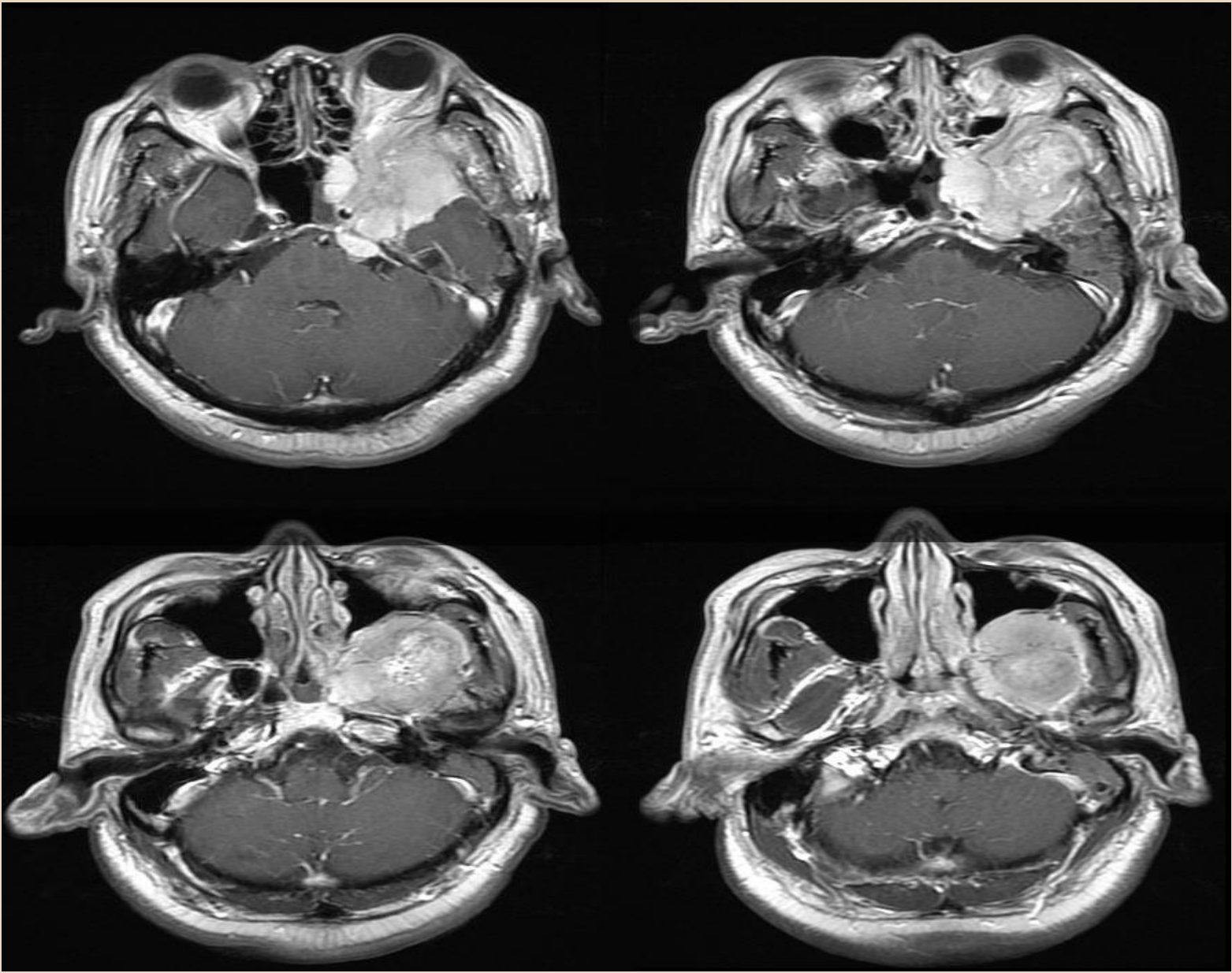


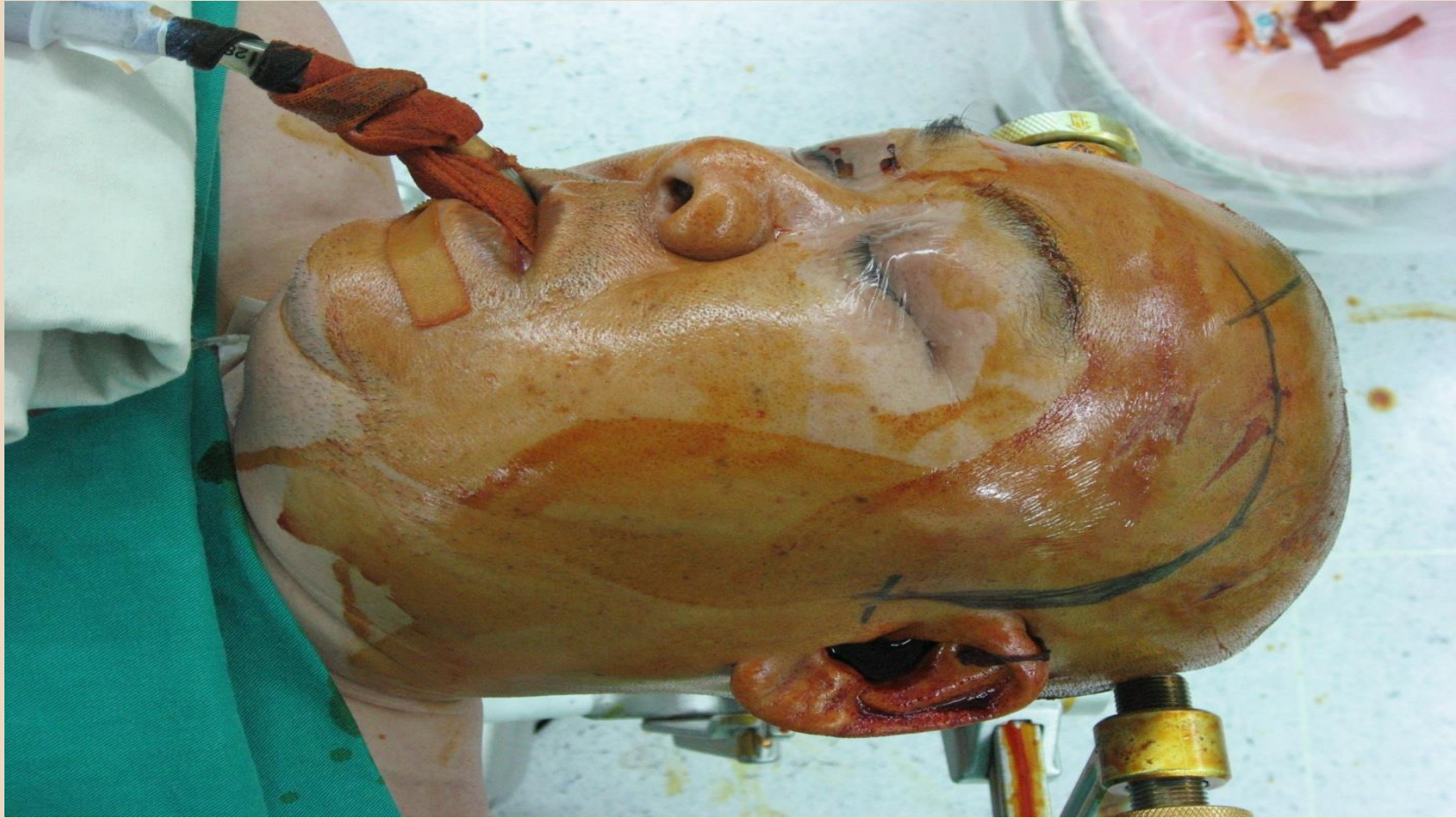

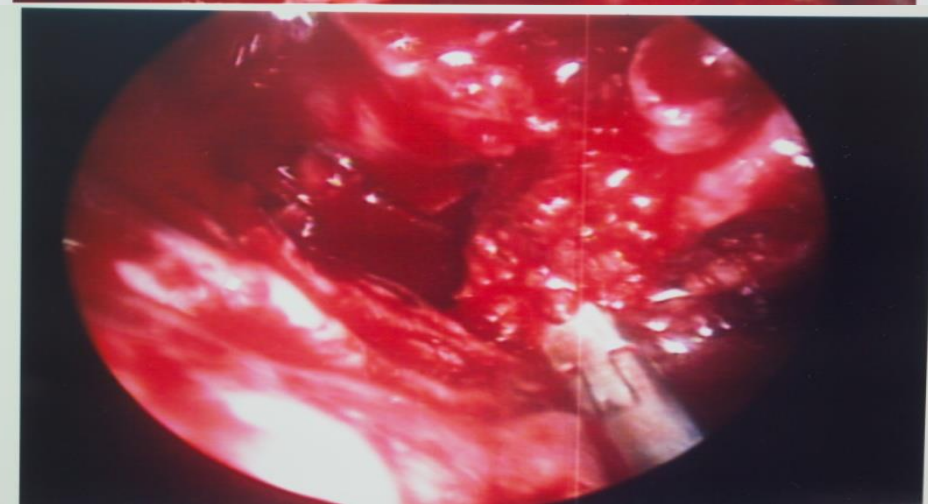
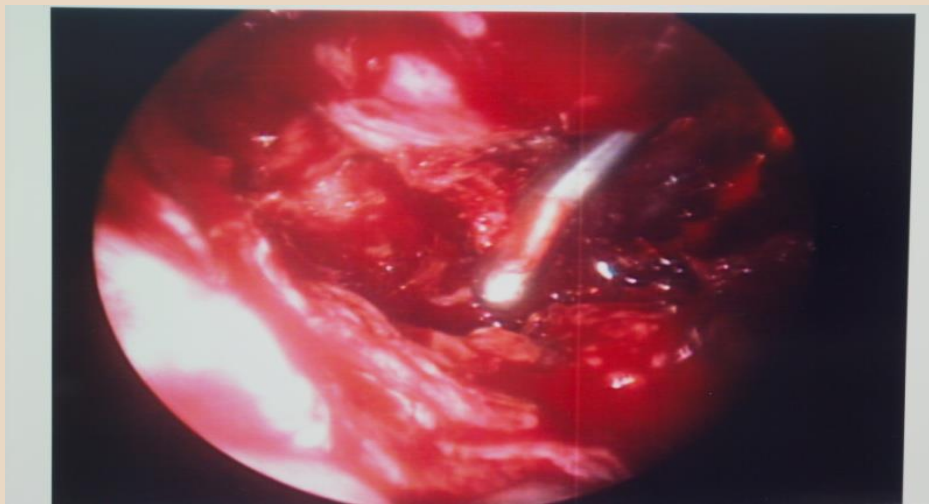
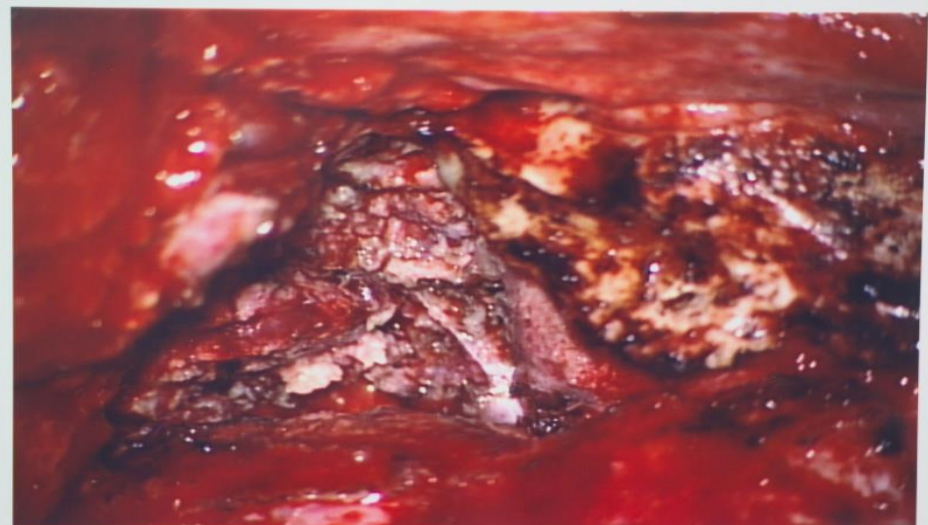
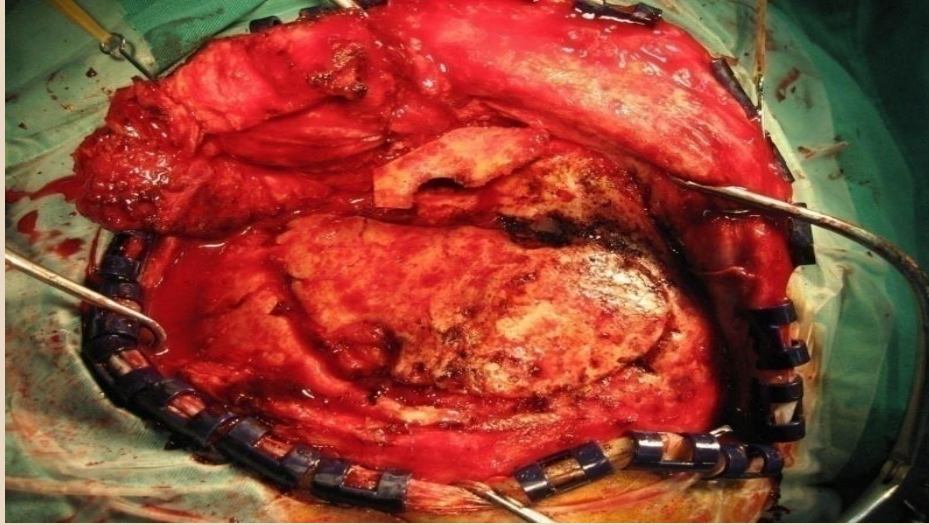


# **Preauricular Infratemporal Subtemporal Combined with Endoscopic Approach**

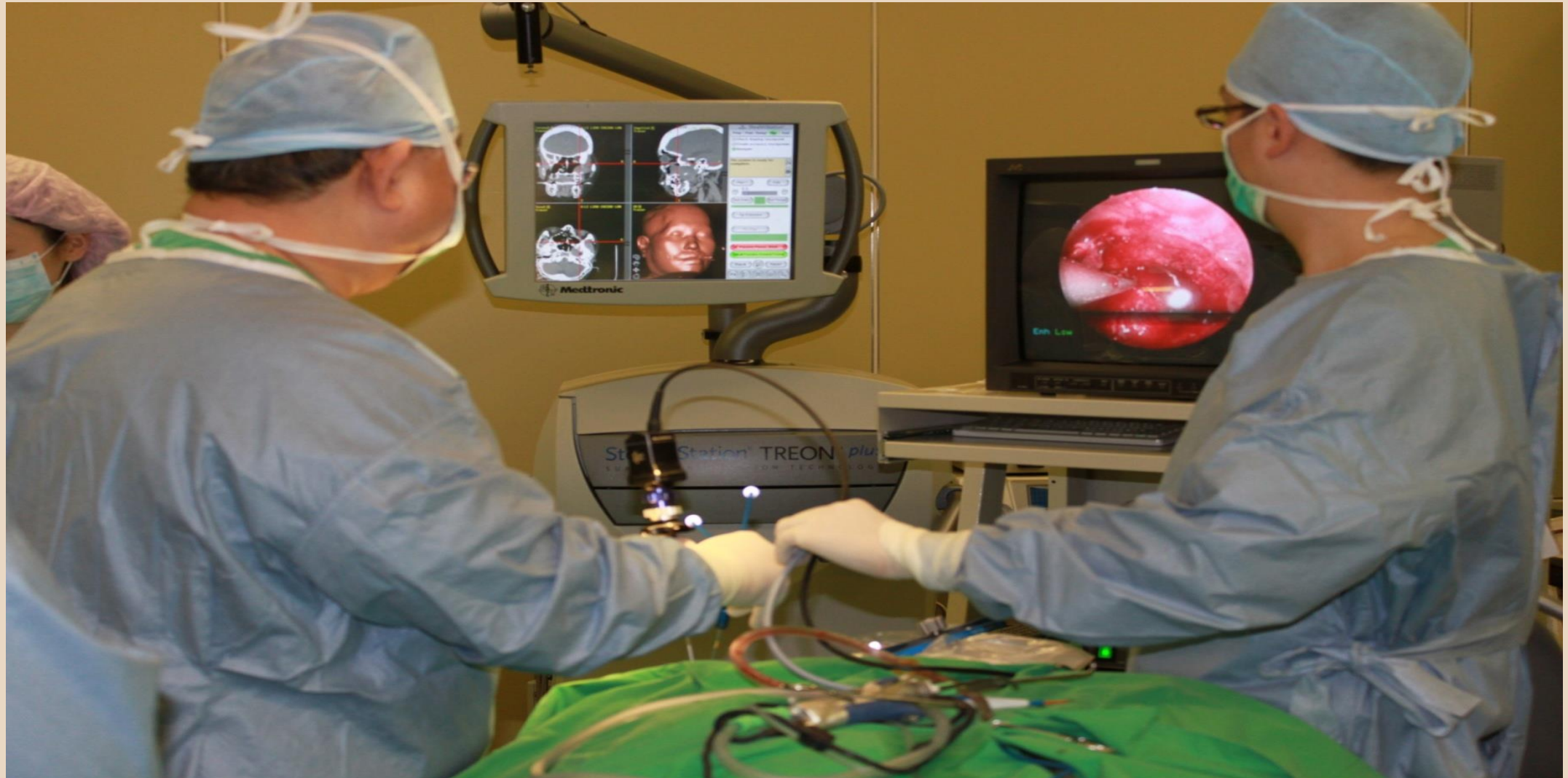





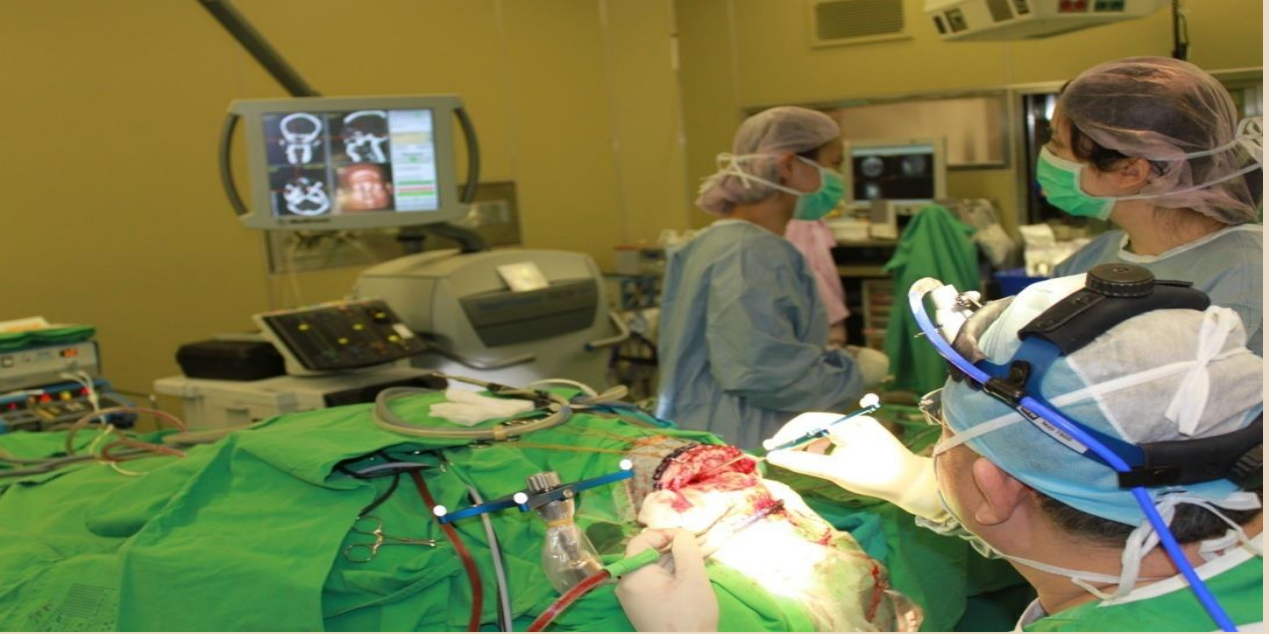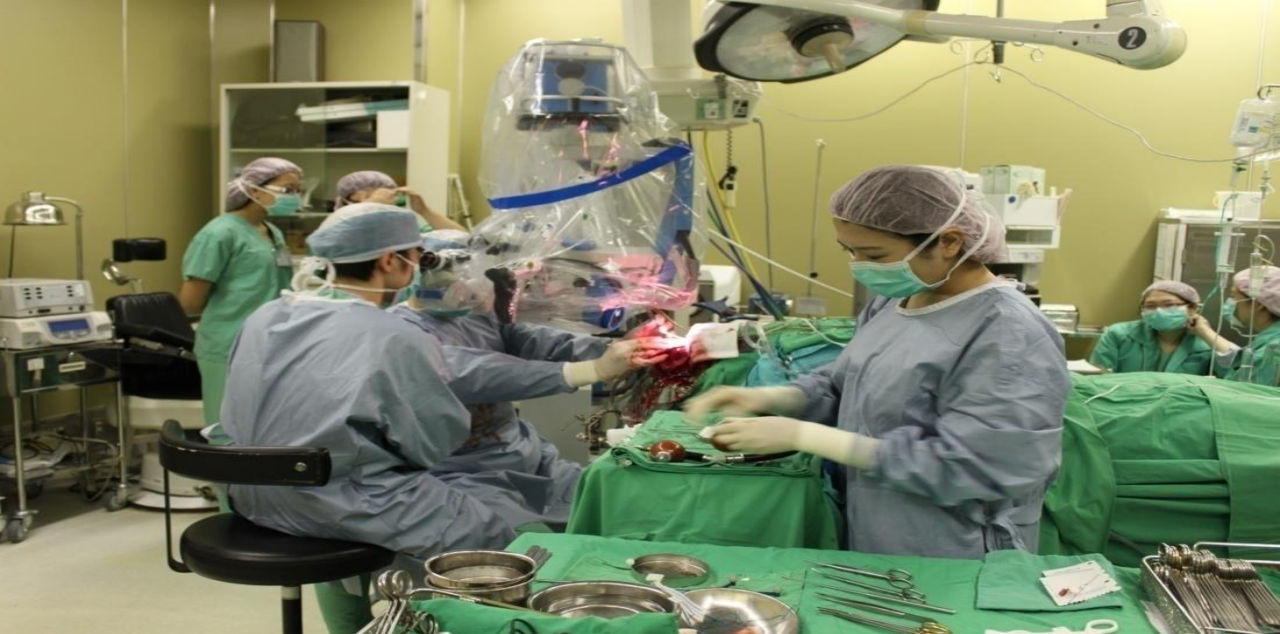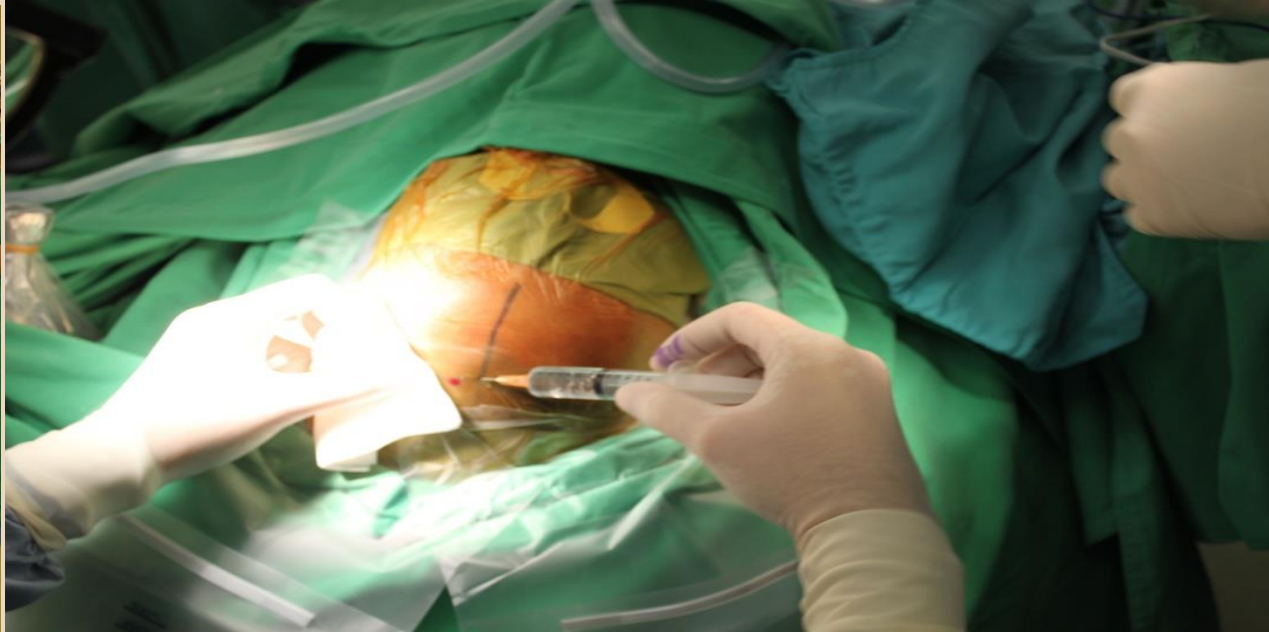


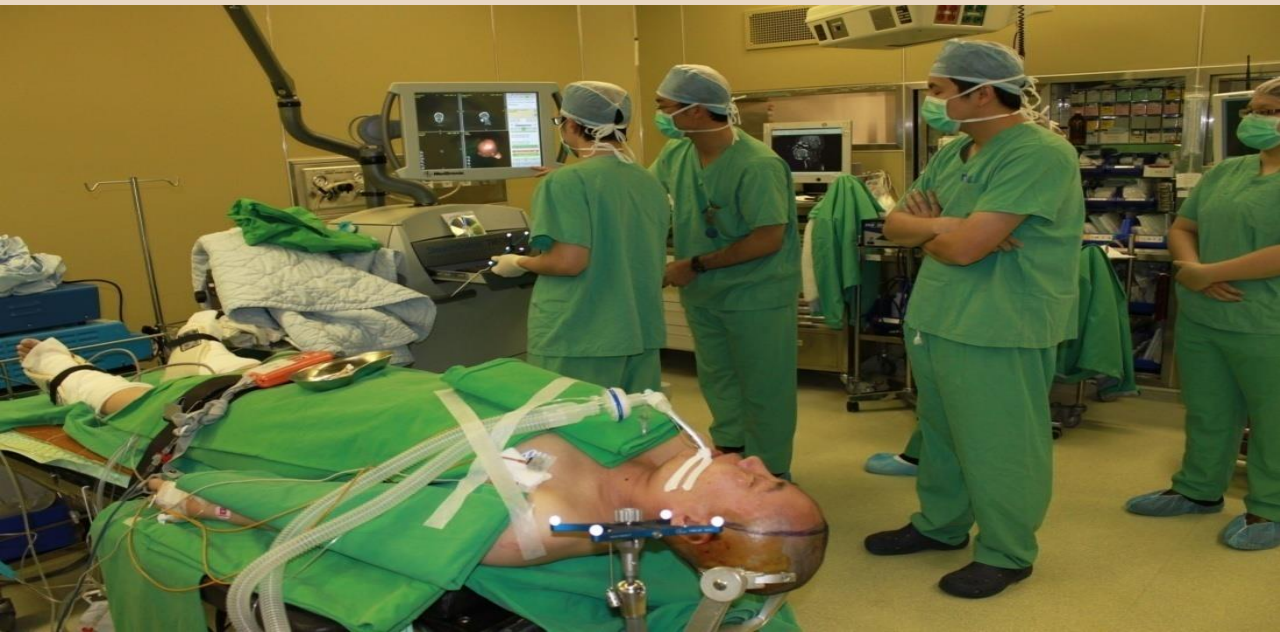# Two surgeons , Four hands technique

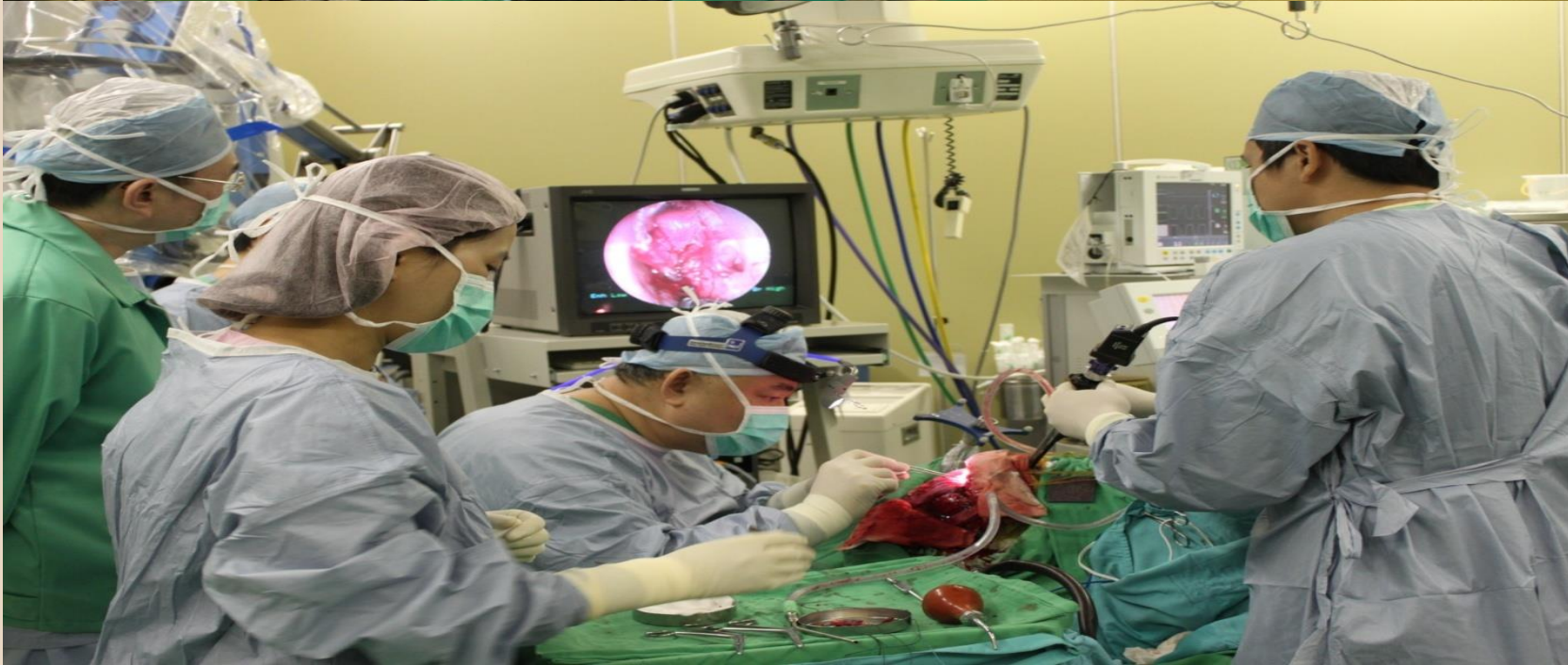
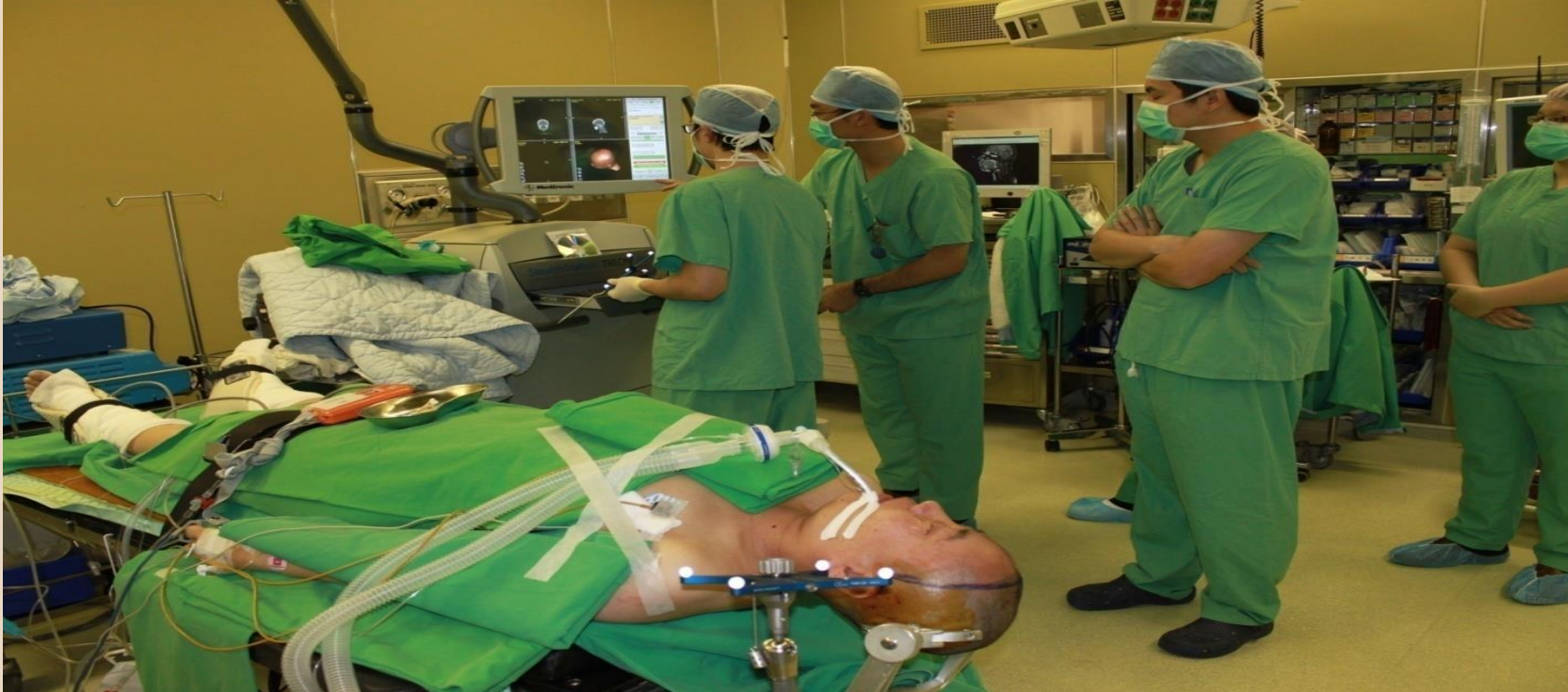
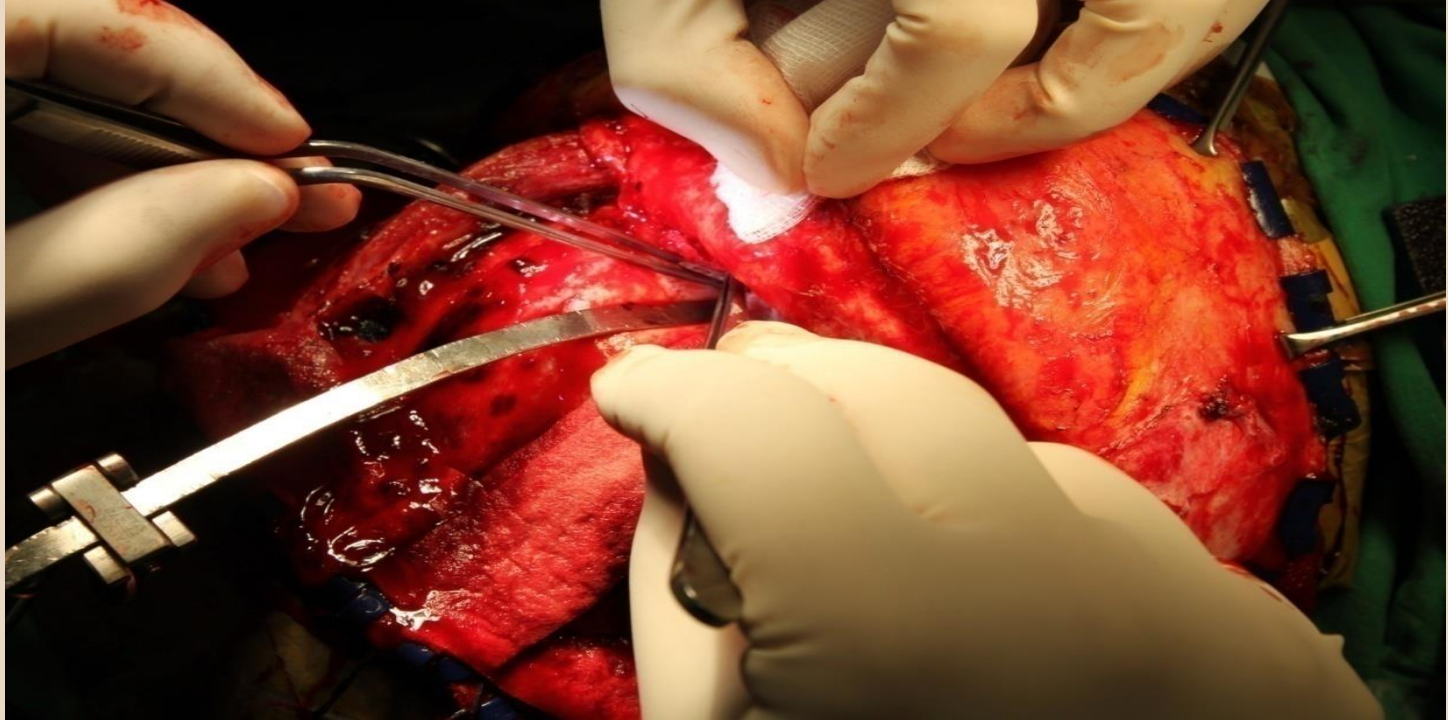
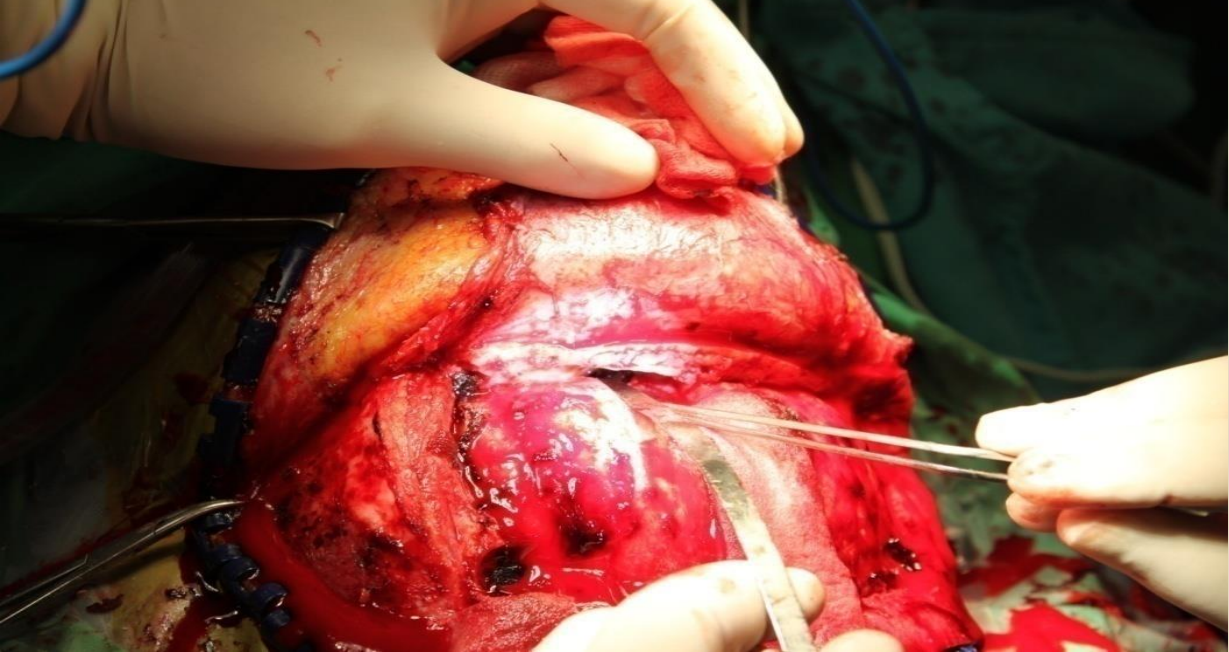
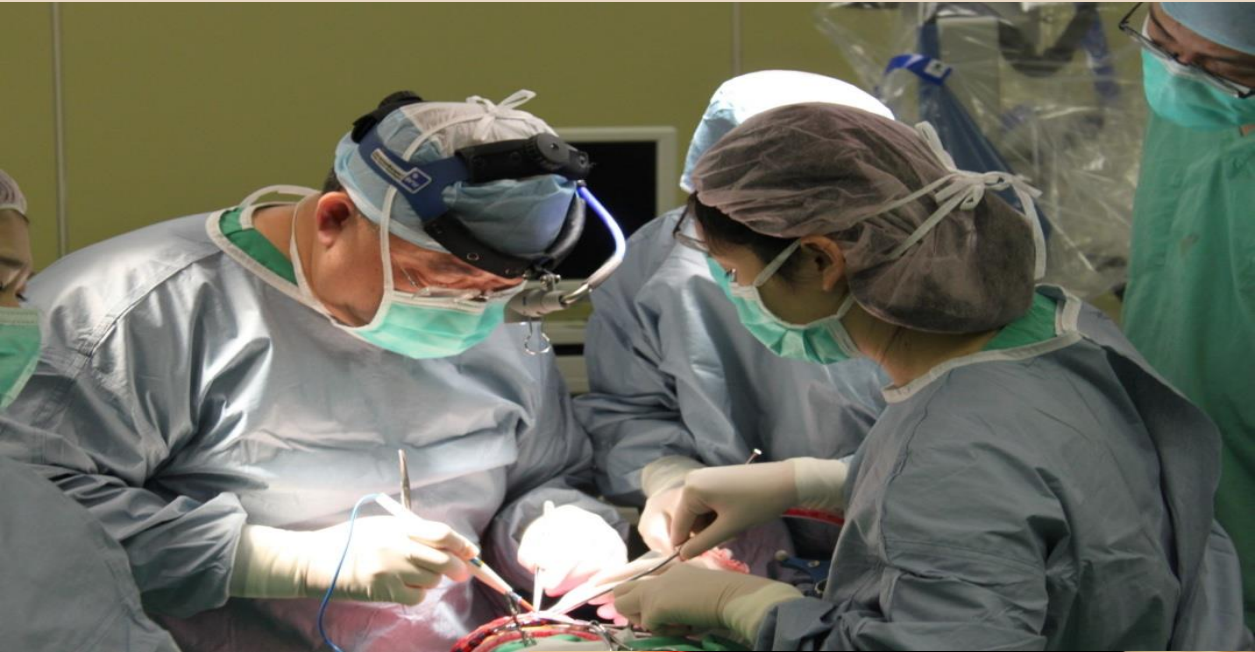# Endoscopic Approach

- Still evolving, indication, technique, instrument
- Two surgeons, four hands technique
- Justified for malignancy?
- CSF leak management?









Thank you

# Results

	Endoscopic 5/11 (45.5%)	Microscopic 6/11 (54.5%)	p value
Age	57	47	0.819
Gender (M:F)	3:2	4:2	0.358
Sellar: Parasellar	4:1	5:1	0.887
<b>Op Bleeding</b>	205 ml	333 ml	0.358
<b>Op Time</b>	205 min	233 min	0.216

# Results

	Endoscopic	Microscopic	P value
CSF leakage	0/5 (0%)	1/6 (16.7%)	0.338
CNS infection	0/5 (0%)	1/6 (16.7%)	0.338
<b>ICU course</b> (Day)	1.4	1.5	0.740

# Transcranial Resection of Olfactory Neuroblastoma

*Skull Base 2005 ; 15:163-71*

*Wang CC, Chen YL, Hsu YS, Jung SM, Hao SP*

- Transcranial approach & Resection
- Sinoscopic assistance
- Galeopericranial flap reconstruction

# Surgery

- **Approach**

- Frontal craniotomy
- Orbital bar osteotomy

- **Resection**

- En bloc
- Piecemeal

- **Reconstruction**

- Galeopericranial flap