


OTOIMMUNOLOGY
To-day
Experiments of nature



Utrecht University

Em. Prof. Dr. Jan E. Veldman



Universiteit Utrecht

Diseases with immunological features

- ★ Connective tissue diseases
- ★ Hematological diseases
- ★ Endocrine and associated organ diseases
- ★ Non-endocrine organ diseases

Where Autoimmunity May Strike

DISEASE

Addison's disease

Autoimmune hemolytic anemia

Crohn's disease

Goodpasture's syndrome

Graves' disease

Hashimoto's thyroiditis

Idiopathic thrombocytopenic purpura

Insulin-dependent diabetes mellitus

Multiple sclerosis

Myasthenia gravis

Pemphigus vulgaris

Pernicious anemia

Poststreptococcal glomerulonephritis

Psoriasis

Rheumatoid arthritis

Scleroderma

Sjögren's syndrome

Spontaneous infertility

Systemic lupus erythematosus

TARGET

Adrenal gland

Red blood cell membrane proteins

Gut

Kidney and lungs

Thyroid

Thyroid

Platelets

Pancreatic beta cells

Brain and spinal cord

Nerve/muscle synapses

Skin

Gastric parietal cells

Kidney

Skin

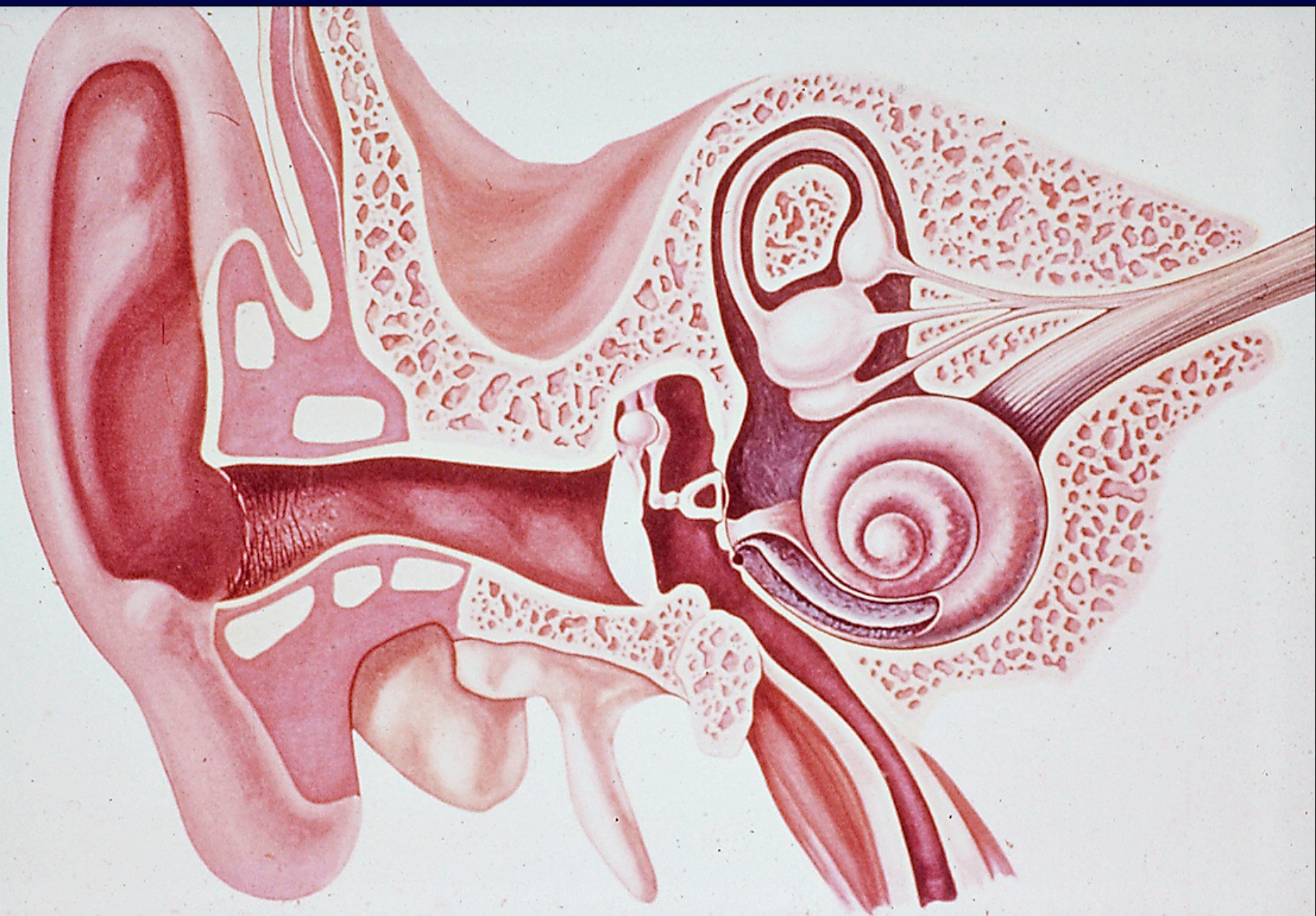
Connective tissue

Heart, lungs, gut, kidney

Liver, kidney, brain, thyroid,
salivary gland

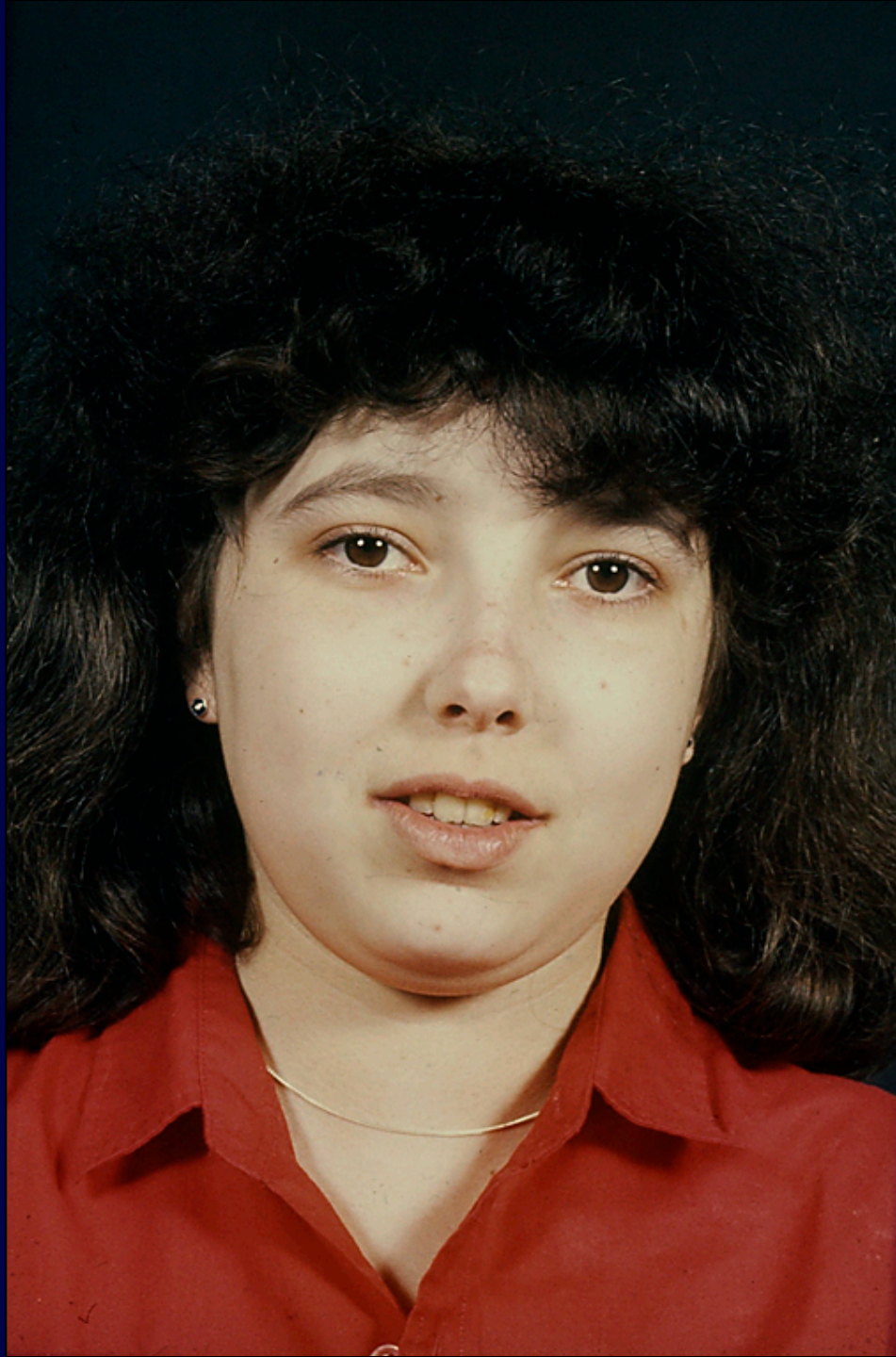Sperm

DNA, platelets, other tissues



Inner ear complex

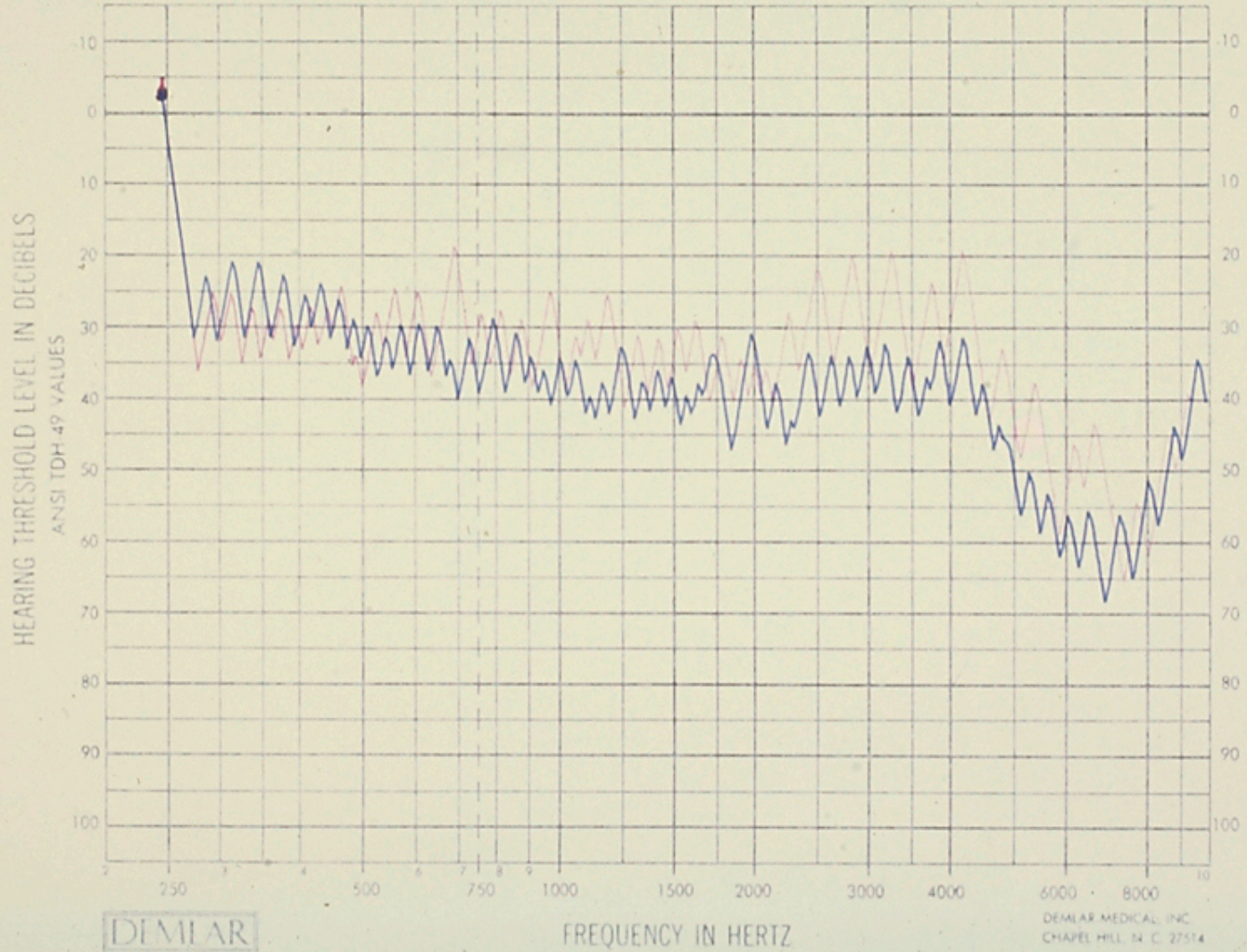
- Immune reactivity
- Organ specific autoimmunity ?
- ★ General. autoimmune disease



Immune-mediated ... Autoimmune SNHL SNHL

LEFT		RIGHT		SPEED		TYPE		PAD		TRAVEL	
LEFT	RIGHT	FAST	•	CONT	•	+ 20 dB				FWD	•
	•	SLOW		FUSED	•	OUT	•			REV	
				LOT		- 20 dB					

NAME Jacq Mehallawi
 NUMBER _____ SEX _____ AGE 3.6.68
 DATE 3.6.82 TIME _____
 BY: Masonet



DELMAR

DELMAR MEDICAL, INC.
CHAPEL HILL, N. C. 27514

General. Autoimmune disease

.

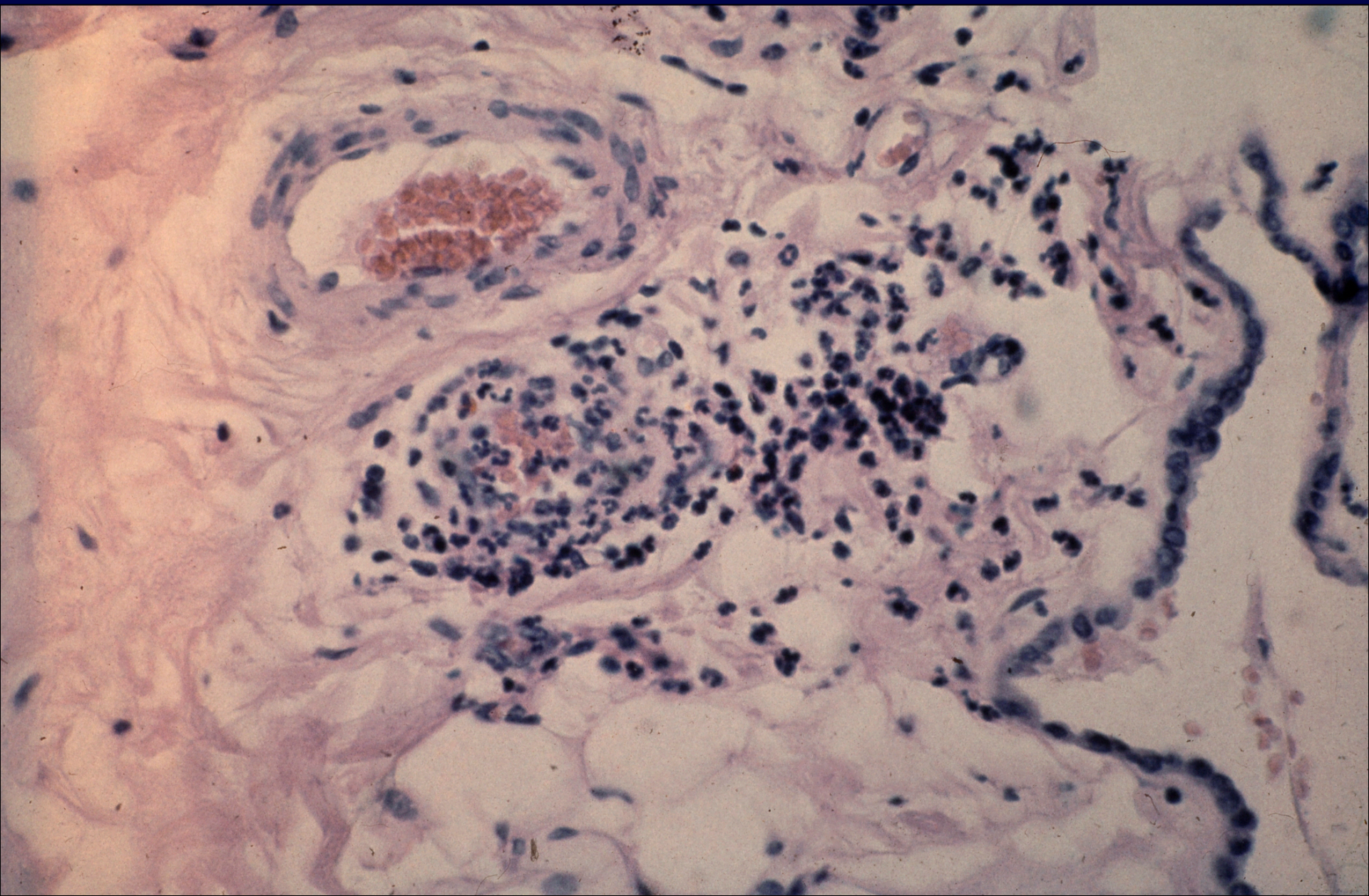
.

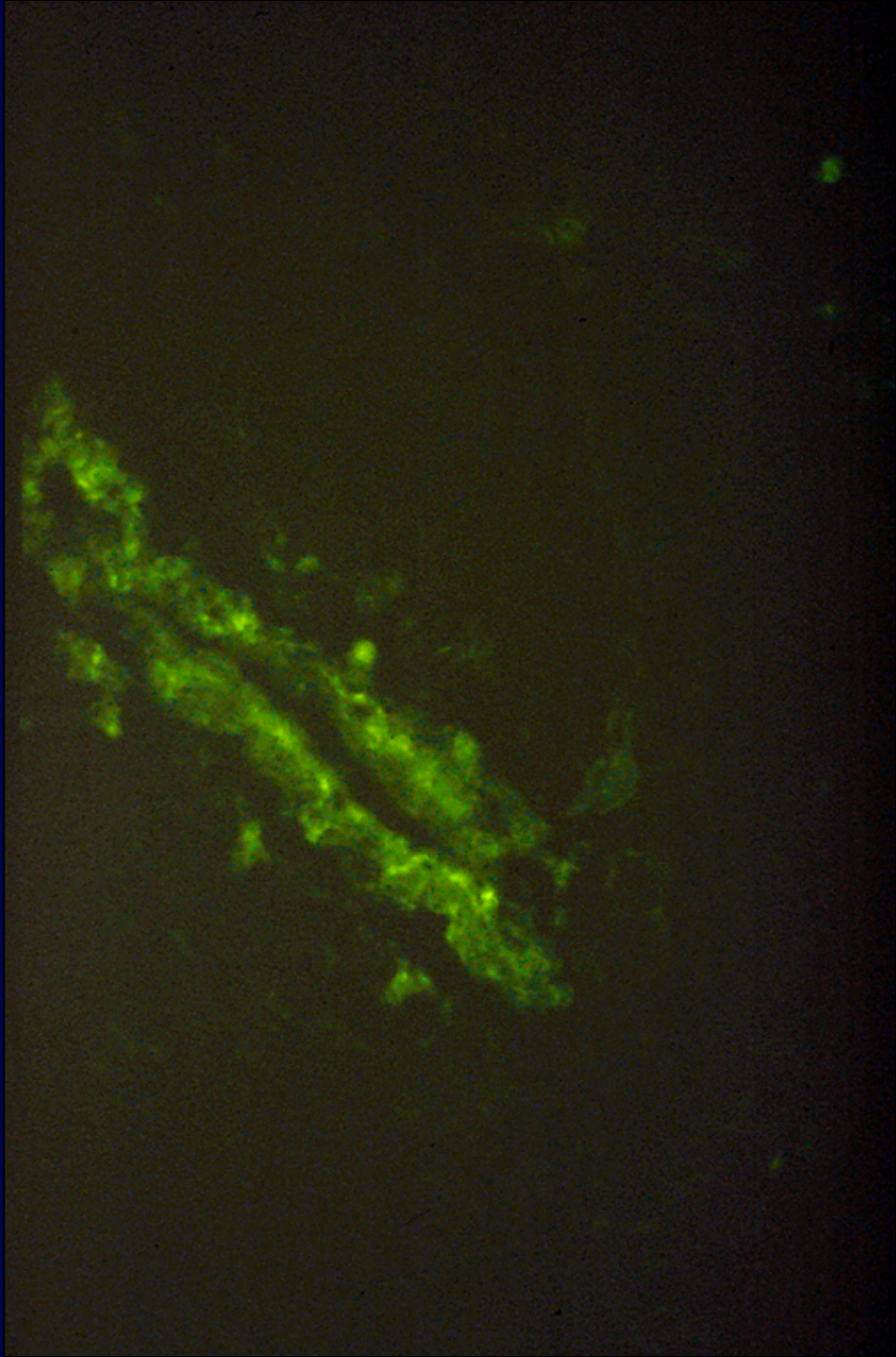
vasculitis

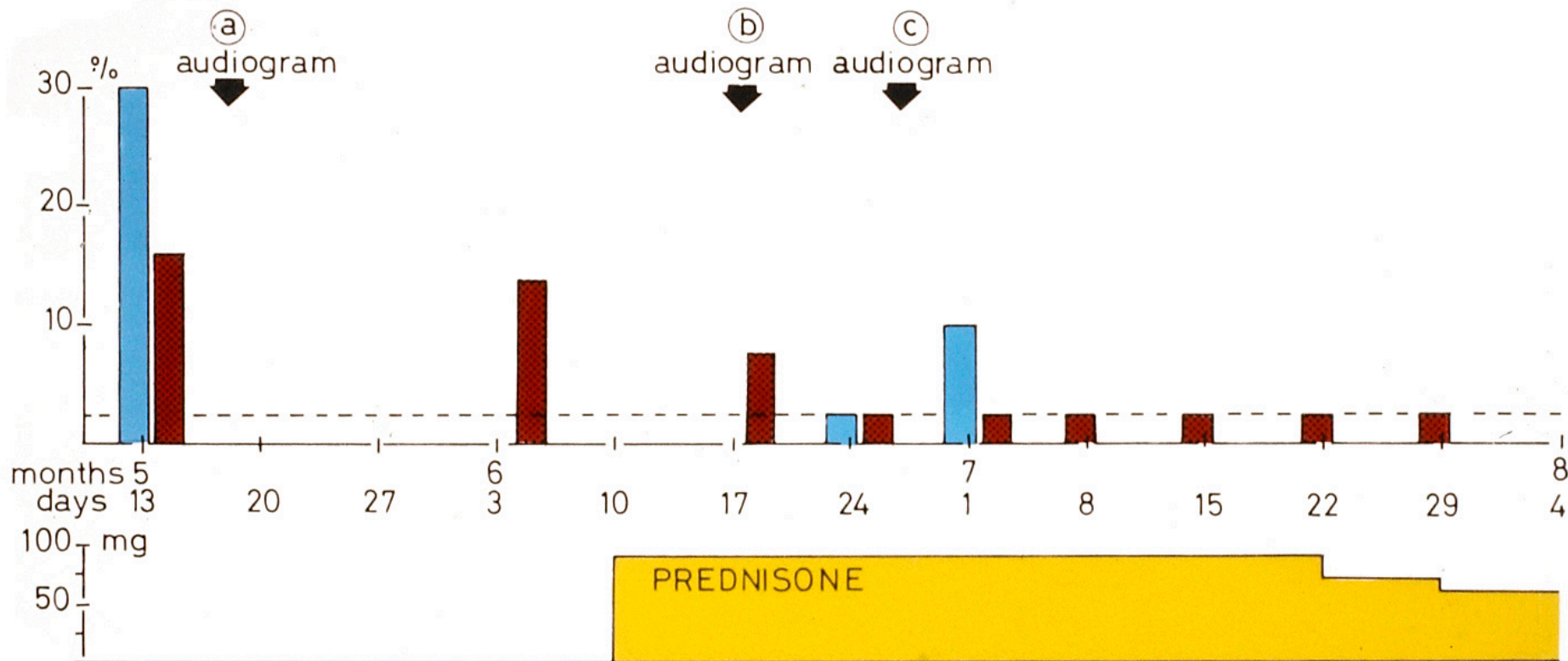
Immune complexes

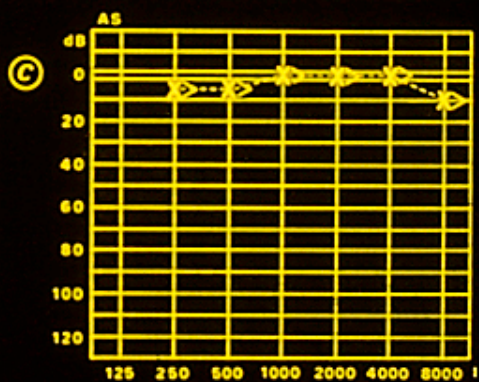
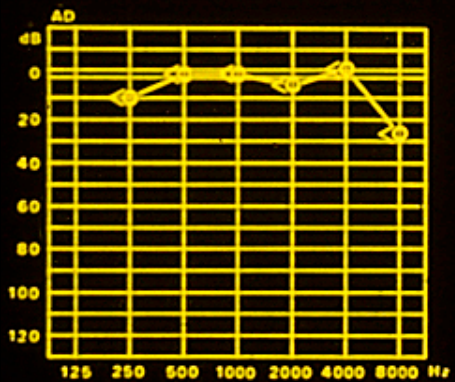
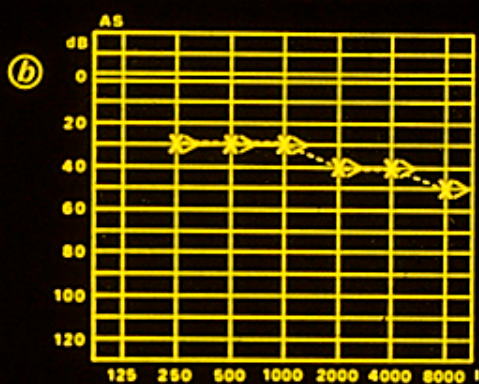
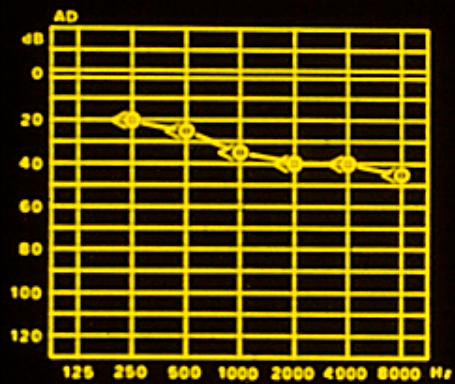
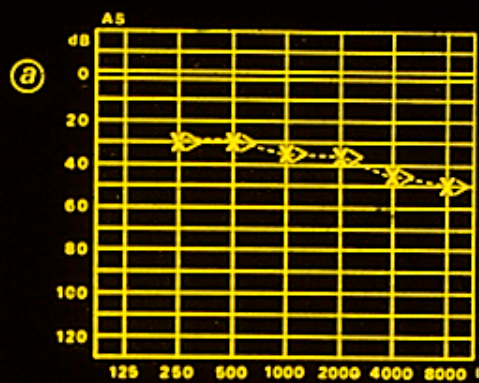
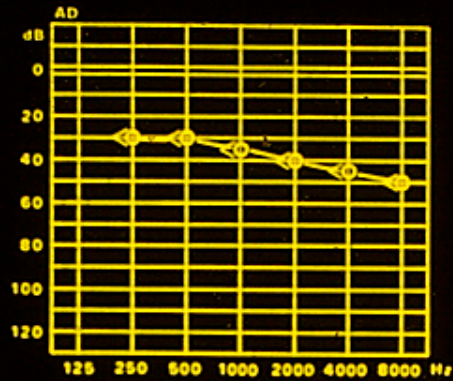
and

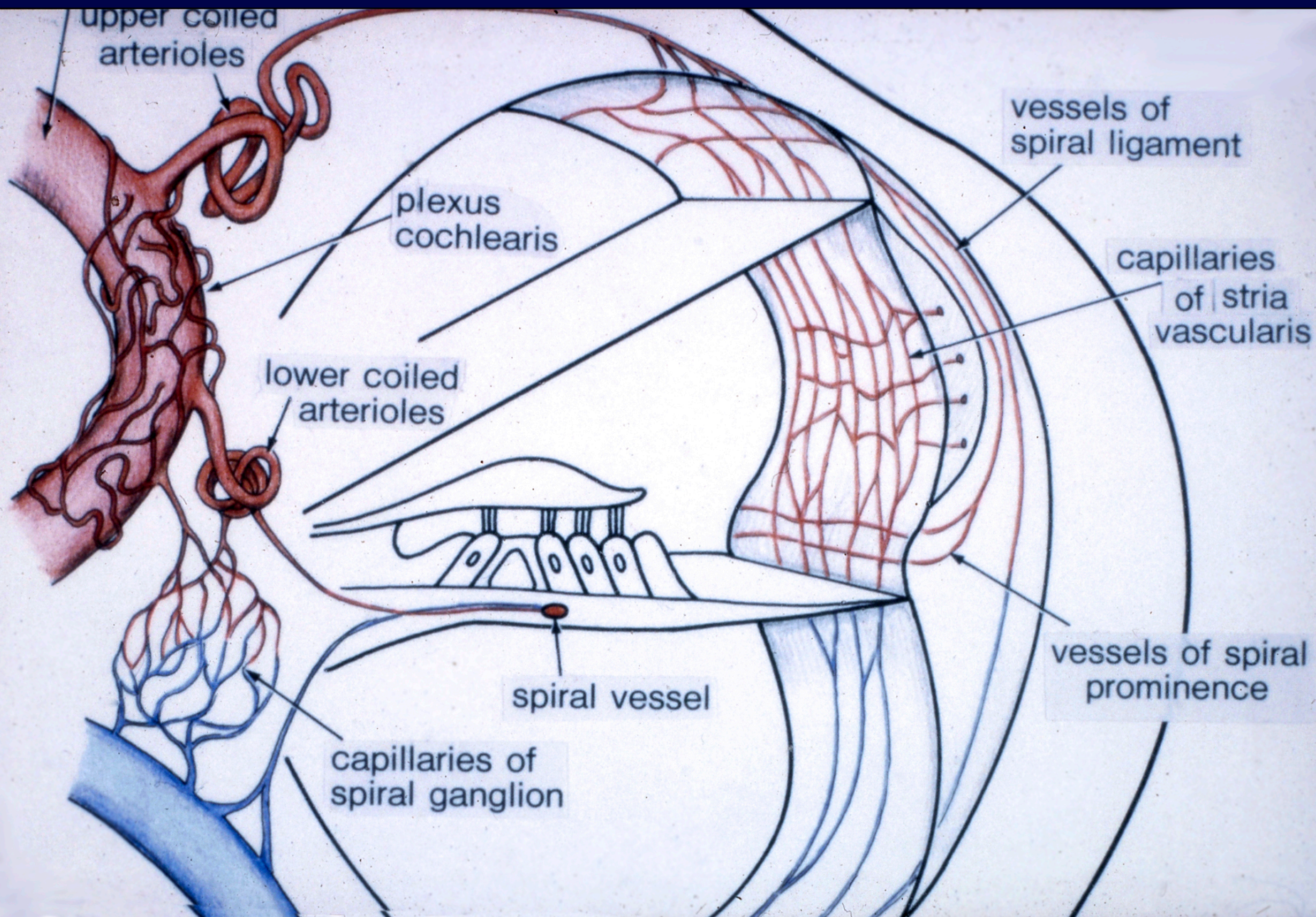
Sensorineural hearing loss







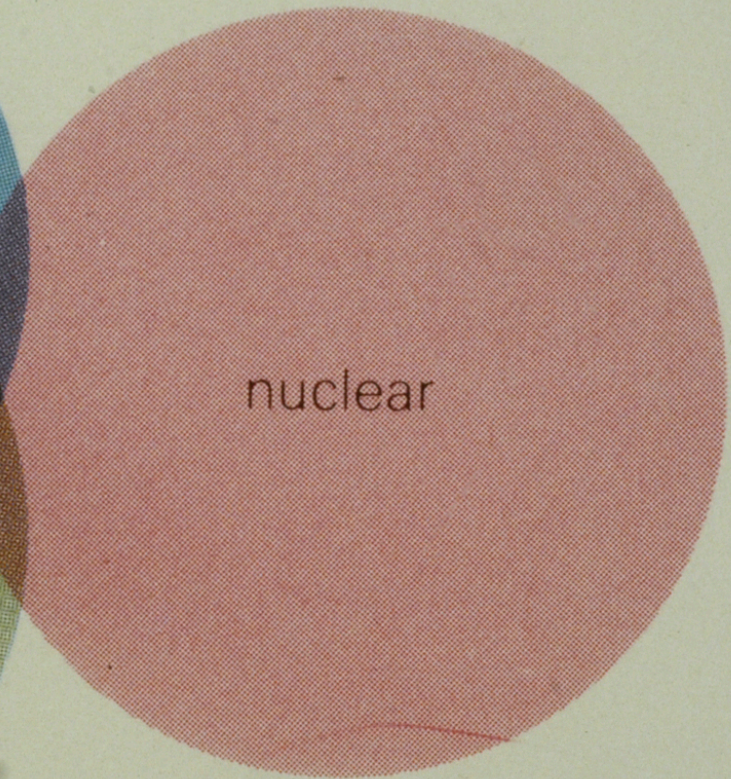
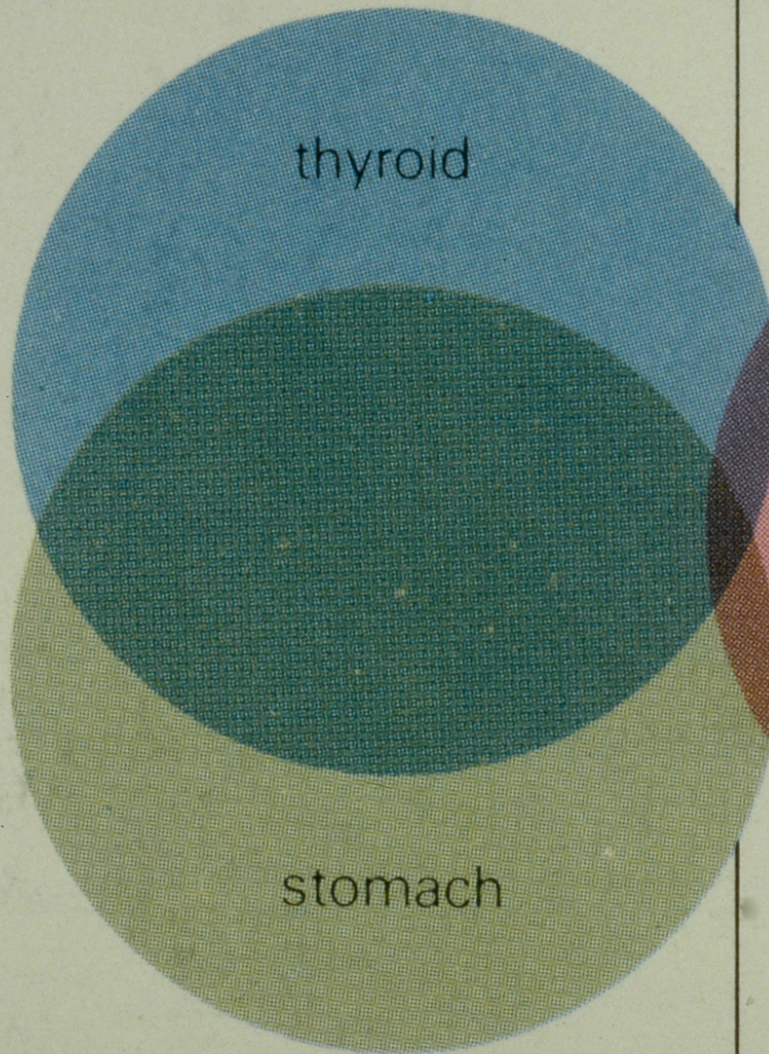





DIAGNOSTIC AND THERAPEUTIC DILEMMAS

**organ specific
antibodies**


**non-organ specific
antibodies**



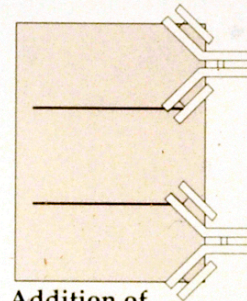
Immunoblotting



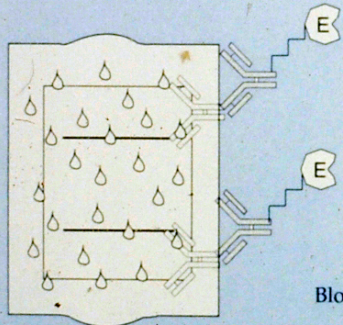
Electrophoresis



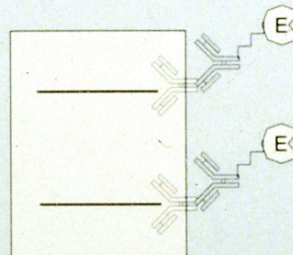
Blot Transfer



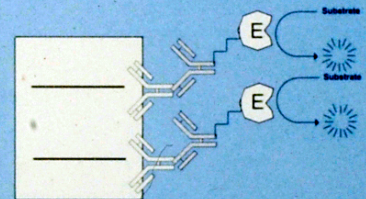
Addition of
Primary Antibody



Blocking and Washing



Indirect immunodetection complex



Detection with Substrate

IgG

A B C D E

kD


84-

47-

33-

24-

16-



"Diseases" with immunological features in Otology and Neuro-otology

TYMPANIC MEMBRANE

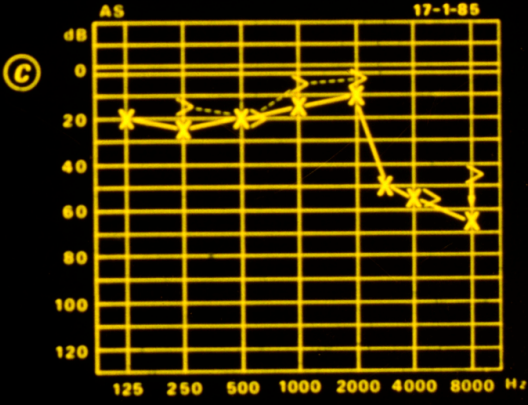
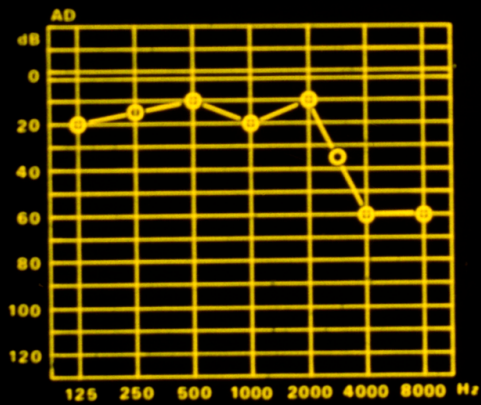
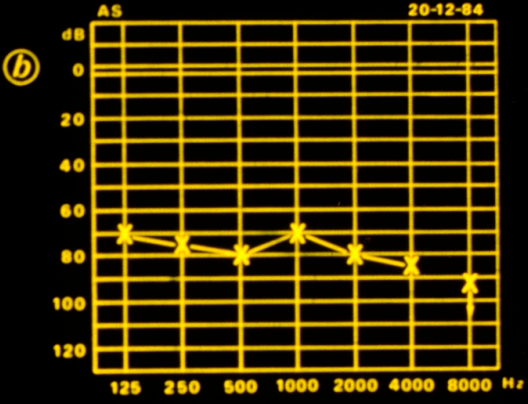
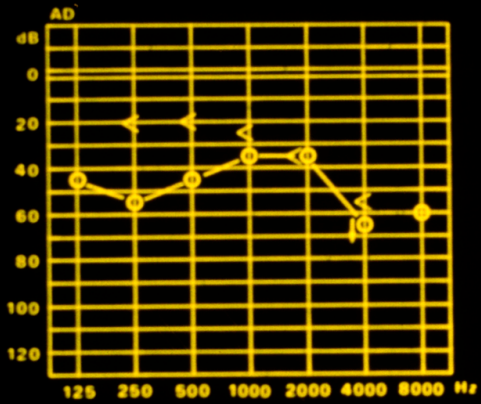
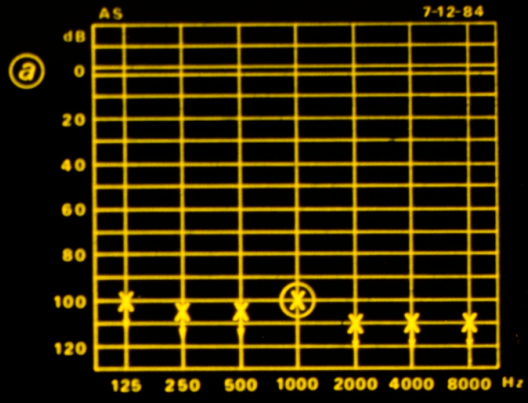
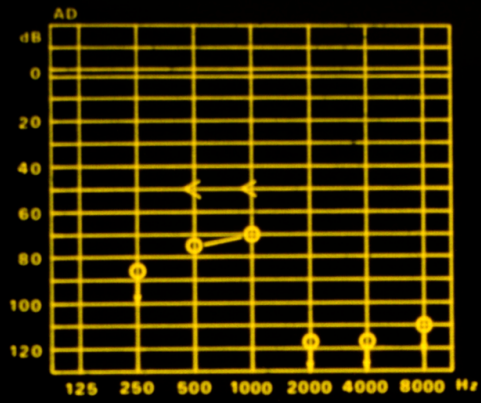
MIDDLE EAR

INNER EAR 

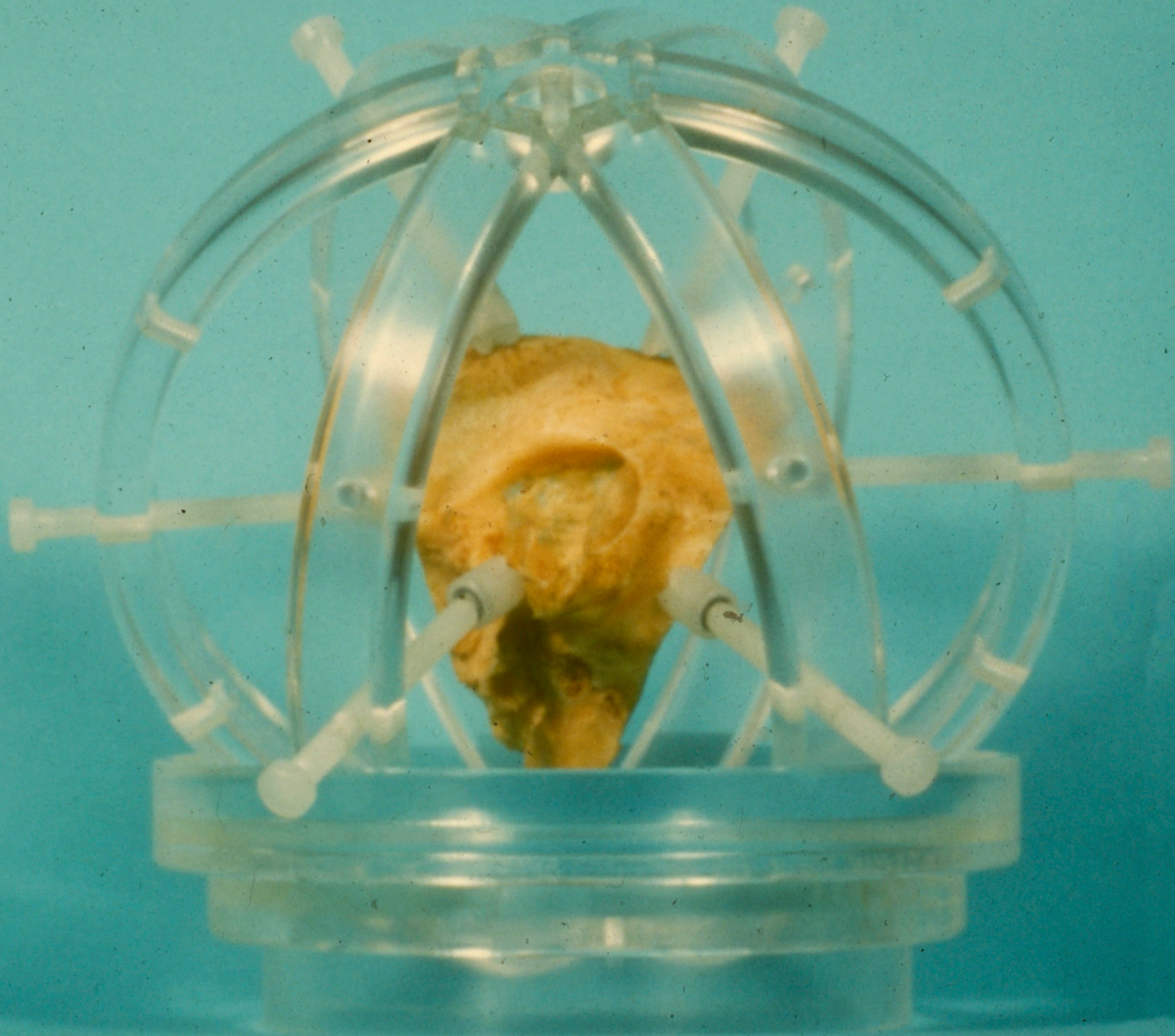
```
graph LR; A[INNER EAR] --- B[vestibular]; A --- C[cochlear]
```


RETRO-COCHLEAR

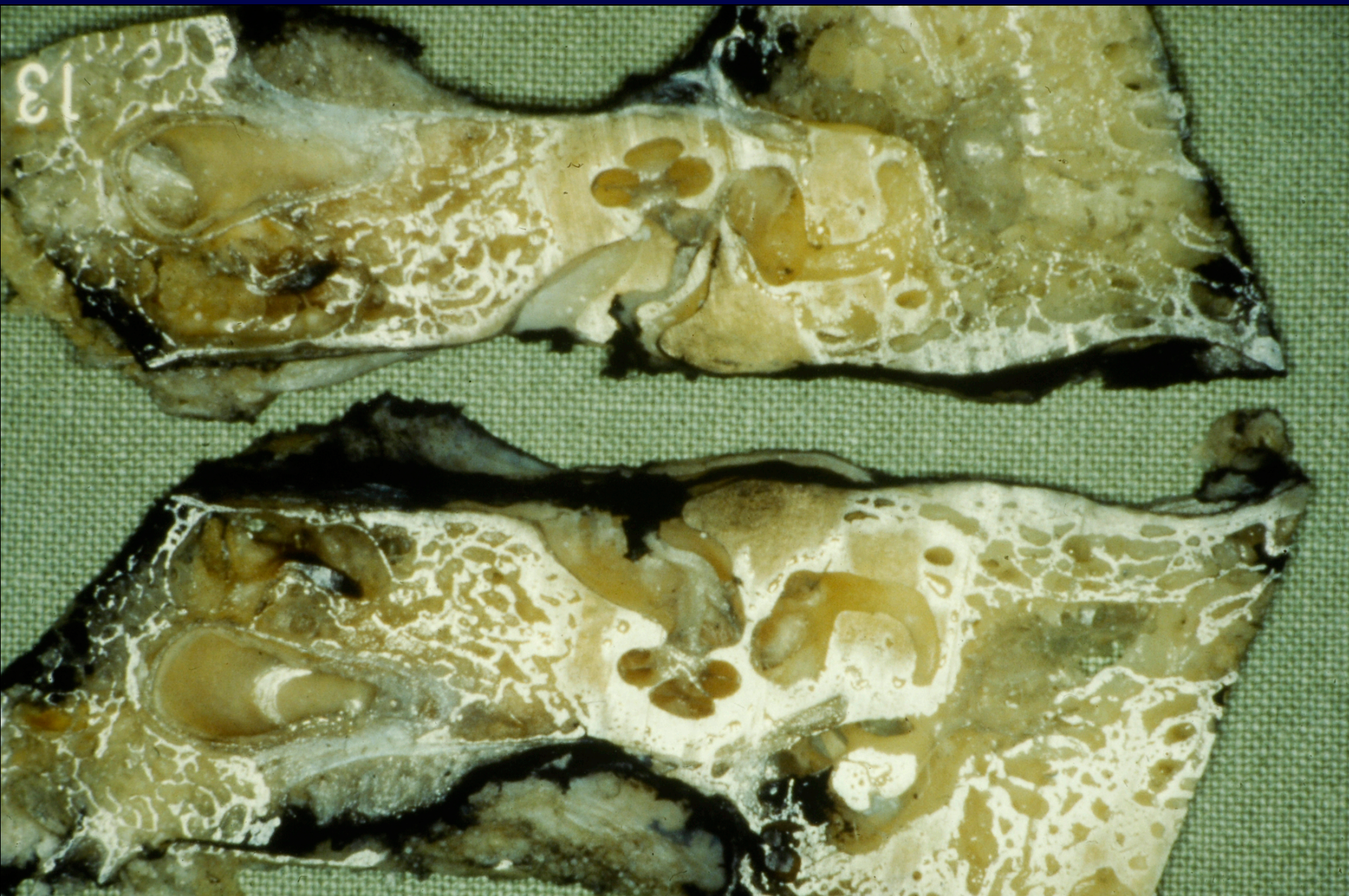
- **demyelinating diseases**






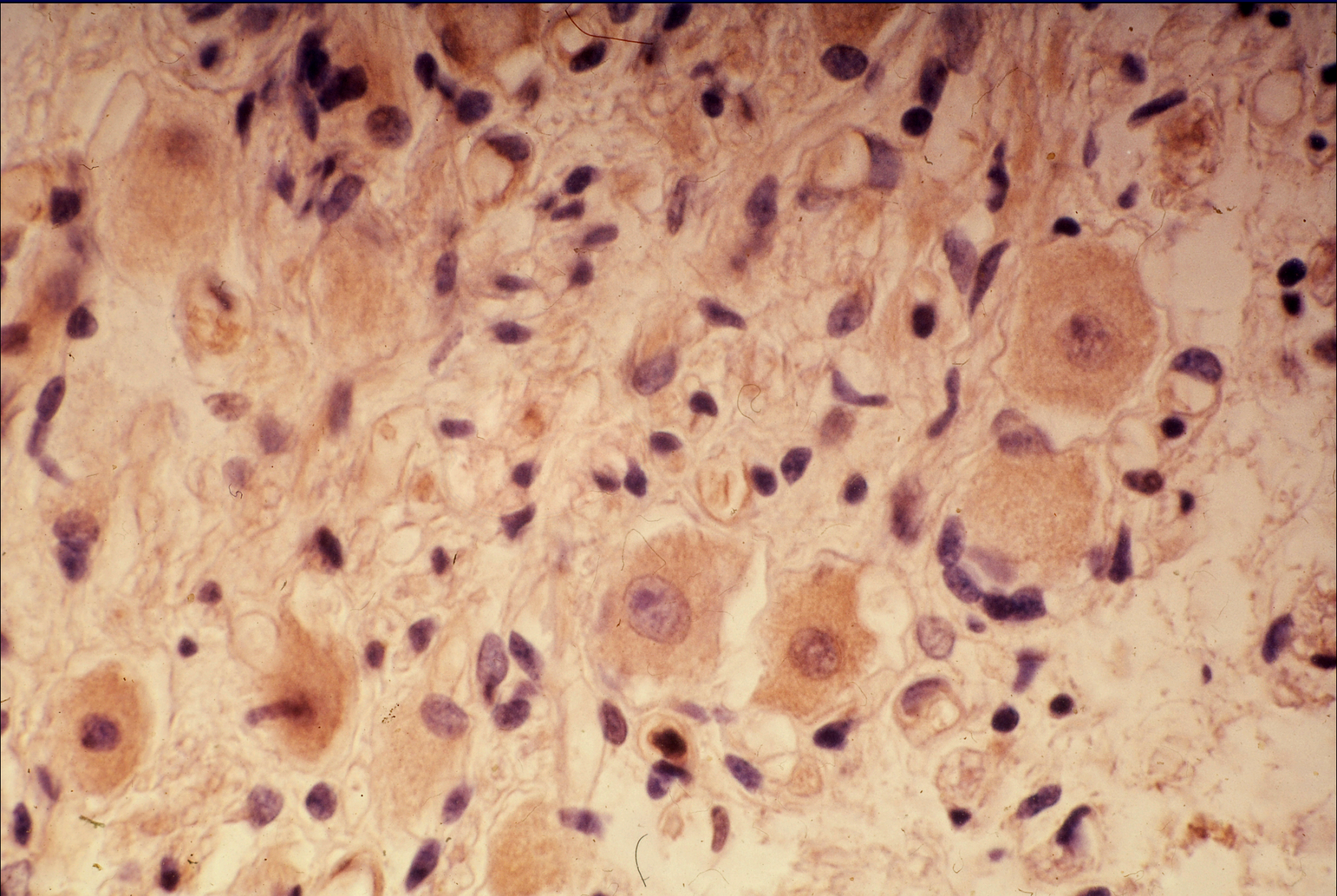


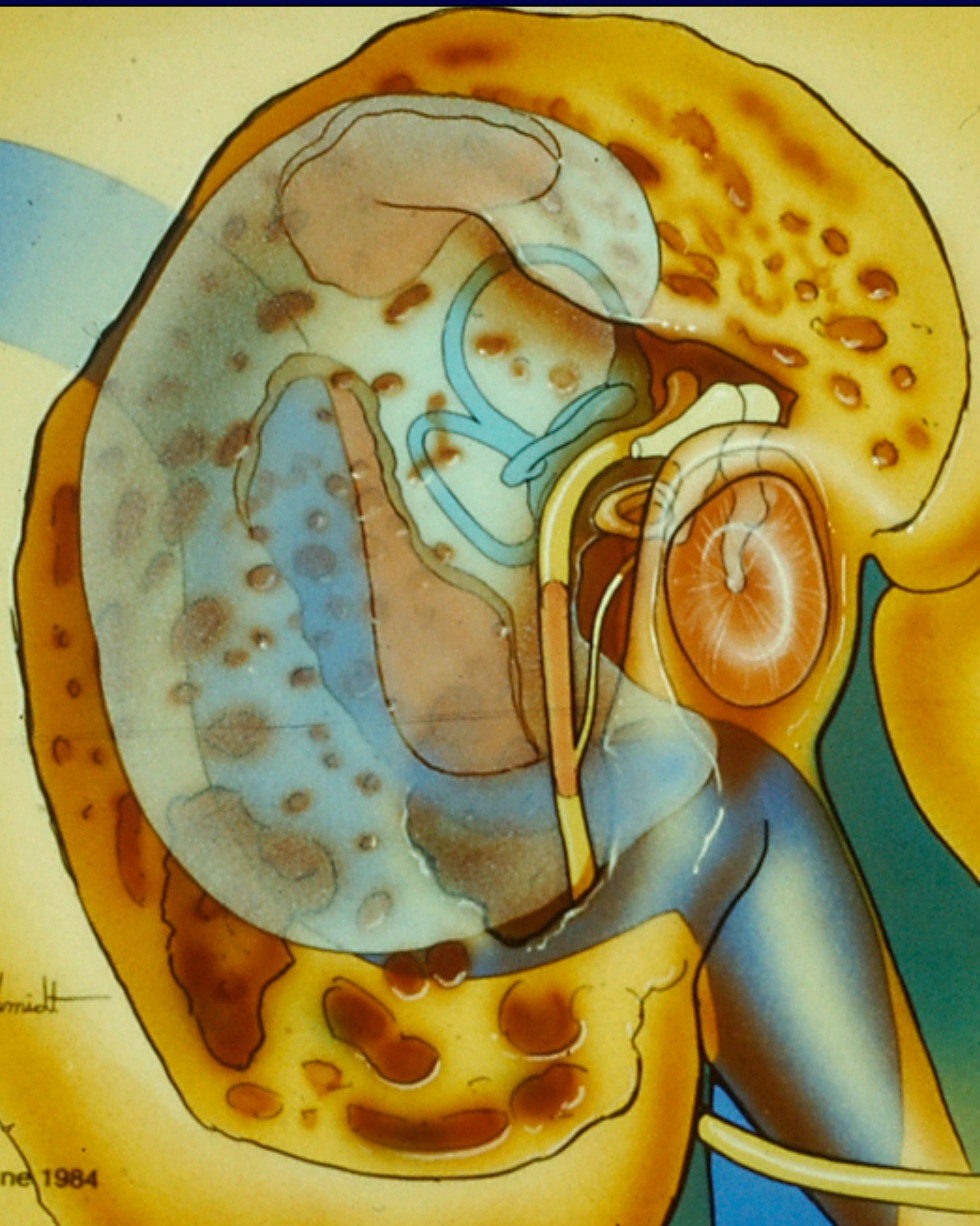



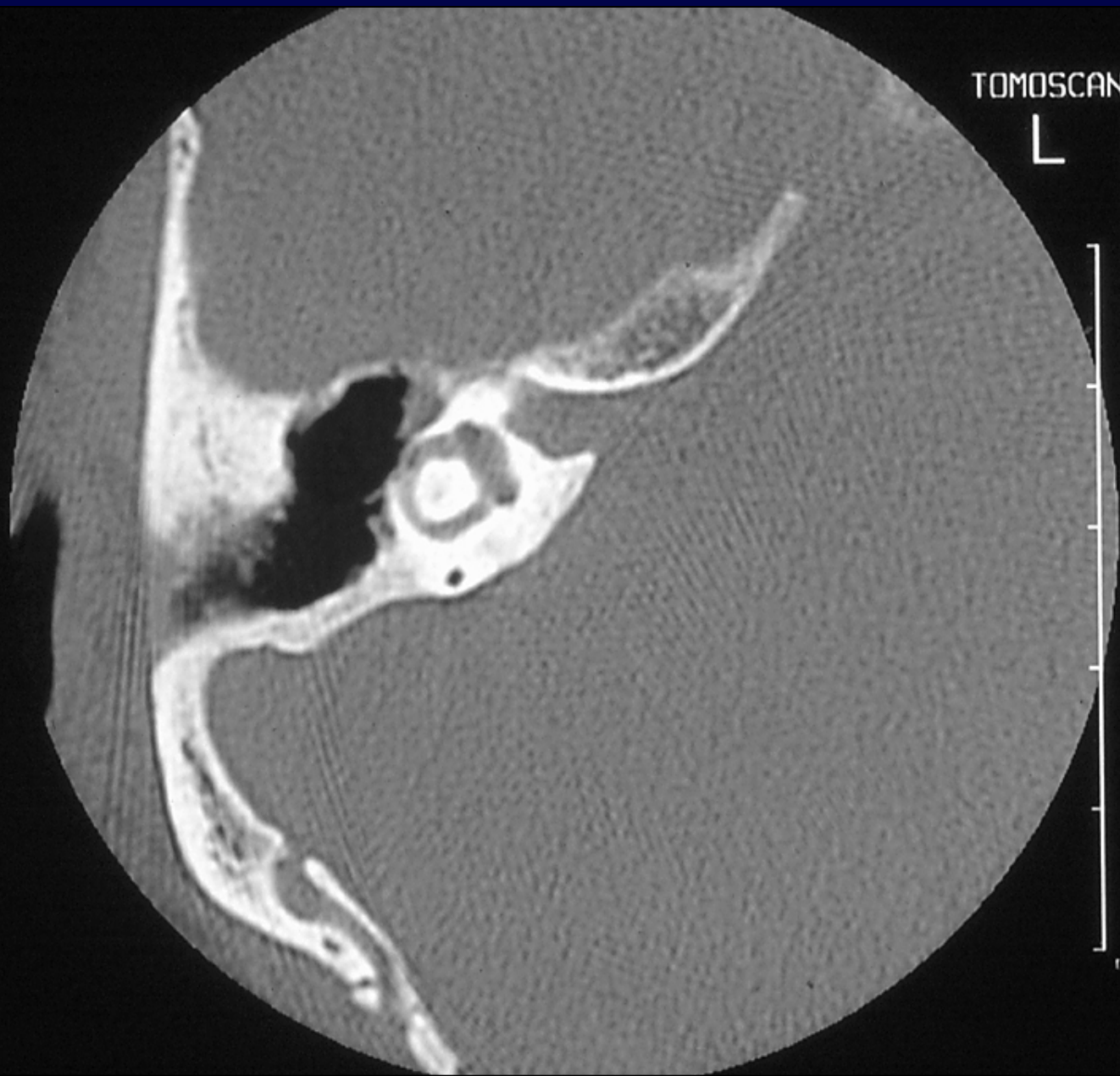








J. Schmitt

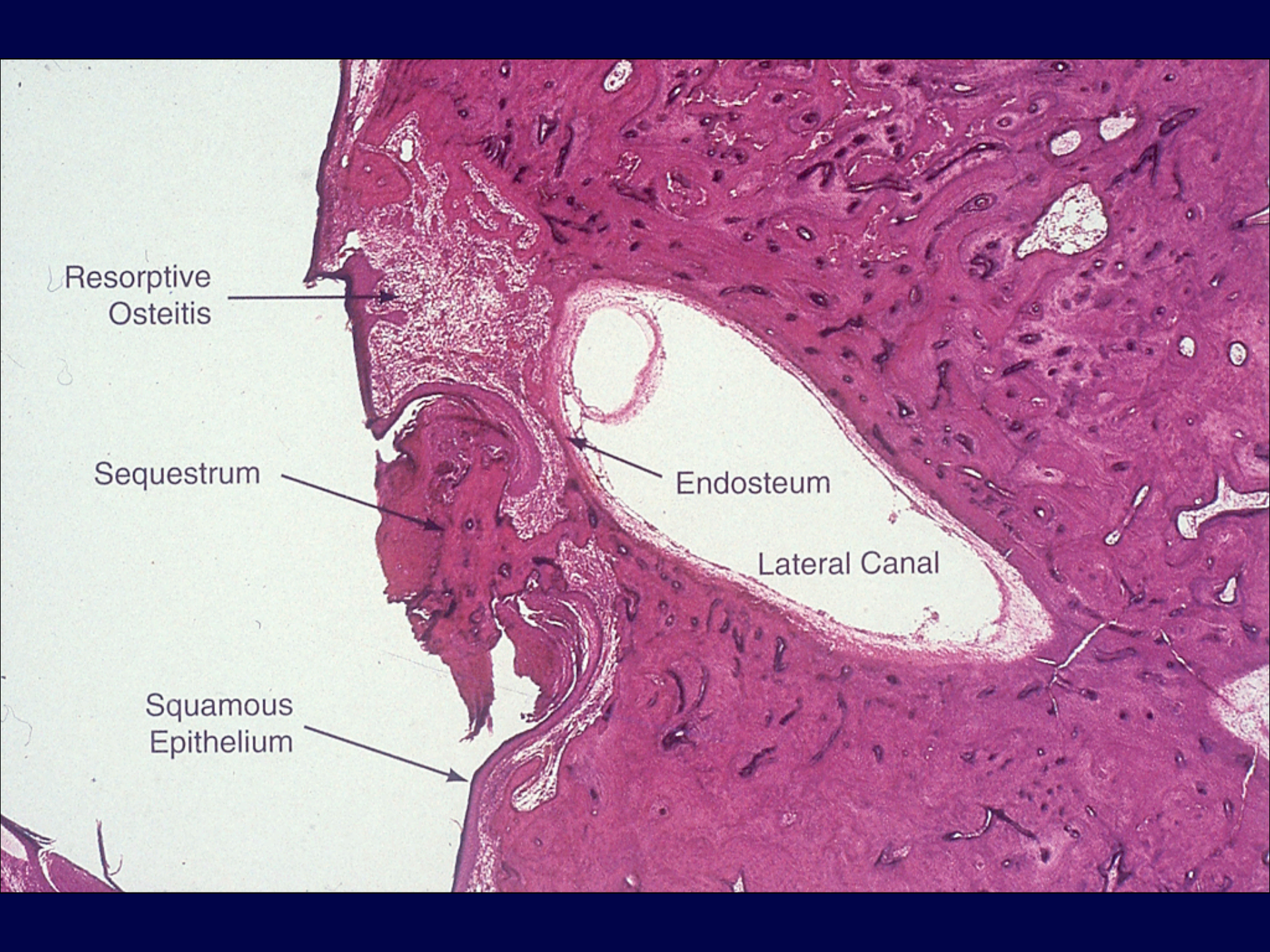
©Baylor College of Medicine 1984



TOMOSCAN

L





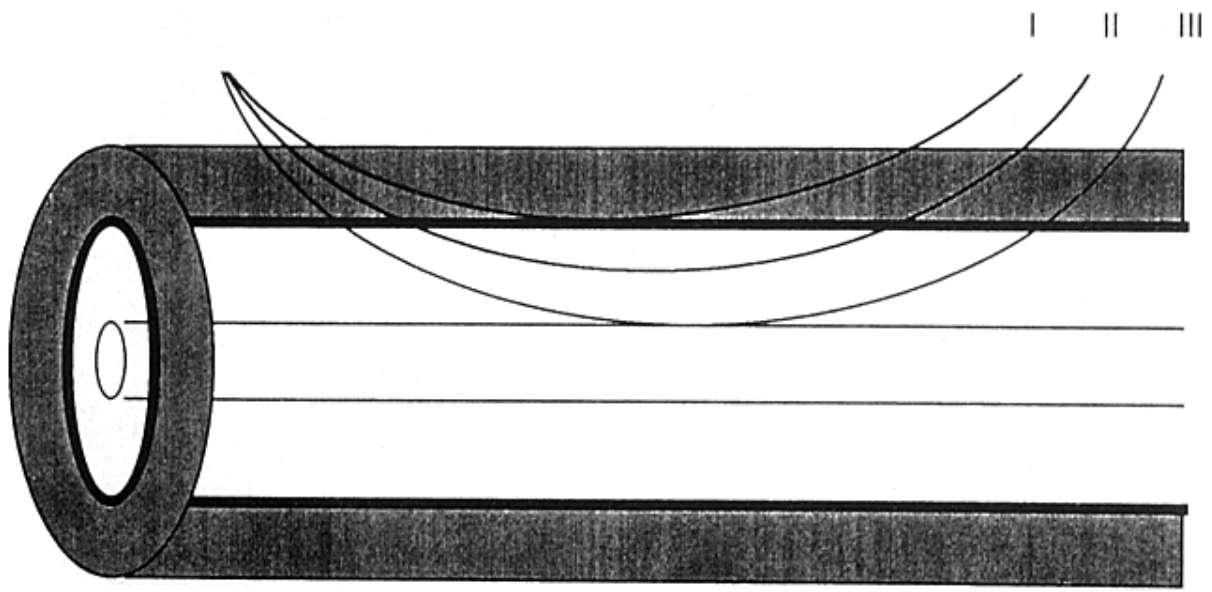
Resorptive
Osteitis

Sequestrum

Squamous
Epithelium

Endosteum

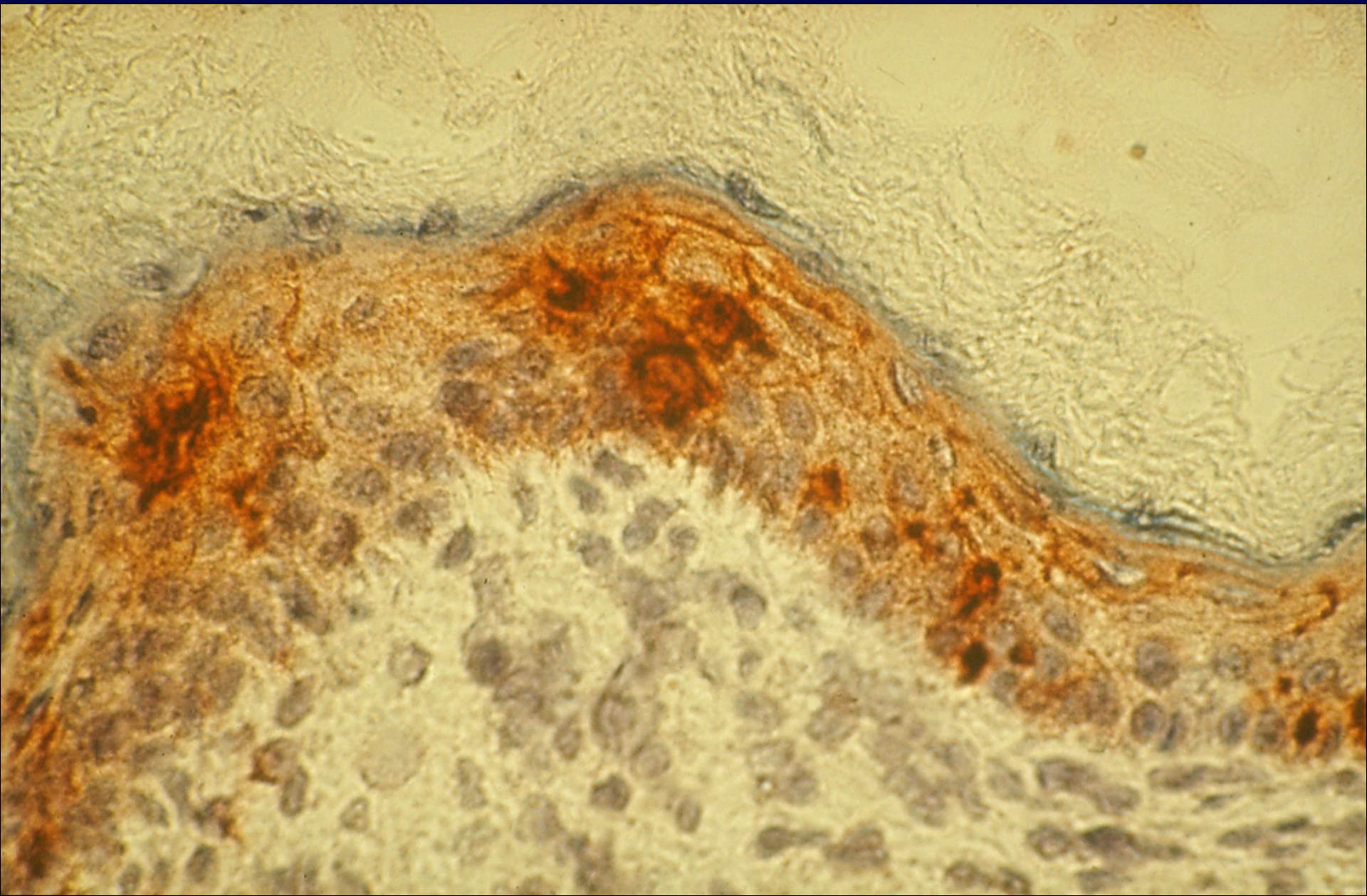
Lateral Canal

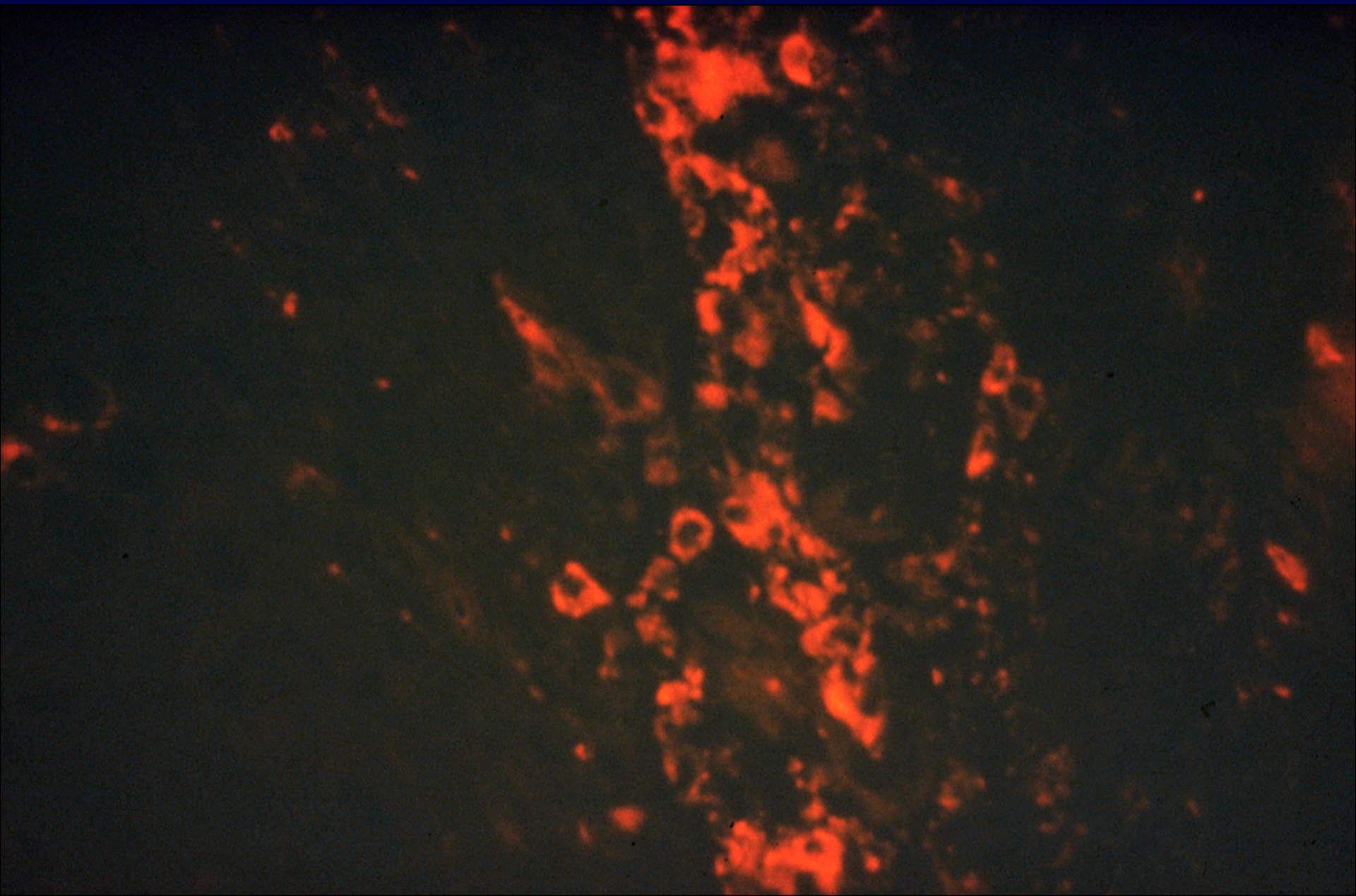


I II III

- - - - bony labyrinth
- - - - endosteum
- - - - perilymphatic space
- - - - membranous labyrinth


Serous Labyrinthitis



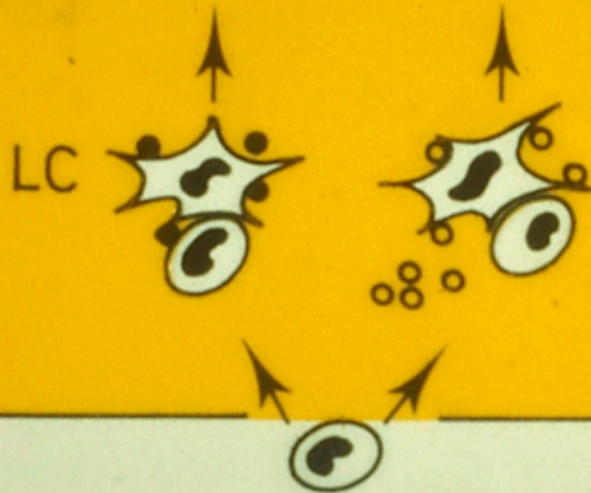


Microsurgery

Keratinization



Cholesteatoma



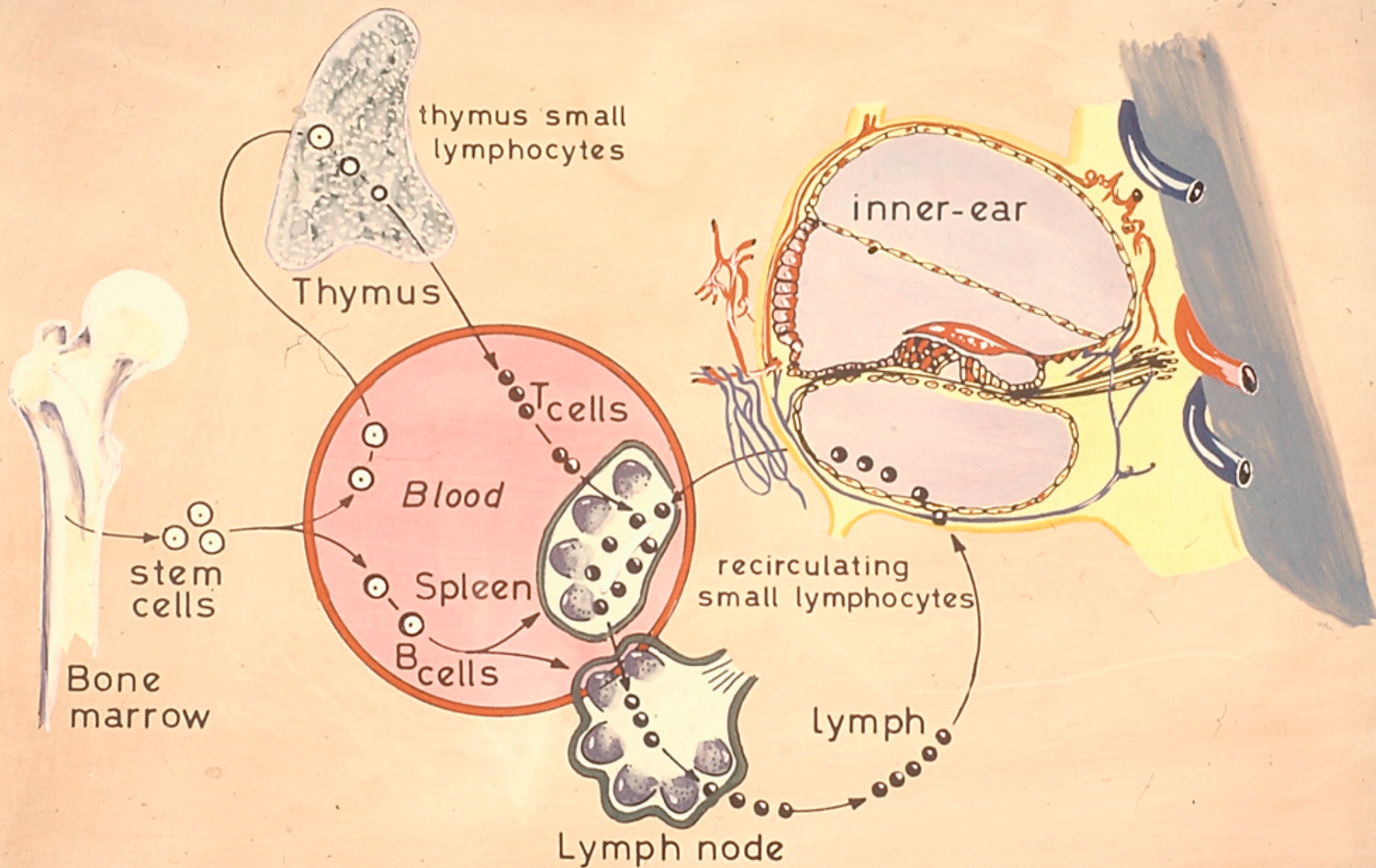
Apposition

Lymphokine secretion

enzyme release

bone erosion

T-cell (Ag. or hapten, - cholesteatoma specific)
+ memory



6 weeks

- **mod. radical AS**
- **disease-free ear**
- **fistula closed**

"Serous Labyrinthitis"

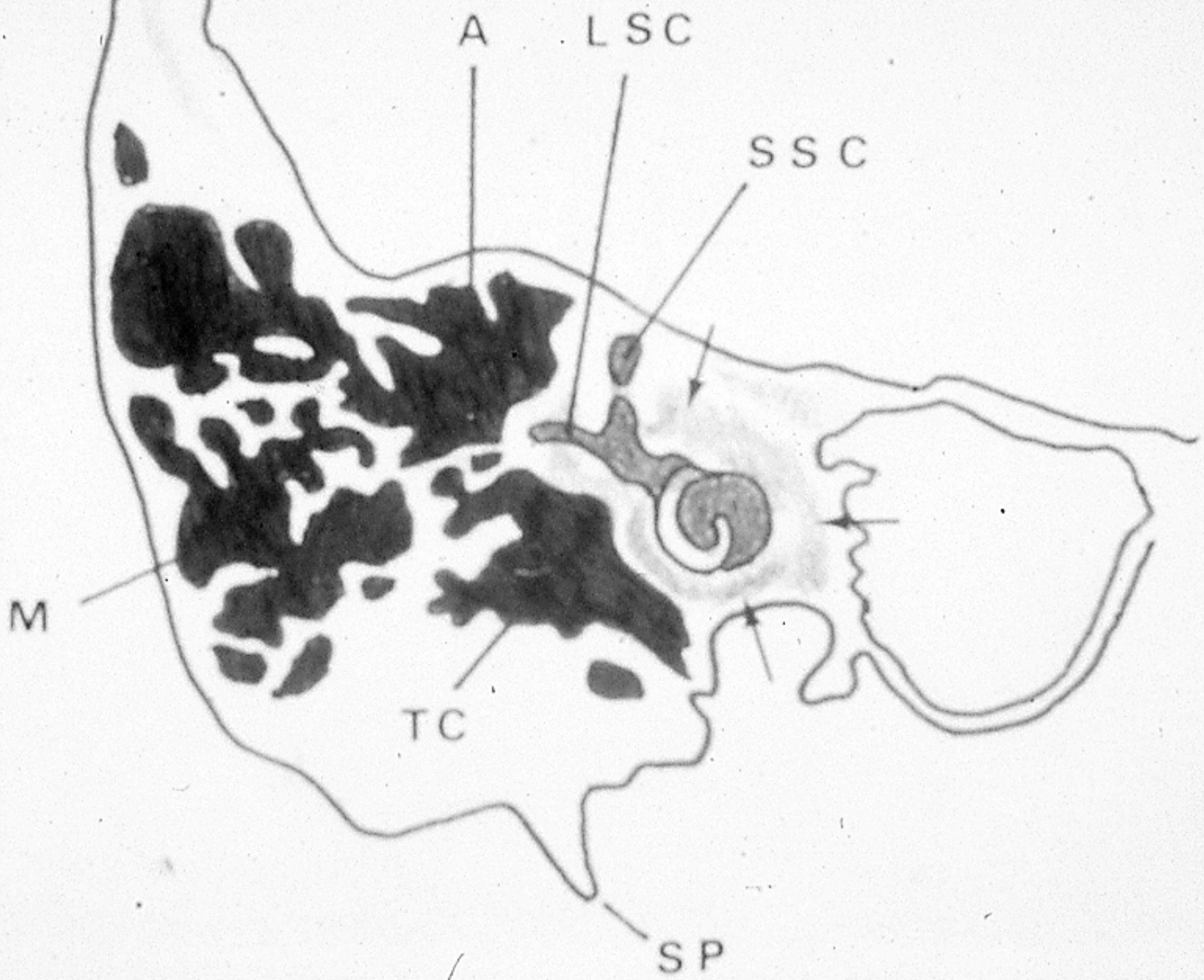
-
-
-

Perilabyrinthitis

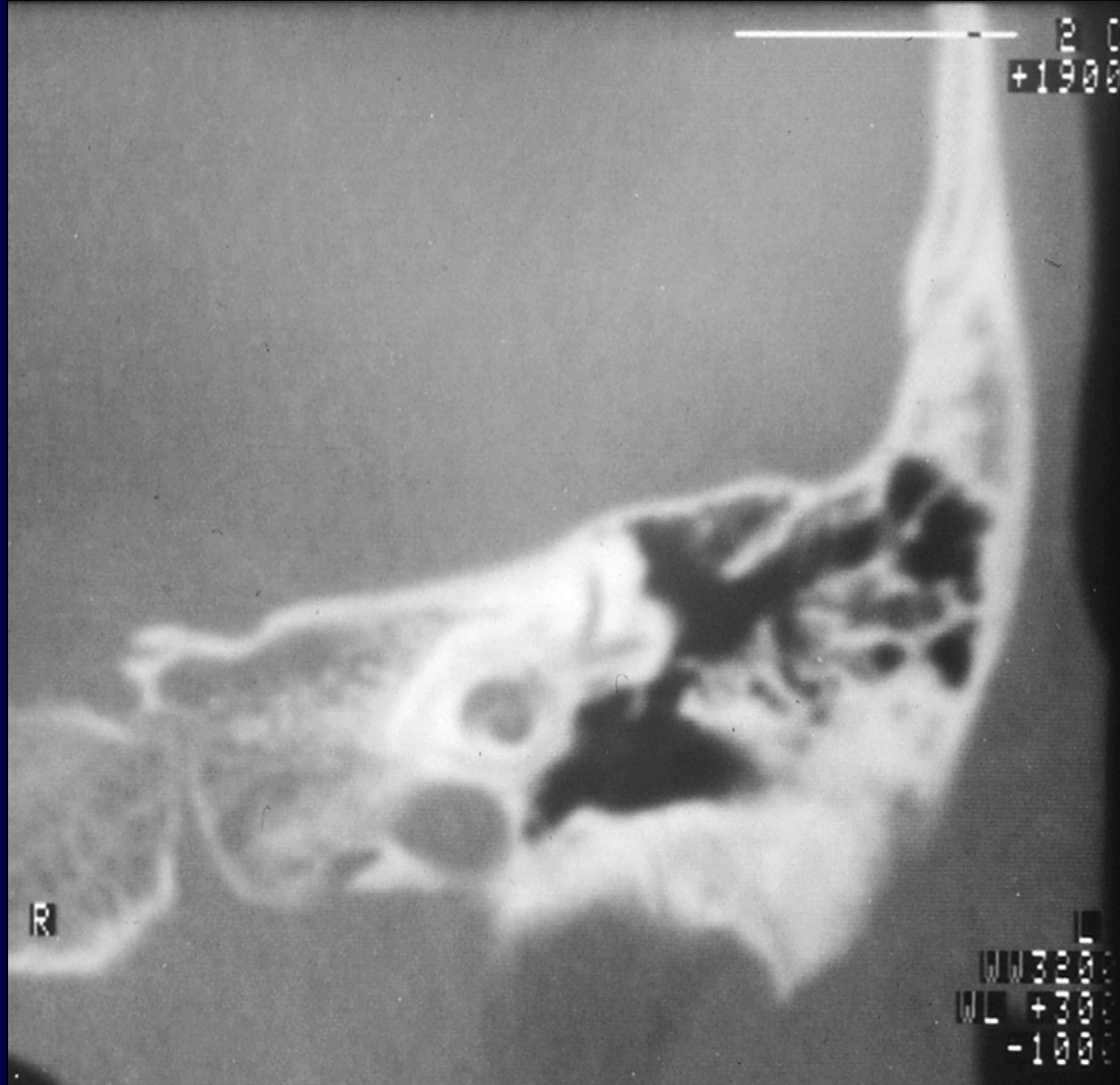Immune-mediated hydrops

-
-
-

peri-labyrinthitis



20
+1900

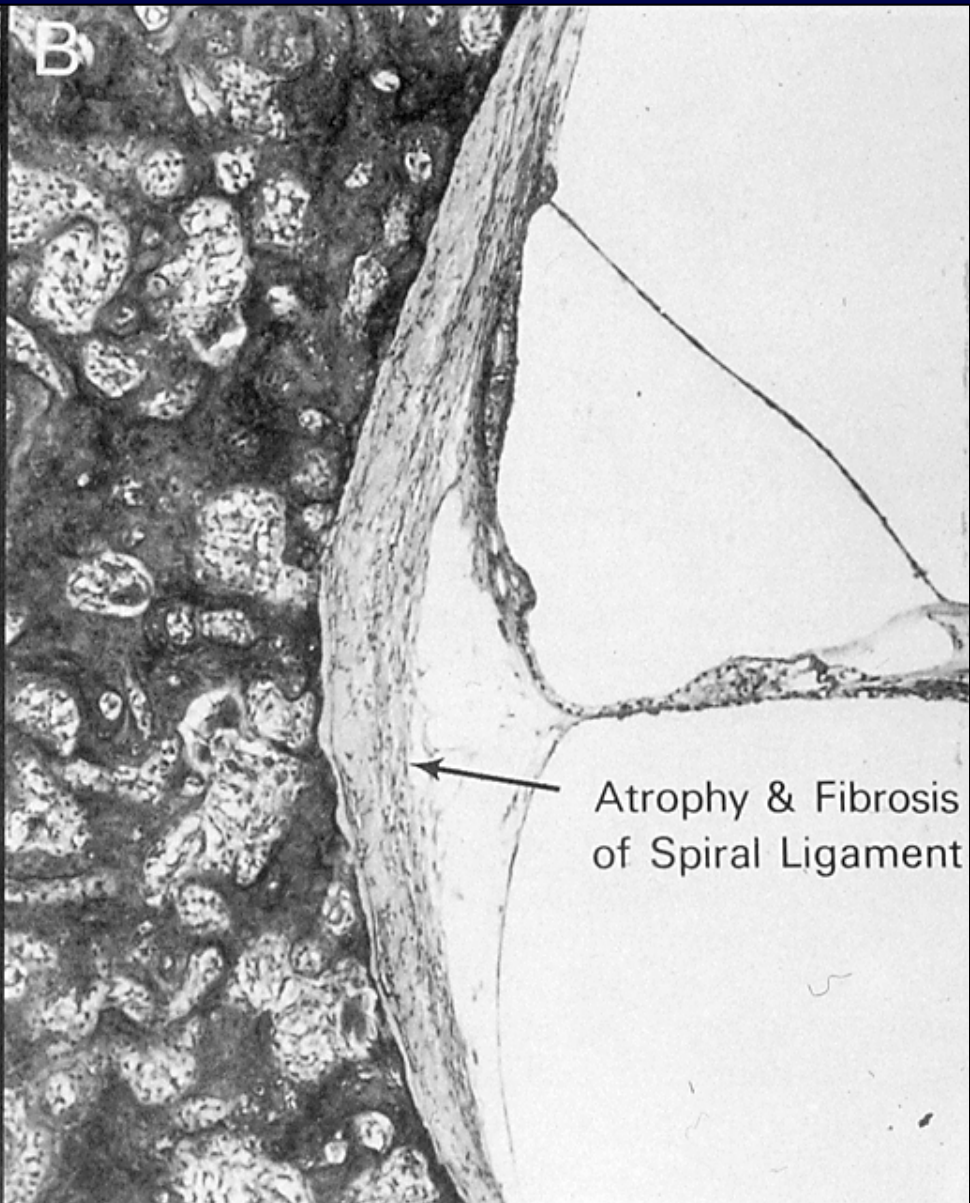
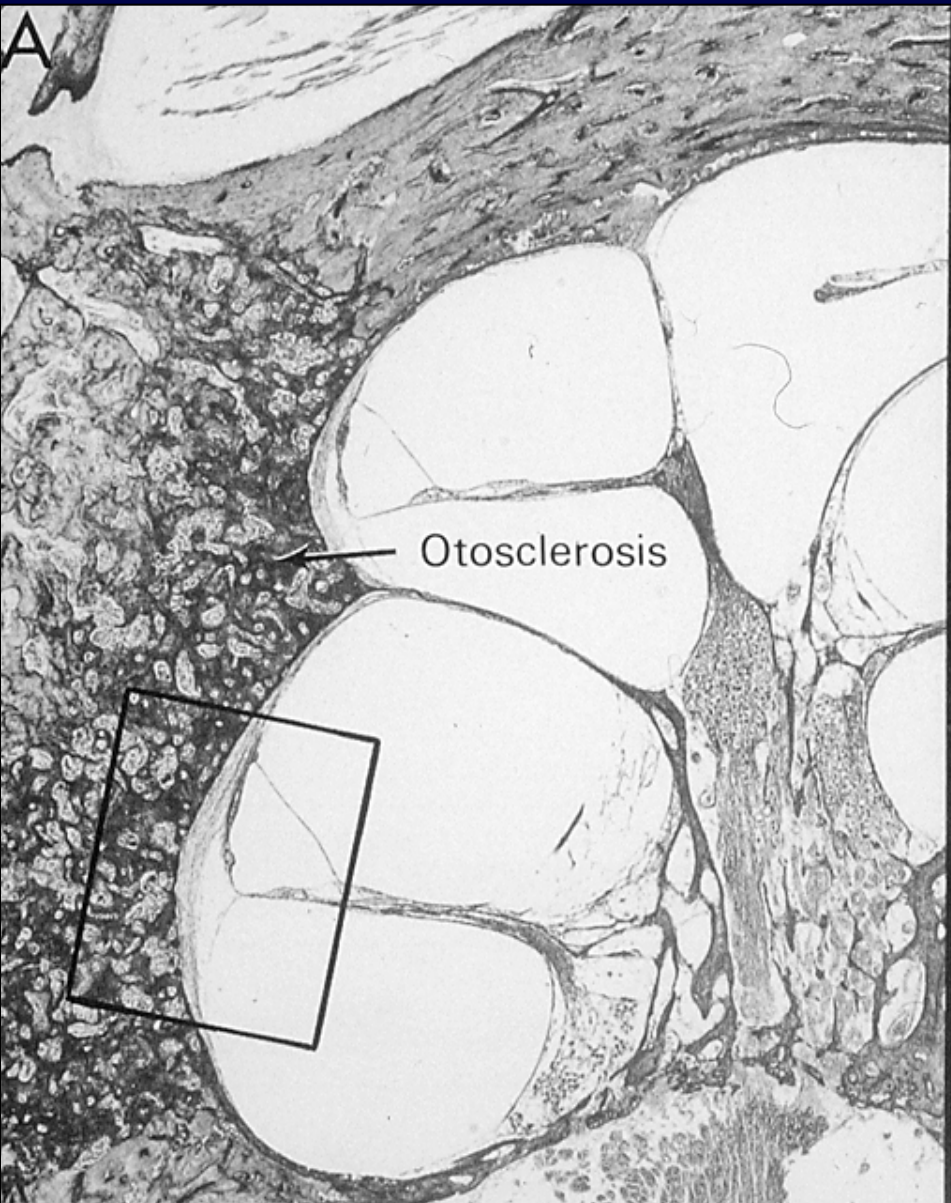


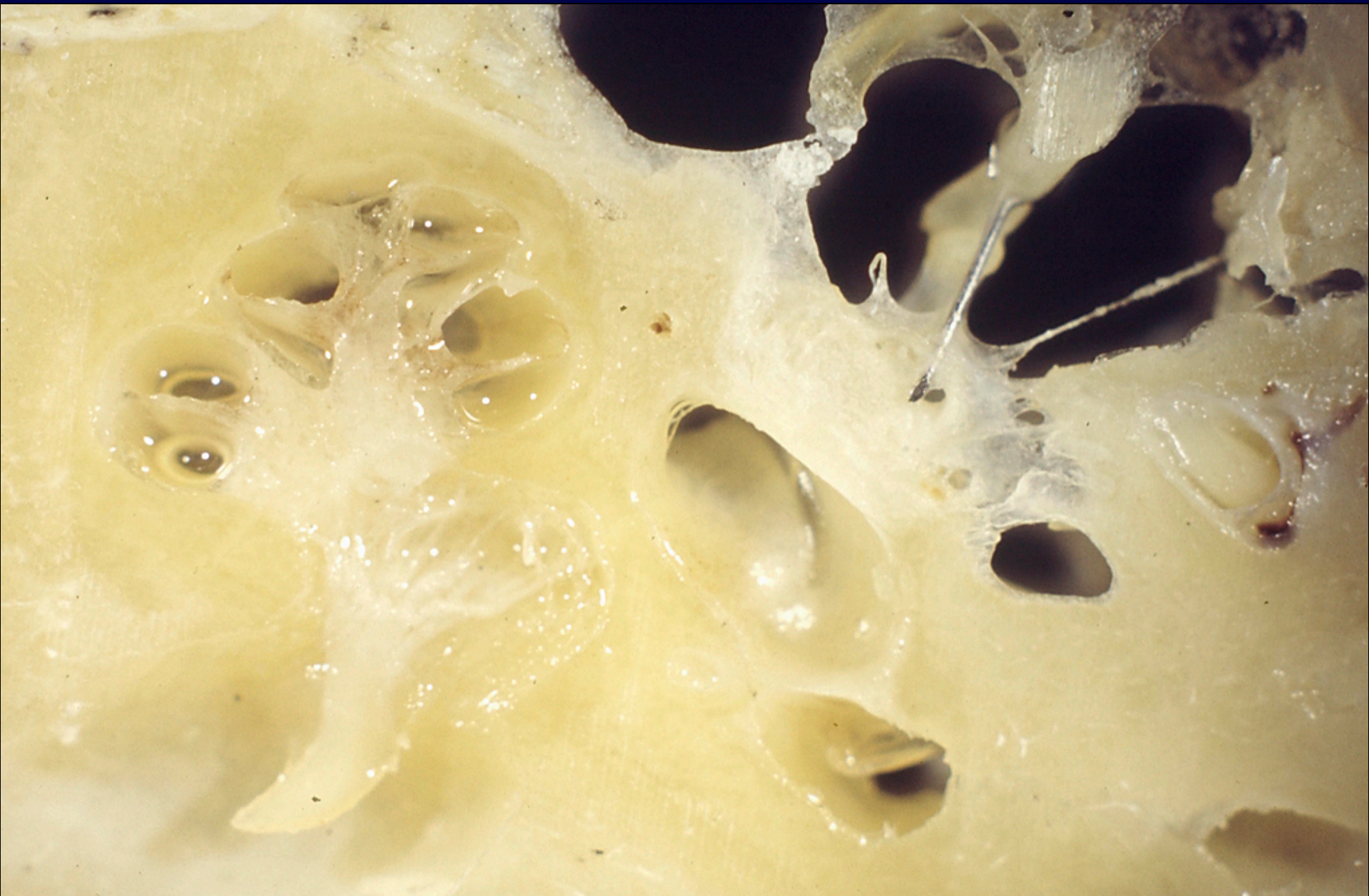R

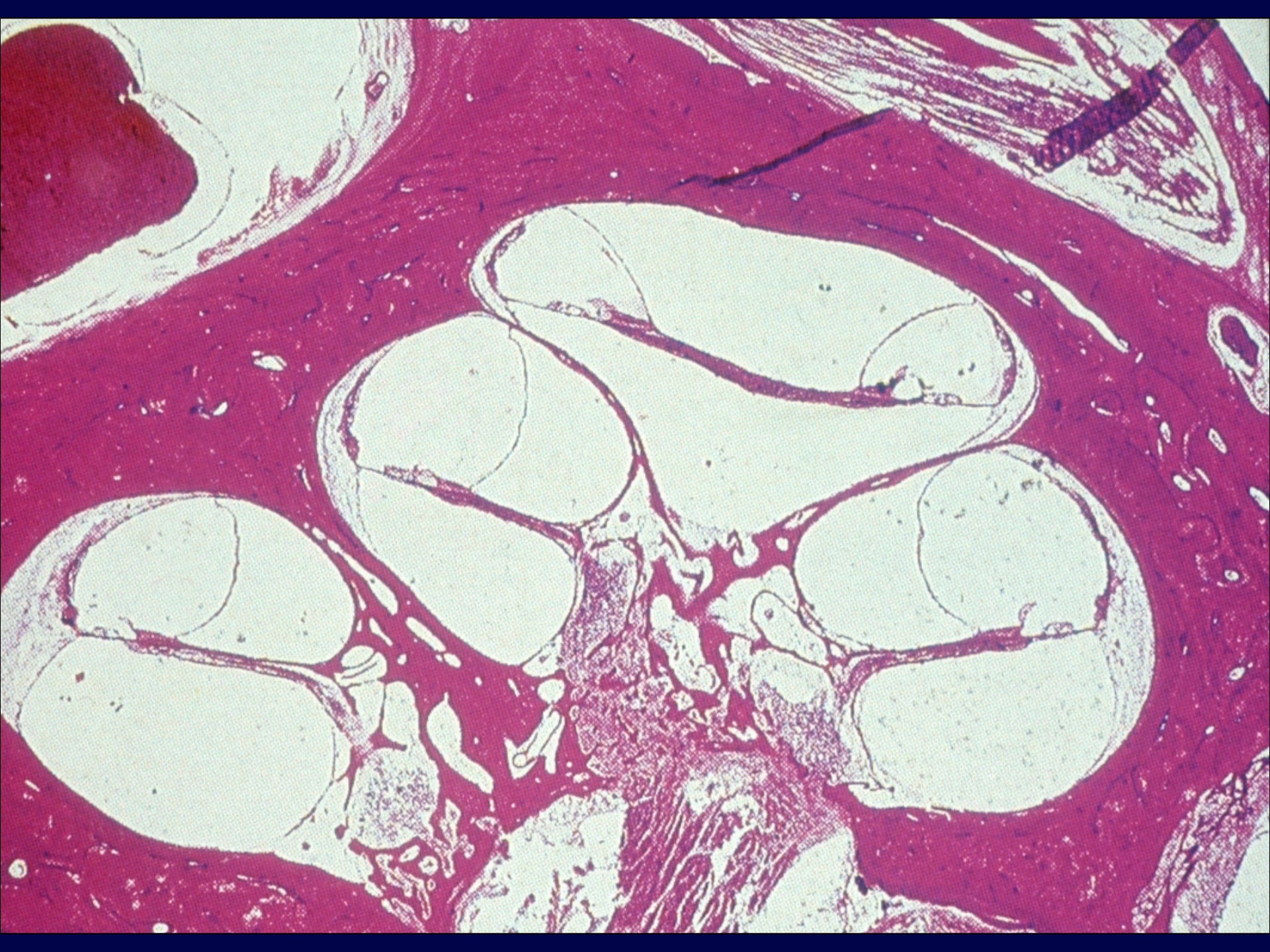
UN3200
WL +300
-1000

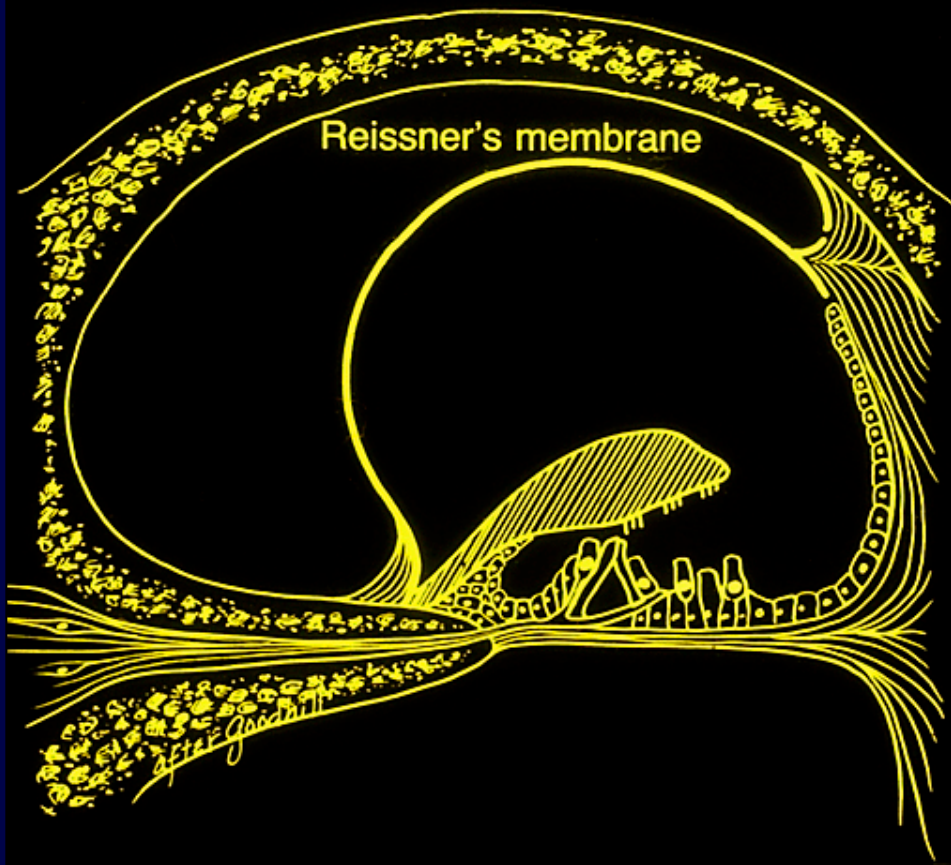
UNIV. HOSP. UTR.

TOMOSCAN 310









Reissner's membrane

after Goodall

