

MASTOID OBLITERATION



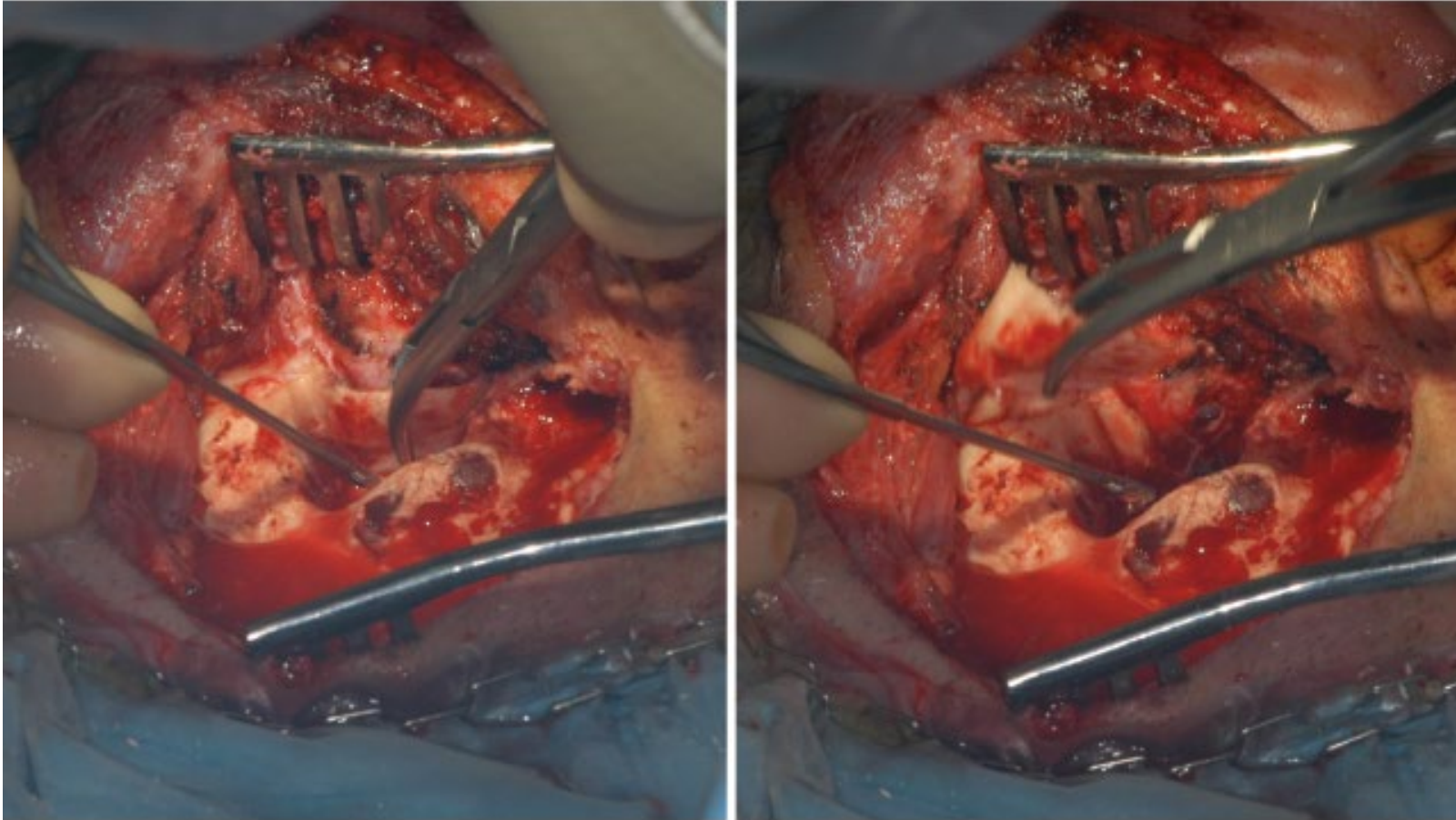
Thierry MOM
Clermont-Ferrand
FRANCE

IFOS COURSE
11-13 NOVEMBER 2018-LIMA PERU

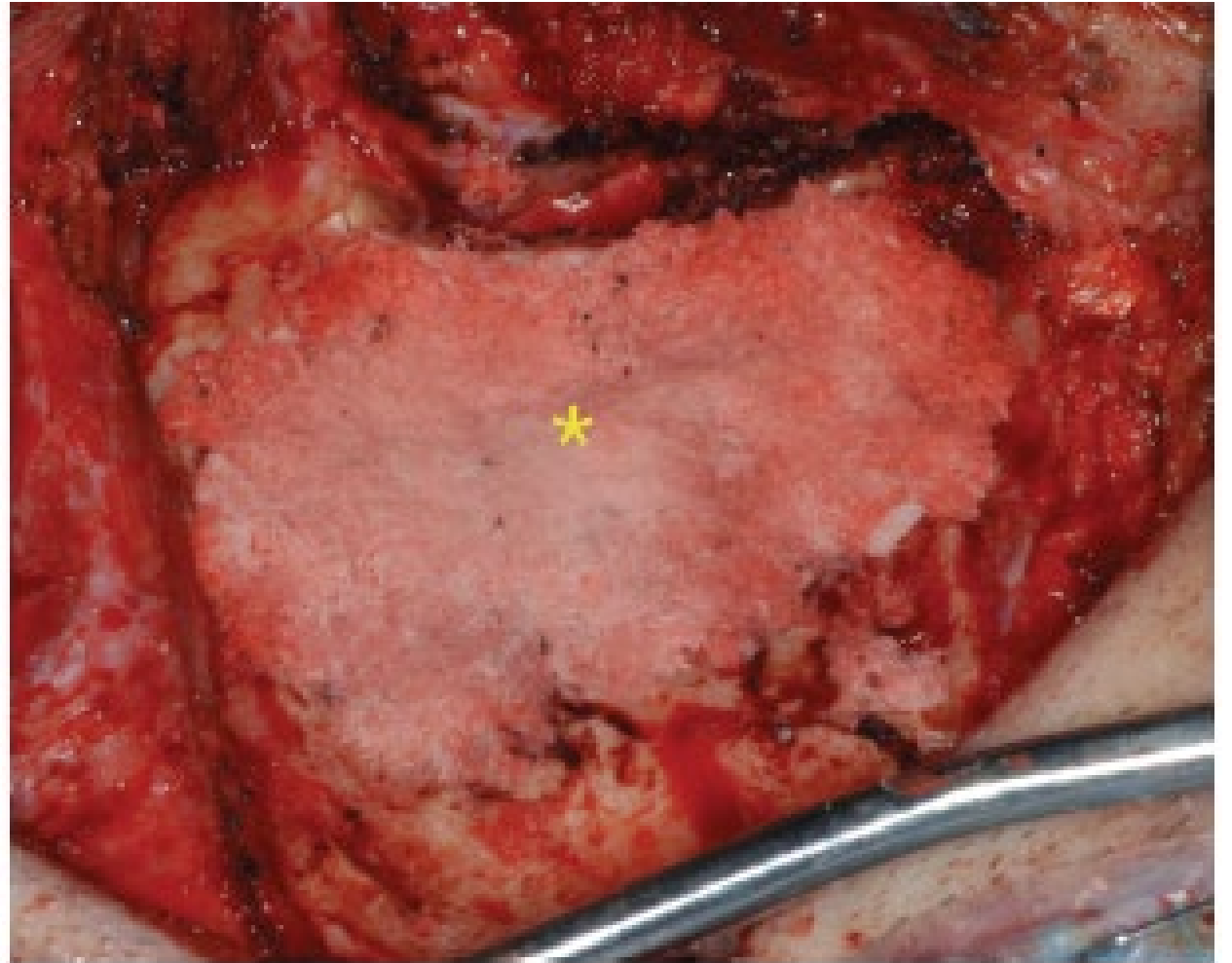
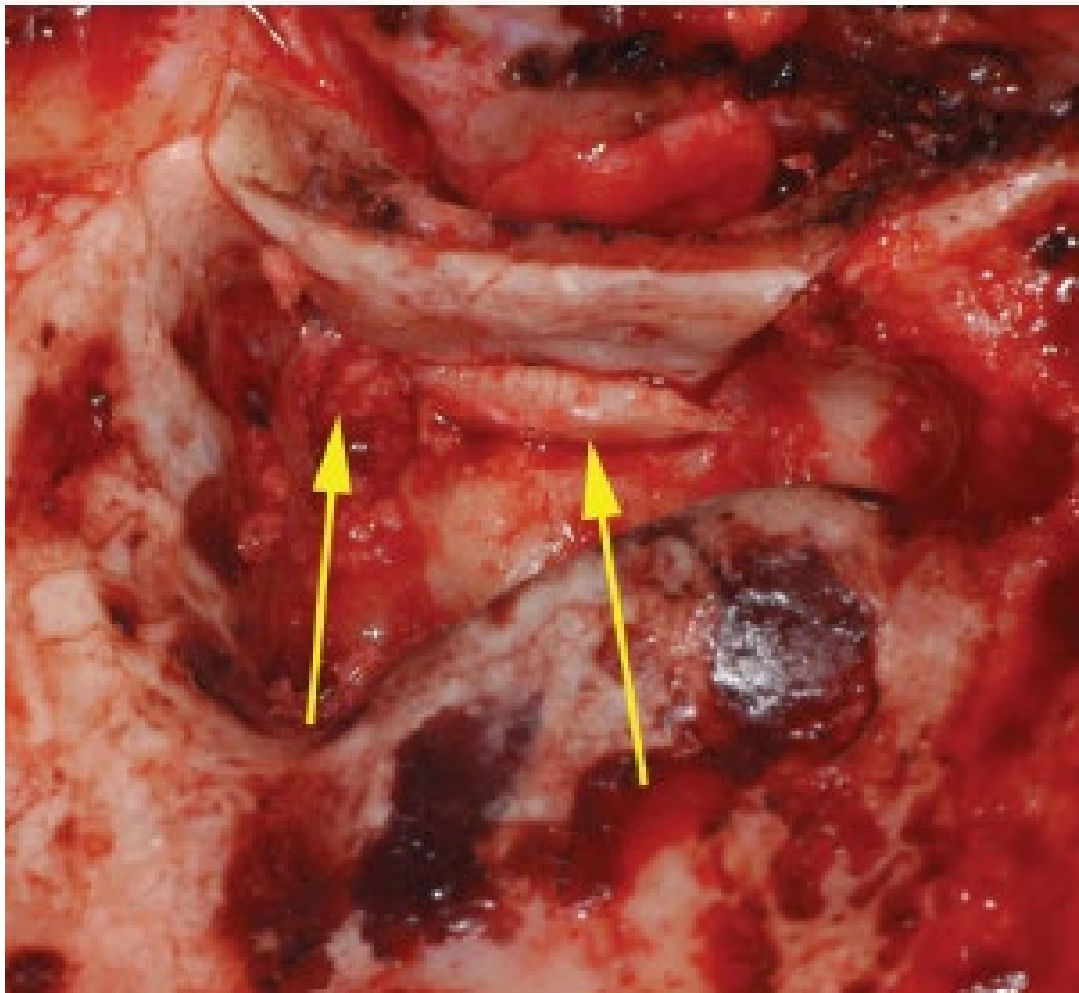
Cholesteatoma

- IDEAL AIM:
 - No residual disease
 - No recurrences
 - Good hearing
 - Preserve anatomy
- Middle ear condition in cholesteatoma: three evidences
 - Anatomical sites difficult to control
 - Constant Mucosal inflammation: lack of mucosal respiration, with retraction of tympanic membrane
 - Tympanic membrane almost constant: whatever the technique ossiculoplasty is worth it
- What can we do?
 - CWD technique: few recurrences, but repeated cleaning of the cavity mandatory, frequent otorrhea, swimming not allowed, hearing aid uncomfortable...
 - CWU: Recurrences or residual disease in almost 20% of cases in adults/ up to 40 % in children
 - Mastoid obliteration : <2% of recurrences (Mercke 1987; Gantz et al 2005); but complete modification of anatomy

Removal of External Bony Canal (Gantz et al 2005):
same comfort than in CWD for cholesteatoma removal



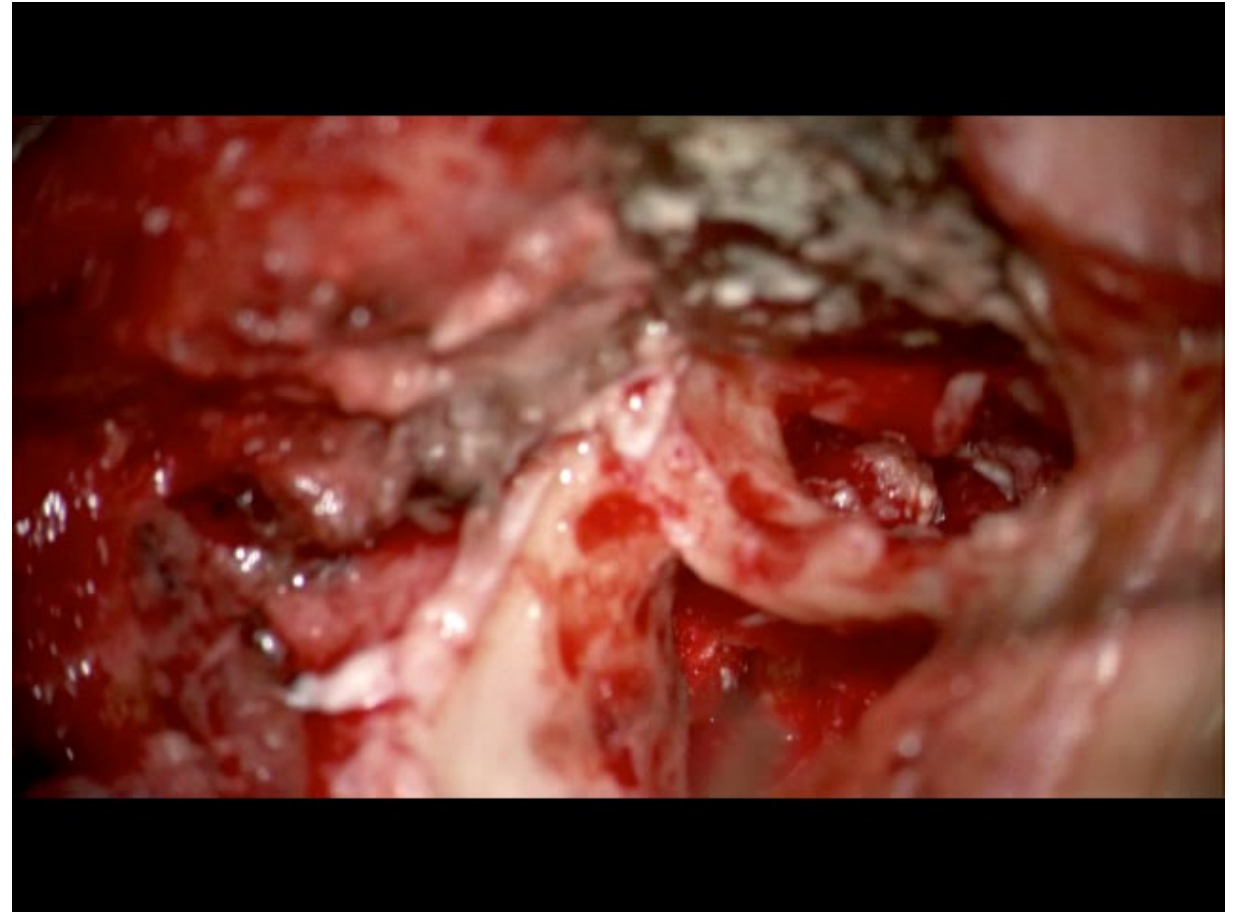
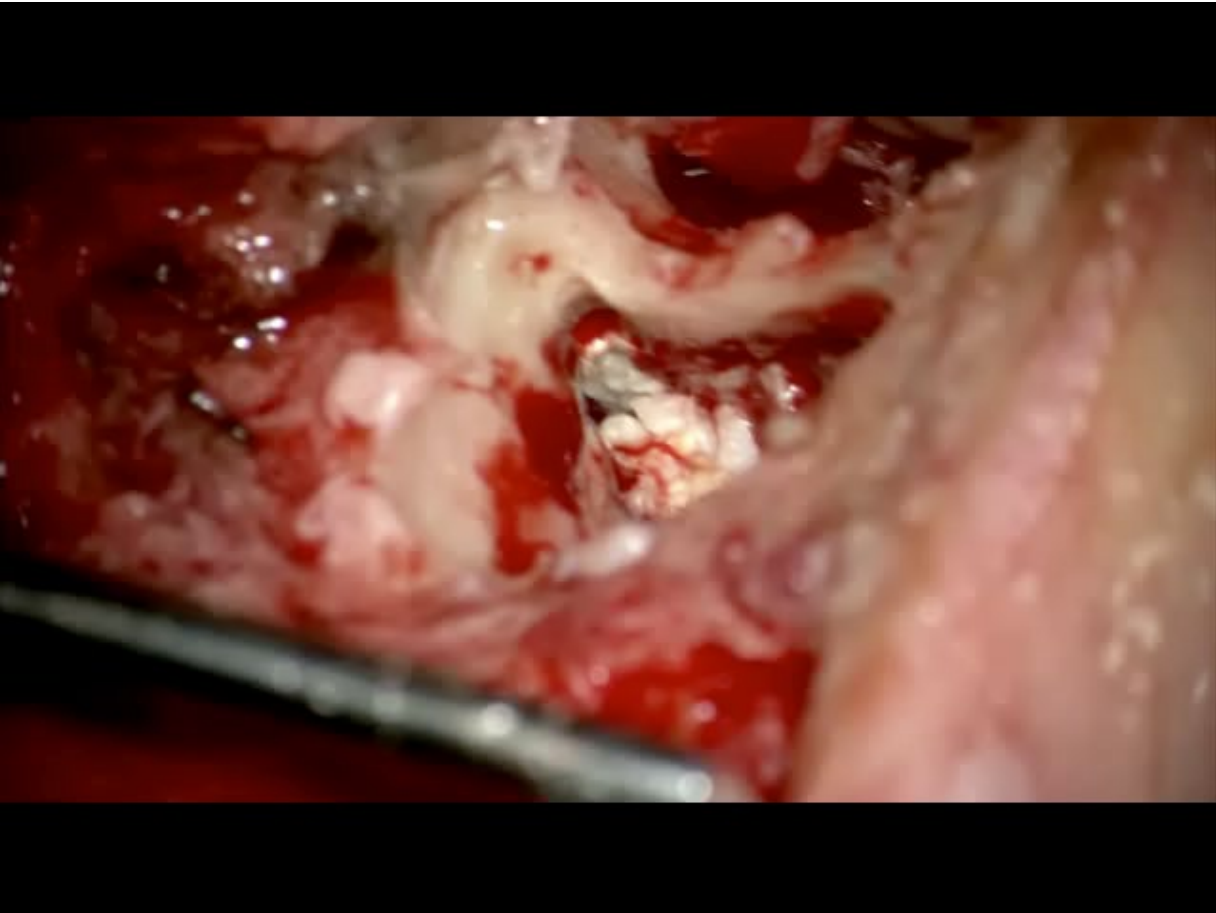
Reconstruction of External Bony Canal and Mastoid obliteration with bone dust (Gantz et al 2005)
modification of anatomy and physiology of middle ear



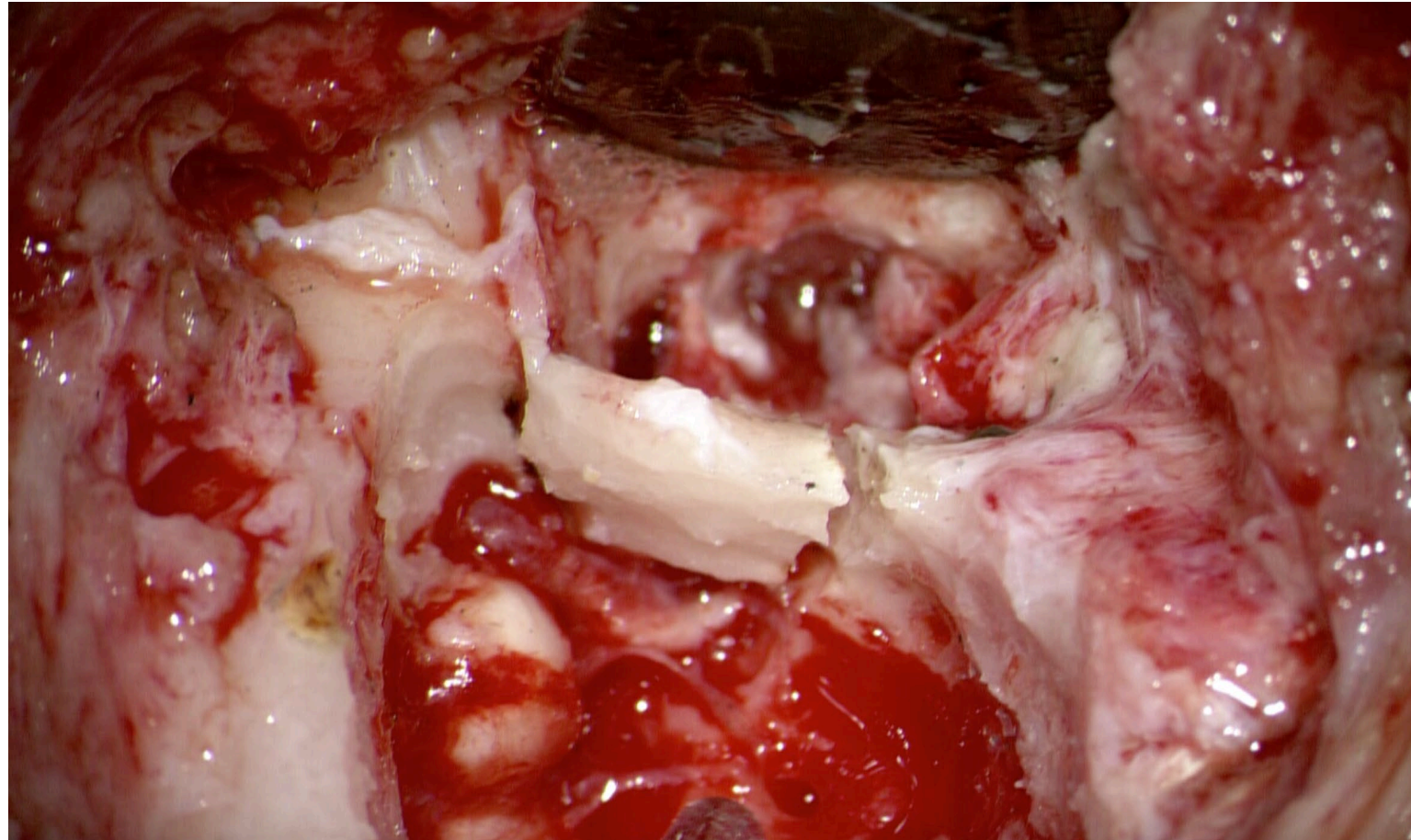
Cholesteatoma: our standpoint

- Extended Cholesteatoma, or multiple recurrences in fragile patient: CWD with single and quick procedure
- Healthy patient: Adapted removal of bony canal wall « on demand » to perfectly visualize the entire cholesteatoma
 - Remove a bony window or part of the external bony canal wall, or entire bony wall (adapt to the size of cholesteatoma)
 - Follow the matrix
 - After removal and wash –out, ossiculoplasty when needed
 - Then, reconstruction with repositioning of bony wall or cartilage or both and bone dust.
 - Obliterate may not be mandatory

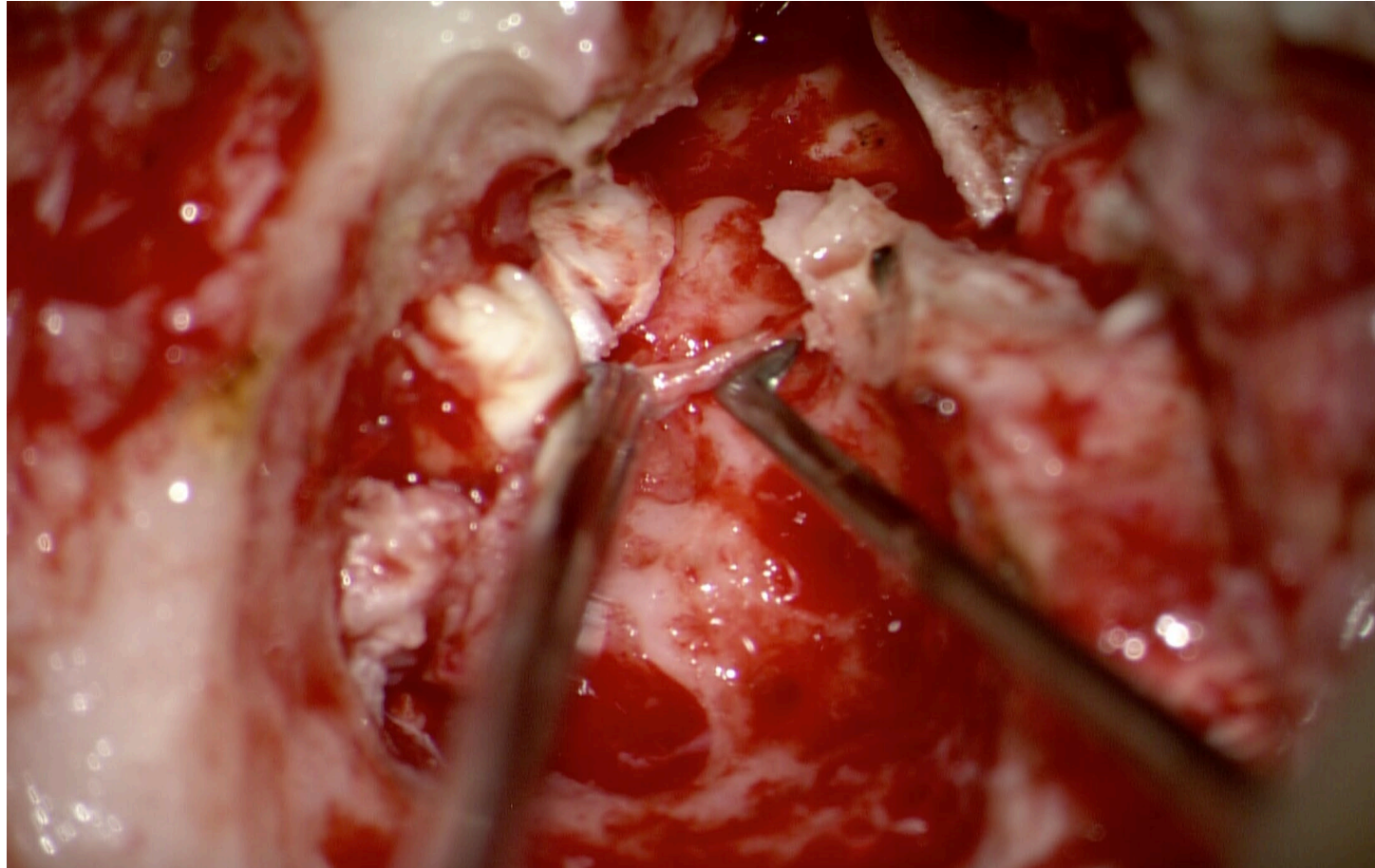
Classical CWU technique: somehow difficult to control hidden sites of middle ear



Example of transient removal of bony external canal wall with obliteration for Left recurrent Attical and mastoid cholesteatoma



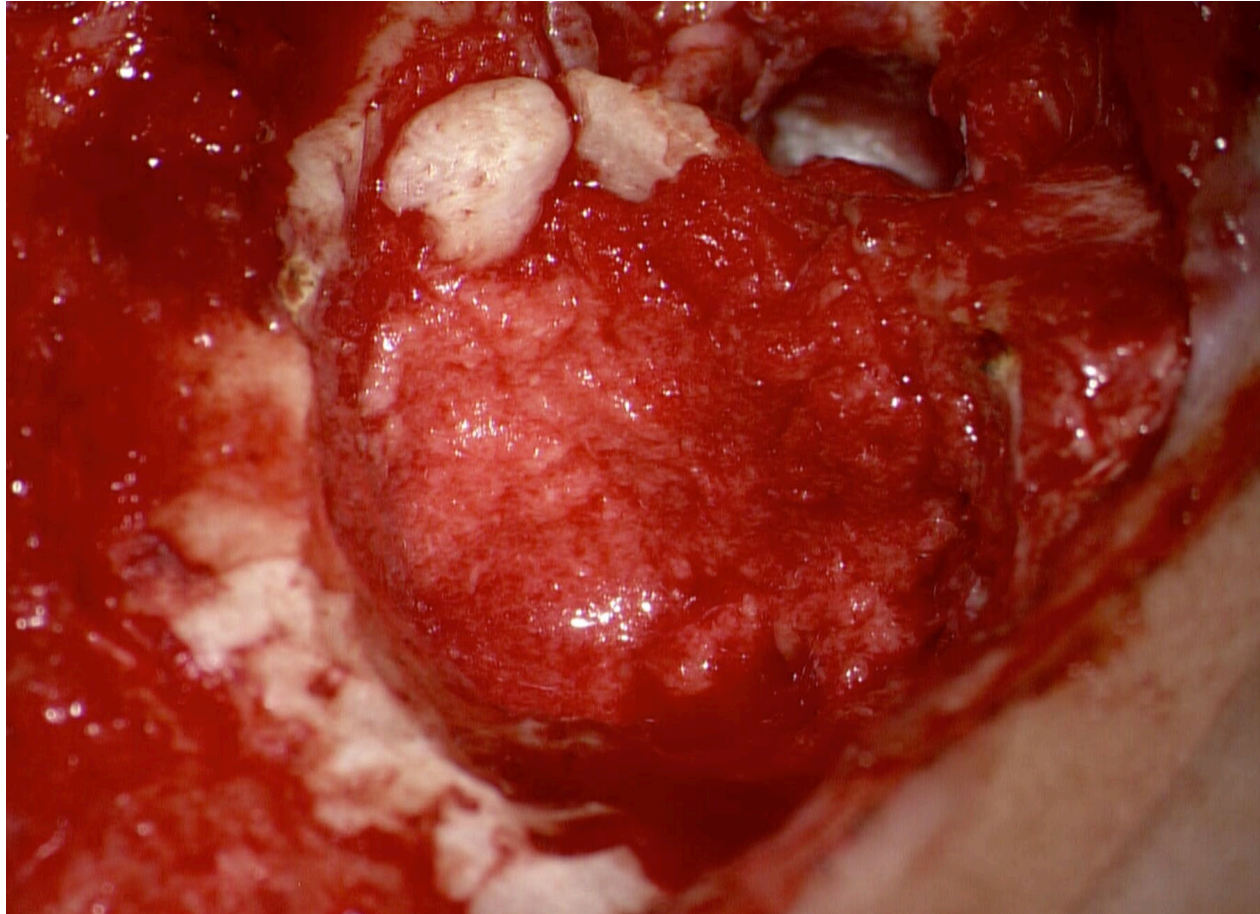
MUCH EASIER AND BETTER RESECTION AFTER
CW REMOVAL



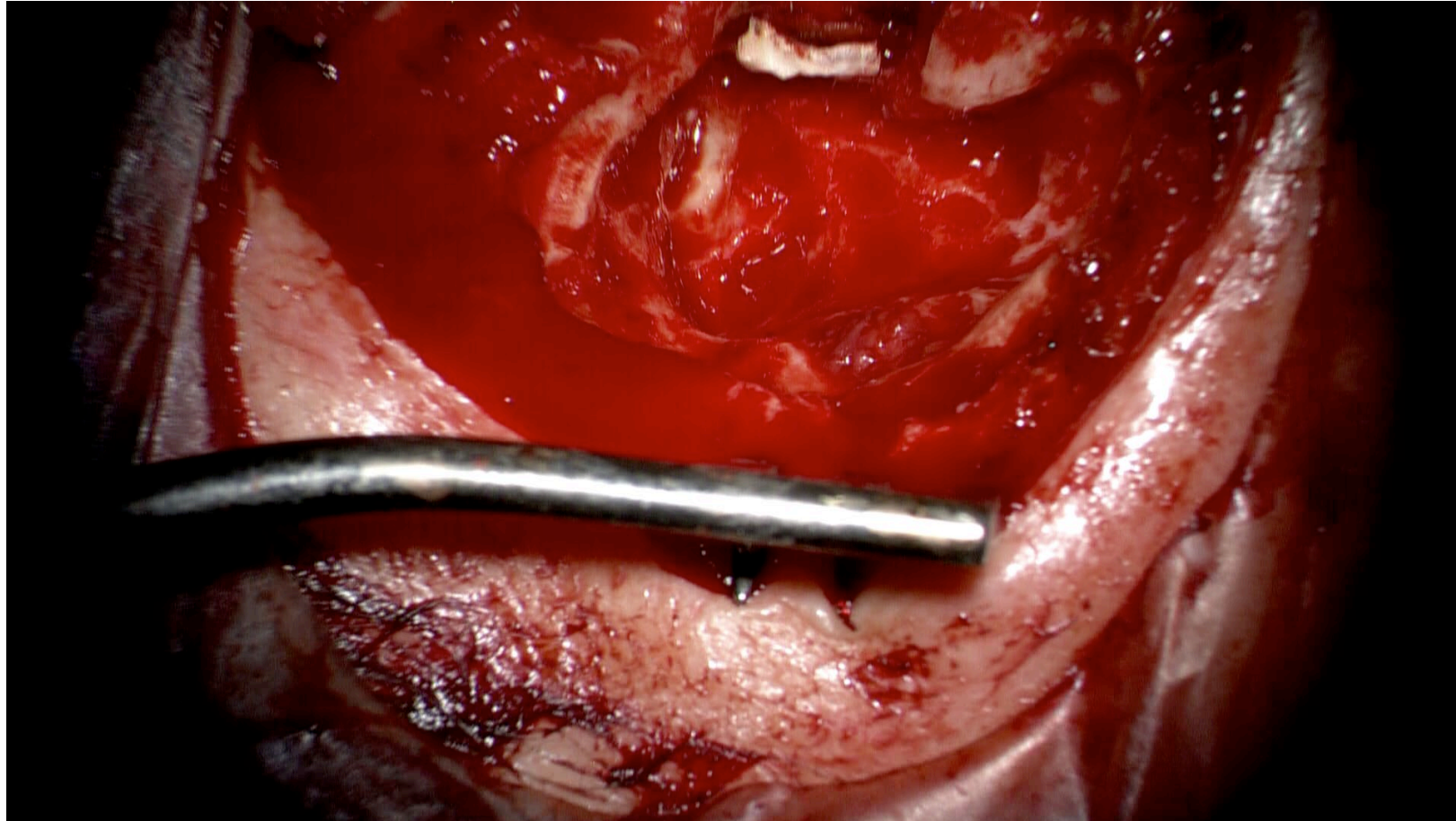
First conclusions

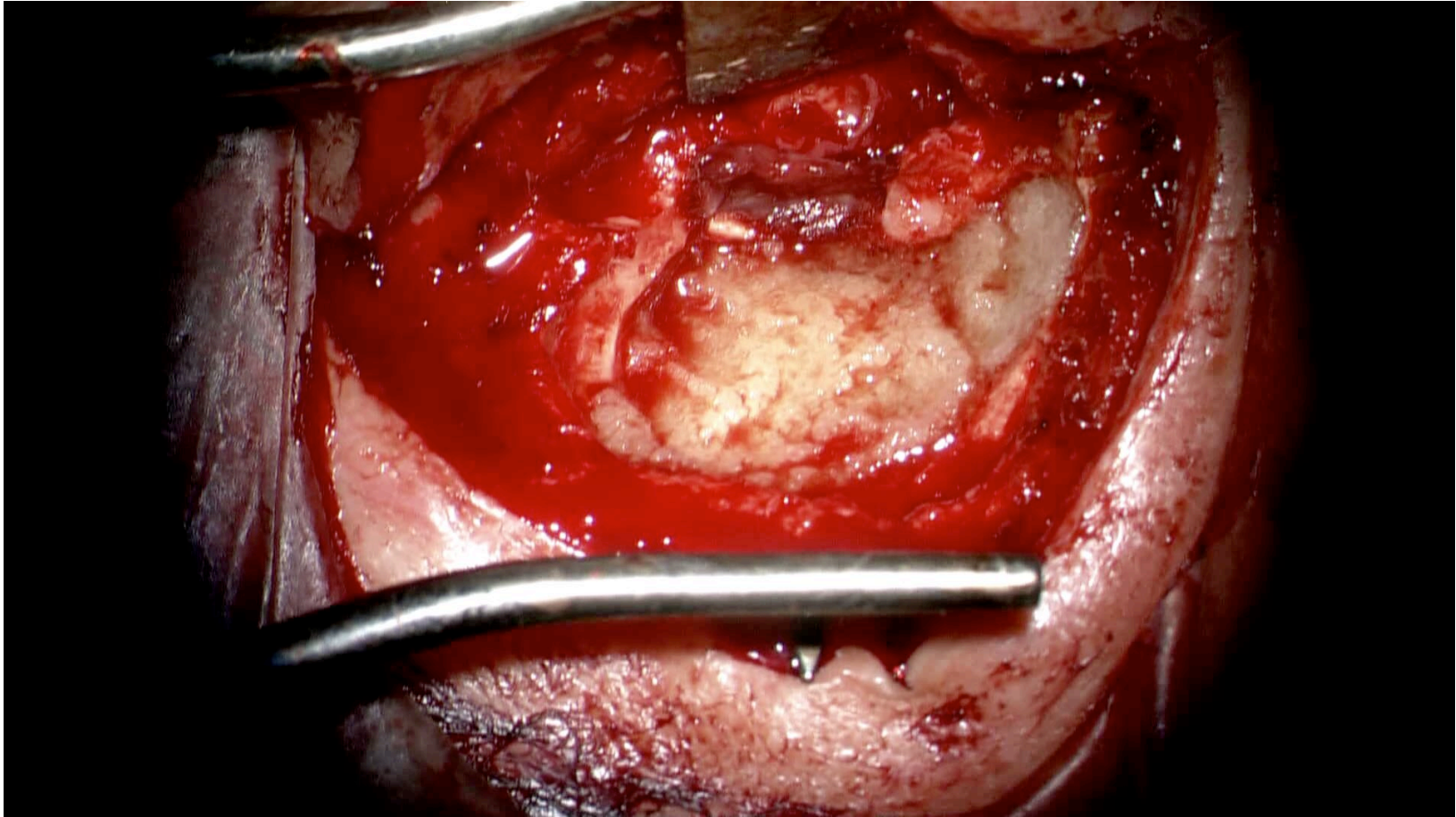
- It is obviously easier to remove cholesteatoma when the bony canal wall is removed
- Should we reconstruct as before removal? Why not?
 - Respect anatomy
 - Respect mastoid ventilation
 - No needs for cleaning an open technique
 - But, a vast cavity in bad mucosal respiratory condition expose to recurrence: same problems than a CWU technique
- Should we obliterate mastoid?
 - Precludes theoretically any extension of recurrence in mastoid
 - Change anatomy: no more respiratory function of mastoid mucosa: but is it still functioning?
 - RenderS difficult the acces to mastoid in the future (Cochlear implant)

OBLITERATION WITH AUTOLOGOUS BONE DUST

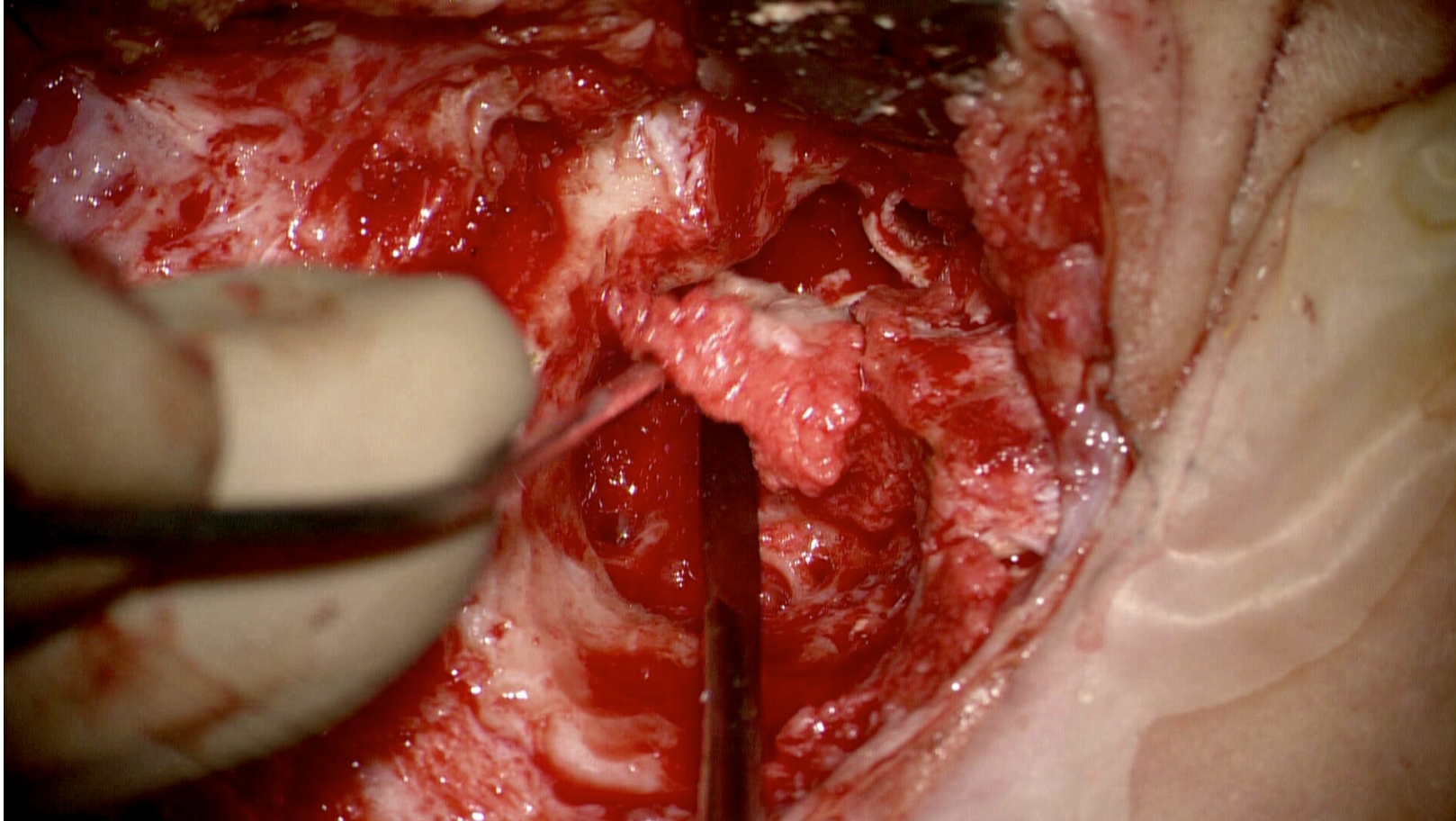


Exemple of mastoid obliteration with hydroxyapatite and glass fibers (Glassbone[®])

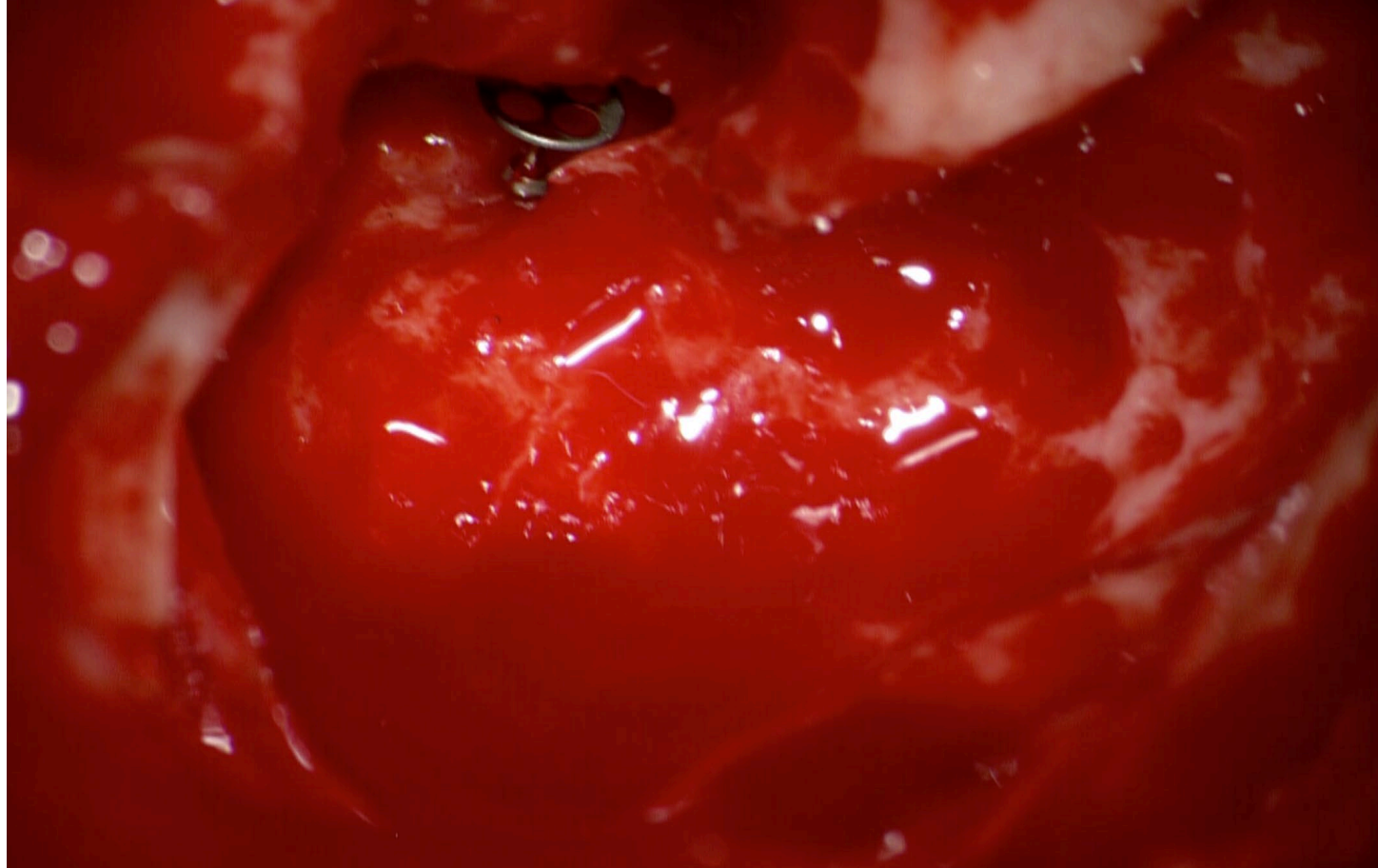




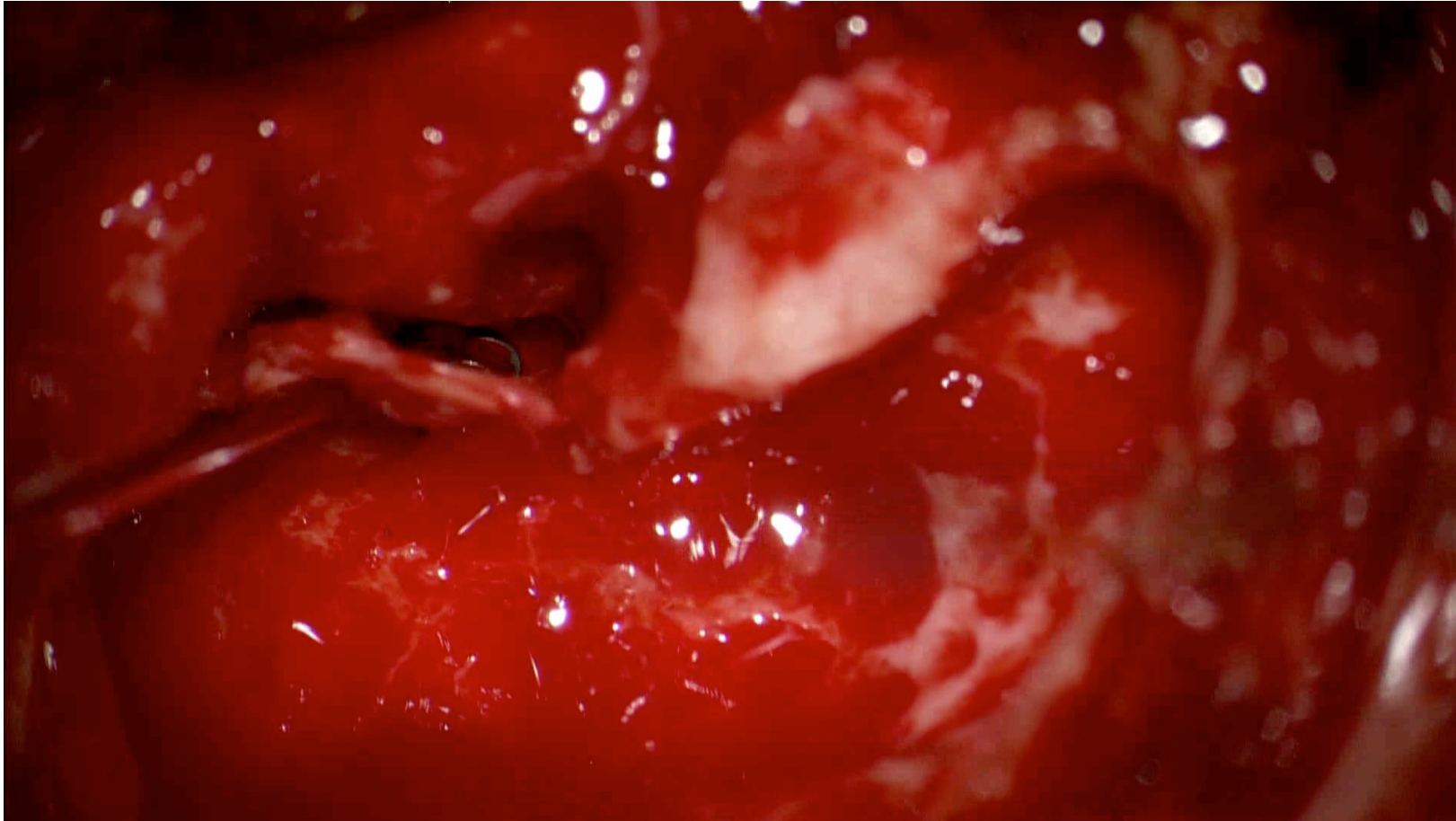
PLACING BACK BONY CANAL WALL WITH NO
OBLITERATION: RESPECT ANATOMY BUT THEORETICAL RISK
OF RECURRENCE



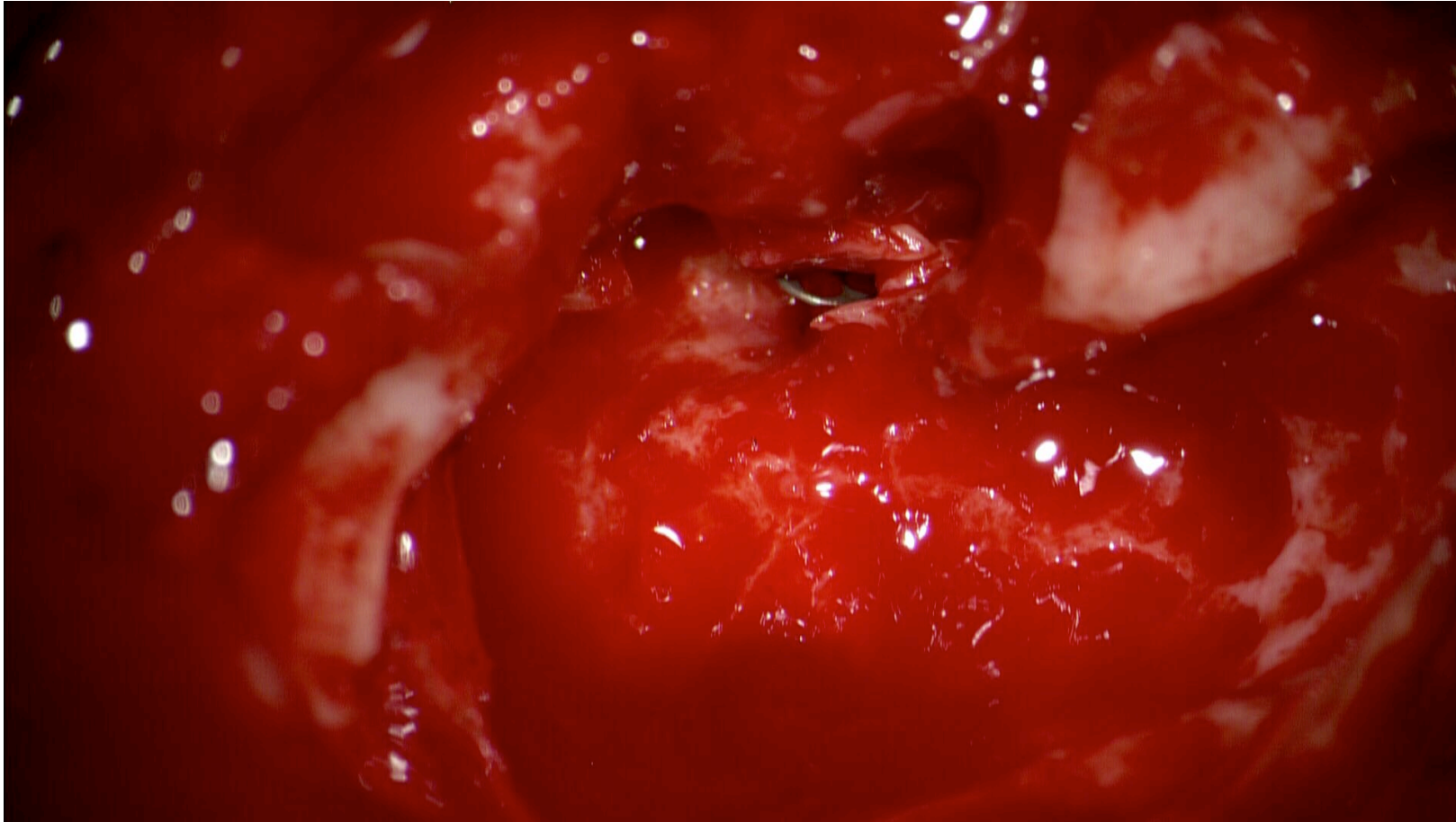
WHAT ABOUT OSSICULOPLASTY?



CARTILAGE PLATE ON TORP



REPOSITIONING OF BONY CANAL WALL



FOLLOW-UP

- OSSIFICATION IN 6 -8 WEEKS : BONE DUST OR FOREIGN SUBSTANCES WITH HYDROXYAPATITE
- NO INFECTION WITH BONE DUST WHEN SOAKED BY ANTIBIOTICS EARDROP
- NO EXTRUSION OF BONE DUST
- WHEN OSSIFIED: NO RESORPTION

- MIXTURE OF HYDROXYAPATITE AND FIBERGLASS IS ANTISEPTIC
- INDUCES VERY GOOD OSSIFICATION
- QUANTITY: NOT LIMITED IF NOT BY COST
- BUT CAN BE EXTRUDED IN SHORT OR MIDDLE TERM: NEED FOR REVISION SURGERY

Conclusion

- Cholestatoma: Don't hesitate to remove canal wall bone « on demand »: much easier / much better resection
- Reconstruct canal wall with removed bone and bone dust when possible. Foreign material with hydroxyapatite if bone missing
- Don't hesitate to obliterate mastoid in adults when massive destruction or several recurrences
- In children: give a chance with CWU technique first, but prefer mastoid obliteration to CWD
- Ossiculoplasty is always possible such as in CWD or CWU techniques