





1062

| | | | | | |
|-----------------|---|---|---|---|---|
| 5 VIDEOS | 062 01'49'' | 063 02'00'' | 064 02'05'' | 065 02'05'' | 066 02'08'' |
| |  |  |  |  |  |

CHOLESTEATOMA SURGERY VIDEO SESSION

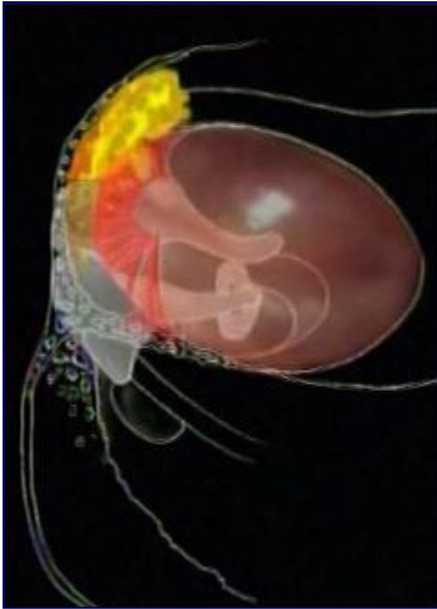
■ B. FRAYSSE, J. FAYAD



IFOS WORLD MASTER COURSE ON HEARING REHABILITATION

DUBAI
March 2019, 28-29-30

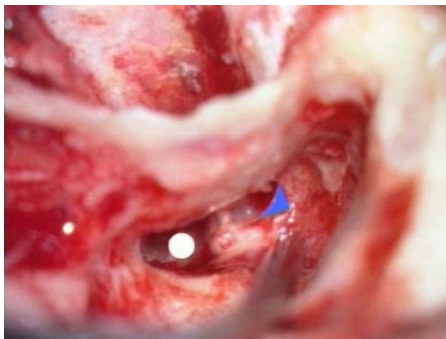
CHOLESTEATOMA AND SURGICAL STRATEGY



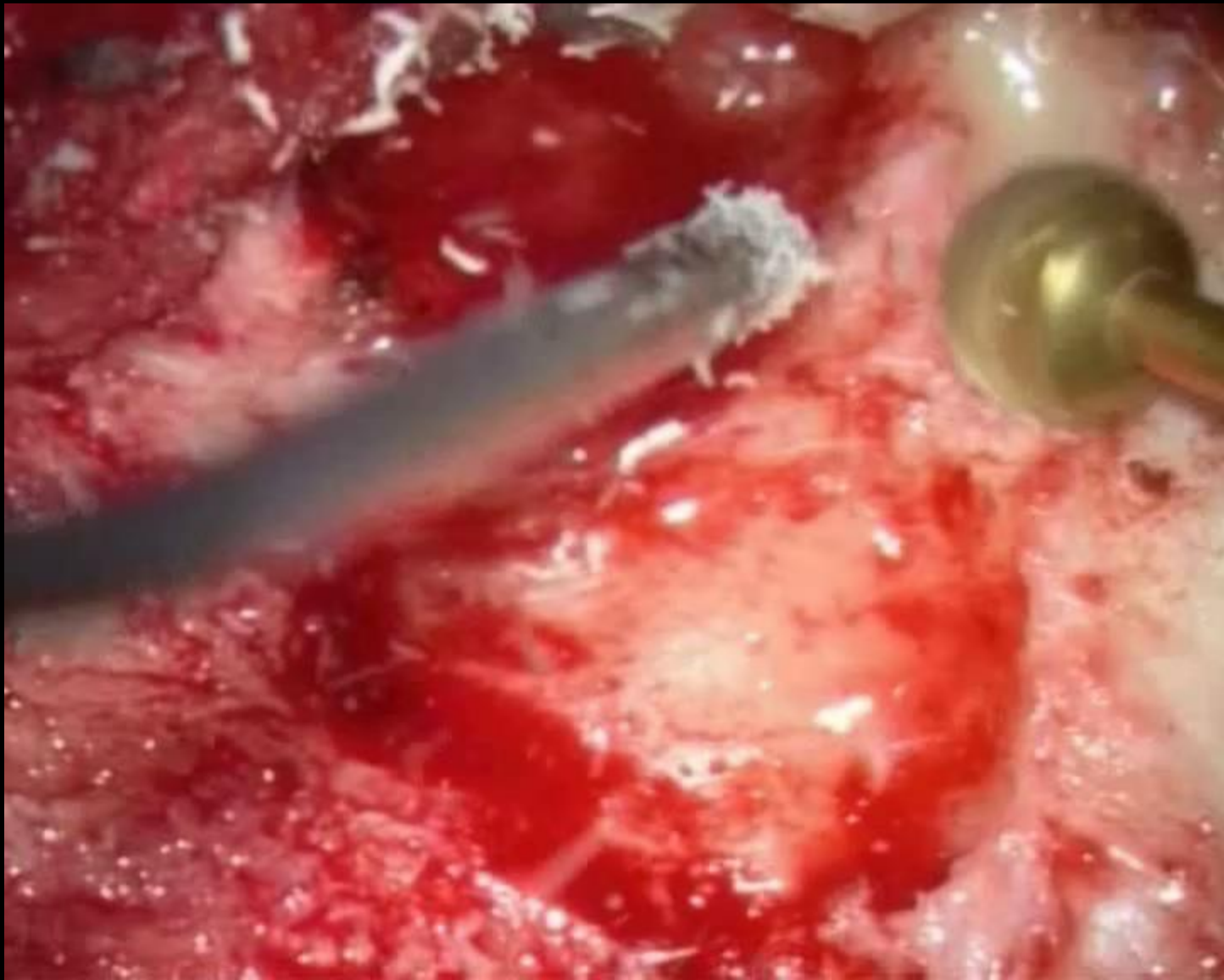
Anterior and posterior
epitympanic cholesteatoma



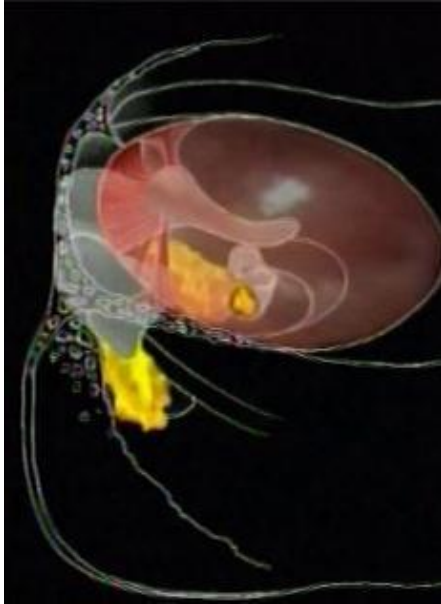
Canal wall up technique with
anterior epitympanotomy



- *Removal of the incus, head of the malleus, attic bony plate, tensor fold*
 - *To improve accessibility*
 - *To create a new aeration pathway from the supratubal recess to the antrum*



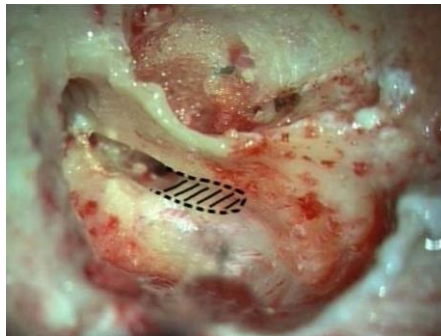
CHOLESTEATOMA AND SURGICAL STRATEGY



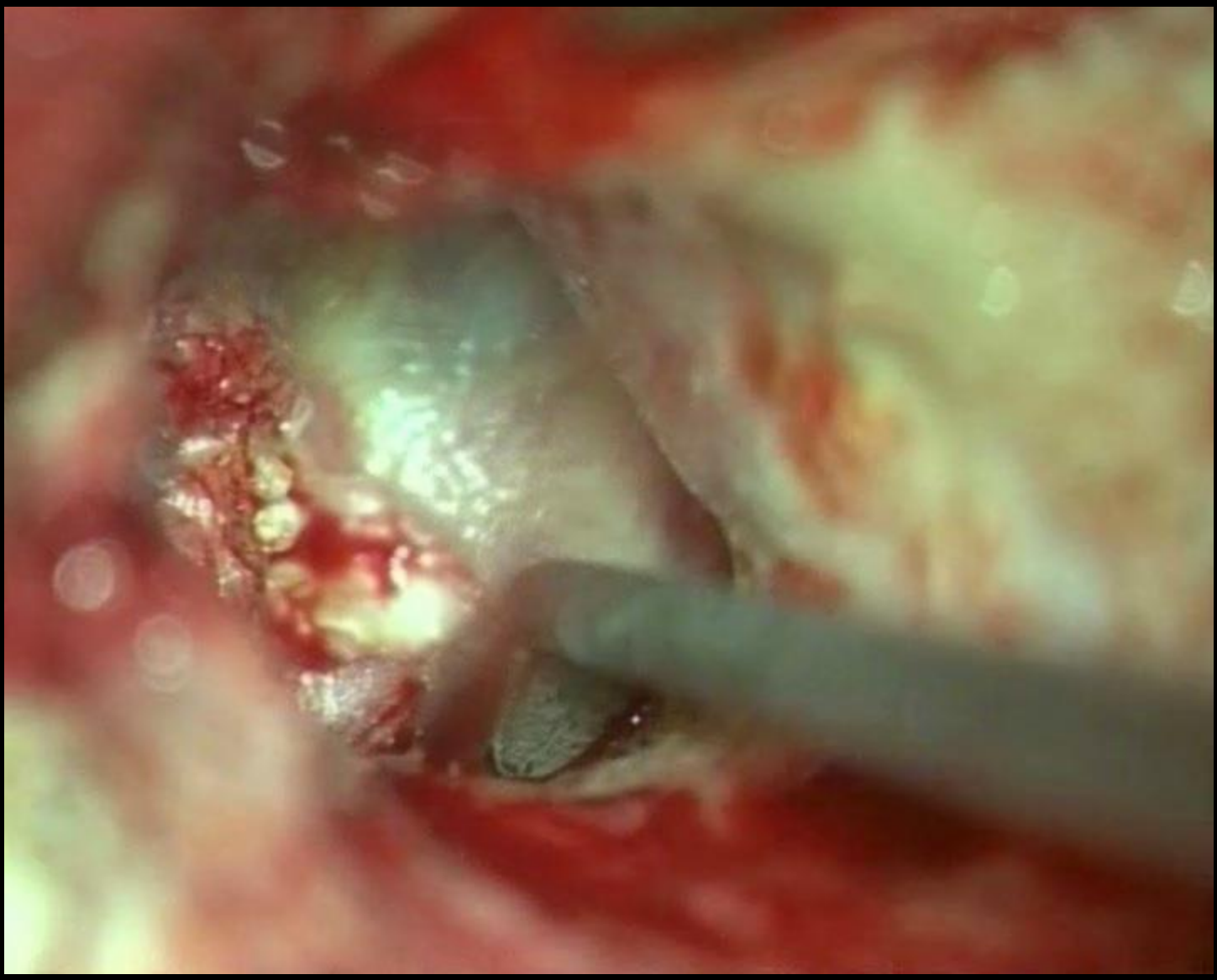
Mesotympanic cholesteatoma



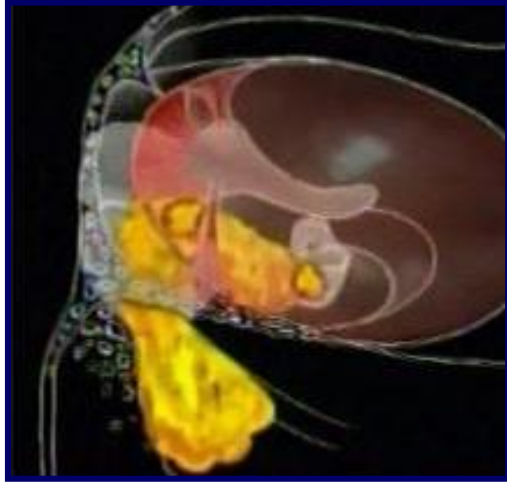
Canal wall up technique with posterior tympanotomy



- *Identification of the vertical (mastoid) segment of the facial nerve*
- *Opening of the facial recess and large posterior tympanotomy (extended facial recess)*



CHOLESTEATOMA AND SURGICAL STRATEGY



Holotympanic cholesteatoma



Sclerotic mastoid



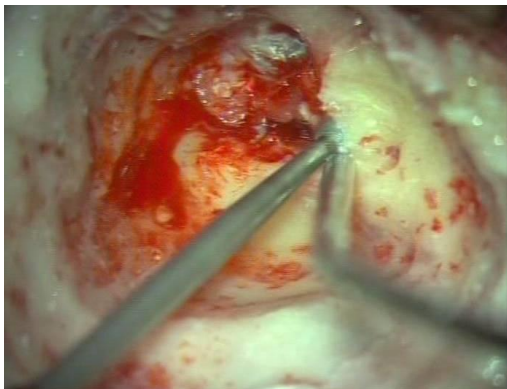
Large mastoid



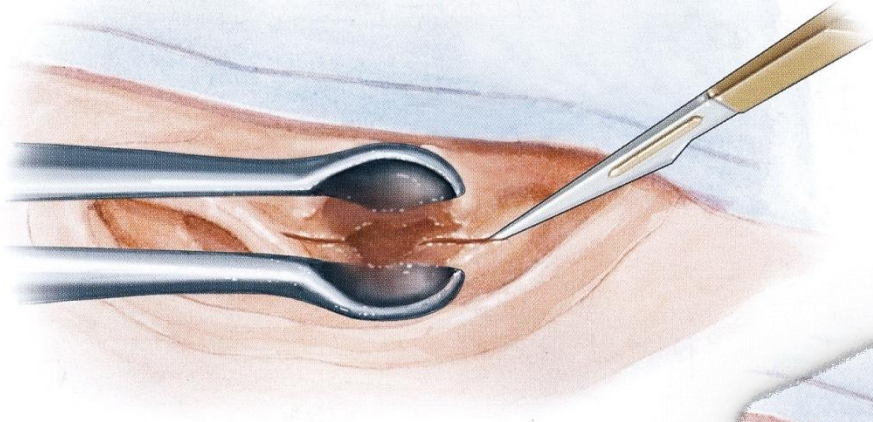
Open technique



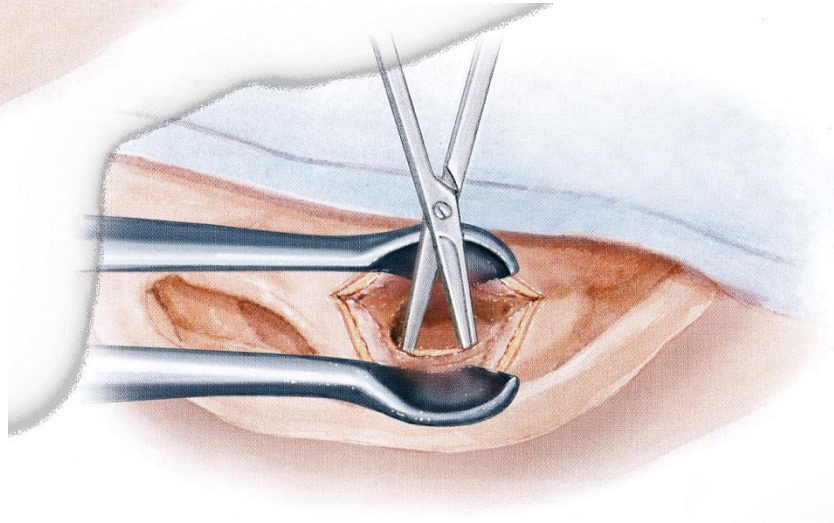
Combined approach
Anterior and posterior tympanotomy



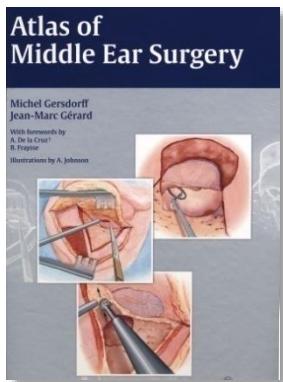
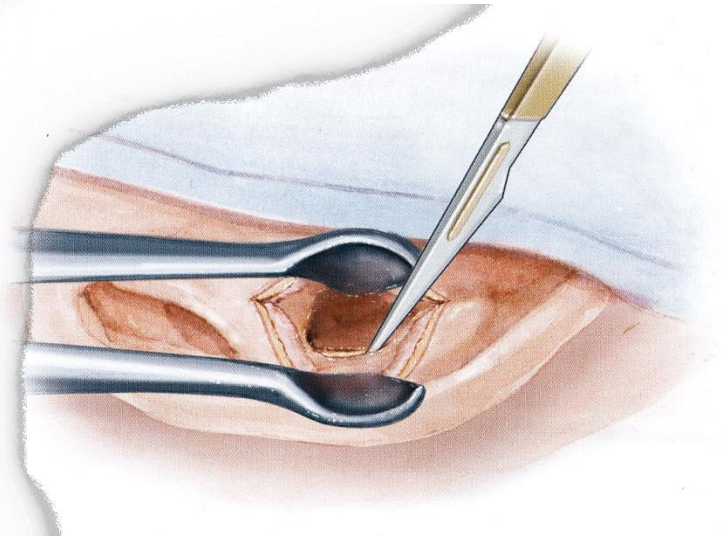
- Lateral incision

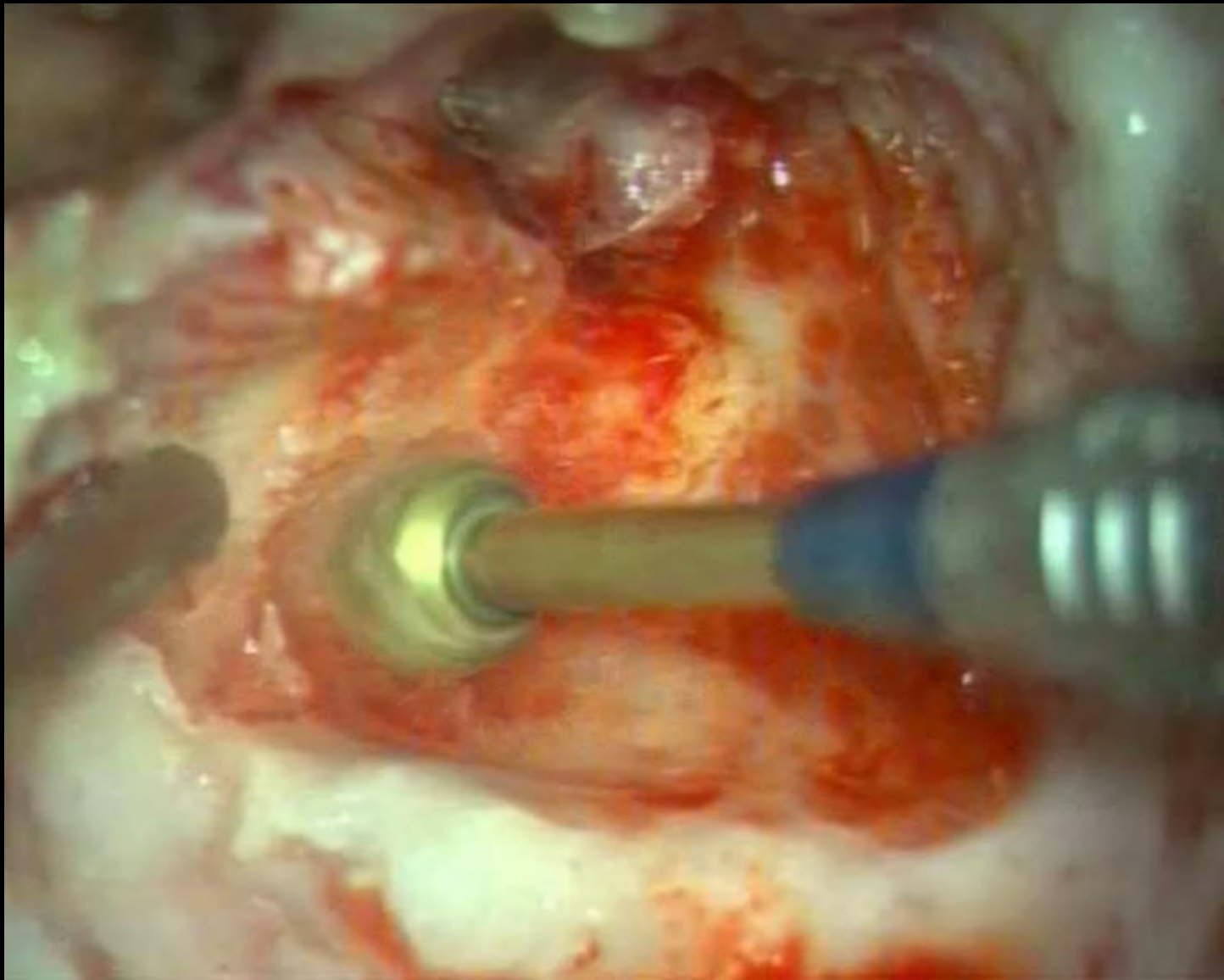


- Skin dissection

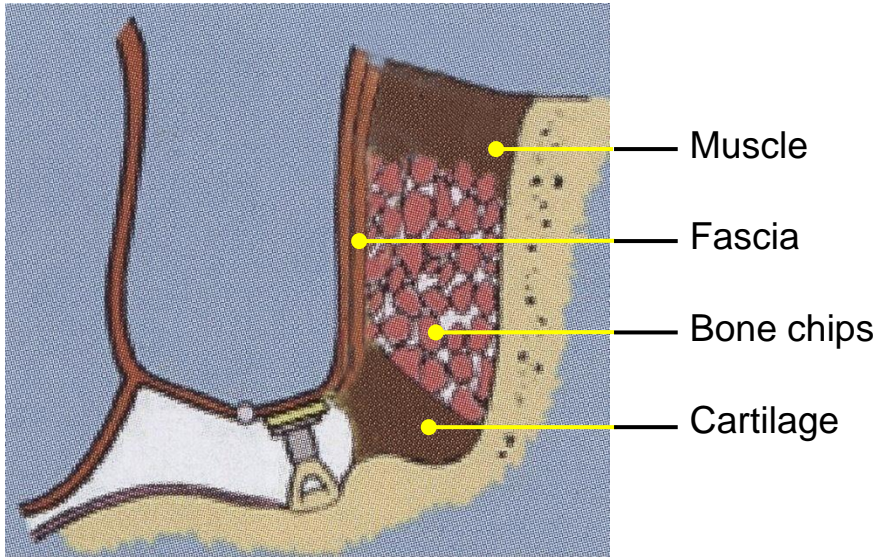


- Cartilage removal

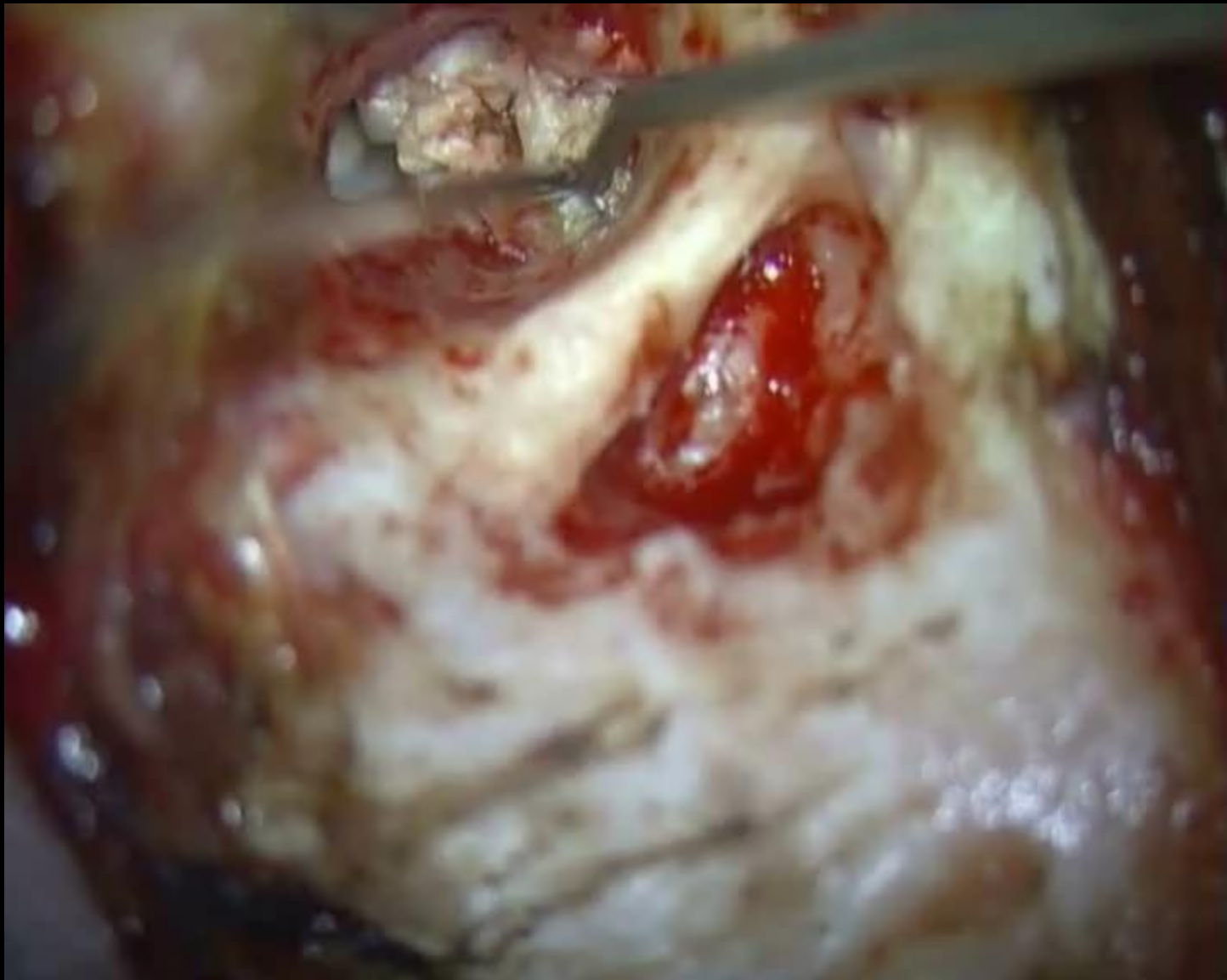




OBLITERATIVE TECHNIQUE



- FELDMANN 1978
- MERKE 1987
- GANTZ 2005
- VERCRUYSSSE 2008





SFORL
SOCIÉTÉ FRANÇAISE
D'ORL ET DE CHIRURGIE
DE LA FACE ET DU COU

IFOS WORLD MASTER COURSE ON HEARING REHABILITATION

Thank you for your attention